

# World Journal of *Clinical Cases*

*World J Clin Cases* 2023 August 6; 11(22): 5193-5415



**MINIREVIEWS**

- 5193 Research progress on reactive oxygen species production mechanisms in tumor sonodynamic therapy  
*Dong HQ, Fu XF, Wang MY, Zhu J*

**ORIGINAL ARTICLE****Retrospective Study**

- 5204 Combining the age-male-albumin-bilirubin-platelets score and shear wave elastography stratifies carcinogenic risk in hepatitis C patients after viral clearance  
*Masaoka R, Gytoku Y, Shirahashi R, Suda T, Tamano M*
- 5215 Changes in neurotransmitter levels, brain structural characteristics, and their correlation with PANSS scores in patients with first-episode schizophrenia  
*Xu XJ, Liu TL, He L, Pu B*
- 5224 Five-year outcomes of immediate implant placement for mandibular molars with and without chronic apical periodontitis: A retrospective study  
*Yang H, Luo D, Yuan MJ, Yang JJ, Wang DS*

**Observational Study**

- 5236 Standardization of apple cancellation test for neglect patients in Korea: An observational study  
*Jang WH, Jang JS*

**Prospective Study**

- 5244 Diabetic neuropathy results in vasomotor dysfunction of medium sized peripheral arteries  
*Ege F, Kazci Ö, Aydin S*

**SYSTEMATIC REVIEWS**

- 5252 COVID-19-induced gastrointestinal autonomic dysfunction: A systematic review  
*Elbeltagi R, Al-Beltagi M, Saeed NK, Bediwy AS*

**META-ANALYSIS**

- 5273 Meta-analysis of outcomes from drug-eluting stent implantation in infrapopliteal arteries  
*Li MX, Tu HX, Yin MC*

**CASE REPORT**

- 5288 Acute hepatitis of unknown etiology in an adult female: A case report  
*Dass L, Pacia AMM, Hamidi M*

- 5296** Zimberelimab plus chemotherapy as the first-line treatment of malignant peritoneal mesothelioma: A case report and review of literature  
*Peng XD, You ZY, He LX, Deng Q*
- 5303** Recurrent ventricular arrhythmia due to aconite intoxication successfully treated with landiolol: A case report  
*Matsuo C, Yamamoto K, Fukushima H, Yajima D, Inoue H*
- 5309** Anti-phospholipase A2 receptor-associated membranous nephropathy with human immunodeficiency virus infection treated with telitacicept: A case report  
*Wang JL, Sun YL, Kang Z, Zhang SK, Yu CX, Zhang W, Xie H, Lin HL*
- 5316** Rapid progression of heart failure secondary to radioactive iodine treatment of hyperthyroidism: A case report  
*Li ZH, Ni LJ, Liu YQ, Si DY*
- 5322** Pathological complete response to neoadjuvant alectinib in unresectable anaplastic lymphoma kinase positive non-small cell lung cancer: A case report  
*Wang LM, Zhao P, Sun XQ, Yan F, Guo Q*
- 5329** Hepatoid adenocarcinoma of the stomach with neuroendocrine differentiation: A case report and review of literature  
*Fei H, Li ZF, Chen YT, Zhao DB*
- 5338** Acquired haemophilia as a complicating factor in treatment of non-muscle invasive bladder cancer: A case report  
*Ryšánková K, Gumulec J, Grepl M, Krhut J*
- 5344** Persistent dysexecutive syndrome after pneumococcal meningitis complicated by recurrent ischemic strokes: A case report  
*Abbruzzese L, Martinelli G, Salti G, Basagni B, Damora A, Scarselli C, Peppoloni G, Podgorska A, Rosso G, Bacci M, Alfano AR, MANCUSO M*
- 5351** Treatment of refractory anti-melanoma differentiation-associated gene 5 antibody-positive dermatomyositis complicated by rapidly progressing interstitial pulmonary disease: Two case reports  
*Wang QH, Chen LH*
- 5358** TINAVI robot-assisted one-stage anteroposterior surgery in lateral position for severe thoracolumbar fracture dislocation: A case report  
*Ye S, Chen YZ, Zhong LJ, Yu CZ, Zhang HK, Hong Y*
- 5365** Individual with concurrent chest wall tuberculosis and triple-negative essential thrombocythemia: A case report  
*Xu XY, Yang YB, Yuan J, Zhang XX, Kang L, Ma XS, Yang J*
- 5373** Self-strangulation induced penile partial amputation: A case report  
*Maimaitiming ABLT, Mulati YLSD, Apizi ART, Li XD*
- 5382** Long-term rare giant sialolithiasis for 30 years: A case report and review of literature  
*Mao JS, Lee YC, Chi JCY, Yi WL, Tsou YA, Lin CD, Tai CJ, Shih LC*

- 5391** Kawasaki disease with peritonsillar abscess as the first symptom: A case report  
*Huo LM, Li LM, Peng HY, Wang LJ, Feng ZY*
- 5398** Treatment of a patient with severe lactic acidosis and multiple organ failure due to mitochondrial myopathy: A case report  
*Chen L, Shuai TK, Gao YW, Li M, Fang PZ, Christian W, Liu LP*
- 5407** Early esophageal carcinomas in achalasia patient after endoscopic submucosal dissection combined with peroral endoscopic myotomy: A case report  
*An BQ, Wang CX, Zhang HY, Fu JD*

**LETTER TO THE EDITOR**

- 5412** Caution in the use of sedation and endomyocardial biopsy for the management of pediatric acute heart failure caused by endocardial fibroelastosis  
*Xin XX, Se YY*



**ABOUT COVER**

Editorial Board Member of *World Journal of Clinical Cases*, Etienne Andrade Munhoz, PhD, Associate Professor, Department of Dentistry, Health Science Centre, Federal University of Santa Catarina, Florianopolis 88040-379, Brazil. etiamfob@yahoo.com

**AIMS AND SCOPE**

The primary aim of *World Journal of Clinical Cases* (WJCC, *World J Clin Cases*) is to provide scholars and readers from various fields of clinical medicine with a platform to publish high-quality clinical research articles and communicate their research findings online.

WJCC mainly publishes articles reporting research results and findings obtained in the field of clinical medicine and covering a wide range of topics, including case control studies, retrospective cohort studies, retrospective studies, clinical trials studies, observational studies, prospective studies, randomized controlled trials, randomized clinical trials, systematic reviews, meta-analysis, and case reports.

**INDEXING/ABSTRACTING**

The WJCC is now abstracted and indexed in Science Citation Index Expanded (SCIE, also known as SciSearch®), Journal Citation Reports/Science Edition, Current Contents®/Clinical Medicine, PubMed, PubMed Central, Reference Citation Analysis, China National Knowledge Infrastructure, China Science and Technology Journal Database, and Superstar Journals Database. The 2023 Edition of Journal Citation Reports® cites the 2022 impact factor (IF) for WJCC as 1.1; IF without journal self cites: 1.1; 5-year IF: 1.3; Journal Citation Indicator: 0.26; Ranking: 133 among 167 journals in medicine, general and internal; and Quartile category: Q4.

**RESPONSIBLE EDITORS FOR THIS ISSUE**

Production Editor: Si Zhao; Production Department Director: Xu Guo; Editorial Office Director: Jin-Lei Wang.

**NAME OF JOURNAL**

*World Journal of Clinical Cases*

**ISSN**

ISSN 2307-8960 (online)

**LAUNCH DATE**

April 16, 2013

**FREQUENCY**

Thrice Monthly

**EDITORS-IN-CHIEF**

Bao-Gan Peng, Jerzy Tadeusz Chudek, George Kontogeorgos, Maurizio Serati, Ja Hyeon Ku

**EDITORIAL BOARD MEMBERS**

<https://www.wjgnet.com/2307-8960/editorialboard.htm>

**PUBLICATION DATE**

August 6, 2023

**COPYRIGHT**

© 2023 Baishideng Publishing Group Inc

**INSTRUCTIONS TO AUTHORS**

<https://www.wjgnet.com/bpg/gerinfo/204>

**GUIDELINES FOR ETHICS DOCUMENTS**

<https://www.wjgnet.com/bpg/GerInfo/287>

**GUIDELINES FOR NON-NATIVE SPEAKERS OF ENGLISH**

<https://www.wjgnet.com/bpg/gerinfo/240>

**PUBLICATION ETHICS**

<https://www.wjgnet.com/bpg/GerInfo/288>

**PUBLICATION MISCONDUCT**

<https://www.wjgnet.com/bpg/gerinfo/208>

**ARTICLE PROCESSING CHARGE**

<https://www.wjgnet.com/bpg/gerinfo/242>

**STEPS FOR SUBMITTING MANUSCRIPTS**

<https://www.wjgnet.com/bpg/GerInfo/239>

**ONLINE SUBMISSION**

<https://www.f6publishing.com>



# Zimberelimab plus chemotherapy as the first-line treatment of malignant peritoneal mesothelioma: A case report and review of literature

Xiao-Dong Peng, Zhen-Yu You, Lian-Xiang He, Qi Deng

**Specialty type:** Medicine, research and experimental

**Provenance and peer review:** Unsolicited article; Externally peer reviewed.

**Peer-review model:** Single blind

**Peer-review report's scientific quality classification**

Grade A (Excellent): A  
Grade B (Very good): 0  
Grade C (Good): C, C  
Grade D (Fair): D  
Grade E (Poor): 0

**P-Reviewer:** Imai Y, Japan; Konala VM, United States; Rajer M, Slovenia

**Received:** March 1, 2023

**Peer-review started:** March 1, 2023

**First decision:** May 25, 2023

**Revised:** June 21, 2023

**Accepted:** July 11, 2023

**Article in press:** July 11, 2023

**Published online:** August 6, 2023



**Xiao-Dong Peng, Zhen-Yu You,** Department of Cancer, The First Affiliated Hospital of Nanchang University, Nanchang 330006, Jiangxi Province, China

**Lian-Xiang He, Qi Deng,** Department of Medical Affairs, Guangzhou Gloria Bioscience Co.,Ltd., Beijing 100005, China

**Corresponding author:** Xiao-Dong Peng, MD, Chief Physician, Department of Cancer, The First Affiliated Hospital of Nanchang University, No. 1519 Dongyue Avenue, Nanchang 330006, Jiangxi Province, China. [pxddhbb@163.com](mailto:pxddhbb@163.com)

## Abstract

### BACKGROUND

Malignant peritoneal mesothelioma (MPeM) is a rare cancer with a poor prognosis at advanced stage, and the standard first-line treatment for inoperable patients is chemotherapy. Although combining programmed cell death 1 (PD-1) inhibitors with chemotherapy is generally considered safe and effective in several malignant solid tumors, there are few reports regarding initial immunochemotherapy in advanced MPeM.

### CASE SUMMARY

Here, to our knowledge, we present the first case of a patient with epithelioid subtype MPeM, who was treatment-naïve and benefited from initial PD-1 inhibitor plus standard chemotherapy with a prolonged progression-free survival (PFS) and good tolerance. A 49-year-old man was admitted to our hospital for a persistent burning sensation in the abdomen. Computed tomography revealed a solid mass in the lower abdomen, which was subsequently diagnosed histologically as epithelioid subtype MPeM by core needle biopsy. The patient received eight cycles of pemetrexed 800 mg (day 1), cisplatin 60/50 mg (day 1-2), and zimberelimab (PD-1 inhibitor) 240 mg (day 1) every 3 wk. He achieved significant reduction of peritoneal tumors with remarkable improvement in symptoms. The best tumor response was partial remission with a final PFS of 7 mo. No immune-related adverse event occurred during the combination treatment.

### CONCLUSION

The outcome of the present case demonstrates the promising anti-tumor activity of immunochemotherapy to treat inoperable MPeM in the future.

**Key Words:** Malignant peritoneal mesothelioma; Immune checkpoint inhibitors; Immunotherapy; Zimberelimab; Chemotherapy; Case report

©The Author(s) 2023. Published by Baishideng Publishing Group Inc. All rights reserved.

**Core Tip:** Malignant peritoneal mesothelioma (MPeM) is a rare cancer with a poor prognosis at advanced stage. Here, we present the first case of a patient with epithelioid subtype MPeM, who was treatment-naïve and benefited from initial programmed cell death 1 inhibitor plus standard chemotherapy with a prolonged progression-free survival and good tolerance. We would like to share our experience with immunochemotherapy, which will help clinicians make appropriate decisions in the future.

**Citation:** Peng XD, You ZY, He LX, Deng Q. Zimberelimab plus chemotherapy as the first-line treatment of malignant peritoneal mesothelioma: A case report and review of literature. *World J Clin Cases* 2023; 11(22): 5296-5302

**URL:** <https://www.wjgnet.com/2307-8960/full/v11/i22/5296.htm>

**DOI:** <https://dx.doi.org/10.12998/wjcc.v11.i22.5296>

## INTRODUCTION

Malignant peritoneal mesothelioma (MPeM) is a lethal and highly aggressive tumor that originates from peritoneal mesothelial cells. It has an extremely low incidence rate of approximately 0.13 cases per 100000 individuals and accounts for 15%–20% of malignant mesotheliomas[1,2]. MPeM is histologically classified into three subtypes: Epithelioid, biphasic, and sarcomatoid. The epithelioid subtype constitutes 70%–80% of all MPeM cases and is associated with less aggressive biological behavior than the others[3]. Typical symptoms of MPeM include abdominal discomfort, distention, and ascites[4]. However, the symptoms are nonspecific, leading to most patients being diagnosed at an advanced stage that is unsuitable for surgery. The median overall survival (OS) for untreated MPeM patients is reportedly < 12 mo[5].

Currently, cytoreductive surgery (CRS) with hyperthermic intraperitoneal chemotherapy (HIPEC) remains the primary standard therapy for operable MPeM. However, combination chemotherapy is the preferred treatment strategy for inoperable disease, with an approximate objective response rate (ORR) of 38% and a poor median OS of 15.4 mo[6]. Therefore, innovative approaches are urgently needed for the treatment of inoperable MPeM to improve tumor response and survival outcomes.

Malignant pleural mesothelioma (MPM) and MPeM have the same pathological origin. In recent years, several encouraging reports have shown that MPM shows great tumor response to immune checkpoint inhibitors (ICIs)[7–10]. However, thus far, few clinical studies have focused on the efficacy and safety of the first-line ICI therapy in advanced MPeM regardless of monotherapy or immunochemotherapy. We herein report a case of 49-year-old man with MPeM who was treated with cisplatin, pemetrexed, and zimberelimab [a novel, fully humanized anti-programmed cell death 1 (PD-1) antibody granted firstly in China]; he achieved progression-free survival (PFS) of 7 mo with good tolerance.

## CASE PRESENTATION

### Chief complaints

A 49-year-old man was referred to our hospital in December 2021 with an abdominal mass that had persisted for over three weeks.

### History of present illness

The patient initially presented with a burning sensation in the abdomen and a sudden weight loss of 10 kg between November and December 2021. The abdominal mass was observed by imaging scan, and thus, he was referred to our hospital for diagnosis and treatment as the severity of his clinical symptoms progressively increased during the course of the illness.

### History of past illness

He had a history of untreated hepatitis B for more than 30 years.

### Personal and family history

He had no previous personal or family history.

### Physical examination

The Eastern Cooperative Oncology Group-performance status score was 0, and his vital signs remained stable. Except his

symptoms, no remarkable signs were observed.

### Laboratory examinations

Immunohistochemical analysis revealed that the cells were positive for calretinin (Figure 1), Wilm's tumor gene 1, D2-40, and cytokeratin 5/6, weakly positive for desmin, and negative for SMA, Dog-1, Bcl-2, HMB45, Melan-A, and CD99.

### Imaging examinations

Abdominal computed tomography (CT) revealed a solid mass in the abdomen (8.9 cm × 5.2 cm) with multiple lesions in the omentum and abdominal cavity, as well as a cystic mass in the lower abdomen (Figure 2A).

## FINAL DIAGNOSIS

The patient was pathologically diagnosed as stage III MPeM (cT3N0M1) by core needle biopsy[11].

## TREATMENT

As the disease was in advanced stages and thus ineligible for CRS, with the consent and decision of the patient and his family, he was given pemetrexed 800 mg (day 1), cisplatin 60 mg (day 1–2), and zimberelimab 240 mg (day 1), every 3 wk for four cycles from January to March 2022. However, due to the moderate increase in serum creatinine to 116.6 μmol/L (normal range in male: 53–106 μmol/L) caused by the chemotherapeutic agents, cisplatin was reduced to 50 mg fifth cycle onward. Subsequently, the patient received three additional cycles of this combination regimen.

## OUTCOME AND FOLLOW-UP

In April 2022, after five treatment cycles, the maximum lesion had shrunk remarkably from 8.9 cm × 5.2 cm to 4.1 cm × 4.0 cm (Figure 2B), and the levels of CA125, which is a tumor marker for MPeM, decreased from 64.1 U/mL to 15.1 U/mL over this period. According to Immune-based Response Evaluation Criteria in Solid Tumors, the efficacy was evaluated as partial response. However, in July 2022, CT imaging showed that the target lesion had increased from 4.1 cm × 4.0 cm to 4.4 cm × 4.0 cm (Figure 2C), and a new irregular solid mass was observed in the pelvic vesicorectal fossa area, suggesting progressive disease (Figure 2D). At his last follow-up in September 2022, he was finally identified as having progressive disease with a PFS of 7 mo. Consequently, he discontinued the combination regimens and was transferred to a local hospital where he was subsequently lost to follow-up. He did not experience any significant immune-related adverse event.

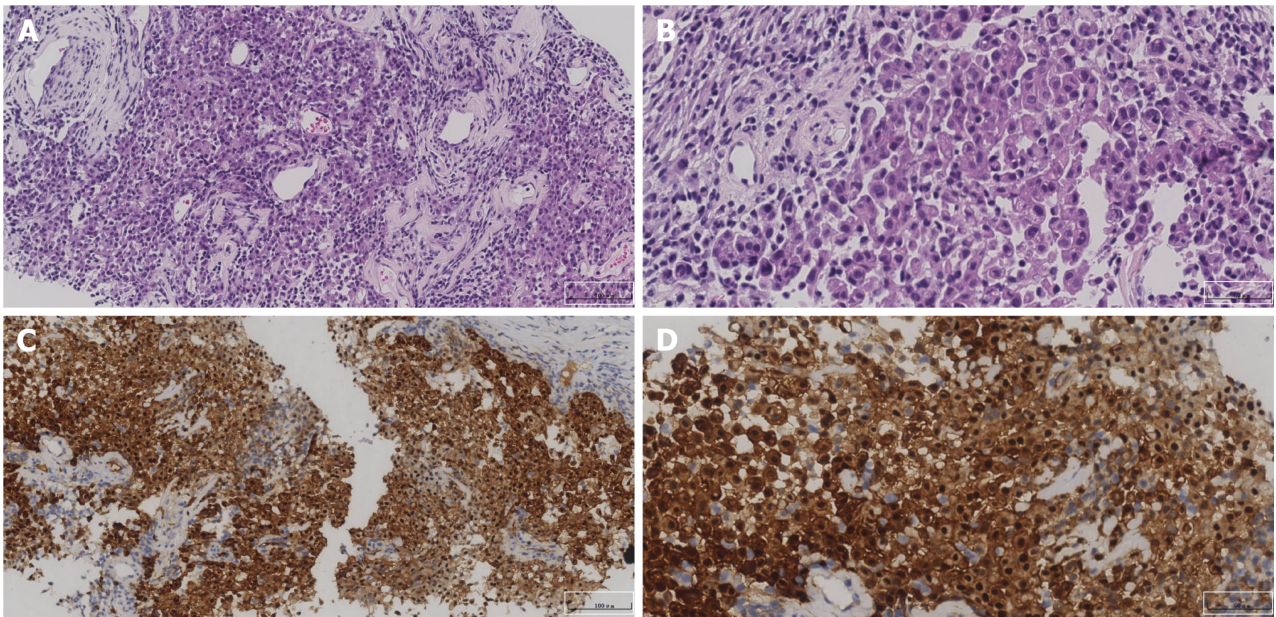
## DISCUSSION

While the cancer is still in an operable stage, CRS and HIPEC have been extensively studied and recommended as the cornerstone of therapeutic strategy for MPeM because of their acceptable long-term survival rates[1]. However, for patients who are ineligible for or unwilling to undergo surgery, cisplatin plus pemetrexed has remained the standard first-line treatment for almost two decades in MPM; according to a phase III study, it offers a limited median PFS and OS of 5.7 mo and 13.2 mo, respectively[12]. Owing to the similarity between MPM and MPeM, cisplatin plus pemetrexed is also recommended as the standard therapy for MPeM according to the current guidelines[13]. Therefore, novel therapies are urgently needed for the treatment of MPeM.

In recent years, PD-1/PD-L1 inhibitors have emerged as a prominent avenue in tumor treatment and have been used in the treatment of various malignancies. Multiple PD-1/L1 and cytotoxic T lymphocyte antigen 4 (CTLA-4) inhibitors have shown good clinical efficacy and safety in several studies, providing promising treatment options for MPM patients[14]. However, there is currently limited evidence regarding the clinical value of PD-1/L1 inhibitors in MPeM.

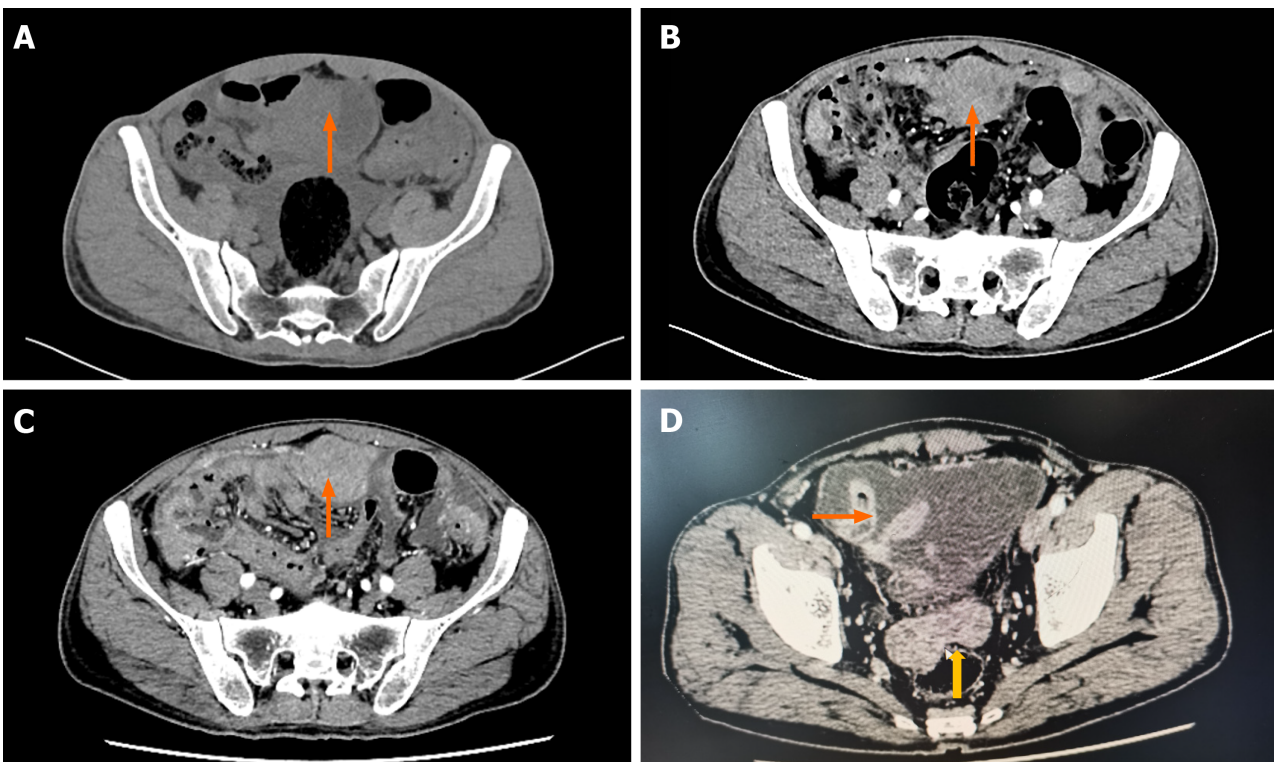
NIBIT-MESO-1 was the first study to demonstrate encouraging efficacy of PD-1/L1 inhibitors in patients with unresectable malignant pleural or peritoneal mesothelioma who received combination immunotherapy with tremelimumab (a CTLA-4 inhibitor) and durvalumab (a PD-L1 inhibitor). Among the 40 patients enrolled, 28% (11/40) achieved an immune-related objective response, but only two were MPeM patients[15]. The PROMISE-meso trial was the first randomized controlled study to evaluate the efficacy of anti-PD-1 therapy in pre-treated patients with relapsed MPM. In this multicenter phase III study, 144 patients were randomly assigned (ratio 1:1) to receive either pembrolizumab or single-agent chemotherapy. The objective response rates were 22% and 6%, respectively[16]. After the PROMISE-meso study, CONFIRM is the first multicenter, placebo-controlled, double-blind, randomized phase III clinical trial to evaluate the efficacy of the PD-1 inhibitor nivolumab in patients with either pleural or peritoneal mesothelioma that had progressed after platinum-based chemotherapy. A total of 332 participants (only 16 MPeM patients) were enrolled; the mPFS was 3.0 mo (95%CI: 2.8–4.1 mo) and 1.8 mo (95%CI: 1.4–2.6 mo) in the nivolumab group (*n* = 221) and the placebo group (*n* = 111), respectively; meanwhile, the mOS was 10.2 mo (95%CI: 8.5–12.1 mo) and 6.9 mo (95%CI: 5.0–





DOI: 10.12998/wjcc.v11.i22.5296 Copyright ©The Author(s) 2023.

**Figure 1** Pathological diagnosis of malignant peritoneal mesothelioma. A and B: Hematoxylin-eosin staining (A:  $\times 200$ , B:  $\times 400$ ); C and D: Immunohistochemistry: Calretinin (C:  $\times 200$ , D:  $\times 400$ ).



DOI: 10.12998/wjcc.v11.i22.5296 Copyright ©The Author(s) 2023.

**Figure 2** Abdominal computed tomography scans of the patient. A: A solid mass in the abdomen (8.9 cm  $\times$  5.2 cm) in December 2021; B: The targeted lesion shrank from 8.9 cm  $\times$  5.2 cm to 4.1 cm  $\times$  4.0 cm after five cycles of treatment in April 2022, thus achieving partial response; C: The targeted lesion was enlarged from 4.1 cm  $\times$  4.0 cm to 4.4 cm  $\times$  4.0 cm in July 2022; D: The targeted lesion (4.4 cm  $\times$  4.0 cm) and a new irregular solid mass in the pelvic vesicorectal fossa area were observed in July 2022, and this was evaluated as progressive disease. The orange arrow indicates the primary lesion, whereas the yellow arrow points to the new one.

8.0 mo), respectively. The results showed that nivolumab was superior to the placebo in terms of both mPFS and mOS[9]. A phase II trial, which investigated the effect of atezolizumab (a PD-L1 inhibitor) in 20 advanced MPeM patients previously treated with platinum–pemetrexed chemotherapy, showed promising anti-tumor activity against MPeM, with an ORR of 40%, 1-year PFS rate of 61%, and 1-year OS rate of 85% [4]. The JAVELIN study was a single-arm prospective

clinical trial that evaluated the efficacy and toxicity profile of avelumab (a PD-L1 inhibitor) in 53 patients with predominantly pleural and peritoneal mesothelioma[17], and it reported a low ORR of approximately 10%. CheckMate 743 was a phase III clinical trial that compared the efficacy and safety of nivolumab + ipilimumab and chemotherapy as the first-line treatment for unresectable MPeM. The reported mOS was 18.1 and 14.1 mo, respectively, and the 3-year OS rates were 23% and 15%, respectively, supporting that the combination of immunotherapy had superior outcomes. Additionally, clinical benefit with nivolumab + ipilimumab was also observed across all subgroups regardless of PD-L1 expression and its clinical efficacy was particularly favorable in epithelioid subtype MPeM[18].

Cerbone *et al*[19] reported a case of a heavily treated patient with MPM who underwent multiple anticancer treatments, including chemotherapy and ICIs, and achieved a PFS of > 26 mo after the administration of nivolumab[19]. Furthermore, several clinical trials have explored the safety and efficacy of immunotherapies targeting the PD-1 or PD-L1 pathway as first-line or subsequent treatments for patients with MPM[10,16,20-23]. Although these studies only provided preliminary results, the ORR ranged from 10%–30%. This suggests that a small subset of patients may benefit from PD-1/PD-L1 monotherapy, and more effective combination therapies should be explored to improve antitumor efficacy. Notably, some studies showed that PD-L1 expression is not significantly associated with ORR[24,25].

Thus far, few prospective clinical studies have investigated the efficacy of ICIs in combination with chemotherapy for advanced MPeM. Durvalumab, an anti-PD-L1 antibody, in combination with cisplatin and pemetrexed has demonstrated sufficient efficacy, safety, and tolerability in two phase II studies for the first-line treatment of unresectable MPM[26,27]. Additionally, several case reports have upheld the efficacy of this combination therapy. Foote *et al*[28] reported on two patients who received pembrolizumab in addition to platinum and pemetrexed treatment, and both achieved a durable partial response. Notably, neither of the two patients had established biomarkers for ICI therapy, such as tumor mutational burden and PD-L1 expression[28]. Huang *et al*[29] also reported a similar case with a short survival duration of 2 mo[29]. Thus, we hypothesize that ICIs and chemotherapy have synergistic activities in MPeM, and initial immunochemotherapy may be feasible as an optional first-line regimen. Notably, PD-L1 expression is observed in nearly 50% of MPeM patients but only in 30% of MPM patients[30].

Zimberelimab is a novel, fully humanized anti-PD-1 monoclonal immunoglobulin G4 developed from the OmniRat transgenic platform[31-34]. Compared with another PD-1 inhibitor (pembrolizumab, not a head-to-head comparison) in a phase II study, zimberelimab achieved a higher ORR in relapsed/refractory classical Hodgkin lymphoma[35,36]. We attempted to adopt platinum-based chemotherapy + zimberelimab for our relatively younger patient. The present case finally achieved rapid tumor response and an acceptable PFS of 7 mo.

To our knowledge, this is the first report of initial immunochemotherapy with a PD-1 inhibitor and chemotherapy being used as the first-line regimen for MPeM, and it achieved a favorable PFS. However, a limitation of this case is that PD-L1 expression was not tested because it is not a routine recommendation according to current guidelines.

## CONCLUSION

In the present case of inoperable MPeM, initial combination therapy with a PD-1 inhibitor and chemotherapy achieved anti-tumor activity, which can be considered for personalized therapy of such a rare cancer. We also recommend that a well-designed prospective clinical trial could be conducted to explore the potential benefit of immunochemotherapy as a new first-line treatment option for MPeM.

## FOOTNOTES

**Author contributions:** Deng Q is responsible for writing the manuscript; He LX revised this manuscript; Peng XD and You ZY provided idea and case, and reviewed the manuscript; all authors have read and approve the final manuscript.

**Informed consent statement:** The patient provided a written informed consent form.

**Conflict-of-interest statement:** The authors declare that they have no conflict of interest to disclose.

**CARE Checklist (2016) statement:** The authors have read the CARE Checklist (2016), and the manuscript was prepared and revised according to the CARE Checklist (2016).

**Open-Access:** This article is an open-access article that was selected by an in-house editor and fully peer-reviewed by external reviewers. It is distributed in accordance with the Creative Commons Attribution NonCommercial (CC BY-NC 4.0) license, which permits others to distribute, remix, adapt, build upon this work non-commercially, and license their derivative works on different terms, provided the original work is properly cited and the use is non-commercial. See: <https://creativecommons.org/licenses/by-nc/4.0/>

**Country/Territory of origin:** China

**ORCID number:** Xiao-Dong Peng 0000-0002-8441-0490; Qi Deng 0000-0002-1591-9162.

**S-Editor:** Fan JR

**L-Editor:** A



## REFERENCES

- 1 Broeekx G, Pauwels P. Malignant peritoneal mesothelioma: a review. *Transl Lung Cancer Res* 2018; **7**: 537-542 [PMID: 30450291 DOI: 10.21037/tlcr.2018.10.04]
- 2 DeSantis CE, Kramer JL, Jemal A. The burden of rare cancers in the United States. *CA Cancer J Clin* 2017; **67**: 261-272 [PMID: 28542893 DOI: 10.3322/caac.21400]
- 3 Li CY, Kennedy T, Alexander HR. Treatment of Patients with Malignant Peritoneal Mesothelioma. *J Clin Med* 2022; **11** [PMID: 35407498 DOI: 10.3390/jcm11071891]
- 4 Raghav K, Liu S, Overman MJ, Willett AF, Knafl M, Fu SC, Malpica A, Prasad S, Royal RE, Scally CP, Mansfield PF, Wistuba II, Futreal AP, Maru DM, Solis Soto LM, Parra Cuentas ER, Chen H, Villalobos P, Verma A, Mahvash A, Hwu P, Cortazar P, McKenna E, Yun C, Dervin S, Schulze K, Darbonne WC, Morani AC, Kopetz S, Fournier KF, Woodman SE, Yao JC, Varadhachary GR, Halperin DM. Efficacy, Safety, and Biomarker Analysis of Combined PD-L1 (Atezolizumab) and VEGF (Bevacizumab) Blockade in Advanced Malignant Peritoneal Mesothelioma. *Cancer Discov* 2021; **11**: 2738-2747 [PMID: 34261675 DOI: 10.1158/2159-8290.CD-21-0331]
- 5 Li CY, Alexander HR Jr. Peritoneal Metastases from Malignant Mesothelioma. *Surg Oncol Clin N Am* 2018; **27**: 539-549 [PMID: 29935688 DOI: 10.1016/j.soc.2018.02.010]
- 6 Nagata Y, Sawada R, Takashima A, Shoji H, Honma Y, Iwasa S, Amano K, Kato K, Hamaguchi T, Shimada Y, Saruta M, Boku N. Efficacy and safety of pemetrexed plus cisplatin as first-line chemotherapy in advanced malignant peritoneal mesothelioma. *Jpn J Clin Oncol* 2019; **49**: 1004-1008 [PMID: 31287877 DOI: 10.1093/jcco/hyz104]
- 7 de Gooijer CJ, Borm FJ, Scherpereel A, Baas P. Immunotherapy in Malignant Pleural Mesothelioma. *Front Oncol* 2020; **10**: 187 [PMID: 32154179 DOI: 10.3389/fonc.2020.00187]
- 8 Baas P, Scherpereel A, Nowak AK, Fujimoto N, Peters S, Tsao AS, Mansfield AS, Popat S, Jahan T, Antonia S, Oulkhouri Y, Bautista Y, Cornelissen R, Greillier L, Grossi F, Kowalski D, Rodríguez-Cid J, Aanur P, Oukessou A, Baudelet C, Zalcman G. First-line nivolumab plus ipilimumab in unresectable malignant pleural mesothelioma (CheckMate 743): a multicentre, randomised, open-label, phase 3 trial. *Lancet* 2021; **397**: 375-386 [PMID: 33485464 DOI: 10.1016/S0140-6736(20)32714-8]
- 9 Fennell DA, Ewings S, Ottensmeier C, Califano R, Hanna GG, Hill K, Danson S, Steele N, Nye M, Johnson L, Lord J, Middleton C, Szlosarek P, Chan S, Gaba A, Darlison L, Wells-Jordan P, Richards C, Poile C, Lester JF, Griffiths G; CONFIRM trial investigators. Nivolumab versus placebo in patients with relapsed malignant mesothelioma (CONFIRM): a multicentre, double-blind, randomised, phase 3 trial. *Lancet Oncol* 2021; **22**: 1530-1540 [PMID: 34656227 DOI: 10.1016/S1470-2045(21)00471-X]
- 10 Alley EW, Lopez J, Santoro A, Morosky A, Saraf S, Piperdi B, van Brummelen E. Clinical safety and activity of pembrolizumab in patients with malignant pleural mesothelioma (KEYNOTE-028): preliminary results from a non-randomised, open-label, phase 1b trial. *Lancet Oncol* 2017; **18**: 623-630 [PMID: 28291584 DOI: 10.1016/S1470-2045(17)30169-9]
- 11 Yan TD, Deraco M, Elias D, Glehen O, Levine EA, Moran BJ, Morris DL, Chua TC, Piso P, Sugarbaker PH; Peritoneal Surface Oncology Group. A novel tumor-node-metastasis (TNM) staging system of diffuse malignant peritoneal mesothelioma using outcome analysis of a multi-institutional database\*. *Cancer* 2011; **117**: 1855-1863 [PMID: 21509762 DOI: 10.1002/cncr.25640]
- 12 Vogelzang NJ, Rusthoven JJ, Symanowski J, Denham C, Kaukel E, Ruffie P, Gatzemeier U, Boyer M, Emri S, Manegold C, Niyikiza C, Paoletti P. Phase III Study of Pemetrexed in Combination With Cisplatin Versus Cisplatin Alone in Patients With Malignant Pleural Mesothelioma. *J Clin Oncol* 2023; **41**: 2125-2133 [PMID: 37068377 DOI: 10.1200/JCO.22.02542]
- 13 Chun CP, Song LX, Zhang HP, Guo DD, Xu GX, Li Y, Xin X, Cao J, Li F. Malignant peritoneal mesothelioma. *Am J Med Sci* 2023; **365**: 99-103 [PMID: 35940275 DOI: 10.1016/j.amjms.2022.07.008]
- 14 Metro G, Signorelli D, Pizzutillo EG, Giannetta L, Cerea G, Garaffa M, Friedlaender A, Addeo A, Mandarano M, Bellezza G, Roila F. Immune checkpoint inhibitors for unresectable malignant pleural mesothelioma. *Hum Vaccin Immunother* 2021; **17**: 2972-2980 [PMID: 34003722 DOI: 10.1080/21645515.2021.1917933]
- 15 Calabrò L, Morra A, Giannarelli D, Amato G, D'Incecco A, Covre A, Lewis A, Rebelatto MC, Danielli R, Altomonte M, Di Giacomo AM, Maio M. Tremelimumab combined with durvalumab in patients with mesothelioma (NIBIT-MESO-1): an open-label, non-randomised, phase 2 study. *Lancet Respir Med* 2018; **6**: 451-460 [PMID: 29773326 DOI: 10.1016/S2213-2600(18)30151-6]
- 16 Popat S, Curioni-Fontecedro A, Dafni U, Shah R, O'Brien M, Pope A, Fisher P, Spicer J, Roy A, Gilligan D, Gautschi O, Nadal E, Janthur WD, López Castro R, García Campelo R, Rusakiewicz S, Letovanec I, Polydoropoulou V, Roschitzki-Voser H, Ruepp B, Gasca-Ruchti A, Peters S, Stahel RA. A multicentre randomised phase III trial comparing pembrolizumab versus single-agent chemotherapy for advanced pre-treated malignant pleural mesothelioma: the European Thoracic Oncology Platform (ETOP 9-15) PROMISE-meso trial. *Ann Oncol* 2020; **31**: 1734-1745 [PMID: 32976938 DOI: 10.1016/j.annonc.2020.09.009]
- 17 Hassan R, Thomas A, Nemunaitis JJ, Patel MR, Bennouna J, Chen FL, Delord JP, Dowlati A, Kochuparambil ST, Taylor MH, Powderly JD, Vaishampayan UN, Verschraegen C, Grote HJ, von Heydebreck A, Chin K, Gulley JL. Efficacy and Safety of Avelumab Treatment in Patients With Advanced Unresectable Mesothelioma: Phase 1b Results From the JAVELIN Solid Tumor Trial. *JAMA Oncol* 2019; **5**: 351-357 [PMID: 30605211 DOI: 10.1001/jamaoncol.2018.5428]
- 18 Peters S, Scherpereel A, Cornelissen R, Oulkhouri Y, Greillier L, Kaplan MA, Talbot T, Monnet I, Hirt S, Baas P, Nowak AK, Fujimoto N, Tsao AS, Mansfield AS, Popat S, Zhang X, Hu N, Balli D, Spires T, Zalcman G. First-line nivolumab plus ipilimumab versus chemotherapy in patients with unresectable malignant pleural mesothelioma: 3-year outcomes from CheckMate 743. *Ann Oncol* 2022; **33**: 488-499 [PMID: 35124183 DOI: 10.1016/j.annonc.2022.01.074]
- 19 Cerbone L, Delfanti S, De Angelis AM, Crivellari S, Boccuzzi F, Cimorelli A, Bertolotti M, Righi L, Bertino P, Grosso F. Unprecedented long-term survival in a patient with malignant pleural mesothelioma treated with subsequent systemic chemo- and immunotherapeutic regimens. *Thorac Cancer* 2023; **14**: 524-527 [PMID: 36599413 DOI: 10.1111/1759-7714.14789]
- 20 Okada M, Kijima T, Aoe K, Kato T, Fujimoto N, Nakagawa K, Takeda Y, Hida T, Kanai K, Imamura F, Oizumi S, Takahashi T, Takenoyama M, Tanaka H, Hirano J, Namba Y, Ohe Y. Clinical Efficacy and Safety of Nivolumab: Results of a Multicenter, Open-label, Single-arm, Japanese Phase II study in Malignant Pleural Mesothelioma (MERIT). *Clin Cancer Res* 2019; **25**: 5485-5492 [PMID: 31164373 DOI: 10.1158/1078-0432.CCR.18.2548]

- 10.1158/1078-0432.CCR-19-0103]
- 21 **Fennell DA.** Programmed Death 1 Blockade With Nivolumab in Patients With Recurrent Malignant Pleural Mesothelioma. *J Thorac Oncol* 2018; **13**: 1436-1437 [PMID: 30244849 DOI: 10.1016/j.jtho.2018.07.007]
- 22 **Metaxas Y,** Rivalland G, Mauti LA, Klingbiel D, Kao S, Schmid S, Nowak AK, Gautschi O, Bartnick T, Hughes BG, Bouchaab H, Rothschild SI, Pavlakis N, Wolleb S, Petrasch U, O'Byrne K, Froesch P, Löffler-Baumann M, Pratsch-Peter S, Russell P, Mingrone W, Savic S, Thapa B, Früh M, Pless M, von Moos R, John T. Pembrolizumab as Palliative Immunotherapy in Malignant Pleural Mesothelioma. *J Thorac Oncol* 2018; **13**: 1784-1791 [PMID: 30142389 DOI: 10.1016/j.jtho.2018.08.007]
- 23 **Scherpereel A,** Mazieres J, Greillier L, Lantuejoul S, Dô P, Bylicki O, Monnet I, Corre R, Audigier-Valette C, Locatelli-Sanchez M, Molinier O, Guisier F, Urban T, Ligeza-Poisson C, Planchard D, Amour E, Morin F, Moro-Sibilot D, Zalcman G; French Cooperative Thoracic Intergroup. Nivolumab or nivolumab plus ipilimumab in patients with relapsed malignant pleural mesothelioma (IFCT-1501 MAPS2): a multicentre, open-label, randomised, non-comparative, phase 2 trial. *Lancet Oncol* 2019; **20**: 239-253 [PMID: 30660609 DOI: 10.1016/S1470-2045(18)30765-4]
- 24 **Ahmadzadeh T,** Cooper WA, Holmes M, Mahar A, Westman H, Gill AJ, Nordman I, Yip PY, Pal A, Zielinski R, Pavlakis N, Nagrial A, Daneshvar D, Brungs D, Karikios D, Aleksova V, Burn J, Asher R, Grau GE, Hosseini-Beheshti E, Reid G, Clarke S, Kao S. Retrospective Evaluation of the Use of Pembrolizumab in Malignant Mesothelioma in a Real-World Australian Population. *JTO Clin Res Rep* 2020; **1**: 100075 [PMID: 34589956 DOI: 10.1016/j.jto.2020.100075]
- 25 **Yap TA,** Nakagawa K, Fujimoto N, Kuribayashi K, Guren TK, Calabrò L, Shapira-Frommer R, Gao B, Kao S, Matos I, Planchard D, Chatterjee A, Jin F, Norwood K, Kindler HL. Efficacy and safety of pembrolizumab in patients with advanced mesothelioma in the open-label, single-arm, phase 2 KEYNOTE-158 study. *Lancet Respir Med* 2021; **9**: 613-621 [PMID: 33836153 DOI: 10.1016/S2213-2600(20)30515-4]
- 26 **Nowak A,** Kok P, Lesterhuis W, Hughes B, Brown C, Kao S, Karikios D, John T, Pavlakis N, O'Byrne K, Yip S, Lam W, Briscoe K, Karapetis C, Stockler M. OA08.02 DREAM - A Phase 2 Trial of Durvalumab with First Line Chemotherapy in Mesothelioma: Final Result. *J Thorac Oncol* 2018; **13**: S338-S339 [DOI: 10.1016/j.jtho.2018.08.276]
- 27 **Forde PM,** Sun Z, Anagnostou V, Kindler HL, Purcell WT, Goulart BHL, Dudek AZ, Borghaei H, Brahmer JR, Ramalingam SS. PrE0505: Phase II multicenter study of anti-PD-L1, durvalumab, in combination with cisplatin and pemetrexed for the first-line treatment of unresectable malignant pleural mesothelioma (MPM)—A PrECOG LLC study. *J Clin Oncol* 2020; **38**: 9003-9003 [DOI: 10.1200/jco.2020.38.15\_suppl.9003]
- 28 **Footo MB,** Shia J, Zauderer MG, Nash GM, Cercek A. Treatment of Platinum Nonresponsive Metastatic Malignant Peritoneal Mesothelioma With Combination Chemoimmunotherapy. *J Immunother* 2022; **45**: 100-103 [PMID: 34723916 DOI: 10.1097/CJI.0000000000000399]
- 29 **Huang X,** Hong Y, Xie SY, Liao HL, Huang HM, Liu JH, Long WJ. Malignant peritoneal mesothelioma with massive ascites as the first symptom: A case report. *World J Clin Cases* 2022; **10**: 10317-10325 [PMID: 36246798 DOI: 10.12998/wjcc.v10.i28.10317]
- 30 **Chapel DB,** Stewart R, Furtado LV, Husain AN, Krausz T, Deftereos G. Tumor PD-L1 expression in malignant pleural and peritoneal mesothelioma by Dako PD-L1 22C3 pharmDx and Dako PD-L1 28-8 pharmDx assays. *Hum Pathol* 2019; **87**: 11-17 [PMID: 30794891 DOI: 10.1016/j.humpath.2019.02.001]
- 31 **Lin S,** Gong J, Xu Y, Zhang X, Peng Z, Qi C, Li G, Meng H, Liu Z, Wang H, Chen C, Li J, Zheng Y, Lee J, Zhang Y, Zhang Q, Jin G, Yang Y, Zhao G. GLS-010, a novel anti-PD-1 mAb in Chinese advanced gastrointestinal tumor: Result of a phase Ib clinical trial. *J Clin Oncol* 2019; **37**: 125-125 [DOI: 10.1200/jco.2019.37.4\_suppl.125]
- 32 **Shen L,** Gong J, Xu Y, Zhang X, Peng Z, Qi C, Li G, Meng H, Liu Z, Wang H, Chen C, Li J, Zheng Y, Lee J, Zhang Y, Zhang Q. 65P - A novel recombinant human anti-PD-1 monoclonal antibody GLS-010 in patients with advanced cancer: Result of a phase Ia clinical trial. *Ann Oncol* 2018; **29**: x22-x23 [DOI: 10.1093/annonc/mdy486.017]
- 33 **Lou B,** Wei H, Yang F, Wang S, Yang B, Zheng Y, Zhu J, Yan S. Preclinical Characterization of GLS-010 (Zimberelimab), a Novel Fully Human Anti-PD-1 Therapeutic Monoclonal Antibody for Cancer. *Front Oncol* 2021; **11**: 736955 [PMID: 34604074 DOI: 10.3389/fonc.2021.736955]
- 34 **Osborn MJ,** Ma B, Avis S, Binnie A, Dilley J, Yang X, Lindquist K, Ménoret S, Isache AL, Ouisse LH, Rajpal A, Anegón I, Neuberger MS, Buelow R, Brüggemann M. High-affinity IgG antibodies develop naturally in Ig-knockout rats carrying germline human IgH/Igκ/Igλ loci bearing the rat CH region. *J Immunol* 2013; **190**: 1481-1490 [PMID: 23303672 DOI: 10.4049/jimmunol.1203041]
- 35 **Lin N,** Zhang M, Bai H, Liu H, Cui J, Ke X, Zhang H, Liu L, Yan D, Jiang Y, Zang A, Qi J, Wang L, Liu Z, Xu B, Zhang Y, Zhang Z, Zhao X, Hu C, Yang S, Zhou H, Shi J, Shao Z, Xiang Y, Zhu J, Song Y. Efficacy and safety of GLS-010 (zimberelimab) in patients with relapsed or refractory classical Hodgkin lymphoma: A multicenter, single-arm, phase II study. *Eur J Cancer* 2022; **164**: 117-126 [PMID: 34462189 DOI: 10.1016/j.ejca.2021.07.021]
- 36 **Pembrolizumab Improves Progression-Free Survival in Relapsed/Refractory Hodgkin Lymphoma.** *Oncologist* 2020; **25** Suppl 1: S18-S19 [PMID: 32588926 DOI: 10.1634/theoncologist.2020-0561]





Published by **Baishideng Publishing Group Inc**  
7041 Koll Center Parkway, Suite 160, Pleasanton, CA 94566, USA

**Telephone:** +1-925-3991568

**E-mail:** [bpgoffice@wjgnet.com](mailto:bpgoffice@wjgnet.com)

**Help Desk:** <https://www.f6publishing.com/helpdesk>

<https://www.wjgnet.com>

