

World Journal of *Clinical Cases*

World J Clin Cases 2023 August 6; 11(22): 5193-5415



Contents

Thrice Monthly Volume 11 Number 22 August 6, 2023

MINIREVIEWS

- 5193 Research progress on reactive oxygen species production mechanisms in tumor sonodynamic therapy
Dong HQ, Fu XF, Wang MY, Zhu J

ORIGINAL ARTICLE

Retrospective Study

- 5204 Combining the age-male-albumin-bilirubin-platelets score and shear wave elastography stratifies carcinogenic risk in hepatitis C patients after viral clearance
Masaoka R, Gytoku Y, Shirahashi R, Suda T, Tamano M
- 5215 Changes in neurotransmitter levels, brain structural characteristics, and their correlation with PANSS scores in patients with first-episode schizophrenia
Xu XJ, Liu TL, He L, Pu B
- 5224 Five-year outcomes of immediate implant placement for mandibular molars with and without chronic apical periodontitis: A retrospective study
Yang H, Luo D, Yuan MJ, Yang JJ, Wang DS

Observational Study

- 5236 Standardization of apple cancellation test for neglect patients in Korea: An observational study
Jang WH, Jang JS

Prospective Study

- 5244 Diabetic neuropathy results in vasomotor dysfunction of medium sized peripheral arteries
Ege F, Kazci Ö, Aydin S

SYSTEMATIC REVIEWS

- 5252 COVID-19-induced gastrointestinal autonomic dysfunction: A systematic review
Elbeltagi R, Al-Beltagi M, Saeed NK, Bediwy AS

META-ANALYSIS

- 5273 Meta-analysis of outcomes from drug-eluting stent implantation in infrapopliteal arteries
Li MX, Tu HX, Yin MC

CASE REPORT

- 5288 Acute hepatitis of unknown etiology in an adult female: A case report
Dass L, Pacia AMM, Hamidi M

- 5296** Zimberelimab plus chemotherapy as the first-line treatment of malignant peritoneal mesothelioma: A case report and review of literature
Peng XD, You ZY, He LX, Deng Q
- 5303** Recurrent ventricular arrhythmia due to aconite intoxication successfully treated with landiolol: A case report
Matsuo C, Yamamoto K, Fukushima H, Yajima D, Inoue H
- 5309** Anti-phospholipase A2 receptor-associated membranous nephropathy with human immunodeficiency virus infection treated with telitacicept: A case report
Wang JL, Sun YL, Kang Z, Zhang SK, Yu CX, Zhang W, Xie H, Lin HL
- 5316** Rapid progression of heart failure secondary to radioactive iodine treatment of hyperthyroidism: A case report
Li ZH, Ni LJ, Liu YQ, Si DY
- 5322** Pathological complete response to neoadjuvant alectinib in unresectable anaplastic lymphoma kinase positive non-small cell lung cancer: A case report
Wang LM, Zhao P, Sun XQ, Yan F, Guo Q
- 5329** Hepatoid adenocarcinoma of the stomach with neuroendocrine differentiation: A case report and review of literature
Fei H, Li ZF, Chen YT, Zhao DB
- 5338** Acquired haemophilia as a complicating factor in treatment of non-muscle invasive bladder cancer: A case report
Ryšánková K, Gumulec J, Grepl M, Krhut J
- 5344** Persistent dysexecutive syndrome after pneumococcal meningitis complicated by recurrent ischemic strokes: A case report
Abbruzzese L, Martinelli G, Salti G, Basagni B, Damora A, Scarselli C, Peppoloni G, Podgorska A, Rosso G, Bacci M, Alfano AR, MANCUSO M
- 5351** Treatment of refractory anti-melanoma differentiation-associated gene 5 antibody-positive dermatomyositis complicated by rapidly progressing interstitial pulmonary disease: Two case reports
Wang QH, Chen LH
- 5358** TINAVI robot-assisted one-stage anteroposterior surgery in lateral position for severe thoracolumbar fracture dislocation: A case report
Ye S, Chen YZ, Zhong LJ, Yu CZ, Zhang HK, Hong Y
- 5365** Individual with concurrent chest wall tuberculosis and triple-negative essential thrombocythemia: A case report
Xu XY, Yang YB, Yuan J, Zhang XX, Kang L, Ma XS, Yang J
- 5373** Self-strangulation induced penile partial amputation: A case report
Maimaitiming ABLT, Mulati YLSD, Apizi ART, Li XD
- 5382** Long-term rare giant sialolithiasis for 30 years: A case report and review of literature
Mao JS, Lee YC, Chi JCY, Yi WL, Tsou YA, Lin CD, Tai CJ, Shih LC

- 5391** Kawasaki disease with peritonsillar abscess as the first symptom: A case report
Huo LM, Li LM, Peng HY, Wang LJ, Feng ZY
- 5398** Treatment of a patient with severe lactic acidosis and multiple organ failure due to mitochondrial myopathy: A case report
Chen L, Shuai TK, Gao YW, Li M, Fang PZ, Christian W, Liu LP
- 5407** Early esophageal carcinomas in achalasia patient after endoscopic submucosal dissection combined with peroral endoscopic myotomy: A case report
An BQ, Wang CX, Zhang HY, Fu JD

LETTER TO THE EDITOR

- 5412** Caution in the use of sedation and endomyocardial biopsy for the management of pediatric acute heart failure caused by endocardial fibroelastosis
Xin XX, Se YY

ABOUT COVER

Editorial Board Member of *World Journal of Clinical Cases*, Etienne Andrade Munhoz, PhD, Associate Professor, Department of Dentistry, Health Science Centre, Federal University of Santa Catarina, Florianopolis 88040-379, Brazil. etiamfob@yahoo.com

AIMS AND SCOPE

The primary aim of *World Journal of Clinical Cases* (WJCC, *World J Clin Cases*) is to provide scholars and readers from various fields of clinical medicine with a platform to publish high-quality clinical research articles and communicate their research findings online.

WJCC mainly publishes articles reporting research results and findings obtained in the field of clinical medicine and covering a wide range of topics, including case control studies, retrospective cohort studies, retrospective studies, clinical trials studies, observational studies, prospective studies, randomized controlled trials, randomized clinical trials, systematic reviews, meta-analysis, and case reports.

INDEXING/ABSTRACTING

The WJCC is now abstracted and indexed in Science Citation Index Expanded (SCIE, also known as SciSearch®), Journal Citation Reports/Science Edition, Current Contents®/Clinical Medicine, PubMed, PubMed Central, Reference Citation Analysis, China National Knowledge Infrastructure, China Science and Technology Journal Database, and Superstar Journals Database. The 2023 Edition of Journal Citation Reports® cites the 2022 impact factor (IF) for WJCC as 1.1; IF without journal self cites: 1.1; 5-year IF: 1.3; Journal Citation Indicator: 0.26; Ranking: 133 among 167 journals in medicine, general and internal; and Quartile category: Q4.

RESPONSIBLE EDITORS FOR THIS ISSUE

Production Editor: Si Zhao; Production Department Director: Xu Guo; Editorial Office Director: Jin-Lei Wang.

NAME OF JOURNAL

World Journal of Clinical Cases

ISSN

ISSN 2307-8960 (online)

LAUNCH DATE

April 16, 2013

FREQUENCY

Thrice Monthly

EDITORS-IN-CHIEF

Bao-Gan Peng, Jerzy Tadeusz Chudek, George Kontogeorgos, Maurizio Serati, Ja Hyeon Ku

EDITORIAL BOARD MEMBERS

<https://www.wjgnet.com/2307-8960/editorialboard.htm>

PUBLICATION DATE

August 6, 2023

COPYRIGHT

© 2023 Baishideng Publishing Group Inc

INSTRUCTIONS TO AUTHORS

<https://www.wjgnet.com/bpg/gerinfo/204>

GUIDELINES FOR ETHICS DOCUMENTS

<https://www.wjgnet.com/bpg/GerInfo/287>

GUIDELINES FOR NON-NATIVE SPEAKERS OF ENGLISH

<https://www.wjgnet.com/bpg/gerinfo/240>

PUBLICATION ETHICS

<https://www.wjgnet.com/bpg/GerInfo/288>

PUBLICATION MISCONDUCT

<https://www.wjgnet.com/bpg/gerinfo/208>

ARTICLE PROCESSING CHARGE

<https://www.wjgnet.com/bpg/gerinfo/242>

STEPS FOR SUBMITTING MANUSCRIPTS

<https://www.wjgnet.com/bpg/GerInfo/239>

ONLINE SUBMISSION

<https://www.f6publishing.com>



Individual with concurrent chest wall tuberculosis and triple-negative essential thrombocythemia: A case report

Xiao-Yan Xu, Yong-Bin Yang, Jun Yuan, Xiao-Xia Zhang, Lin Kang, Xiang-Shu Ma, Jie Yang

Specialty type: Hematology

Provenance and peer review:

Unsolicited article; Externally peer reviewed.

Peer-review model: Single blind

Peer-review report's scientific quality classification

Grade A (Excellent): 0

Grade B (Very good): 0

Grade C (Good): C, C

Grade D (Fair): 0

Grade E (Poor): 0

P-Reviewer: Kalayarsan R, India;
Wani I, India

Received: April 23, 2023

Peer-review started: April 23, 2023

First decision: June 15, 2023

Revised: June 25, 2023

Accepted: July 17, 2023

Article in press: July 17, 2023

Published online: August 6, 2023



Xiao-Yan Xu, Jun Yuan, Xiao-Xia Zhang, Jie Yang, Department of Haematology, Hebei General Hospital, Shijiazhuang 050051, Hebei Province, China

Xiao-Yan Xu, Graduate School, Hebei North University, Zhangjiakou 075000, Hebei Province, China

Yong-Bin Yang, Department of Vascular Surgery, Hebei General Hospital, Shijiazhuang 050051, Hebei Province, China

Lin Kang, Department of Pathology, Hebei General Hospital, Shijiazhuang 050051, Hebei Province, China

Xiang-Shu Ma, Clinical Laboratory, Hebei General Hospital, Shijiazhuang 050051, Hebei Province, China

Corresponding author: Jie Yang, Doctor, Associate Professor, Department of Haematology, Hebei General Hospital, No. 348 Heping West Road, Shijiazhuang 050051, Hebei Province, China. yjyyb313@163.com

Abstract

BACKGROUND

Chest wall tuberculosis (TB) and triple-negative essential thrombocythemia (TN-ET) are rare medical conditions, and their combination is extremely rare globally. Only one case of TB peritonitis with thrombocytosis has been reported, which was identified in 1974.

CASE SUMMARY

Herein, we report the case of a 23-year-old man with concurrent chest wall mass and TN-ET. The patient presented to a local hospital due to having a headache and low-grade fever for 2 d, with their bodily temperature fluctuating at around 36.8 °C. Hematological analysis showed a high platelet count of $1503 \times 10^9/L$. Subsequently, the patient visited our hospital for further investigation. Computed tomography of the chest suggested a submural soft tissue density shadow in the left lower chest wall. After surgical resection, the pathological findings of the swelling were reported as TB with massive caseous necrosis. According to the World Health Organization diagnostic criteria, the patient was diagnosed with TN-ET, as they met the requirement of four main criteria or the first three main criteria and one secondary criterion. The patient was eventually diagnosed with chest wall TB with TN-ET, which is extremely rare.

CONCLUSION

Chest wall TB is rare. TN-ET diagnosis requires secondary factor exclusion and satisfaction of primary diagnostic criteria. miRNA, combined with the methylation process, could explain suppressor of cytokine signaling (SOCS) 1 and SOCS3 downregulation in ET-JAK2V617F-negative patients. The miRNA could participate in JAK2 pathway activation. SOCS3 may be a novel MPN biomarker.

Key Words: Platelet; Thrombocytopenia; Triple-negative; Chest wall tuberculosis; SOCS3 gene; JAK-STAT pathway; Case report

©The Author(s) 2023. Published by Baishideng Publishing Group Inc. All rights reserved.

Core Tip: Essential thrombocythemia (ET) is a myeloproliferative neoplasm (MPN) disorder resulting from genetic mutations in one or more common oncogenes. Here, we report the case of a 23-year-old male patient with a chest wall mass and extremely high platelet count, which remained extremely high even after surgical excision of the chest wall mass, chest wall tuberculosis (TB) diagnosis, and anti-TB combinatory drug therapy. Suppressor of cytokine signaling may be a novel MPN biomarker. Concurrent triple-negative ET and chest wall TB is uncommon, and its pathogenesis requires investigation.

Citation: Xu XY, Yang YB, Yuan J, Zhang XX, Kang L, Ma XS, Yang J. Individual with concurrent chest wall tuberculosis and triple-negative essential thrombocythemia: A case report. *World J Clin Cases* 2023; 11(22): 5365-5372

URL: <https://www.wjgnet.com/2307-8960/full/v11/i22/5365.htm>

DOI: <https://dx.doi.org/10.12998/wjcc.v11.i22.5365>

INTRODUCTION

Essential thrombocythemia (ET) is a clonal myeloproliferative neoplasm (MPN) originating from hematopoietic stem cells. It is characterized by abnormal megakaryocyte proliferation in the bone marrow and persistent thrombocytosis in the peripheral blood, which is accompanied by abnormal platelet (PLT) morphology and function. Although some patients may be asymptomatic, the most common clinical manifestations in symptomatic patients are thrombosis and bleeding[1-3]. In some patients, the disease can transform into primary myelofibrosis (PMF), acute myeloid leukemia (AML), or polycythemia vera (PV). In 2008, the World Health Organization (WHO) classified ET, PV, and PMF as myeloproliferative tumors with a negative BCR-ABL fusion gene[4]. In approximately 80%-90% of patients with ET, disease-defining mutations, such as JAK2 V617F, MPL exon 10, and CALR exon 9 mutations, are found in a mutually exclusive manner. These gene mutations can induce the constitutive activation of MPL, the thrombopoietin (TPO) receptor, and its downstream molecules, leading to the clonal expansion of hematopoietic stem cells and the cell-autonomous expansion of megakaryocytes, thus, causing thrombocytosis. Negative disease-defining mutations in JAK2, MPL, and CALR are observed in 10%-15% of patients with ET and are defined as triple-negative ET (TN-ET)[5-7]. Patients with TN-ET lack known mutations, and the mechanism behind it is unclear. Cases of concurrent chest wall tuberculosis (TB) and thrombocytosis have rarely been reported worldwide. Here, we report a case of chest wall TB combined with TN-ET.

CASE PRESENTATION

Chief complaints

A 23-year-old man presented to the hematology department, having suffered from a headache and low-grade fever for 2 d.

History of present illness

The patient was admitted to a local hospital due to the above symptoms in July 2017. He was found to have a bodily temperature fluctuating around 36.8 °C. Hematological analysis showed a high PLT count of $1503 \times 10^9/L$. Subsequently, the patient visited our hematology department for further investigation.

History of past illness

The patient underwent right axillary lipoma resection in 2012 and had no history of thrombosis or bleeding and no significant weight loss. He also had no risk factors for coronary artery disease.

Personal and family history

The patient denied any family history of malignant tumors or thrombocytosis.

Physical examination

Upon examination, the patient looked well, with no signs of jaundice or cyanosis. His blood pressure, temperature, pulse, respiratory rate, and oxygen saturation were 129/70 mmHg, 37.3 °C, 85 beats per minute, 20 breaths per minute, and 100% in ambient air, respectively. No bleeding spots or ecchymosis was observed, and the peripheral superficial lymph nodes were not enlarged. Additionally, no pressure pain was observed in the sternum. The liver was not palpable and the spleen was palpable 2 cm below the ribs, with medium quality and no pressure pain. There was no edema in either lower limb.

Laboratory examinations

Initial investigations showed a hemoglobin level, white blood cell count, PLT count, and neutrophil count of 140 g/L, $18.38 \times 10^9/\mu\text{L}$, $2064 \times 10^9/\mu\text{L}$, and $13.82 \times 10^9/\mu\text{L}$, respectively. A normal blood sedimentation rate of 4 mm/h and normal C-reactive protein concentration of 1.22 mg/L were observed. Additionally, the patient tested negative for serum TB antibodies, T-lymphocyte subsets, immunoglobulins, and HIV. The TB-infected T-cell spot assay A result was 97 SFCs/2.5*PBMC, and the TB-infected T-cell spot assay B result was 53 SFCs/2.5*PBMC. The prothrombin time was 14.1 s.

Bone marrow imaging: (1) Good sampling, smear, and staining, granular (++) oil (-); (2) Bone marrow proliferation was evidently active. Granulocytes accounted for 72%, while red lineage accounted for 13.5%. Granulocytes were red with a lineage ratio of 5.3:1; and (3) Increased granulocyte ratio, eosinophils were clearly observed, decreased red lineage ratio, and no obvious abnormalities in morphology were observed. Approximately 47 megakaryocytes were observed on the glass slide, and PLTs were mostly distributed in piles and patches (Figure 1). Blood examination revealed an increased white blood cell count, increased granulocyte ratio, no significant abnormalities in granulocyte and mature red blood cell morphology, and no nucleated red blood cells in a count of 100 white blood cells. PLTs were distributed in piles and observed more frequently. Bone marrow biopsy pathological diagnosis of the right posterior superior iliac spine bone marrow tissue showed a small amount of bone marrow tissue, a hematopoietic area of about 70%, a large size, multifoliation, and the presence of other various lineages of cells, which was consistent with megakaryocytosis (Figure 2). Immunohistochemical staining: CD42b (+++), CD71 (+), MPO (+), CD34 (-), CD3 (\pm), and CD20 (\pm). Characteristic staining: Reticular fibers (+) and Masson (-). Bone marrow tested negative for the BCR-ABL fusion, JAK2 V617F, JAK2 (exon 12), MPL, and CALR genes. The results of MPN/AML/MDS-leukemia mutation gene screening (34 genes: ASXL1, BCOR, BCORL1, CALR, CBL, CSF3R, DNMT3A, ETV6 EZH2, IDH1, IDH2, JAK2, KRAS, MPL, NRAS, PIGA, RUNX1, SETBP1, SF3B1, SH2B3, SRSF2, TET2, TP53, U2AF1, ZRSR2, CEBPA, and FLT3) were negative. Clinical bioinformatics analysis (GeneCan®, Beijing Jinyou Qikang Technology Co. Ltd.) initially identified 100 molecules that were highly correlated with a possible disease (Table 1).

Imaging examinations

Computed tomography (CT) of the chest suggested a submural soft tissue density shadow in the left lower chest wall, a flocculent hyper density shadow in the upper lobe of both lungs, a small nodular shadow in the upper lobe of the right lung, and multiple cord shadows in the left lung. Abdominal ultrasonography showed that the spleen was 130 mm \times 68 mm, and the width of the splenic vein was 8.9 mm. The liver, gallbladder, pancreas, and both kidneys showed no significant abnormalities. Vascular ultrasonography of the lower extremity suggested cloudy echogenicity in the lumen of the bilateral intermuscular veins of the lower leg, and no significant abnormalities were observed in the bilateral femoral and bilateral popliteal veins.

FINAL DIAGNOSIS

Combined with the patient's medical history, the final diagnosis was concurrent chest wall TB and TN-ET.

TREATMENT

The patient's chest enhancement CT subsequently showed improvements. Assessment revealed a flocculent hyperdense shadow in the upper lobes of both lungs and a submural soft tissue density shadow in the left lower chest wall with a heterogeneous density of 43 mm \times 34 mm \times 65 mm, which was considered satisfactory for a chest wall TB diagnosis. A CT-guided thoracic wall mass aspiration biopsy was performed, and pathological analysis revealed a small amount of chronic soft tissue inflammation with epithelioid cells at the margins and some coagulated necrotic tissue without structure, which was sufficient for a TB diagnosis. Acid-resistant bacilli were not detected by acid staining. The preliminary diagnosis was ET and a left chest wall mass, and possible chest wall TB. The patient's PLT count was extremely high and required surgical treatment. Thus, 1.0 g/d of hydroxyurea was orally administered to lower the PLT count.

The patient was transferred to the Department of Thoracic Surgery and underwent chest wall tumor resection under general anesthesia. There was an irregularly bordered, surface-rich, encapsulated mass on the surface of the chest wall, measuring 43 mm \times 34 mm \times 65 mm. The process proceeded smoothly, with approximately 20 mL of bleeding. The pathological findings of the swelling were reported as TB with massive caseous necrosis (Figure 3). The diagnosis of chest wall TB was further confirmed, and the patient was subsequently administered isoniazid, rifampin, ethambutol, and pyrazinamide as anti-TB treatments, during which the PLT count remained extremely high after repeated hematological

Table 1 Clinical bioinformatics analysis of the patient, based on the results of transcriptome sequencing	
Results of transcriptome sequencing	
Upregulated genes	MT-TP, AC246787.3, MIR4537, SPATA13, MIR23A, CTB-89H12.4, MIR4489, PDXDC2P, TRBJ2-2P, IGHJ3P, MIR4539, RPL41P5, AC004231.2, RP11-395L14.17, PRSS33, RPL37P6, RN7SL5P, AC007952.5, C19orf81, TIFAB, RPSAP47, CTA-384D8.31, RPL39P3, LRRC36, MT1DP, DEFA1, MIR4477B, AP000807.2, RPSAP15, SNORD99, RP11-61N20.3, SNORD104, AC005702.1, AC087793.1, MIR3687-2, LGALS2, RP11-1152H14.1, MIR339, FABP5P7, MIR3781, ZNF683, MIR25, RP11-543P15.1, AC007249.3, RP11-113K21.4, RPL21P122, RP5-1099D15.1, FAM207BP, MIR4697, CTD-2192J16.26
Downregulated genes	EEF1G, CD68, CD177, ATP6V0C, IFI30, ILK, PFKFB2, EIF4A1, SAP25, ADAMTS2, ANKHD1, NDST2, CD163, CD177P1, TMEM256-PLSCR3, ARG1, VNN1, SAMSN1, UBE2V1, BCKDHA, TMEM110, PFKFB3, ABHD16A, GADD45A, VSIG4, SOCS3, ATP13A3, CSGALNACT2, SLC1A3, HBD, ADAM9, UGCG, IL18RAP, IL18R1, JMJD7, CTRL, ACSL1, MUSTN1, SIPA1L2, AGFG1, ASPH, RPS10, TXNDC5, EDNRB, PLA2G4B, KCNMA1, RBM4, CPT1B, IRAK3, GALNT4

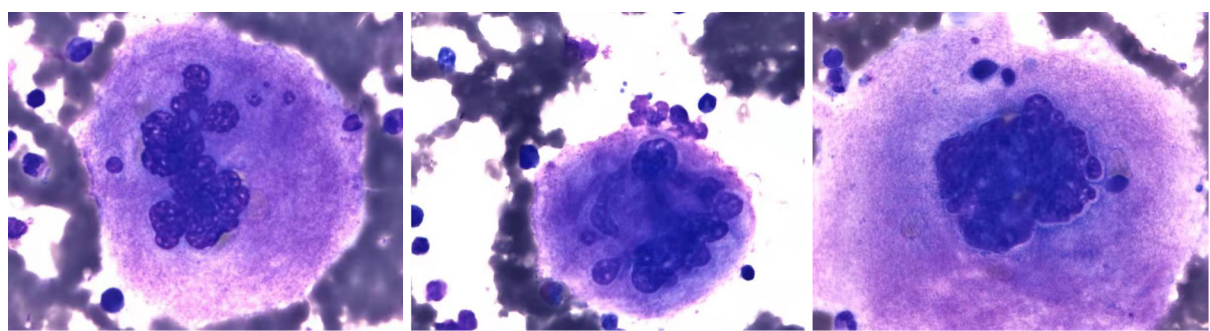


Figure 1 Bone marrow cell smear. Oil microscopy, 1000 ×. Megakaryocytes are large and multi-lobulated.

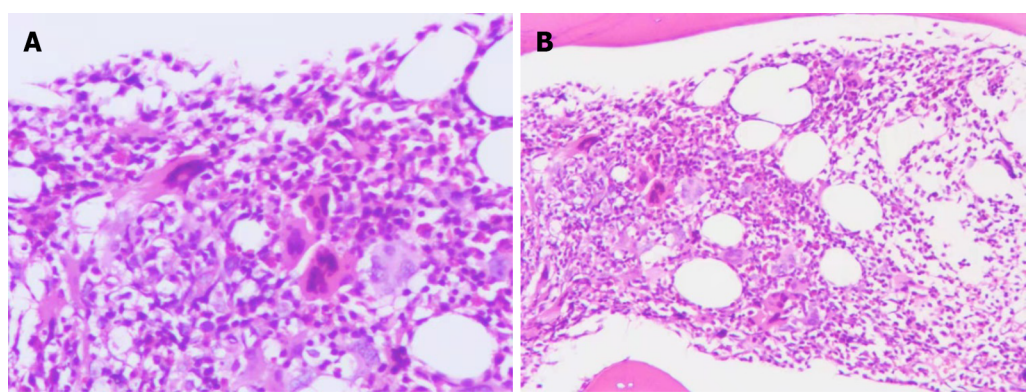
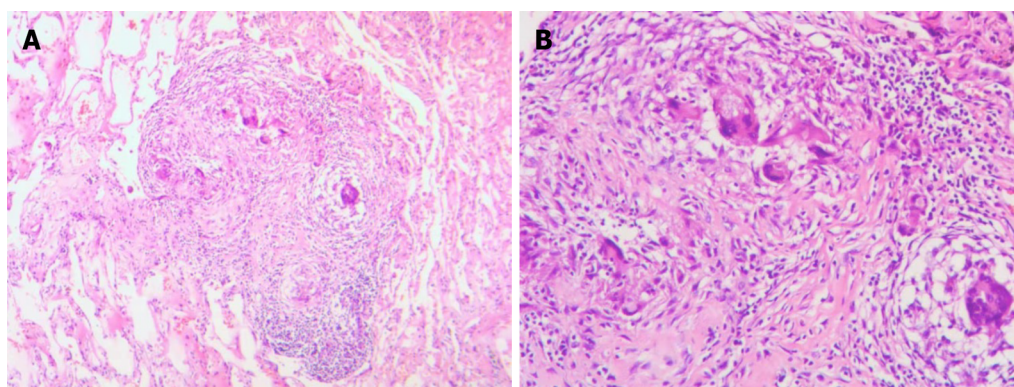


Figure 2 Bone marrow pathology images. A: Large bone marrow megakaryocytes under high magnification (200 ×); B: Large bone marrow megakaryocytes under low magnification (100 ×).

analysis. Subsequently, PLT-lowering treatment was performed using 2.0 g/d of hydroxyurea. After completing 8 mo of regular anti-TB treatment, a chest CT and hematology analysis were once again undertaken, and it was observed that the lung lesions had disappeared (Figures 4 and 5). However, the PLT count continued to be $> 1000 \times 10^9/L$. Subcutaneous injection of recombinant human interferon $\alpha 2b$ at 3 million u thrice a week was performed, and the amount of hydroxyurea was adjusted according to the PLT and white blood cell levels, ranging from 0.5-1.0 g/d. The patient's PLT count fluctuated from $537\text{--}1260 \times 10^9/L$.

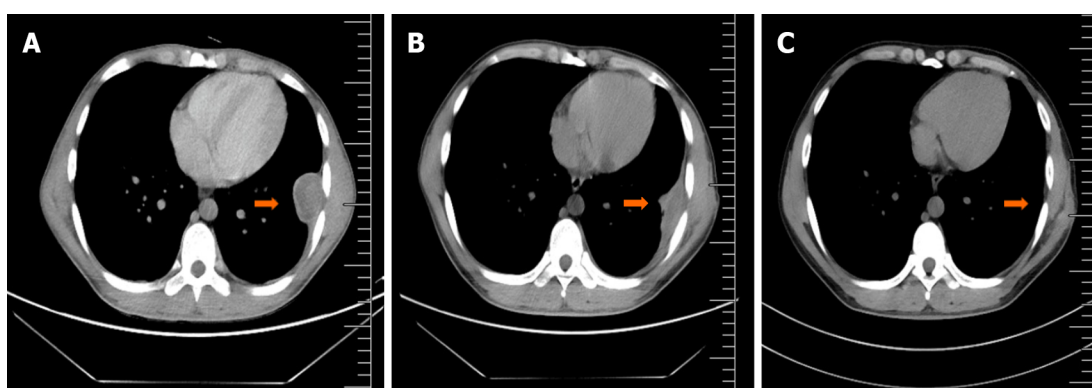
OUTCOME AND FOLLOW-UP

The patient was very young and had a high chance of long-term survival. Thus, hydroxyurea was discontinued and replaced by weekly injections of 180 μg polyethylene glycol $\alpha\text{-}2b$ (pegaptan), after which the patient's PLT count fluctuated from $440\text{--}520 \times 10^9/L$.



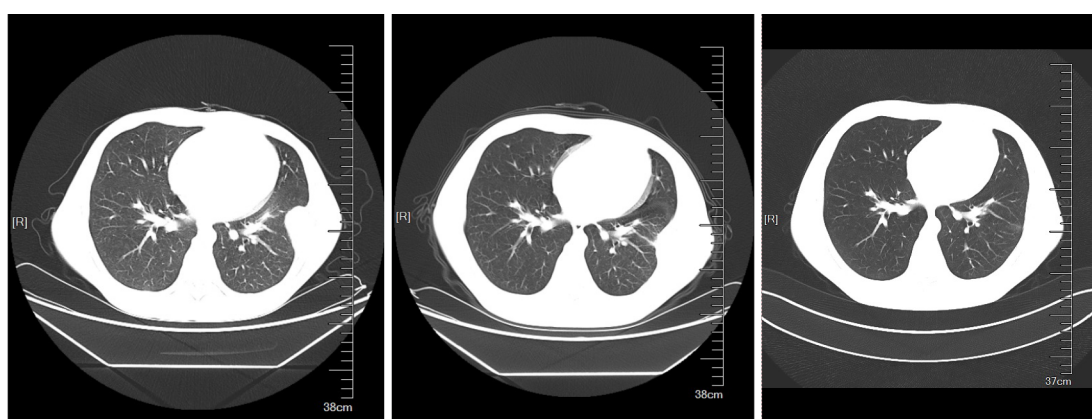
DOI: 10.12998/wjcc.v11.i22.5365 Copyright ©The Author(s) 2023.

Figure 3 Pathological pictures of the chest wall mass. A: Chest wall tuberculosis under low magnification (100 ×) showing epithelioid cells; B: Chest wall tuberculosis under high magnification (200 ×) showing epithelioid cells and granuloma.



DOI: 10.12998/wjcc.v11.i22.5365 Copyright ©The Author(s) 2023.

Figure 4 Chest computed tomography scan. A: Taken July 27, 2017. A mound-shaped soft tissue density shadow with heterogeneous density can be seen under the left lower chest wall. Its size is about 43 mm × 34 mm × 65 mm, without obvious enhancement. Both the scan and enhancement computed tomography values were between 40-50 HU; B: Taken January 9, 2018. A small amount of fluid density shadow can be seen in the left thorax, partially wrapped; C: Taken June 11, 2021. The original mound-shaped soft tissue is no longer visible.



DOI: 10.12998/wjcc.v11.i22.5365 Copyright ©The Author(s) 2023.

Figure 5 Chest wall computed tomography scan.

DISCUSSION

Thrombocythemia occurs with an elevated PLT count. The main types are essential (primary) and reactive (secondary) thrombocythemia. ET is an MPN that results from abnormal dysregulation of PLT production from bone marrow progenitor cells and is associated with mutated genes, such as JAK2. Secondary thrombocytosis, also known as reactive thrombocytosis, is defined as an abnormally high PLT count due to an underlying event, disease, or the use of certain

medications. Reactive causes of thrombocytosis include transient reactive thrombocytosis (such as acute blood loss and acute infection) or persistent reactive thrombocytosis (including iron deficiency, azoospermia, cancer, and chronic inflammatory or infectious diseases), such as TB[8].

TB is a chronic infectious disease caused by *Mycobacterium* TB (MTB), with pulmonary TB being the most common. It can also spread throughout the body *via* lymphatic and hematogenous dissemination, leading to extrapulmonary TB[9]. Extrapulmonary infections from TB can affect any organ, and the most common extrapulmonary sites of infection are the lymph nodes, pleura, and bone and joint areas. Chest wall TB is a rare form of TB, with an incidence of 1%-5% in osteoarthritic site TB, and 0.1% in all forms of TB. Chest wall TB most commonly presents as a solitary lesion without fluctuating or local inflammatory signs, and nonspecific clinical signs, such as irritated cough, pleuritic discomfort, weight loss, or night sweats. Diagnosis is based on sampling, preferably surgical biopsy, because of the low sensitivity of fine needle aspiration and the low presence of MTB in the biopsy sample. Most researchers advocate for combined medicinal and surgical treatment to reduce the recurrence rate of chest wall TB[10,11].

In this case report, the patient underwent surgical excision of a chest wall mass after CT, and puncture biopsy results did not exclude TB. Histopathological analysis led to a diagnosis of TB with massive caseous necrosis. The clinical manifestations of most TB types include systemic and respiratory symptoms, such as fever, night sweats, weight loss, and thrombocytosis. Although many reports have described TB-associated hematologic abnormalities (including thrombocytosis) as a reactive rise in PLT count due to TB causes, the mechanisms are unclear and may be related to factors such as TB activity, increased TPO levels, and cytokine levels. Additionally, reports have mentioned IL-6 synthesis and release after phagocytosis of MTB by macrophages in primary TB, which subsequently activates inflammatory cells and causes systemic effects, such as induction of acute phase reactants and thrombocytosis[12]. An association between TB and thrombocytosis is rare, but reactive thrombocytosis is common in patients with active TB. Nonetheless, there have been few cases of thrombocytosis with PLT counts $> 1000 \times 10^9/L$.

A case of TB peritonitis with thrombocytosis was reported in 1974 in a 20-year-old female patient who presented with marked thrombocytosis (PLT count $> 1372 \times 10^9/L$) and a 2-mo history of generalized abdominal pain and swelling. Upon examination, she was febrile (with a body temperature of 38 °C) and emaciated[13]. Her abdomen appeared doughy, and signs of ascites were present. However, there was no hepatomegaly or splenomegaly. Furthermore, her chest X-ray was normal. During peritoneoscopy, the visceral and parietal peritoneum was found to be studded with tubercles, and a nodule biopsy confirmed the presence of caseous TB. A bone marrow aspiration specimen showed a myeloid reaction with an increased number of megakaryocytes and normal morphology. After treatment with streptomycin, isoniazid, and ethambutol, the PLT counts gradually decreased to $1152 \times 10^9/L$, $1034 \times 10^9/L$, and $579 \times 10^9/L$ at 3, 4, and 8 wk, respectively. Thus, there may have been a correlation between thrombocytosis and TB in this patient.

In contrast, the patient in the present case report recovered well from TB when regular quadruple anti-TB treatment was administered after mass resection and interferon and hydroxyurea PLT-lowering therapy was applied simultaneously. However, the PLT count always decreased insignificantly, thus, thrombocytosis in this patient may not be correlated with TB.

The WHO 2016 version of the classification criteria for myeloid neoplasms and acute leukemia includes three driver mutations, JAK2, CALR, and MPL, as the main diagnostic criteria for MPN[14]. In addition to these driver mutations, several recent studies have identified the presence of other genetic mutations in MPN, such as ASXL1, EZH2, IDH1, IDH2, and SRSF2, as high-risk mutations, and have shown an association with a poor prognosis in MPN[5,15,16]. In addition, there is a subset of patients who are negative for BCR/ABL, JAK2/V617, MPL, and CALR genes, but ET cannot be excluded due to limited genetic testing and can be diagnosed as TN-ET according to the diagnostic criteria.

In 2016, the WHO published the relevant diagnostic criteria[14]. ET can be diagnosed by meeting four main criteria or the first three main criteria and one secondary criterion. The main criteria were as follows: (1) Consistent PLT count $\geq 450 \times 10^9/L$; (2) Bone marrow biopsy showing highly proliferated megakaryocytes with an increased number of mature megakaryocytes with large cytosomes and lobulated nuclei, no significant proliferation or leftward shift of granular and red lineages, and minimal and mild (Grade 1) increase in reticulocyte levels; (3) Failure to meet the diagnostic criteria for MDS, BCR-ABL + CML, PV, PMF, and other diagnostic criteria for myeloid neoplasms; and (4) The presence of JAK2, CALR, or MPL gene mutations. The secondary criterion was evidence of clonal markers or unresponsive thrombocytosis.

In the present case, biopsy histopathology confirmed the diagnosis of chest wall TB after chest wall mass resection, and the PLT count persisted at $> 450 \times 10^9/L$ even after 8 mo of regular anti-TB drug treatment with the 1HRZE regimen. A bone marrow smear and biopsy suggested megakaryocytosis, large size, multi-lobularity, PLTs in piles with a patchy distribution, and multiplicity, with no significant hyperplasia or left shift of granular and red lineages. Absence of morbid hematopoiesis, primitive naïve cells, *etc.*, did not meet the diagnostic criteria for CML, PV, PMF, MDS, or other myeloid neoplasms. The biopsy tested negative for BCR/ABL, JAK2V617F, CALR, and MPL fusion genes.

Individuals who meet the first three main diagnostic criteria and the secondary criterion are diagnosed with TN-ET. Compared to JAK2 mutated cases, patients with TN-ET are younger and have lower hemoglobin levels and lower thrombotic incidence[17,18]. The patient in this case report was 23 years old at the time of initial diagnosis and had a very low thrombosis risk (no history of thrombosis, aged < 60 years, and no JAK2 mutation).

JAK2V617F is by far the most common mutation in BCR-ABL1-negative MPN[19], with 95% of patients with PV, 65% of patients with PMF, and 55% of patients with ET having this mutation, in addition to the more commonly mutated MPL and CALR genes. Patients with ET have higher JAK-STAT3 activity, and JAK2V617F-negative ET may have mutations in other genes of the JAK-STAT pathway. JAK2 V617F is found in most patients with MPNs, and tyrosine phosphorylates suppressor of cytokine signaling (SOCS) 3 and escapes its repression. In addition, the JAK2 exon 12 mutant described in the V617F-negative MPN disease set stabilizes tyrosine phosphorylated SOCS3[20,21].

It has been reported that differentially expressed miRNAs between JAK2V617F-positive and -negative patients could explain the activation of the JAK/STAT pathway in the absence of a V617F mutation. The miRNA alone, in combination with the methylation process, could explain the downregulation of SOCS1 and SOCS3 in ET-JAK2V617F-negative patients, thus, participate in the activation of the JAK2 pathway[22].

Bioinformatics analysis of the patient in this case report, who was JAK2V617F-negative, showed changes in the expression of the downregulated gene SOCS3. Thus, SOCS3, a negative regulator of erythropoietin receptor and receptor-associated JAK2 kinase, may be a novel MPN biomarker and a potential mechanism for mutant JAK2 kinase to overcome SOCS3 inhibition[20].

CONCLUSION

The present case report involves a patient with concurrent chest wall TB and TN-ET, which is globally rare. The specific pathogenesis of the combination of these diseases is still unclear and needs to be studied in depth.

FOOTNOTES

Author contributions: Xu XY, Yang YB, Yuan J, and Zhang XX, contributed to manuscript writing and editing, and data collection; Kang L and Ma XS contributed to data analysis; Yang J contributed to conceptualization and supervision; all authors have read and approved the final manuscript.

Informed consent statement: Written informed consent for this case report has been obtained from the patient.

Conflict-of-interest statement: The authors report no conflicts of interest in this work.

CARE Checklist (2016) statement: The authors have read the CARE Checklist (2016), and the manuscript was prepared and revised according to the CARE Checklist (2016).

Open-Access: This article is an open-access article that was selected by an in-house editor and fully peer-reviewed by external reviewers. It is distributed in accordance with the Creative Commons Attribution NonCommercial (CC BY-NC 4.0) license, which permits others to distribute, remix, adapt, build upon this work non-commercially, and license their derivative works on different terms, provided the original work is properly cited and the use is non-commercial. See: <https://creativecommons.org/licenses/by-nc/4.0/>

Country/Territory of origin: China

ORCID number: Xiao-Yan Xu 0000-0002-7789-7018; Jie Yang 0000-0002-9902-4314.

S-Editor: Yan JP

L-Editor: A

P-Editor: Yan JP

REFERENCES

- 1 Kuykendall AT, Komrokji R. What's in a Number? Examining the Prognostic and Predictive Importance of Platelet Count in Patients With Essential Thrombocythemia. *J Natl Compr Canc Netw* 2020; **18**: 1279-1284 [PMID: 32886905 DOI: 10.6004/jnccn.2020.7595]
- 2 Mora B, Passamonti F. Developments in diagnosis and treatment of essential thrombocythemia. *Expert Rev Hematol* 2019; **12**: 159-171 [PMID: 30793984 DOI: 10.1080/17474086.2019.1585239]
- 3 Tefferi A, Barbui T. Polycythemia vera and essential thrombocythemia: 2019 update on diagnosis, risk-stratification and management. *Am J Hematol* 2019; **94**: 133-143 [PMID: 30281843 DOI: 10.1002/ajh.25303]
- 4 Tefferi A, Vardiman JW. Classification and diagnosis of myeloproliferative neoplasms: the 2008 World Health Organization criteria and point-of-care diagnostic algorithms. *Leukemia* 2008; **22**: 14-22 [PMID: 17882280 DOI: 10.1038/sj.leu.2404955]
- 5 Barbui T, Thiele J, Vannucchi AM, Tefferi A. Rationale for revision and proposed changes of the WHO diagnostic criteria for polycythemia vera, essential thrombocythemia and primary myelofibrosis. *Blood Cancer J* 2015; **5**: e337 [PMID: 26832847 DOI: 10.1038/bcj.2015.64]
- 6 Inano T, Araki M, Morishita S, Imai M, Kihara Y, Okuda M, Yang Y, Ito M, Osaga S, Mano H, Edahiro Y, Ochiai T, Misawa K, Fukuda Y, Ando J, Komatsu N. Cell-autonomous megakaryopoiesis associated with polyclonal hematopoiesis in triple-negative essential thrombocythemia. *Sci Rep* 2021; **11**: 17702 [PMID: 34489506 DOI: 10.1038/s41598-021-97106-9]
- 7 Tefferi A, Lasho TL, Finke CM, Elala Y, Hanson CA, Ketterling RP, Gangat N, Pardanani A. Targeted deep sequencing in primary myelofibrosis. *Blood Adv* 2016; **1**: 105-111 [PMID: 29296803 DOI: 10.1182/bloodadvances.2016000208]
- 8 Rokkam VR, Killeen RB, Kotagiri R. Secondary Thrombocytosis. 2023 Mar 24. In: StatPearls [Internet]. Treasure Island (FL): StatPearls Publishing; 2023 Jan-. [PMID: 32809645]
- 9 Loveday M, Mzobe YN, Pillay Y, Barron P. Figures of the dead: A decade of tuberculosis mortality registrations in South Africa. *S Afr Med J* 2019; **109**: 728-732 [PMID: 31635566 DOI: 10.7196/SAMJ.2019.v109i10.14073]
- 10 Abid M, Ben Amar M, Abdenadher M, Kacem AH, Mzali R, Mohamed IB. [Isolated abscess of the thoracic and abdominal wall: an

- exceptional form of tuberculosis]. *Rev Mal Respir* 2010; **27**: 72-75 [PMID: 20146955 DOI: 10.1016/j.rmr.2009.11.010]
- 11 **Rosales-Castillo A**, Javier-Martínez MR, López-Ruz MÁ. Chest wall tuberculosis: a rare extrapulmonary localization. *Med Clin (Barc)* 2021; **157**: 42 [PMID: 32693922 DOI: 10.1016/j.medcli.2020.04.045]
- 12 **Unsal E**, Aksaray S, Köksal D, Sipit T. Potential role of interleukin 6 in reactive thrombocytosis and acute phase response in pulmonary tuberculosis. *Postgrad Med J* 2005; **81**: 604-607 [PMID: 16143693 DOI: 10.1136/pgmj.2004.030544]
- 13 **Omar MA**, Jogessar VB, Kamdar MC. Thrombocytosis associated with tuberculous peritonitis. *Tubercle* 1983; **64**: 295-296 [PMID: 6659077 DOI: 10.1016/0041-3879(83)90027-2]
- 14 **Barbui T**, Thiele J, Gisslinger H, Kvasnicka HM, Vannucchi AM, Guglielmelli P, Orazi A, Tefferi A. The 2016 WHO classification and diagnostic criteria for myeloproliferative neoplasms: document summary and in-depth discussion. *Blood Cancer J* 2018; **8**: 15 [PMID: 29426921 DOI: 10.1038/s41408-018-0054-y]
- 15 **Guglielmelli P**, Lasho TL, Rotunno G, Mudireddy M, Mannarelli C, Nicolosi M, Pacilli A, Pardanani A, Rumi E, Rosti V, Hanson CA, Mannelli F, Ketterling RP, Gangat N, Rambaldi A, Passamonti F, Barosi G, Barbui T, Cazzola M, Vannucchi AM, Tefferi A. MIPSS70: Mutation-Enhanced International Prognostic Score System for Transplantation-Age Patients With Primary Myelofibrosis. *J Clin Oncol* 2018; **36**: 310-318 [PMID: 29226763 DOI: 10.1200/JCO.2017.76.4886]
- 16 **Vannucchi AM**, Lasho TL, Guglielmelli P, Biamonte F, Pardanani A, Pereira A, Finke C, Score J, Gangat N, Mannarelli C, Ketterling RP, Rotunno G, Knudson RA, Susini MC, Laborde RR, Spolverini A, Pancrazzi A, Pieri L, Manfredini R, Tagliafico E, Zini R, Jones A, Zoi K, Reiter A, Duncombe A, Pietra D, Rumi E, Cervantes F, Barosi G, Cazzola M, Cross NC, Tefferi A. Mutations and prognosis in primary myelofibrosis. *Leukemia* 2013; **27**: 1861-1869 [PMID: 23619563 DOI: 10.1038/leu.2013.119]
- 17 **Barbui T**, Vannucchi AM, Buxhofer-Ausch V, De Stefano V, Betti S, Rambaldi A, Rumi E, Ruggeri M, Rodeghiero F, Randi ML, Bertozzi I, Gisslinger H, Finazzi G, Carobbio A, Thiele J, Passamonti F, Falcone C, Tefferi A. Practice-relevant revision of IPSET-thrombosis based on 1019 patients with WHO-defined essential thrombocythemia. *Blood Cancer J* 2015; **5**: e369 [PMID: 26617062 DOI: 10.1038/bcj.2015.94]
- 18 **Tefferi A**, Guglielmelli P, Larson DR, Finke C, Wassie EA, Pieri L, Gangat N, Fjerza R, Belachew AA, Lasho TL, Ketterling RP, Hanson CA, Rambaldi A, Finazzi G, Thiele J, Barbui T, Pardanani A, Vannucchi AM. Long-term survival and blast transformation in molecularly annotated essential thrombocythemia, polycythemia vera, and myelofibrosis. *Blood* 2014; **124**: 2507-13; quiz 2615 [PMID: 25037629 DOI: 10.1182/blood-2014-05-579136]
- 19 **Tefferi A**. Novel mutations and their functional and clinical relevance in myeloproliferative neoplasms: JAK2, MPL, TET2, ASXL1, CBL, IDH and IKZF1. *Leukemia* 2010; **24**: 1128-1138 [PMID: 20428194 DOI: 10.1038/leu.2010.69]
- 20 **Elliott J**, Suessmuth Y, Scott LM, Nahlik K, McMullin MF, Constantinescu SN, Green AR, Johnston JA. SOCS3 tyrosine phosphorylation as a potential bio-marker for myeloproliferative neoplasms associated with mutant JAK2 kinases. *Haematologica* 2009; **94**: 576-580 [PMID: 19229050 DOI: 10.3324/haematol.2008.002352]
- 21 **Furqan M**, Mukhi N, Lee B, Liu D. Dysregulation of JAK-STAT pathway in hematological malignancies and JAK inhibitors for clinical application. *Biomark Res* 2013; **1**: 5 [PMID: 24252238 DOI: 10.1186/2050-7771-1-5]
- 22 **Navarro A**, Pairet S, Álvarez-Larrán A, Pons A, Ferrer G, Longarón R, Fernández-Rodríguez C, Camacho L, Monzó M, Besses C, Bellosillo B. miR-203 and miR-221 regulate SOCS1 and SOCS3 in essential thrombocythemia. *Blood Cancer J* 2016; **6**: e406 [PMID: 26990535 DOI: 10.1038/bcj.2016.10]



Published by **Baishideng Publishing Group Inc**
7041 Koll Center Parkway, Suite 160, Pleasanton, CA 94566, USA

Telephone: +1-925-3991568

E-mail: bpgoffice@wjgnet.com

Help Desk: <https://www.f6publishing.com/helpdesk>

<https://www.wjgnet.com>

