

# World Journal of *Clinical Cases*

*World J Clin Cases* 2023 August 16; 11(23): 5416-5627



## REVIEW

- 5416 Recent progress in understanding mitokines as diagnostic and therapeutic targets in hepatocellular carcinoma

Wang J, Luo LZ, Liang DM, Guo C, Huang ZH, Jian XH, Wen J

## ORIGINAL ARTICLE

## Retrospective Cohort Study

- 5430 Clinical characteristics and risk factors of intracranial hemorrhage after spinal surgery

Yan X, Yan LR, Ma ZG, Jiang M, Gao Y, Pang Y, Wang WW, Qin ZH, Han YT, You XF, Ruan W, Wang Q

## Retrospective Study

- 5440 Application effect of phloroglucinol injection in elderly patients with spastic abdominal pain in emergency department

Liu YF, Chen J

- 5447 Efficacy and prognosis of adjuvant treatment of endometrial cancer with medroxyprogesterone acetate COX regression analysis

Wang DR

- 5455 Serum vascular endothelial growth factor and cortisol expression to predict prognosis of patients with hypertensive cerebral hemorrhage

Zhang CY, Wang B, Hua XT, Fan K, Li YF

- 5462 Progress of ulcerative colitis patients during the COVID-19 pandemic

Suda T, Takahashi M, Katayama Y, Soga K, Kobori I, Kusano Y, Tamano M

## Observational Study

- 5468 Effect of vitamin supplementation on polycystic ovary syndrome and key pathways implicated in its development: A Mendelian randomization study

Shen JY, Xu L, Ding Y, Wu XY

## Prospective Study

- 5479 Evaluation of childhood developing *via* optical coherence tomography-angiography in Qamdo, Tibet, China: A prospective cross-sectional, school-based study

Sun KX, Xiang YG, Zhang T, Yi SL, Xia JY, Yang X, Zheng SJ, Ji Y, Wan WJ, Hu K

## SYSTEMATIC REVIEWS

- 5494 Isolated left ventricular apical hypoplasia: Systematic review and analysis of the 37 cases reported so far

Bassareo PP, Duignan S, James A, Dunne E, McMahon CJ, Walsh KP

**META-ANALYSIS**

- 5504** Identification of key genes and biological pathways in lung adenocarcinoma by integrated bioinformatics analysis

*Zhang L, Liu Y, Zhuang JG, Guo J, Li YT, Dong Y, Song G*

**CASE REPORT**

- 5519** Clinical outcomes of robotic-assisted and manual total hip arthroplasty in the same patient: A case report  
*Hu TY, Lin DC, Zhou YJ, Zhang ZW, Yuan JJ*
- 5525** Emphysematous sloughed floating ball after prostate water vaporization Rezum: A case report  
*Alnazari M, Bakhsh A, Rajih ES*
- 5530** Imaged guided surgery during arteriovenous malformation of gastrointestinal stromal tumor using hyperspectral and indocyanine green visualization techniques: A case report  
*Wagner T, Mustafov O, Hummels M, Grabenkamp A, Thomas MN, Schiffmann LM, Bruns CJ, Stippel DL, Wahba R*
- 5538** Membranous nephropathy with systemic light-chain amyloidosis of remission after rituximab therapy: A case report  
*Zhang J, Wang X, Zou GM, Li JY, Li WG*
- 5547** Rhabdomyolysis-induced acute kidney injury after administration of a red yeast rice supplement: A case report  
*Wang YH, Zhang SS, Li HT, Zhi HW, Wu HY*
- 5554** Jackstone in the renal calyx: A rare case report  
*Song HF, Liang L, Liu YB, Xiao B, Hu WG, Li JX*
- 5559** Critical respiratory failure due to pregnancy complicated by COVID-19 and bacterial coinfection: A case report  
*Zhou S, Liu MH, Deng XP*
- 5567** Townes-Brocks syndrome with adult renal impairment in a Chinese family: A case report  
*Wu J, Zhang J, Xiao TL, He T*
- 5573** Nasopharyngeal carcinoma with synchronous breast metastasis: A case report  
*Lei YY, Li DM*
- 5580** Anti-melanoma differentiation-associated gene 5 and anti-Ro52 antibody-dual positive dermatomyositis accompanied by rapidly lung disease: Three case reports  
*Ye WZ, Peng SS, Hu YH, Fang MP, Xiao Y*
- 5589** Anaphylactic shock induced by polyethylene glycol after bowel preparation for the colorectal cancer surgery: A case report  
*Park GW, Park N, Kuk JC, Shin EJ, Lim DR*
- 5595** Knee locking caused by osteochondroma of the proximal tibia adjacent to the pes anserinus: A case report  
*Sonobe T, Hakozaiki M, Matsuo Y, Takahashi Y, Yoshida K, Konno S*

- 5602** Complex inferior vena cava reconstruction during *ex vivo* liver resection and autotransplantation: A case report  
*Humaerhan J, Jiang TM, Aji T, Shao YM, Wen H*
- 5610** Hemocholecyst caused by accidental injury associated with radiofrequency ablation for hepatocellular carcinoma: A case report  
*Tan YW, Zhang XY*
- 5615** Pancreatic cavernous hemangioma complicated with chronic intracapsular spontaneous hemorrhage: A case report and review of literature  
*Li T*
- 5622** Pyogenic liver abscess secondary to gastric perforation of an ingested toothpick: A case report  
*Park Y, Han HS, Yoon YS, Cho JY, Lee B, Kang M, Kim J, Lee HW*

**ABOUT COVER**

Editorial Board Member of *World Journal of Clinical Cases*, Ellis J Neufeld, MD, PhD, Chief Physician, Executive Vice President, Professor, Department of Hematology, St. Jude Children's Research Hospital, Memphis, TN 38105, United States. ellis.neufeld@stjude.org

**AIMS AND SCOPE**

The primary aim of *World Journal of Clinical Cases* (WJCC, *World J Clin Cases*) is to provide scholars and readers from various fields of clinical medicine with a platform to publish high-quality clinical research articles and communicate their research findings online.

WJCC mainly publishes articles reporting research results and findings obtained in the field of clinical medicine and covering a wide range of topics, including case control studies, retrospective cohort studies, retrospective studies, clinical trials studies, observational studies, prospective studies, randomized controlled trials, randomized clinical trials, systematic reviews, meta-analysis, and case reports.

**INDEXING/ABSTRACTING**

The WJCC is now abstracted and indexed in Science Citation Index Expanded (SCIE, also known as SciSearch®), Journal Citation Reports/Science Edition, Current Contents®/Clinical Medicine, PubMed, PubMed Central, Reference Citation Analysis, China National Knowledge Infrastructure, China Science and Technology Journal Database, and Superstar Journals Database. The 2023 Edition of Journal Citation Reports® cites the 2022 impact factor (IF) for WJCC as 1.1; IF without journal self cites: 1.1; 5-year IF: 1.3; Journal Citation Indicator: 0.26; Ranking: 133 among 167 journals in medicine, general and internal; and Quartile category: Q4.

**RESPONSIBLE EDITORS FOR THIS ISSUE**

Production Editor: Hua-Ge Yin; Production Department Director: Xiang Li; Editorial Office Director: Jin-Lei Wang.

**NAME OF JOURNAL**

*World Journal of Clinical Cases*

**ISSN**

ISSN 2307-8960 (online)

**LAUNCH DATE**

April 16, 2013

**FREQUENCY**

Thrice Monthly

**EDITORS-IN-CHIEF**

Bao-Gan Peng, Jerzy Tadeusz Chudek, George Kontogeorgos, Maurizio Serati, Ja Hyeon Ku

**EDITORIAL BOARD MEMBERS**

<https://www.wjgnet.com/2307-8960/editorialboard.htm>

**PUBLICATION DATE**

August 16, 2023

**COPYRIGHT**

© 2023 Baishideng Publishing Group Inc

**INSTRUCTIONS TO AUTHORS**

<https://www.wjgnet.com/bpg/gerinfo/204>

**GUIDELINES FOR ETHICS DOCUMENTS**

<https://www.wjgnet.com/bpg/GerInfo/287>

**GUIDELINES FOR NON-NATIVE SPEAKERS OF ENGLISH**

<https://www.wjgnet.com/bpg/gerinfo/240>

**PUBLICATION ETHICS**

<https://www.wjgnet.com/bpg/GerInfo/288>

**PUBLICATION MISCONDUCT**

<https://www.wjgnet.com/bpg/gerinfo/208>

**ARTICLE PROCESSING CHARGE**

<https://www.wjgnet.com/bpg/gerinfo/242>

**STEPS FOR SUBMITTING MANUSCRIPTS**

<https://www.wjgnet.com/bpg/GerInfo/239>

**ONLINE SUBMISSION**

<https://www.f6publishing.com>





## Townes–Brocks syndrome with adult renal impairment in a Chinese family: A case report

Jing Wu, Jun Zhang, Tang-Li Xiao, Ting He

**Specialty type:** Urology and nephrology

**Provenance and peer review:** Unsolicited article; Externally peer reviewed.

**Peer-review model:** Single blind

**Peer-review report's scientific quality classification**

Grade A (Excellent): A  
Grade B (Very good): B  
Grade C (Good): 0  
Grade D (Fair): 0  
Grade E (Poor): 0

**P-Reviewer:** Malik S, Pakistan;  
Mijwil MM, Iraq

**Received:** May 4, 2023

**Peer-review started:** May 4, 2023

**First decision:** June 12, 2023

**Revised:** June 28, 2023

**Accepted:** July 27, 2023

**Article in press:** July 27, 2023

**Published online:** August 16, 2023



**Jing Wu, Jun Zhang, Tang-Li Xiao, Ting He**, Department of Nephrology, The Key Laboratory for the Prevention and Treatment of Chronic Kidney Disease of Chongqing, Chongqing Clinical Research Center of Kidney and Urology Diseases, Xinqiao Hospital, Army Medical University (Third Military Medical University), Chongqing 400037, China

**Corresponding author:** Ting He, Doctor, Department of Nephrology, The Key Laboratory for the Prevention and Treatment of Chronic Kidney Disease of Chongqing, Chongqing Clinical Research Center of Kidney and Urology Diseases, Xinqiao Hospital, Army Medical University (Third Military Medical University), No. 83 Xinqiao Street, Shapingba District, Chongqing 400037, China. [tingsr2000@sina.com](mailto:tingsr2000@sina.com)

### Abstract

#### BACKGROUND

Townes–Brocks syndrome (TBS) is a rare autosomal dominant syndrome that is characterized by a triad of imperforate anus, dysplastic ears, and thumb malformations. Heterozygous variants of *SALL1* are responsible for this syndrome. Renal structural abnormalities and functional impairments are often reported in TBS patients.

#### CASE SUMMARY

We report a case of TBS in a Chinese family. The index patients showed obvious renal atrophy and renal failure. TBS was suggested after a physical examination and pedigree analysis. Whole exome sequencing revealed a heterozygous variant of *SALL1*. The variant (NM\_001127892 c.1289\_c.1290 insC) led to a read-frame shift of the encoded protein, which was confirmed by Sanger sequencing. The variant cosegregated with the phenotype among affected members.

#### CONCLUSION

A novel variant in *SALL1* gene may be the molecular pathogenic basis of this disorder.

**Key Words:** Townes-Brocks syndrome; *SALL1*; Renal impairment; Pedigree; Whole exon sequencing; Case report

©The Author(s) 2023. Published by Baishideng Publishing Group Inc. All rights reserved.

**Core Tip:** Townes-Brocks syndrome (TBS) is a rare autosomal dominant syndrome, which is caused by the mutations of *SALL1*. We report a case of TBS with renal impairment in a Chinese family. TBS was suspected and a heterozygous variant of *SALL1* was revealed by whole exome sequencing. The variant led to a read-frame shift of the encoded protein. The variant co-segregated with the phenotype among affected members, which suggested that the variant of *SALL1* might be the molecular pathogenic basis of this disorder.

**Citation:** Wu J, Zhang J, Xiao TL, He T. Townes-Brocks syndrome with adult renal impairment in a Chinese family: A case report. *World J Clin Cases* 2023; 11(23): 5567-5572

**URL:** <https://www.wjgnet.com/2307-8960/full/v11/i23/5567.htm>

**DOI:** <https://dx.doi.org/10.12998/wjcc.v11.i23.5567>

## INTRODUCTION

Townes-Brocks syndrome (TBS, OMIM 107480) is characterized by the triad of imperforate anus, dysplastic ears, and thumb malformations. Other features of the condition include hearing loss, foot malformations, renal impairment, genitourinary malformations, and congenital heart disease. This syndrome is an autosomal dominant syndrome caused by a pathogenic variant of *SALL1* gene[1]. This syndrome was first described by Townes and Brocks in 1972, and the mutations in *SALL1* responsible for TBS were first identified by Kohlhasse in 1998[2,3]. Thereafter, many TBS cases were found with pathogenic variants of *SALL1* to make a molecular diagnosis.

The clinical presentations of TBS are complicated. TBS should be suspected in individuals with the three major clinical features: imperforate anus or anal stenosis, dysplastic ears, and typical thumb malformations. As the disease-causing gene is clear, identification of a pathogenic variant of *SALL1* by molecular genetic testing can establish the precise diagnosis if clinical features are inconclusive. The protein encoded by *SALL1* is a zinc finger transcriptional repressor and may be part of the NuRD histone deacetylase complex. The encoded protein plays a crucial role in the development of multiple organs. Among the TBS patients, one third of cases have impaired renal functions. This category of patients is often treated by nephrologists. However, the clinical diagnosis and treatment are still a challenge for nephrologists. In this case report, we describe an adult TBS patient, whose genetic testing was performed by whole exon sequencing (WES). A pathogenic variant of *SALL1* gene was found, which helped to make a precise diagnosis.

## CASE PRESENTATION

### Chief complaints

A 46-year-old Han Chinese male (height 158 cm, weight 51 kg) was admitted to our department because of renal failure.

### History of present illness

He had a history of gout for approximately 18 years, and his serum creatinine level had been elevated for 5 years. The patient was referred to our hospital for better treatment.

### History of past illness

Not special.

### Personal and family history

Pedigree analysis showed that his mother had renal impairment.

### Physical examination

No obvious edema was noted, except for slight anemia at the admission check.

### Laboratory examinations

Routine blood tests showed decreased blood red cell counts and hemoglobin (Table 1). Serum chemistry showed elevated levels of serum creatinine, uric acid, parathyroid hormone, and cystatin C, as well as decreased levels of albumin and calcium. Urine tests revealed mild proteinuria and occult blood. Based on estimated glomerular filtration rate, the patient was categorized as having end-stage renal disease (ESRD) and was undergoing hemodialysis.

During hospitalization, an abnormality in his hand was noted by our nephrologist, and a more detailed physical examination was performed. Excessive earlobe and toe deformities were detected, and the preaxial polydactyly underwent surgical resection when he was a boy (Figure 1). He was born with an imperforate anus, and surgery was performed after birth to correct anal stenosis. Visual impairment was recognized on examination of the ocular fundus, but no hearing loss was evident.

**Table 1** Abnormal laboratory data at admission

Parameters	Proband	Mother	Reference range
Routine blood tests			
RBC, 10 <sup>12</sup> /L	2.26		4.3-5.8
HGB, g/L	70	91	115-150/130-175
Routine urine tests			
UP	3+	1+	Negative
Urinary occult blood	1+		Negative
24-h UP, g/d	0.86		0-0.12
UP/urinary creatinine, g/g	1.42	0.23	
Serum chemistry			
Creatinine, μmol/L	610.5	309	45-105
Uric acid, μmol/L	486.0		140-420
Cystatin-C, mg/L	5.22	3.62	0-1.16
PTH, pg/mL	816.1	258.0	12-65
Albumin, g/L	34.4	39.6	40-50
Calcium, mmol/L	1.88		2.02-2.6
Phosphorus, mmol/L	1.39	0.74	0.9-1.34
Thyroxine (T <sub>4</sub> ), nmol/L	58.42		62.68-150.84
Serum iron, μmol/L	5.80		10.62-29.54
ESR, mm/h	57.0		0-15
CPR, mg/L	59.2		0-8
Immunology			
IgG, g/L	3.80		7-15
IgA, g/L	0.23		0.7-4.0
C3, g/L	0.69	0.69	0.9-2.1
Lambda, mg/dL	191.0		313-723
Kappa, mg/dL	296.0		629-1350

CPR: C-reactive protein; ESR: Erythrocyte sedimentation rate; HGB: Hemoglobin; RBC: Red blood cell; PTH: Parathyroid hormone; UP: Urinary protein.

### Imaging examinations

Abdominal ultrasound examination revealed obvious renal atrophy (right 4.9 cm × 2.0 cm × 0.52 cm, left 5.3 cm × 2.0 cm × 0.59 cm), with thinned renal cortex and hyperechogenicity. No abnormalities were detected in the liver, pancreas or spleen on ultrasound examination.

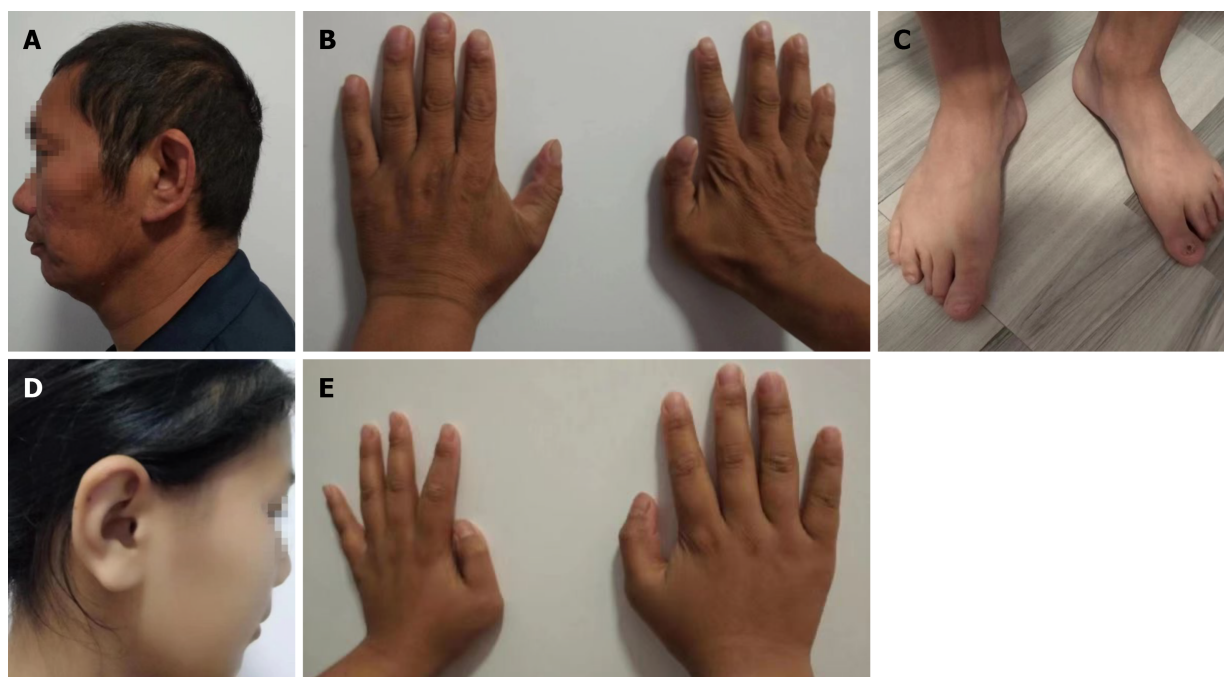
### Pedigree analysis

Pedigree analysis showed that his mother had the same appearance of ears and toes, and renal impairment was observed at the age of 68 years (Table 1 and Figure 2). His second daughter had the same symptoms, such as ears, preaxial polydactyly, and toes. She was diagnosed with leukemia at the age of 18 years without any renal impairment. The proband's son had similar symptoms, but his renal function was normal, except for elevated uric acid (529.0 μmol/L). Based on these findings, TBS was highly suspected in this family.

### Genetic analysis

Considering the diagnosis of TBS and the similar symptoms of the family members, the proband was recommended to undergo genetic testing to make a precise diagnosis. As his father had already died for unknown reasons, DNA samples were isolated from the peripheral blood cells of the proband, his mother, and children. WES was performed by the Chigene (Beijing) Translational Medical Research Center, as previously described[4]. Sequence analysis revealed a heterozygous variant of the *SALL1* gene. The variant NM\_001127892 c.1289\_c.1290 insC led to a read-frame shift of the encoded protein. Sanger sequencing was performed to validate the identified variations (Figure 2). The variant cosegregated with





DOI: 10.12998/wjcc.v11.i23.5567 Copyright ©The Author(s) 2023.

**Figure 1 Clinical data for the family.** A: Excessive earlobe of the proband; B: Preaxial polydactyly after surgical resection of the proband; C: Toe deformities of the proband; D: Excessive earlobe of the proband's daughter; E: Preaxial polydactyly after surgical resection of the proband's daughter.

the phenotype among affected members. The variant was excluded from the Single Nucleotide Polymorphism (dbSNP) and Human ClinVar databases. According to the American College of Medical Genetics and Genomics standards and guidelines, the variant was classified as pathogenic (PVS1+PM2+PP1).

## FINAL DIAGNOSIS

TBS with renal impairment.

## TREATMENT

Due to the high level of serum creatinine, he was treated with temporary hemodialysis. In addition, he received oral nifedipine (30 mg/d) to control the blood pressure, and febuxostat (40 mg/d) to lower the uric acid. Recombinant human EPO was also administered for one week to correct anemia.

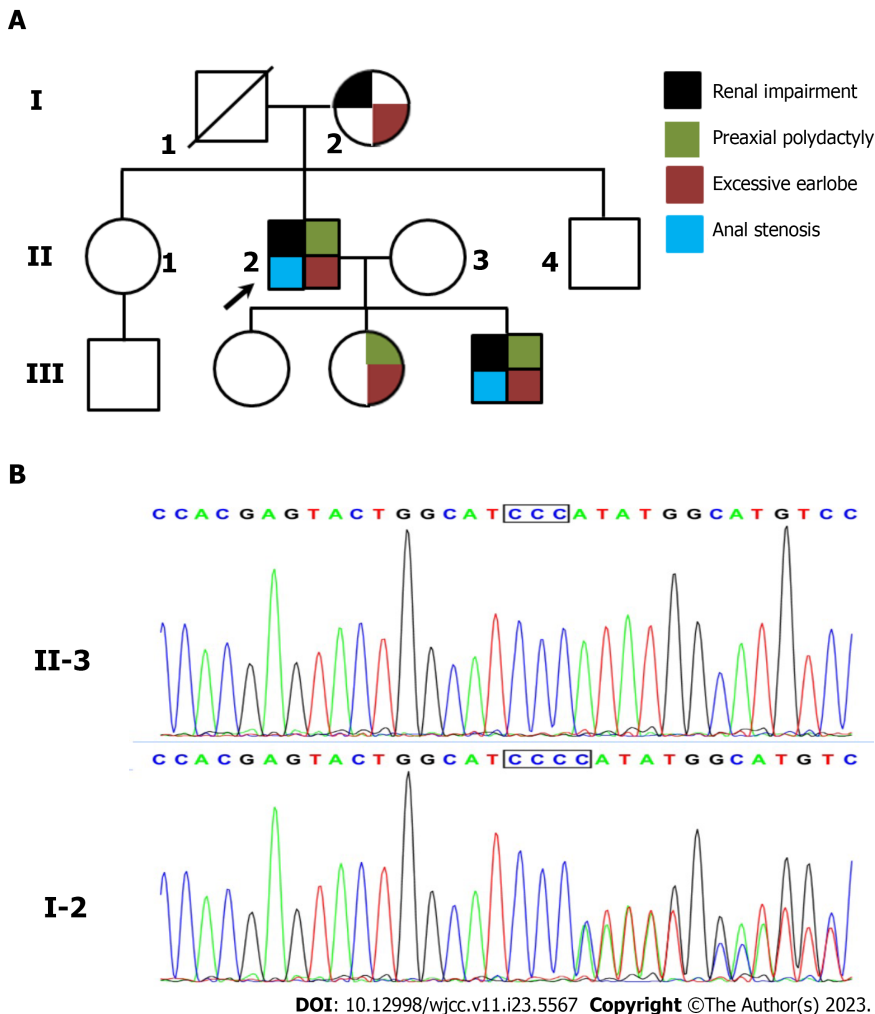
## OUTCOME AND FOLLOW-UP

At a 1-year follow-up, the patient had stage 5 chronic kidney disease and was treated with regular hemodialysis.

## DISCUSSION

In this case report, a diagnosis of TBS in this family was highly suspected, but uremia was the first symptom to prompt the proband to visit the hospital. After analyzing the family history and symptoms, genetic testing based on WES was performed and a final diagnosis was made. In clinical practice, uremic patients with TBS symptoms are rare, and nephrologists can hardly associate renal impairment with TBS. Therefore, misdiagnosis is often made.

It has been reported that renal anomalies, including functional impairment with or without structural abnormalities, were detected in 43% of patients with TBS. Recently, Beaudoux *et al*[3] reported two related TBS cases that exhibited kidney hypoplasia (focal and segmental glomerulosclerosis) and ESRD. Their literature review showed that 10 of 44 adult cases of TBS with genetic confirmation had kidney disease. Several studies have reported renal impairment in patients with TBS in the Chinese population. Fang *et al*[5] reported a novel heterozygous mutation in *SALL1* in a TBS family in which the proband and his paternal aunt had a history of unexplained renal failure with hemodialysis. Another study



**Figure 2 Identification of the heterozygous variant in the family.** A: Pedigree of the Chinese family. Affected family members are denoted in color. Three members (I-2, II-2 and III-4) underwent genetic study, while others were verified by Sanger sequencing. Arrow indicates the proband; B: Direct Sanger sequencing confirmed the heterozygous variant in *SALL1* gene.

reported a 40-day-old infant with renal failure, polycystic renal dysplasia, and other symptoms. Genetic testing revealed that the patient harbored an unreported frameshift variant of *SALL1*[6]. Lin *et al*[7] reported a male patient who presented with multiple bilateral cortical kidney cysts at the age of 4 years and end-stage renal failure at 16 years. As extrarenal involvement, including imperforate anus at birth, preaxial polydactyly, and dysplastic right ear, was evident, TBS was suspected and confirmed by WES. These studies showed that the age of onset of renal impairment varies greatly. In the family, one had no renal presentation and three members had renal impairment. In addition, the age of onset of renal impairment varied from 18 to 68 years. This indicated intrafamilial variability in the renal presentation.

*SALL1* encodes a zinc finger transcriptional repressor, which contains 11 WT1-binding sites and one SIX1-binding site. Currently, approximately 300 variants have been deposited in the ClinVar database, and 58 variants are categorized as pathogenic or likely pathogenic. Most of them are nonsense mutations and frameshift mutations and are located in the hotspot of *SALL1* mutations[8]. In our case, the pathogenic variant was also located in the hotspot, and the putative prematurely terminated protein lacked all the DZF domains. In a mouse model, the truncated mutant protein was capable of dominant-negative activity that resulted in the ectopic activation of two downstream genes. Therefore, TBS phenotypes are due to the expression of a truncated mutant protein and not haploinsufficiency[9].

In this case, the second daughter of the proband had leukemia at the age of 18 years. Besides similar symptoms, including excessive earlobe, preaxial polydactyly, and toe deformities, she was also diagnosed with leukemia at the age of 18 years. However, we cannot conclude an association between *SALL1* mutations and leukemia.

## CONCLUSION

In summary, we report a novel pathogenic variant of *SALL1* in a Chinese family with TBS, and expand the spectrum of *SALL1* mutations. Genetic testing based on WES benefits the clinical diagnosis and genetic counseling of patients with TBS.

## ACKNOWLEDGEMENTS

We wish to thank the patient and her family for participation in the study.

## FOOTNOTES

**Author contributions:** He T designed the research study; Wu J and Zhang J performed the research; He T and Xiao TL analyzed the data and wrote the manuscript; all authors have read and approve the final manuscript.

**Supported by** Joint Medical Project of Science and Technology Commission of Chongqing, No. 2021MSXM164.

**Informed consent statement:** Written informed consent to participate in the study was obtained from the parents of the patients.

**Conflict-of-interest statement:** The authors have no conflicts of interest to declare.

**CARE Checklist (2016) statement:** The authors have read the CARE Checklist (2016), and the manuscript was prepared and revised according to the CARE Checklist (2016).

**Open-Access:** This article is an open-access article that was selected by an in-house editor and fully peer-reviewed by external reviewers. It is distributed in accordance with the Creative Commons Attribution NonCommercial (CC BY-NC 4.0) license, which permits others to distribute, remix, adapt, build upon this work non-commercially, and license their derivative works on different terms, provided the original work is properly cited and the use is non-commercial. See: <https://creativecommons.org/licenses/by-nc/4.0/>

**Country/Territory of origin:** China

**ORCID number:** Jun Zhang [0000-0003-2134-6126](#); Tang-Li Xiao [0000-0002-8144-6252](#); Ting He [0000-0002-6653-6356](#).

**S-Editor:** Yan JP

**L-Editor:** A

**P-Editor:** Yan JP

## REFERENCES

- 1 **Kohlhase J.** Townes-Brocks Syndrome. 2007 Jan 24. In: GeneReviews® [Internet]. Seattle (WA): University of Washington, Seattle; 1993–[PMID: [20301618](#)]
- 2 **Miller EM,** Hopkin R, Bao L, Ware SM. Implications for genotype-phenotype predictions in Townes-Brocks syndrome: case report of a novel SALL1 deletion and review of the literature. *Am J Med Genet A* 2012; **158A**: 533-540 [PMID: [22308078](#) DOI: [10.1002/ajmg.a.34426](#)]
- 3 **Beaudoux O,** Lebre AS, Doco Fenzy M, Spodenkiewicz M, Canivet E, Colosio C, Poirsier C. Adult diagnosis of Townes-Brocks syndrome with renal failure: Two related cases and review of literature. *Am J Med Genet A* 2021; **185**: 937-944 [PMID: [33438842](#) DOI: [10.1002/ajmg.a.62050](#)]
- 4 **Zhang J,** Dai LM, Li FR, Zhang B, Zhao JH, Cheng JB. A Chinese family of autosomal recessive polycystic kidney disease identified by whole exome sequencing. *Medicine (Baltimore)* 2020; **99**: e20413 [PMID: [32481435](#) DOI: [10.1097/MD.00000000000020413](#)]
- 5 **Fang JX,** Zhang JS, Wang MM, Liu L. Novel mutation in the SALL1 gene in a four-generation Chinese family with uraemia: A case report. *World J Clin Cases* 2022; **10**: 7068-7075 [PMID: [36051141](#) DOI: [10.12998/wjcc.v10.i20.7068](#)]
- 6 **Wei H,** Sun L, Li M, Chen H, Han W, Fu W, Zhong J. [Analysis of SALL1 gene variant in a boy with Townes-Brocks syndrome without anal atresia]. *Zhonghua Yi Xue Yi Chuan Xue Za Zhi* 2022; **39**: 401-404 [PMID: [35446975](#) DOI: [10.3760/cma.j.cn511374-20200831-00637](#)]
- 7 **Lin FJ,** Lu W, Gale D, Yao Y, Zou R, Bian F, Jiang GR. Delayed diagnosis of Townes-Brocks syndrome with multicystic kidneys and renal failure caused by a novel SALL1 nonsense mutation: A case report. *Exp Ther Med* 2016; **11**: 1249-1252 [PMID: [27073431](#) DOI: [10.3892/etm.2016.3035](#)]
- 8 **Kohlhase J,** Taschner PE, Burfeind P, Pasche B, Newman B, Blanck C, Breuning MH, ten Kate LP, Maaswinkel-Mooy P, Mitulla B, Seidel J, Kirkpatrick SJ, Pauli RM, Wargowski DS, Devriendt K, Proesmans W, Gabrielli O, Coppa GV, Wesby-van Swaay E, Trembath RC, Schinzel AA, Reardon W, Seemanova E, Engel W. Molecular analysis of SALL1 mutations in Townes-Brocks syndrome. *Am J Hum Genet* 1999; **64**: 435-445 [PMID: [9973281](#) DOI: [10.1086/302238](#)]
- 9 **Kiefer SM,** Robbins L, Barina A, Zhang Z, Rauchman M. SALL1 truncated protein expression in Townes-Brocks syndrome leads to ectopic expression of downstream genes. *Hum Mutat* 2008; **29**: 1133-1140 [PMID: [18470945](#) DOI: [10.1002/humu.20759](#)]



Published by **Baishideng Publishing Group Inc**  
7041 Koll Center Parkway, Suite 160, Pleasanton, CA 94566, USA

**Telephone:** +1-925-3991568

**E-mail:** [bpgoffice@wjgnet.com](mailto:bpgoffice@wjgnet.com)

**Help Desk:** <https://www.f6publishing.com/helpdesk>

<https://www.wjgnet.com>

