

# World Journal of *Clinical Cases*

*World J Clin Cases* 2023 August 16; 11(23): 5416-5627



## REVIEW

- 5416 Recent progress in understanding mitokines as diagnostic and therapeutic targets in hepatocellular carcinoma

*Wang J, Luo LZ, Liang DM, Guo C, Huang ZH, Jian XH, Wen J*

## ORIGINAL ARTICLE

## Retrospective Cohort Study

- 5430 Clinical characteristics and risk factors of intracranial hemorrhage after spinal surgery

*Yan X, Yan LR, Ma ZG, Jiang M, Gao Y, Pang Y, Wang WW, Qin ZH, Han YT, You XF, Ruan W, Wang Q*

## Retrospective Study

- 5440 Application effect of phloroglucinol injection in elderly patients with spastic abdominal pain in emergency department

*Liu YF, Chen J*

- 5447 Efficacy and prognosis of adjuvant treatment of endometrial cancer with medroxyprogesterone acetate COX regression analysis

*Wang DR*

- 5455 Serum vascular endothelial growth factor and cortisol expression to predict prognosis of patients with hypertensive cerebral hemorrhage

*Zhang CY, Wang B, Hua XT, Fan K, Li YF*

- 5462 Progress of ulcerative colitis patients during the COVID-19 pandemic

*Suda T, Takahashi M, Katayama Y, Soga K, Kobori I, Kusano Y, Tamano M*

## Observational Study

- 5468 Effect of vitamin supplementation on polycystic ovary syndrome and key pathways implicated in its development: A Mendelian randomization study

*Shen JY, Xu L, Ding Y, Wu XY*

## Prospective Study

- 5479 Evaluation of childhood developing *via* optical coherence tomography-angiography in Qamdo, Tibet, China: A prospective cross-sectional, school-based study

*Sun KX, Xiang YG, Zhang T, Yi SL, Xia JY, Yang X, Zheng SJ, Ji Y, Wan WJ, Hu K*

## SYSTEMATIC REVIEWS

- 5494 Isolated left ventricular apical hypoplasia: Systematic review and analysis of the 37 cases reported so far

*Bassareo PP, Duignan S, James A, Dunne E, McMahon CJ, Walsh KP*

**META-ANALYSIS**

- 5504** Identification of key genes and biological pathways in lung adenocarcinoma by integrated bioinformatics analysis

*Zhang L, Liu Y, Zhuang JG, Guo J, Li YT, Dong Y, Song G*

**CASE REPORT**

- 5519** Clinical outcomes of robotic-assisted and manual total hip arthroplasty in the same patient: A case report  
*Hu TY, Lin DC, Zhou YJ, Zhang ZW, Yuan JJ*
- 5525** Emphysematous sloughed floating ball after prostate water vaporization Rezum: A case report  
*Alnazari M, Bakhsh A, Rajih ES*
- 5530** Imaged guided surgery during arteriovenous malformation of gastrointestinal stromal tumor using hyperspectral and indocyanine green visualization techniques: A case report  
*Wagner T, Mustafov O, Hummels M, Grabenkamp A, Thomas MN, Schiffmann LM, Bruns CJ, Stippel DL, Wahba R*
- 5538** Membranous nephropathy with systemic light-chain amyloidosis of remission after rituximab therapy: A case report  
*Zhang J, Wang X, Zou GM, Li JY, Li WG*
- 5547** Rhabdomyolysis-induced acute kidney injury after administration of a red yeast rice supplement: A case report  
*Wang YH, Zhang SS, Li HT, Zhi HW, Wu HY*
- 5554** Jackstone in the renal calyx: A rare case report  
*Song HF, Liang L, Liu YB, Xiao B, Hu WG, Li JX*
- 5559** Critical respiratory failure due to pregnancy complicated by COVID-19 and bacterial coinfection: A case report  
*Zhou S, Liu MH, Deng XP*
- 5567** Townes-Brooks syndrome with adult renal impairment in a Chinese family: A case report  
*Wu J, Zhang J, Xiao TL, He T*
- 5573** Nasopharyngeal carcinoma with synchronous breast metastasis: A case report  
*Lei YY, Li DM*
- 5580** Anti-melanoma differentiation-associated gene 5 and anti-Ro52 antibody-dual positive dermatomyositis accompanied by rapidly lung disease: Three case reports  
*Ye WZ, Peng SS, Hu YH, Fang MP, Xiao Y*
- 5589** Anaphylactic shock induced by polyethylene glycol after bowel preparation for the colorectal cancer surgery: A case report  
*Park GW, Park N, Kuk JC, Shin EJ, Lim DR*
- 5595** Knee locking caused by osteochondroma of the proximal tibia adjacent to the pes anserinus: A case report  
*Sonobe T, Hakozaiki M, Matsuo Y, Takahashi Y, Yoshida K, Konno S*

- 5602** Complex inferior vena cava reconstruction during *ex vivo* liver resection and autotransplantation: A case report  
*Humaerhan J, Jiang TM, Aji T, Shao YM, Wen H*
- 5610** Hemocholecyst caused by accidental injury associated with radiofrequency ablation for hepatocellular carcinoma: A case report  
*Tan YW, Zhang XY*
- 5615** Pancreatic cavernous hemangioma complicated with chronic intracapsular spontaneous hemorrhage: A case report and review of literature  
*Li T*
- 5622** Pyogenic liver abscess secondary to gastric perforation of an ingested toothpick: A case report  
*Park Y, Han HS, Yoon YS, Cho JY, Lee B, Kang M, Kim J, Lee HW*

**ABOUT COVER**

Editorial Board Member of *World Journal of Clinical Cases*, Ellis J Neufeld, MD, PhD, Chief Physician, Executive Vice President, Professor, Department of Hematology, St. Jude Children's Research Hospital, Memphis, TN 38105, United States. [ellis.neufeld@stjude.org](mailto:ellis.neufeld@stjude.org)

**AIMS AND SCOPE**

The primary aim of *World Journal of Clinical Cases* (WJCC, *World J Clin Cases*) is to provide scholars and readers from various fields of clinical medicine with a platform to publish high-quality clinical research articles and communicate their research findings online.

WJCC mainly publishes articles reporting research results and findings obtained in the field of clinical medicine and covering a wide range of topics, including case control studies, retrospective cohort studies, retrospective studies, clinical trials studies, observational studies, prospective studies, randomized controlled trials, randomized clinical trials, systematic reviews, meta-analysis, and case reports.

**INDEXING/ABSTRACTING**

The WJCC is now abstracted and indexed in Science Citation Index Expanded (SCIE, also known as SciSearch®), Journal Citation Reports/Science Edition, Current Contents®/Clinical Medicine, PubMed, PubMed Central, Reference Citation Analysis, China National Knowledge Infrastructure, China Science and Technology Journal Database, and Superstar Journals Database. The 2023 Edition of Journal Citation Reports® cites the 2022 impact factor (IF) for WJCC as 1.1; IF without journal self cites: 1.1; 5-year IF: 1.3; Journal Citation Indicator: 0.26; Ranking: 133 among 167 journals in medicine, general and internal; and Quartile category: Q4.

**RESPONSIBLE EDITORS FOR THIS ISSUE**

Production Editor: Hua-Ge Yin; Production Department Director: Xiang Li; Editorial Office Director: Jin-Lei Wang.

**NAME OF JOURNAL**

*World Journal of Clinical Cases*

**ISSN**

ISSN 2307-8960 (online)

**LAUNCH DATE**

April 16, 2013

**FREQUENCY**

Thrice Monthly

**EDITORS-IN-CHIEF**

Bao-Gan Peng, Jerzy Tadeusz Chudek, George Kontogeorgos, Maurizio Serati, Ja Hyeon Ku

**EDITORIAL BOARD MEMBERS**

<https://www.wjgnet.com/2307-8960/editorialboard.htm>

**PUBLICATION DATE**

August 16, 2023

**COPYRIGHT**

© 2023 Baishideng Publishing Group Inc

**INSTRUCTIONS TO AUTHORS**

<https://www.wjgnet.com/bpg/gerinfo/204>

**GUIDELINES FOR ETHICS DOCUMENTS**

<https://www.wjgnet.com/bpg/GerInfo/287>

**GUIDELINES FOR NON-NATIVE SPEAKERS OF ENGLISH**

<https://www.wjgnet.com/bpg/gerinfo/240>

**PUBLICATION ETHICS**

<https://www.wjgnet.com/bpg/GerInfo/288>

**PUBLICATION MISCONDUCT**

<https://www.wjgnet.com/bpg/gerinfo/208>

**ARTICLE PROCESSING CHARGE**

<https://www.wjgnet.com/bpg/gerinfo/242>

**STEPS FOR SUBMITTING MANUSCRIPTS**

<https://www.wjgnet.com/bpg/GerInfo/239>

**ONLINE SUBMISSION**

<https://www.f6publishing.com>





## Complex inferior vena cava reconstruction during ex vivo liver resection and autotransplantation: A case report

Jiayidaer Humaerhan, Tie-Min Jiang, Tuerganaili Aji, Ying-Mei Shao, Hao Wen

**Specialty type:** Transplantation

**Provenance and peer review:**

Unsolicited article; Externally peer reviewed.

**Peer-review model:** Single blind

**Peer-review report's scientific quality classification**

Grade A (Excellent): A

Grade B (Very good): 0

Grade C (Good): C

Grade D (Fair): 0

Grade E (Poor): 0

**P-Reviewer:** Amante MF, Argentina; Uhlmann D, Germany

**Received:** May 24, 2023

**Peer-review started:** May 24, 2023

**First decision:** June 19, 2023

**Revised:** July 1, 2023

**Accepted:** July 17, 2023

**Article in press:** July 17, 2023

**Published online:** August 16, 2023



**Jiayidaer Humaerhan, Tie-Min Jiang, Tuerganaili Aji, Ying-Mei Shao, Hao Wen**, Department of Hepatobiliary & Hydatid Diseases, Digestive & Vascular Surgery Center, The First Affiliated Hospital of Xinjiang Medical University, Urumqi 830054, Xinjiang Uygur Autonomous Region, China

**Jiayidaer Humaerhan, Tie-Min Jiang, Tuerganaili Aji, Hao Wen**, State Key Laboratory of Pathogenesis, Prevention and Management of High Incidence Diseases in Central Asia, The First Clinical Medical College of Xinjiang Medical University, Urumqi 830054, Xinjiang Uygur Autonomous Region, China

**Ying-Mei Shao**, Xinjiang Clinical Research Center for Echinococcosis and Hepatobiliary Diseases, First Affiliated Hospital of Xinjiang Medical University, Urumqi 830054, Xinjiang Uygur Autonomous Region, China

**Corresponding author:** Hao Wen, PhD, Chief Doctor, State Key Laboratory of Pathogenesis, Prevention and Management of High Incidence Diseases in Central Asia, The First Clinical Medical College of Xinjiang Medical University, No. 137 Leyueshan South Road, Xincheng District, Urumqi 830054, Xinjiang Uygur Autonomous Region, China. [dr.wenhao@163.com](mailto:dr.wenhao@163.com)

### Abstract

#### BACKGROUND

*Ex vivo* liver resection and autotransplantation (ELRA) is an essential approach for treating patients with end-stage hepatic alveolar echinococcosis (AE), and its surgical indications involve severe invasion of important hepatic vessels, which makes *in vivo* resection impossible. Revascularization is a major step in the process of ELRA, which is extremely challenging when the invaded vessels have huge defects.

#### CASE SUMMARY

Herein, we have reported the case of a 26-year-old patient with hepatic AE in an autologous liver graft who underwent complex inferior vena cava (IVC) reconstruction using disease-free IVC, autologous portal vein fragments, and umbilical vein within the ligamentum teres hepatis. The patient showed good surgical recovery without vascular-related complications during the long-term follow-up.

#### CONCLUSION

We reviewed three studies that have reported complex revascularization of the IVC. This case report and systematic review showed that the use of autologous

perihepatic vessels prevents donor-area trauma, immune rejection, and other adverse reactions. When the blood vessel is severely invaded and a single vascular material cannot repair and reconstruct the defect, ELRA may provide a safe and feasible surgical approach, which has good prospects for clinical application.

**Key Words:** Hepatic alveolar echinococcosis; *Ex vivo* liver resection and autotransplantation; Inferior vena cava; Revascularization; Case report

©The Author(s) 2023. Published by Baishideng Publishing Group Inc. All rights reserved.

**Core Tip:** *Ex vivo* liver resection and autotransplantation (ELRA) is an essential approach to cure end-stage hepatic alveolar echinococcosis (AE). Revascularization is a central and challenging step in the process of ELRA when the invaded vessels have large defects. Here, we report the case of a 26-year-old patient with hepatic AE in an autologous liver graft who underwent complex inferior vena cava (IVC) reconstruction using disease-free IVC, autologous portal vein fragments and umbilical vein within the ligamentum teres hepatis and with good surgical recovery without vascular-related complications at long-term follow-up. This study demonstrate that the blood vessel is severely invaded and a single vascular material cannot repair and reconstruct the defect, this technique may provide a feasible surgical option for revascularization during ELRA and has good prospects for clinical application.

**Citation:** Humaerhan J, Jiang TM, Aji T, Shao YM, Wen H. Complex inferior vena cava reconstruction during *ex vivo* liver resection and autotransplantation: A case report. *World J Clin Cases* 2023; 11(23): 5602-5609

**URL:** <https://www.wjgnet.com/2307-8960/full/v11/i23/5602.htm>

**DOI:** <https://dx.doi.org/10.12998/wjcc.v11.i23.5602>

## INTRODUCTION

Hepatic alveolar echinococcosis (AE) is a rare zoonotic infection that is caused by *Echinococcus multilocularis*[1]. It is an invasive disease with systemic metastasis[2]; however, its insidious onset and slow progression make early diagnosis difficult. Radical hepatectomy combined with antiparasitic medication is the only curative treatment approach for patients with hepatic alveolar echinococcosis; however, this approach is feasible for only 35% of patients due to delay in diagnosis[3,4]. Previous studies have shown that *ex vivo* liver resection and autotransplantation (ELRA) can be an effective alternative to allotransplantation in patients with end-stage hepatic AE[5-7]. Compared with allotransplantation, ELRA overcomes the limitations of shortage of liver sources and long-term postoperative immunosuppression[8-10]. Therefore, ELRA is a better choice for patients with end-stage hepatic AE where complete resection of the lesion is not possible and technical challenges, such as *in vivo* revascularization, are difficult to overcome[9,11,12]. End-stage hepatic AE can invade major bile ducts and blood vessels, which requires additional repair and reconstruction procedures of the vessels during ELRA[1,2,13]. In this case, the selection of an appropriate revascularization material is significant. Based on the degree of vascular invasion, reconstruction materials can be selected from autologous vessels, allogeneic vessels, and artificial vessels. Complex revascularization with multiple vascular remnants can also be an effective treatment approach when the area of lesion invasion is huge and a single vascular patch is not sufficient for revascularization. Herein, we have presented a case of complex reconstruction of the inferior vena cava (IVC) using autologous portal vein (PV) fragments, umbilical vein within the ligamentum teres hepatis (LTH), and disease-free IVC during ELRA. Furthermore, the available literature on the complex reconstruction of the IVC during ELRA was reviewed to summarize the experience of the complex reconstruction of the IVC.

## CASE PRESENTATION

### Chief complaints

A 26-year-old Chinese woman presented to the general surgery clinic with a complaint of upper right abdominal pain for 2 wk.

### History of present illness

Symptoms started 2 wk before presentation with recurrent upper right abdominal pain.

### History of past illness

No previous complaints of discomfort.

### Personal and family history

The patient has a long history of living in a pastoral area. She denied any family history of malignant tumours.

### Physical examination

On physical examination, the vital signs were as follows: Body temperature, 36.2°C; blood pressure, 121/72 mmHg; heart rate, 76 beats per min; respiratory rate, 16 breaths per min. Flat abdomen, no abdominal varicose veins, no abdominal muscle tension, no tenderness, no rebound pain, no liquid wave tremor, no water vibration sound, no abdominal mass, bowel sound 4 times per minute.

### Laboratory examinations

No abnormality was found in routine blood, urine analyses, biochemical test and serum tumour markers.

### Imaging examinations

Abdominal color doppler ultrasound revealed a moderate to high echogenic lesion in the right lobe of the liver with a size of approximately 9.5 cm × 8.7 cm. Abdominal computed tomography (CT) revealed space-occupying lesions in the right posterior lobe and the caudate lobe of the liver. The right branch of the PV, the middle hepatic vein (HV), and the initial part of the left HV were invaded. The hepatic IVC was surrounded by lesions and narrowed due to compression (Figure 1A and B).

### Histology

Liver tissues were fixed for more than 24 h and then cut into 5 µm sections after paraffin embedding. Hematoxylin and eosin staining was performed according to the instructions. The staining results showed abundant granulomatous reaction and coagulative necrosis around the laminated parasitic membranes (Figure 2A and B).

---

## FINAL DIAGNOSIS

Combined with the patient's medical history, the final diagnosis was hepatic AE (P4N0M0/PI-II, VI-VIII, and I1V1M0).

---

## TREATMENT

The patient underwent ELRA. The right posterior lobe of the liver, most of the right anterior lobe, the caudate lobe, and a part of the left inner lobe were invaded. The right HV, the root of the middle HV, and the root of the left HV were encircled, and the anterior and lateral walls of the hepatic IVC were surrounded by a lesion of almost 5 cm in size. After the entire liver was dissociated, the important vascular regions were transected and the infected part of the liver was removed. The hepatic IVC was reconstructed with artificial vessels to perform a temporary portal shunt. The entire liver was isolated and rapidly perfused through the left branch of PV with Histidine-Tryptophan-Ketoglutarate solution at 0 to 4°C. The hepatic parenchyma was severed at 2.0 cm along with the right edge of the falciform ligament, the vessels along the way were ligated, and the lesions that invaded the vessels were removed.

The anterolateral wall of the hepatic IVC was invaded by the lesion. Because the resection of the autograft iliac vein and internal jugular vein can be locally traumatic to the patient, we used the umbilical vein within the LTH, PV fragment, and disease-free IVC to reconstruct the huge defect of the hepatic IVC. The anastomosis between the IVC and artificial blood vessel was dismantled, and end-to-end anastomosis of the upper and lower edges of the repaired hepatic IVC was performed. The PV was anastomosed, which opened all blood vessels and ended the anhepatic phase. End-to-end anastomosis of the right branch of the proper hepatic artery with the trunk type of a proper hepatic artery was performed. Furthermore, Roux-en-Y hepaticojejunostomy was performed to drain the left hepatobiliary duct (Figure 1C-H).

The entire surgery took 14 h and 5 min to complete with stable hemodynamics. The patient had a blood loss of almost 700 mL and was transfused 630 mL of fresh plasma and 528 mL of autologous.

---

## OUTCOME AND FOLLOW-UP

The patient developed pleural effusion 6 d post-surgery, which was treated with a pleural puncture and catheter drainage. Ultrasonography was performed on days 0, 1, 2, 4, and 6, which showed unobstructed blood flow signals in IVC. Regular abdominal CT showed normal visualization of the IVC, no distinct stenosis, and a filled defect. The follow-up time was 84 mo (Table 1). The patient showed good liver functions and no revascularization-related complications during follow-ups. The abdominal CT of the patient showed good filling of the vessels after 84 mo with no obstruction or stenosis (Figure 2C-E).

It's been eight years since the operation, the patient was still alive.



**Table 1** Intraoperative and postoperative parameters

Variables	Case 1
Residual liver volume (m <sup>3</sup> )	530
RLV/SLV (%)	46.2
Operation time (h)	14.08
Cold ischemia time (min)	403
Warm ischemia time (min)	18
Anhepatic phase (min)	421
Time of inferior vena cava occlusion (min)	122
Blood loss (mL)	800
Blood transfusion volume	
Suspended RBC (units)	6
Plasma (mL)	1070
Autotransfusion (mL)	750
Cryoprecipitate (units)	0
Platelet (units)	0
ICU stay time (h)	65.4
Hospital stays (d)	35
Postoperative complications	
Pulmonary infection	N
Pleural effusion	Y
Ascites	N
Outflow tract stenosis	N

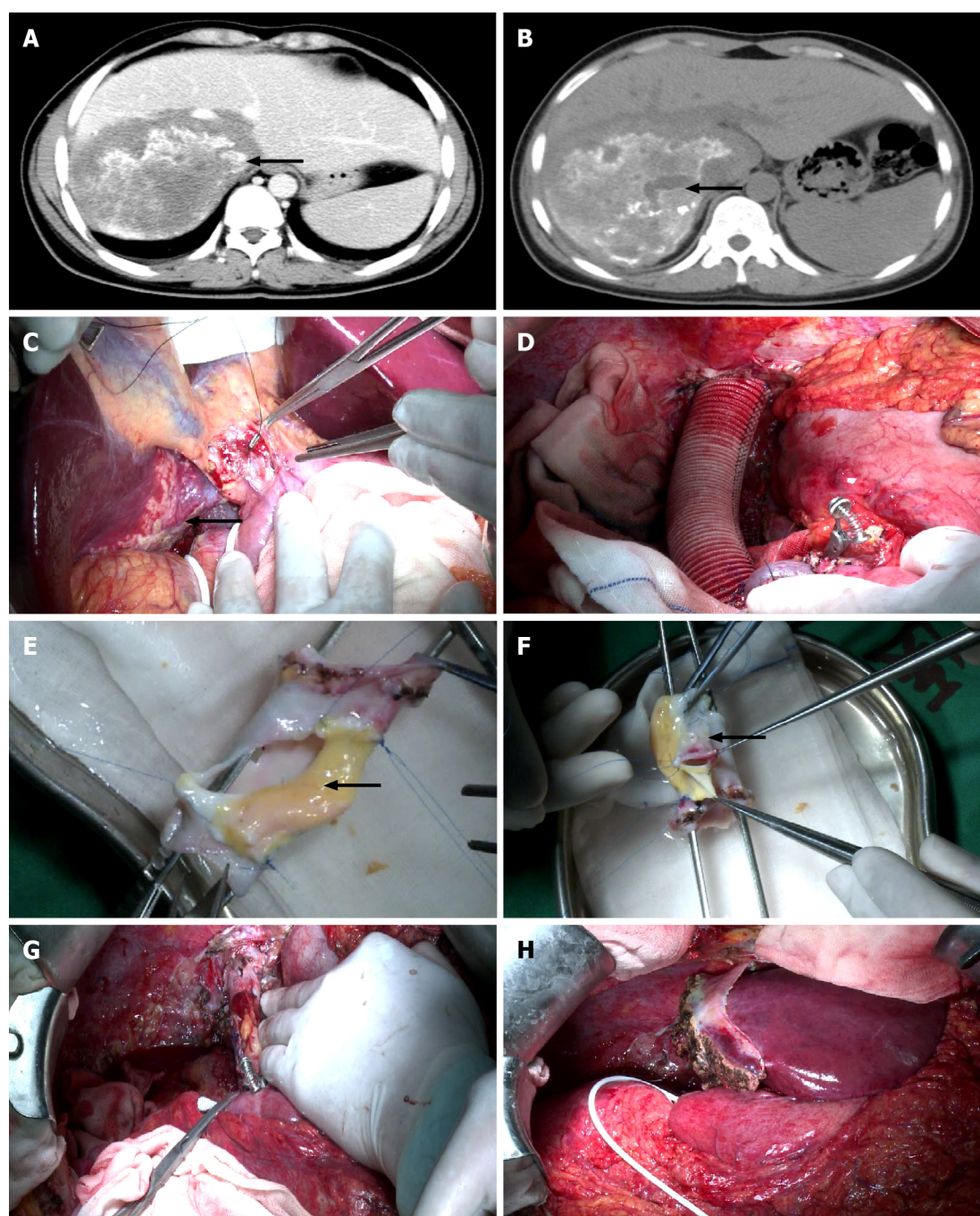
RLV: Residual liver volume; SLV: Standard liver volume; RBC: Red blood cell; ICU: Intensive care unit.

## DISCUSSION

Hepatic AE is a zoonotic infection found worldwide that is caused by *Echinococcus multilocularis*[14]. It is mainly endemic in the northern hemisphere, especially in western China. Radical surgery is the best approach to treat this condition. However, its diagnosis can be delayed because obvious symptoms are not observed during the early stages. Therefore, patients are sometimes deprived of radical surgery due to the significant invasion of vital blood vessels by the time of diagnosis. Chui *et al*[15] achieved good results with the first ELRA in 2003. Therefore, this surgery has gradually become an effective approach for treating end-stage hepatic AE. ELRA has garnered increasing attention in recent years owing to its advantages of radical excision of lesions with no requirement of an immunosuppressive agent. Compared with allotransplantation, ELRA has better long-term efficacy for treating end-stage hepatic AE or benign liver tumors[12]. The major challenge in ELRA is repairing and reconstructing the invaded blood vessels *in vitro*[5,14]. Oldhafer *et al*[16] proposed *in situ* hepatic resection and allotransplantation, which facilitate safe and complex revascularization of hepatic lesions that cannot be treated by combined liver surgery. Individual management of revascularization is challenging and crucial for patient prognosis[5].

Sometimes, the defects in the key blood vessels of the healthy side of the liver are too extensive to be repaired and recreated *in vivo* due to the substantial invasion of end-stage hepatic AE lesions. Therefore, selecting and obtaining proper materials for blood vascular repair is more difficult in ELRA compared with that in allotransplantation. Our center has reported 24 cases of ELRA with revascularization using LTH between August 2010 and October 2018[6]. We have also reported cases of using other vessels, such as internal jugular veins, iliac veins, or artificial vessels, as vascular substitutes [4,5]. However, only a few studies have reported complex revascularization using multiple materials.

In this study, due to the significant area of IVC invasion in the patient, a single vascular material was insufficient for repair and reconstruction. Moreover, blood vessel bank or donation after cardiac death (DCD) vessels was not available during the surgery. In this case, using a range of vascular substitutes that have been proven to be safe was the final option for reconstructing the IVC because of several reasons. Using artificial blood vessels increases the risk of thrombosis and failure of vascular repair and reconstruction[17]. Using a DCD vascular graft requires a blood vessel bank, which is not available in all centers. Autologous vascular grafts are used for vascular reconstruction. Many studies have shown the safety of IVC repair with various autologous venous grafts in allotransplantation[18,19]. The acquisition of autologous

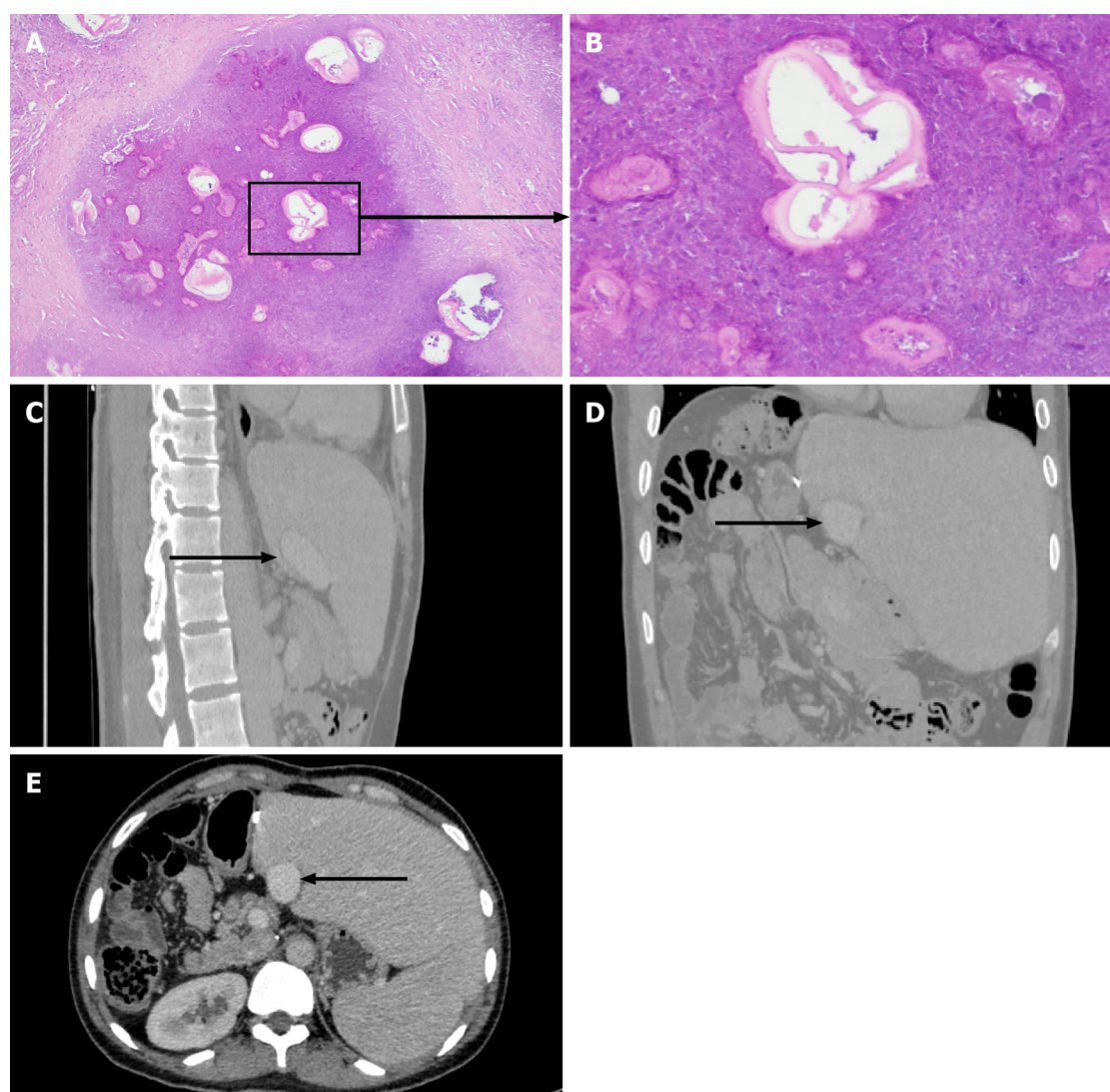


DOI: 10.12998/wjcc.v11.i23.5602 Copyright ©The Author(s) 2023.

**Figure 1** Preoperative imaging examination and surgical procedure. A: Preoperative enhanced computed tomography (CT) scan shows the inferior vena cava (IVC) invaded by the lesion. The black arrow indicates IVC; B: A Preoperative enhanced CT scan shows the hepatic alveolar echinococcosis (AE) lesion located in the right posterior lobe and the caudate lobe of the liver. The black arrow indicates a hepatic AE lesion; C: Ex vivo liver resection and autotransplantation (ELRA) for the treatment of hepatic end-stage AE. The black arrow indicates the lesion; D: Reconstruct the hepatic IVC with artificial vessels to perform a temporary portal shunt; E: Using disease-free IVC and the umbilical vein within the ligamentum teres hepatis (LTH) to reconstruct the IVC. The black arrow indicates the umbilical vein within the LTH; F: Using disease-free IVC and part of the portal vein (PV) to reconstruct the IVC. The black arrow indicates the PV; G: The IVC was replanted back into the abdominal cavity after complex reconstruction; H: After meticulous dissection, the left lateral lobes were replanted back into the abdominal cavity.

vein grafts in other parts of the patient's body, such as the saphenous vein, and internal jugular vein, require local surgery and cause additional donor-area trauma to the patient. The use of perihepatic vessels, such as LTH and PV, can prevent additional donor-area trauma to the patient and the occurrence of revascularization-related complications because of similar blood vessel endothelium. The patient's safety was preliminarily validated during the long-term follow-up and no vascular stenosis, thrombosis, or other complications were reported. This study and all previous studies have shown that complex vascular reconstruction, a key technique, opens up new possibilities for the successful implementation of liver transplantation, both liver transplantation and ELRA.





DOI: 10.12998/wjcc.v11.i23.5602 Copyright ©The Author(s) 2023.

**Figure 2 Pathology of alveolar echinococcosis and long-term follow up 7 years after surgery.** A: Lesions of hepatic alveolar echinococcosis (AE) (hematoxylin and eosin,  $\times 10$ ); B: Lesions of hepatic AE (hematoxylin and eosin,  $\times 40$ ). Long-term follow-up abdominal computed tomography (CT) shows the morphology of the reconstructed inferior vena cava (IVC) in the coronal plane, sagittal plane, and cross-section at 84 mo post-surgery; C-E: The black arrow indicates the reconstructed IVC.

Herein, we reviewed three previous cases with lesions that severely invaded the hepatic IVC and required complex IVC reconstruction. A total of 3 studies with detailed descriptions of 3 cases of complex reconstruct IVC in ELRA were found[20-22]. Table 2 presents the detailed data of these studies (Table 2). Based on the specific data obtained from these studies, the methods for complex reconstruction of the IVC in ELRA were summarized and analyzed. Of the 3 studies, 2 studies were reported from China, and 1 study was from the United Kingdom. These studies reported the complex reconstruction of the IVC in three patients during ELRA. In all three patients, two or more types of blood vessels except IVC were used to reconstruct IVC. The two studies from China reported two patients with hepatic AE who underwent ELRA with the IVC reconstruction. In one patient, the disease-free hepatic IVC, bilateral autologous saphenous veins, and unilateral common iliac vein were used for reconstruction, whereas in the other patient, the bilateral saphenous, inferior, and middle HV, inferior mesenteric vein, and a portion of the lateral wall of the hepatic IVC were used. The United Kingdom study reported a patient with intrahepatic smooth muscle sarcoma during ELRA. The complex reconstruction of the IVC was performed using the left iliac vein of 2 deceased donors and an autologous disease-free IVC from the patient. The postoperative prognosis was good and IVC revascularization-related complications did not occur in all the patients.

IVC invasion, huge lesions in the central location, and lesions near the IVC and HV junction are not suitable for surgical resection, and untreated patients have a dismal prognosis[23]. The patient reported in this study benefited from an extracorporeal technique of ELRA and underwent complex revascularization. *Ex vivo* surgery with complicated revascularization is a complex and challenging technique, which is a new possible treatment for patients with end-stage hepatic AE for whom other conventional treatment options are not available.

**Table 2 Detailed features of all published cases of complex reconstruction of inferior vena cava**

Ref.	Country	Diagnose	Cases	Complex reconstruction of IVC	Reconstructive method	Complications associated with outflow tract reconstruction	Survival
Jiayong <i>et al</i> [20], 2015	China	Alveolar echinococcosis	1	1	Bilateral great saphenous vein, part of the retro hepatic inferior vena and the middle hepatic vein, the inferior mesenteric vein, part of the infra hepatic vena cava	Not mentioned	1
Hu <i>et al</i> [21], 2016	China	Alveolar echinococcosis	12	1	Disease-free RHIVC, bilateral autogenous great saphenous veins, unilateral common iliac vein	Not mentioned	11
Buchholz <i>et al</i> [22], 2020	United Kingdom	Intrahepatic Caval Leiomyosarcoma	1	1	2 caval grafts and the left iliac vein of the graft	Not mentioned	1

IVC: Inferior vena cava; RHIVC: Retrohepatic inferior vena cava.

The present study has certain limitations. This is a retrospective study of a new case report and 3 previous case reports. Due to the small sample size of this study, future studies with more cases and longer follow-ups should investigate the long-term complications of complex revascularization to verify the safety and feasibility of complex revascularization techniques.

## CONCLUSION

To conclude, we showed that complex IVC reconstruction using autogenous multi-vein fragments is feasible and has a good prognosis during ELRA in patients with end-stage hepatic AE. The use of autologous perihepatic vessels prevents donor-area trauma, immune rejection, and other adverse reactions. When the blood vessel is severely invaded and a single vascular material cannot repair and reconstruct the defect, ELRA may provide a safe and feasible surgical approach for revascularization, which has good prospects for clinical application.

## FOOTNOTES

**Author contributions:** Humaerhan J and Jiang TM contributed to manuscript writing and editing, and data collection; Aji T and Shao YM contributed to data analysis; Wen H contributed to conceptualization and supervision; all authors have read and approved the final manuscript.

**Supported by** Key Laboratory Opening Topic Fund Subsidization: The Regulation of Sympathetic Nerve in Liver Regeneration in Hepatic Alveolar Echinococcosis, No. 2021D04024.

**Informed consent statement:** Informed written consent was obtained from the patient for publication of this report and any accompanying images.

**Conflict-of-interest statement:** All the authors declare that they have no conflict of interest to disclose.

**CARE Checklist (2016) statement:** The authors have read the CARE Checklist (2016), and the manuscript was prepared and revised according to the CARE Checklist (2016).

**Open-Access:** This article is an open-access article that was selected by an in-house editor and fully peer-reviewed by external reviewers. It is distributed in accordance with the Creative Commons Attribution NonCommercial (CC BY-NC 4.0) license, which permits others to distribute, remix, adapt, build upon this work non-commercially, and license their derivative works on different terms, provided the original work is properly cited and the use is non-commercial. See: <https://creativecommons.org/licenses/by-nc/4.0/>

**Country/Territory of origin:** China

**ORCID number:** Jiayidaer Humaerhan 0000-0003-4404-9220; Tie-Min Jiang 0000-0002-6100-1870; Tuerganaili Aji 0000-0001-6737-8874; Ying-Mei Shao 0000-0001-5154-345X; Hao Wen 0000-0002-8407-0369.

**S-Editor:** Liu JH

**L-Editor:** A

## REFERENCES

- 1 Wen H, Vuitton L, Tuxun T, Li J, Vuitton DA, Zhang W, McManus DP. Echinococcosis: Advances in the 21st Century. *Clin Microbiol Rev* 2019; **32** [PMID: 30760475 DOI: 10.1128/CMR.00075-18]
- 2 Kern P, Menezes da Silva A, Akhan O, Müllhaupt B, Vizcaychipi KA, Budke C, Vuitton DA. The Echinococcoses: Diagnosis, Clinical Management and Burden of Disease. *Adv Parasitol* 2017; **96**: 259-369 [PMID: 28212790 DOI: 10.1016/bs.apar.2016.09.006]
- 3 Wen H, Dong JH, Zhang JH, Zhao JM, Shao YM, Duan WD, Liang YR, Ji XW, Tai QW, Aji T, Li T. Ex vivo liver resection followed by autotransplantation for end-stage hepatic alveolar echinococcosis. *Chin Med J (Engl)* 2011; **124**: 2813-2817 [PMID: 22040485]
- 4 Wen H, Dong JH, Zhang JH, Duan WD, Zhao JM, Liang YR, Shao YM, Ji XW, Tai QW, Li T, Gu H, Tuxun T, He YB, Huang JF. Ex Vivo Liver Resection and Autotransplantation for End-Stage Alveolar Echinococcosis: A Case Series. *Am J Transplant* 2016; **16**: 615-624 [PMID: 26460900 DOI: 10.1111/ajt.13465]
- 5 Aji T, Dong JH, Shao YM, Zhao JM, Li T, Tuxun T, Shalayiadang P, Ran B, Jiang TM, Zhang RQ, He YB, Huang JF, Wen H. Ex vivo liver resection and autotransplantation as alternative to allotransplantation for end-stage hepatic alveolar echinococcosis. *J Hepatol* 2018; **69**: 1037-1046 [PMID: 30031886 DOI: 10.1016/j.jhep.2018.07.006]
- 6 Jiang T, Ran B, Guo Q, Zhang R, Duan S, Zhong K, Wen H, Shao Y, Aji T. Use of the ligamentum teres hepatis for outflow reconstruction during ex vivo liver resection and autotransplantation in patients with hepatic alveolar echinococcosis: A case series of 24 patients. *Surgery* 2021; **170**: 822-830 [PMID: 33994007 DOI: 10.1016/j.surg.2021.03.040]
- 7 Jiang T, Aji T, Wang Z, Bo R, Guo Q, Zhang R, Tuerger T, Zhong K, Shao Y, Wen H. Reconstruction of hepatic venous outflow and management of its complications using ex vivo liver resection and autotransplantation: a single-center experience. *Expert Rev Gastroenterol Hepatol* 2022; **16**: 279-287 [PMID: 35094615 DOI: 10.1080/17474124.2022.2036123]
- 8 Hwang R, Liou P, Kato T. Ex vivo liver resection and autotransplantation: An emerging option in selected indications. *J Hepatol* 2018; **69**: 1002-1003 [PMID: 30243765 DOI: 10.1016/j.jhep.2018.09.005]
- 9 Zhang Y, Lai ECH, Yang C, Yang H, Liu J, Zhou G, Xian D, Deng S, Lau WY. In situ reconstruction of vascular inflow/outflow to left lateral liver section, ex-vivo liver resection and autologous liver transplantation of remaining liver remnant for hepatic alveolar echinococcosis. *Int J Surg Case Rep* 2020; **69**: 39-43 [PMID: 32251986 DOI: 10.1016/j.ijscr.2020.03.023]
- 10 Yang X, Qiu Y, Huang B, Wang W, Shen S, Feng X, Wei Y, Lei J, Zhao J, Li B, Wen T, Yan L. Novel techniques and preliminary results of ex vivo liver resection and autotransplantation for end-stage hepatic alveolar echinococcosis: A study of 31 cases. *Am J Transplant* 2018; **18**: 1668-1679 [PMID: 29232038 DOI: 10.1111/ajt.14621]
- 11 Kato T, Hwang R, Liou P, Weiner J, Griesemer A, Samstein B, Halazun K, Mathur A, Schwartz G, Cherqui D, Emond J. Ex Vivo Resection and Autotransplantation for Conventionally Unresectable Tumors - An 11-year Single Center Experience. *Ann Surg* 2020; **272**: 766-772 [PMID: 32833756 DOI: 10.1097/SLA.0000000000004270]
- 12 Yang X, Wang T, Kong J, Huang B, Wang W. Resection of retrohepatic inferior vena cava without reconstruction in ex vivo liver resection and autotransplantation: a retrospective study. *BMC Surg* 2020; **20**: 56 [PMID: 32209078 DOI: 10.1186/s12893-020-00720-z]
- 13 Qiu Y, Yang X, Shen S, Huang B, Wang W. Vascular infiltration-based surgical planning in treating end-stage hepatic alveolar echinococcosis with ex vivo liver resection and autotransplantation. *Surgery* 2019; **165**: 889-896 [PMID: 30591376 DOI: 10.1016/j.surg.2018.11.007]
- 14 Yang C, Yang HJ, Deng SP, Zhang Y. Current status of ex-vivo liver resection and autologous liver transplantation for end-stage hepatic alveolar echinococcosis. *Ann Palliat Med* 2020; **9**: 2271-2278 [PMID: 32576011 DOI: 10.21037/apm-20-184]
- 15 Chui AK, Island ER, Rao AR, Lau WY. The longest survivor and first potential cure of an advanced cholangiocarcinoma by ex vivo resection and autotransplantation: a case report and review of the literature. *Am Surg* 2003; **69**: 441-444 [PMID: 12769220 DOI: 10.1177/000313480306900517]
- 16 Oldhafer KJ, Lang H, Schlitt HJ, Hauss J, Raab R, Klempnauer J, Pichlmayr R. Long-term experience after ex situ liver surgery. *Surgery* 2000; **127**: 520-527 [PMID: 10819060 DOI: 10.1067/msy.2000.105500]
- 17 Thorat A, Jeng LB, Yang HR, Li PC, Li ML, Yeh CC, Chen TH, Hsu SC, Poon KS. Outflow reconstruction for right liver allograft with multiple hepatic veins: "V-plasty" of hepatic veins to form a common outflow channel versus 2 or more hepatic vein-to-inferior vena cava anastomoses in limited retrohepatic space. *Liver Transpl* 2016; **22**: 192-200 [PMID: 26390259 DOI: 10.1002/lt.24342]
- 18 Lee SG. Techniques of reconstruction of hepatic veins in living-donor liver transplantation, especially for right hepatic vein and major short hepatic veins of right-lobe graft. *J Hepatobiliary Pancreat Surg* 2006; **13**: 131-138 [PMID: 16547674 DOI: 10.1007/s00534-005-1019-7]
- 19 Quinones-Baldrich W, Alktaifi A, Eilber F. Inferior vena cava resection and reconstruction for retroperitoneal tumor excision. *J Vasc Surg* 2012; **55**: 1386-93; discussion 1393 [PMID: 22386140 DOI: 10.1016/j.jvs.2011.11.054]
- 20 Jianyong L, Jingcheng H, Wentao W, Lunan Y, Jichun Z, Bing H, Ding Y. Ex vivo liver resection followed by autotransplantation to a patient with advanced alveolar echinococcosis with a replacement of the retrohepatic inferior vena cava using autogenous vein grafting: a case report and literature review. *Medicine (Baltimore)* 2015; **94**: e514 [PMID: 25700312 DOI: 10.1097/MD.0000000000000514]
- 21 Hu H, Huang B, Zhao J, Wang W, Guo Q, Ma Y. Liver autotransplantation and retrohepatic vena cava reconstruction for alveolar echinococcosis. *J Surg Res* 2017; **210**: 169-176 [PMID: 28457324 DOI: 10.1016/j.jss.2016.11.023]
- 22 Buchholz BM, Pinter Carvalheiro da Silva Boteon A, Taniere P, Isaac JR, Gourevitch D, Muiesan P. Autotransplantation of the Liver for Ex Vivo Resection of Intrahepatic Caval Leiomyosarcoma: A Case Report. *Exp Clin Transplant* 2020; **18**: 396-401 [PMID: 30880647 DOI: 10.6002/ect.2018.0183]
- 23 Baker MA, Maley WR, Needleman L, Doria C. Ex vivo resection of hepatic neoplasia and autotransplantation: a case report and review of the literature. *J Gastrointest Surg* 2015; **19**: 1169-1176 [PMID: 25820488 DOI: 10.1007/s11605-015-2806-3]





Published by **Baishideng Publishing Group Inc**  
7041 Koll Center Parkway, Suite 160, Pleasanton, CA 94566, USA

**Telephone:** +1-925-3991568

**E-mail:** [bpgoffice@wjgnet.com](mailto:bpgoffice@wjgnet.com)

**Help Desk:** <https://www.f6publishing.com/helpdesk>

<https://www.wjgnet.com>

