

# World Journal of *Clinical Cases*

*World J Clin Cases* 2023 August 26; 11(24): 5628-5839



## MINIREVIEWS

- 5628 Effect of pesticides on phosphorylation of tau protein, and its influence on Alzheimer's disease  
*Torres-Sánchez ED, Ortiz GG, Reyes-Urbe E, Torres-Jasso JH, Salazar-Flores J*

## ORIGINAL ARTICLE

## Case Control Study

- 5643 Reduction rate of monoclonal protein as a useful prognostic factor in standard-risk group of newly diagnosed multiple myeloma  
*Liu M, Zhang JY*

## Retrospective Cohort Study

- 5653 Effectiveness of treating menorrhagia using microwave endometrial ablation at a frequency of 2.45 GHz  
*Kakinuma T, Kaneko A, Kakinuma K, Matsuda Y, Yanagida K, Takeshima N, Ohwada M*
- 5660 Benefits of laparoscopy-assisted ileostomy in colorectal cancer patients with bowel obstruction  
*Wang YJ, Lin KH, Kang JC, Hu JM, Chen CY, Pu TW*

## Retrospective Study

- 5666 Hypopharyngeal cancer trends in a high-incidence region: A retrospective tertiary single center study  
*Cordunianu AGV, Ganea G, Cordunianu MA, Cochior D, Moldovan CA, Adam R*
- 5678 Relevant detection indicator of prethrombotic state in patients with primary hypertension  
*Luo J, Yang T, Ding L, Xiong JH, Ying T, Xu F*
- 5692 Clinical study of extrahepatic biliary adenoma  
*Li W, Tao J, Song XG, Hou MR, Qu K, Gu JT, Yan XP, Yao BW, Qin YF, Dong FF, Sha HC*

## SYSTEMATIC REVIEWS

- 5700 Sodium-glucose cotransporter-2 inhibitor-associated euglycemic diabetic ketoacidosis in COVID-19-infected patients: A systematic review of case reports  
*Khedr A, Hennawi HA, Khan MK, Eissa A, Mir M, Rauf I, Nitesh J, Surani S, Khan SA*

## META-ANALYSIS

- 5710 Efficacy and safety of Huangqi Jianzhong decoction in the treatment of chronic atrophic gastritis: A meta-analysis  
*Yan XP, Si W, Ding MS, Tian YF, Guo Z*

## CASE REPORT

- 5721** Malignant melanoma of the prostate: Primary or metastasis? A case report  
*Zhao H, Liu C, Li B, Guo JM*
- 5729** Intravenous leiomyoma of the uterus extending to the pulmonary artery: A case report  
*Huang YQ, Wang Q, Xiang DD, Gan Q*
- 5736** Percutaneous endoscopic necrosectomy for walled-off necrosis in the retroperitoneal space of the elderly: A case report  
*Sato K, Shibukawa G, Ueda K, Nakajima Y, Togashi K, Ohira H*
- 5742** Acute exacerbation of idiopathic pulmonary fibrosis treated using the Feibi recipe: Two case reports  
*Liu ZH, Li GD, Hao QX, Cao F, Cheng Y, Kou MJ, Jiao Y*
- 5749** Neonatal erythema multiforme associated with a rotavirus infection: A case report  
*Kim JJ, Lee JK*
- 5755** Hemorrhagic Bartholin's cyst in a woman using anti-platelet medication: A case report and review of the literature  
*Li YR, Ding DC*
- 5762** Subintimal recanalization for non-acute occlusion of intracranial vertebral artery in an emergency endovascular procedure: A case report  
*Fu JF, Zhang XL, Lee SY, Zhang FM, You JS*
- 5772** Synchronous rectal adenocarcinoma and intestinal mantle cell lymphoma: A case report  
*Vu KV, Trong NV, Khuyen NT, Huyen Nga D, Anh H, Tien Trung N, Trung Thong P, Minh Duc N*
- 5780** Focal lymphoblastic transformation of chronic myelogenous leukemia develops into erythroid leukemia: A case report  
*Wang W, Chen YL, Gou PP, Wu PL, Shan KS, Zhang DL*
- 5789** Intraoperative sudden arrhythmias in cervical spine surgery adjacent to the stellate ganglion: A case report  
*Seo JH, Cho SY, Park JH, Seo JY, Lee HY, Kim DJ*
- 5797** Papillary thyroid carcinoma with nodular fasciitis-like stroma - an unusual variant with distinctive histopathology: A case report  
*Hu J, Wang F, Xue W, Jiang Y*
- 5804** Malignant form of hidroacanthoma simplex: A case report  
*Yang YF, Wang R, Xu H, Long WG, Zhao XH, Li YM*
- 5811** Penile and scrotal strangulation by stainless steel rings in an human immunodeficiency virus positive man: A case report  
*Usuda D, Kaminishi N, Kato M, Sugawara Y, Shimizu R, Inami T, Tsuge S, Sakurai R, Kawai K, Matsubara S, Tanaka R, Suzuki M, Shimozawa S, Hotchi Y, Osugi I, Katou R, Ito S, Mishima K, Kondo A, Mizuno K, Takami H, Komatsu T, Oba J, Nomura T, Sugita M*

- 5817** Persistent postoperative hypotension caused by subclinical empty sella syndrome after a simple surgery: A case report  
*Zhao KM, Hu JS, Zhu SM, Wen TT, Fang XM*
- 5823** Rare *ROS1-CENPW* gene in pancreatic acinar cell carcinoma and the effect of crizotinib plus AG chemotherapy: A case report  
*Wang T, Shen YY*
- 5830** Fecal transplantation in patient with metastatic melanoma refractory to immunotherapy: A case report  
*del Giglio A, Atui FC*
- 5835** Left hepatic artery pseudoaneurysm complicating endoscopic retrograde cholangiopancreatography: A case report  
*Li QM, Ye B, Yang SW, Zhao H*

**ABOUT COVER**

Editorial Board Member of *World Journal of Clinical Cases*, Kelser de Souza Kock, PhD, Physiotherapist, Professor, Department of Physiotherapy/Medicine, University of South of Santa Catarina, Tubarão 88700000, SC, Brazil. [kelserkock@yahoo.com.br](mailto:kelserkock@yahoo.com.br)

**AIMS AND SCOPE**

The primary aim of *World Journal of Clinical Cases* (*WJCC*, *World J Clin Cases*) is to provide scholars and readers from various fields of clinical medicine with a platform to publish high-quality clinical research articles and communicate their research findings online.

*WJCC* mainly publishes articles reporting research results and findings obtained in the field of clinical medicine and covering a wide range of topics, including case control studies, retrospective cohort studies, retrospective studies, clinical trials studies, observational studies, prospective studies, randomized controlled trials, randomized clinical trials, systematic reviews, meta-analysis, and case reports.

**INDEXING/ABSTRACTING**

The *WJCC* is now abstracted and indexed in Science Citation Index Expanded (SCIE, also known as SciSearch®), Journal Citation Reports/Science Edition, Current Contents®/Clinical Medicine, PubMed, PubMed Central, Reference Citation Analysis, China National Knowledge Infrastructure, China Science and Technology Journal Database, and Superstar Journals Database. The 2023 Edition of Journal Citation Reports® cites the 2022 impact factor (IF) for *WJCC* as 1.1; IF without journal self cites: 1.1; 5-year IF: 1.3; Journal Citation Indicator: 0.26; Ranking: 133 among 167 journals in medicine, general and internal; and Quartile category: Q4.

**RESPONSIBLE EDITORS FOR THIS ISSUE**

Production Editor: *Ying-Yi Yuan*; Production Department Director: *Xu Guo*; Editorial Office Director: *Jin-Lei Wang*.

**NAME OF JOURNAL**

*World Journal of Clinical Cases*

**ISSN**

ISSN 2307-8960 (online)

**LAUNCH DATE**

April 16, 2013

**FREQUENCY**

Thrice Monthly

**EDITORS-IN-CHIEF**

Bao-Gan Peng, Jerzy Tadeusz Chudek, George Kontogeorgos, Maurizio Serati, Ja Hyeon Ku

**EDITORIAL BOARD MEMBERS**

<https://www.wjgnet.com/2307-8960/editorialboard.htm>

**PUBLICATION DATE**

August 26, 2023

**COPYRIGHT**

© 2023 Baishideng Publishing Group Inc

**INSTRUCTIONS TO AUTHORS**

<https://www.wjgnet.com/bpg/gerinfo/204>

**GUIDELINES FOR ETHICS DOCUMENTS**

<https://www.wjgnet.com/bpg/GerInfo/287>

**GUIDELINES FOR NON-NATIVE SPEAKERS OF ENGLISH**

<https://www.wjgnet.com/bpg/gerinfo/240>

**PUBLICATION ETHICS**

<https://www.wjgnet.com/bpg/GerInfo/288>

**PUBLICATION MISCONDUCT**

<https://www.wjgnet.com/bpg/gerinfo/208>

**ARTICLE PROCESSING CHARGE**

<https://www.wjgnet.com/bpg/gerinfo/242>

**STEPS FOR SUBMITTING MANUSCRIPTS**

<https://www.wjgnet.com/bpg/GerInfo/239>

**ONLINE SUBMISSION**

<https://www.f6publishing.com>



## Fecal transplantation in patient with metastatic melanoma refractory to immunotherapy: A case report

Auro del Giglio, Fabio Cesar Atui

**Specialty type:** Oncology

**Provenance and peer review:**

Unsolicited article; Externally peer reviewed.

**Peer-review model:** Single blind

**Peer-review report's scientific quality classification**

Grade A (Excellent): A

Grade B (Very good): B

Grade C (Good): C

Grade D (Fair): 0

Grade E (Poor): 0

**P-Reviewer:** Qin Y, China;  
Safarzadeh Kozani P, Iran

**Received:** June 18, 2023

**Peer-review started:** June 18, 2023

**First decision:** July 4, 2023

**Revised:** July 5, 2023

**Accepted:** July 25, 2023

**Article in press:** July 25, 2023

**Published online:** August 26, 2023



**Auro del Giglio**, Department of Oncology, Faculdade de Medicina da Fundação ABC, Santo André 09060-870, São Paulo, Brazil

**Fabio Cesar Atui**, Department of Endoscopy, Hospital Sirio Libanês, São Paulo 01308-050, São Paulo, Brazil

**Corresponding author:** Auro del Giglio, MD, Professor, Department of Oncology, Faculdade de Medicina da Fundação ABC, Avenida Príncipe de Gales 821, Santo André 09060-870, São Paulo, Brazil. [aurodelgiglio@gmail.com](mailto:aurodelgiglio@gmail.com)

### Abstract

#### BACKGROUND

Immunotherapy has revolutionized the treatment of metastatic melanoma, but a significant proportion of patients still experience treatment resistance. Fecal microbiota transplantation (FMT) has emerged as a potential strategy to overcome immunotherapy resistance by modulating the gut microbiome.

#### CASE SUMMARY

We present a case report of a 57-year-old male with metastatic melanoma refractory to immunotherapy who received FMT in combination with anti-programmed death-ligand 1 (PD-L1) immunotherapy (pembrolizumab). After failing multiple lines of treatment, the patient underwent a single FMT procedure by colonoscopy using fecal material from a female metastatic melanoma donor who successfully responded to immunotherapy. Following FMT, the patient demonstrated a response with decreased subcutaneous disease and subsequently underwent surgery to remove the residual disease. Despite a subsequent recurrence in the small bowel that was resected, the patient remained on pembrolizumab without evidence of melanoma recurrence at the time of writing.

#### CONCLUSION

The favorable clinical and long-lasting effect we saw in our patient without significant toxicity suggests that this procedure should be considered in similar patients with immunotherapy refractory melanomas.

**Key Words:** Melanoma; Fecal microbiota transplantation; Immunotherapy resistance; Metastatic melanoma; Gut microbiome; Cancer; Case report

©The Author(s) 2023. Published by Baishideng Publishing Group Inc. All rights reserved.

**Core Tip:** This case report highlights the use of fecal microbiota transplantation (FMT) as a potential strategy to overcome immunotherapy resistance in metastatic melanoma patients. The case involves a 57-year-old male who had failed multiple lines of treatment and received FMT alongside anti-programmed death-ligand 1 immunotherapy. Following FMT, the patient showed a response with a decrease in disease burden and remained on immunotherapy more than two years. This suggests that FMT may restore sensitivity to immunotherapy in refractory cases. Further research is needed to understand the underlying mechanisms and optimize treatment protocols for FMT in metastatic melanoma.

**Citation:** del Giglio A, Atui FC. Fecal transplantation in patient with metastatic melanoma refractory to immunotherapy: A case report. *World J Clin Cases* 2023; 11(24): 5830-5834

**URL:** <https://www.wjgnet.com/2307-8960/full/v11/i24/5830.htm>

**DOI:** <https://dx.doi.org/10.12998/wjcc.v11.i24.5830>

## INTRODUCTION

Melanoma accounted for 325000 new cases worldwide, causing about 57000 deaths in 2020[1], affecting males more frequently than females. It is estimated that Melanoma cases should increase by 50% in 2040, reaching 510000 new cases and 96000 deaths[1]. Despite the recent remarkable advances in the treatment of metastatic melanoma with immunotherapy and anti-Braf targeted therapies, about 40% of the patients will still die of their disease[2,3].

One possibility treating immune-refractory patients with metastatic melanoma is the manipulation of the gut microbiome through Fecal Microbiota Transplantation (FMT)[4-6]. FMT can restore sensitivity to anti-programmed death-ligand 1 (anti-PD-L1) immunotherapy in about 40% of patients previously refractory to this medication[5,6]. Based on these encouraging preliminary data[5,6], we report here a case of a 57-year-old patient refractory to immunotherapy who benefited from FMT added to anti-PD-L1 immunotherapy with Pembrolizumab, which he was previously refractory to.

## CASE PRESENTATION

### Chief complaints

We report the case of a 57-year-old man with metastatic BRAF V-600E mutated melanoma diagnosed in October 2019 and started on Nivolumab with a partial response.

### History of present illness

The patient presented with intense musculoskeletal pain at the site of the bony metastasis in his right hip.

### History of past illness

The patient had a previous history of a desmoid tumor controlled by surgery and a bariatric surgery, without any other relevant past medical history.

### Personal and family history

No relevant past family history.

### Physical examination

Right inguinal lymphadenopathy, right axillar lymphadenopathy and atrophy of the right shoulder muscles (due to previous desmoid surgery) with no other relevant physical findings.

### Laboratory examinations

Normal blood cell count and biochemical profile.

### Imaging examinations

Computed tomography scan showed right axillary lymphadenopathy and right iliac bone metastasis.

## FINAL DIAGNOSIS

Metastatic malignant melanoma. Tissue was obtained from a percutaneous biopsy of the right axillary lymphadenopathy.

## TREATMENT

Nivolumab with a partial response.

## OUTCOME AND FOLLOW-UP

In October 2020, we noted disease progression of the melanoma in the subcutaneous tissue of the right thoracic region, and we started Cobimetinib and Vemurafenib without a response. In December 2020, we started Ipilimumab plus Pembrolizumab with a new progression. The Pembrolizumab was maintained, and in April 2021, he received only FMT by colonoscopy without prior antibiotic therapy. Fecal material was obtained from a female metastatic melanoma patient donor who achieved a longstanding complete response to Ipilimumab and Nivolumab and was off therapy in remission for more than 2 years. The donor had an entirely negative pre-donation screen for multiple infectious agents. The patient and donor formally consented to the FMT procedure.

After FMT, as seen in [Figure 1](#), the right lateral thoracic subcutaneous disease decreased in size while we maintained Pembrolizumab. In September 2021, the patient underwent surgery to remove the residual disease. In July 2022, he had a PET scan that showed a small intestinal loop with increased FDG uptake, and we also noted a decrease in the ferritin level. A small intestinal survey with an endoscopic capsule revealed an abnormality in the small intestine judged as a melanoma recurrence which was resected and confirmed by the pathological report. As there were no other foci of disease, we maintained Pembrolizumab until this writing (June 23, 2023) and the patient is presently in remission without evidence of melanoma recurrence.

## DISCUSSION

The gut microbiome represents a highly dynamic environment where diet, medication intake, or emotional stress can induce significant changes[7]. There are strong correlations between the gut microbiome and the nervous and immune systems[7]. Intestinal dysbiosis occurs when there is a disturbance in the complex commensal microbial communities in the digestive tract, including the overgrowth of certain microorganisms (*e.g.*, bacteria or fungi). Existing evidence has shown that gut dysbiosis may contribute to the etiology of numerous human diseases[7,8], including diabetes, atherosclerosis, inflammatory bowel disease, atopic dermatitis, autism, or even cancer development. Furthermore, mice with tumors but no gut microbiome showed different responses when treated with cancer immunotherapy[7,8].

Several authors showed that FMT could circumvent immunotherapy resistance in metastatic melanoma patients rendering about 30% of them susceptible again to anti-PD1 agents to which they were resistant[4,5]. The mechanism whereby FMT can restore sensitivity to anti-PD1 monoclonal antibodies is not completely understood. Davar *et al*[5] demonstrated that FMT induced rapid and durable changes in the gut microbiota. The responders showed increased abundance of certain taxa associated with response to anti-PD-1, increased activation of CD8+ T cells with higher cytolytic functions, and decreased frequency of interleukin-8-expressing myeloid cells which may have immunosuppressive activity. Proteomic and metabolomic analyses revealed distinct signatures in the responders, and network analyses confirmed that the gut microbiome regulated these changes[5]. In addition, Baruch *et al*[4] reported that gut sample analysis demonstrated post-treatment up-regulation of gene sets related to adenomatous polyposis colitis *via* major histocompatibility complex (MHC) class 1 and IL-1 mediated signaling. Furthermore, tumor sample analysis showed post-treatment up-regulation of multiple immune-related gene sets (Interferon gamma-, T cell activation, MHC class II protein complex, dendritic cell differentiation, and T helper 1 type immune response)[4].

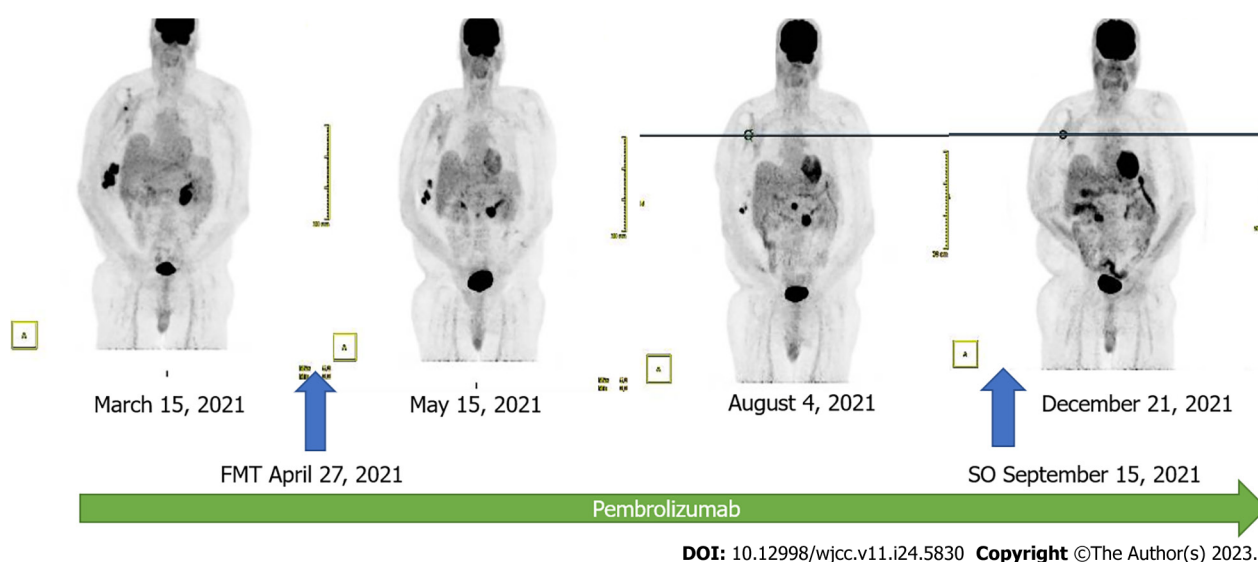
Our patient had disease resistant to Nivolumab, Pembrolizumab (anti-PD1 monoclonal antibodies), and Ipilimumab (an anti-CTLA4 monoclonal antibody). After FMT, Pembrolizumab, to which its disease was resistant, regained its effectivity, as seen by the decrease of his right lateral thoracic subcutaneous disease. We did only one FMT by colonoscopy without prior antibiotic treatment, as did Davar *et al*[5]. Baruch *et al*[4], however, did serial FMTs in the patients they treated by capsules or colonoscopy and used antibiotics pre-FMT. If more than one procedure is needed, whether colonoscopy or capsules may be the best way of doing the FMT, and if antibiotic pretreatment is needed, all require further research. In addition, both Davar *et al*[5] and Baruch *et al*[4] reported changes in the microbiome of patients who underwent FMT and did not show any significant toxicity due to this procedure.

This report has limitations. Besides the fact that we reported here one only case of restoring sensitivity to anti-PD1 treatment through FMT, we also did not pursue immunological studies or fecal microbiome analysis.

## CONCLUSION

Despite these limitations, the favorable clinical and long-lasting effect we saw in our patient without significant toxicity suggests that this procedure should be considered in similar patients with immunotherapy refractory melanomas.





**Figure 1** Time sequence of the fecal microbiota transplantation (FMT) and the following PET images with their dates. As can be seen the disease decreased in size after microbiota transplantation (FMT) showing that Pembrolizumab regained activity after the FMT procedure. Surgery done in September 2021, rendered the patient free of disease.

## FOOTNOTES

**Author contributions:** del Giglio A took clinical care of the patient and wrote the draft of the report; Atui FC did the FMT on the patient described the procedure for publication.

**Informed consent statement:** Informed consent was obtained from the patient to publish the report and associated images.

**Conflict-of-interest statement:** All the authors declare that they have no conflict of interest.

**CARE Checklist (2016) statement:** The authors have read the CARE Checklist (2016), and the manuscript was prepared and revised according to the CARE Checklist (2016).

**Open-Access:** This article is an open-access article that was selected by an in-house editor and fully peer-reviewed by external reviewers. It is distributed in accordance with the Creative Commons Attribution NonCommercial (CC BY-NC 4.0) license, which permits others to distribute, remix, adapt, build upon this work non-commercially, and license their derivative works on different terms, provided the original work is properly cited and the use is non-commercial. See: <https://creativecommons.org/licenses/by-nc/4.0/>

**Country/Territory of origin:** Brazil

**ORCID number:** Auro del Giglio 0000-0002-2009-824X.

**S-Editor:** Liu JH

**L-Editor:** A

**P-Editor:** Yu HG

## REFERENCES

- 1 Arnold M, Singh D, Laversanne M, Vignat J, Vaccarella S, Meheus F, Cust AE, de Vries E, Whiteman DC, Bray F. Global Burden of Cutaneous Melanoma in 2020 and Projections to 2040. *JAMA Dermatol* 2022; **158**: 495-503 [PMID: [35353115](#) DOI: [10.1001/jamadermatol.2022.0160](#)]
- 2 Switzer B, Puzanov I, Skitzki JJ, Hamad L, Ernstoff MS. Managing Metastatic Melanoma in 2022: A Clinical Review. *JCO Oncol Pract* 2022; **18**: 335-351 [PMID: [35133862](#) DOI: [10.1200/OP.21.00686](#)]
- 3 Wolchok JD, Chiarion-Sileni V, Gonzalez R, Grob JJ, Rutkowski P, Lao CD, Cowey CL, Schadendorf D, Wagstaff J, Dummer R, Ferrucci PF, Smylie M, Butler MO, Hill A, Márquez-Rodas I, Haanen JBAG, Guidoboni M, Maio M, Schöffski P, Carlino MS, Lebbé C, McArthur G, Ascierto PA, Daniels GA, Long GV, Bas T, Ritchings C, Larkin J, Hodi FS. Long-Term Outcomes With Nivolumab Plus Ipilimumab or Nivolumab Alone Versus Ipilimumab in Patients With Advanced Melanoma. *J Clin Oncol* 2022; **40**: 127-137 [PMID: [34818112](#) DOI: [10.1200/JCO.21.02229](#)]
- 4 Baruch EN, Youngster I, Ben-Betzalel G, Ortenberg R, Lahat A, Katz L, Adler K, Dick-Necula D, Raskin S, Bloch N, Rotin D, Anafi L, Avivi C, Melnichenko J, Steinberg-Silman Y, Mamtani R, Harati H, Asher N, Shapira-Frommer R, Brosh-Nissimov T, Eshet Y, Ben-Simon S, Ziv O, Khan MAW, Amit M, Ajami NJ, Barshack I, Schachter J, Wargo JA, Koren O, Markel G, Boursi B. Fecal microbiota transplant promotes response in immunotherapy-refractory melanoma patients. *Science* 2021; **371**: 602-609 [PMID: [33303685](#) DOI: [10.1126/science.abb5920](#)]

- 5 **Davar D**, Dzutsev AK, McCulloch JA, Rodrigues RR, Chauvin JM, Morrison RM, Deblasio RN, Menna C, Ding Q, Pagliano O, Zidi B, Zhang S, Badger JH, Vetizou M, Cole AM, Fernandes MR, Prescott S, Costa RGF, Balaji AK, Morgun A, Vujkovic-Cvijin I, Wang H, Borhani AA, Schwartz MB, Dubner HM, Ernst SJ, Rose A, Najjar YG, Belkaid Y, Kirkwood JM, Trinchieri G, Zarour HM. Fecal microbiota transplant overcomes resistance to anti-PD-1 therapy in melanoma patients. *Science* 2021; **371**: 595-602 [PMID: [33542131](#) DOI: [10.1126/science.abf3363](#)]
- 6 **Ferreira A**, Neves MT, Baleiras A, Malheiro M, Martins A. Fecal Microbiota Transplant in Immunotherapy-Resistant Melanoma: What Can We Expect in the Near Future? *Cureus* 2022; **14**: e32586 [PMID: [36654598](#) DOI: [10.7759/cureus.32586](#)]
- 7 **de Vos WM**, Tilg H, Van Hul M, Cani PD. Gut microbiome and health: mechanistic insights. *Gut* 2022; **71**: 1020-1032 [PMID: [35105664](#) DOI: [10.1136/gutjnl-2021-326789](#)]
- 8 **Durack J**, Lynch SV. The gut microbiome: Relationships with disease and opportunities for therapy. *J Exp Med* 2019; **216**: 20-40 [PMID: [30322864](#) DOI: [10.1084/jem.20180448](#)]



Published by **Baishideng Publishing Group Inc**  
7041 Koll Center Parkway, Suite 160, Pleasanton, CA 94566, USA

**Telephone:** +1-925-3991568

**E-mail:** [bpgoffice@wjgnet.com](mailto:bpgoffice@wjgnet.com)

**Help Desk:** <https://www.f6publishing.com/helpdesk>

<https://www.wjgnet.com>

