

World Journal of *Clinical Cases*

World J Clin Cases 2023 September 26; 11(27): 6318-6669



MINIREVIEWS

- 6318 Characteristics of amino acid metabolism in colorectal cancer

Xu F, Jiang HL, Feng WW, Fu C, Zhou JC

ORIGINAL ARTICLE**Clinical and Translational Research**

- 6327 Exploring the pharmacological mechanism of Wuzhuyu decoction on hepatocellular carcinoma using network pharmacology

Ouyang JY, Lin WJ, Dong JM, Yang Y, Yang HK, Zhou ZL, Wang RQ

- 6344 Identification of potential diagnostic and prognostic biomarkers for breast cancer based on gene expression omnibus

Zhang X, Mi ZH

Retrospective Cohort Study

- 6363 Treatment of proximal humeral fractures accompanied by medial calcar fractures using fibular autografts: A retrospective, comparative cohort study

Liu N, Wang BG, Zhang LF

Retrospective Study

- 6374 Effectiveness of out-fracture of the inferior turbinate with reduction nasal bone fracture

Kim SY, Nam HJ, Byeon JY, Choi HJ

- 6383 Prognostic model of hepatocellular carcinoma based on cancer grade

Zhang GX, Ding XS, Wang YL

- 6398 Oncologic efficacy of gonadotropin-releasing hormone agonist in hormone receptor-positive very young breast cancer patients treated with neoadjuvant chemotherapy

Choi HJ, Lee JH, Jung CS, Ryu JM, Chae BJ, Lee SK, Yu JH, Kim SW, Nam SJ, Lee JE, Jung YJ, Kim HY

- 6407 Correlation analysis of serum thyroglobulin, thyroid-stimulating hormone levels, and thyroid-cancer risk in thyroid nodule surgery

Shuai JH, Leng ZF, Wang P, Ji YC

- 6415 Closed thoracic drainage in elderly patients with chronic obstructive pulmonary disease complicated with spontaneous pneumothorax: A retrospective study

Wang W, Zhu DN, Shao SS, Bao J

Observational Study

- 6424 *Helicobacter pylori* eradication treatment for primary gastric diffuse large B-cell lymphoma: A single-center analysis

Saito M, Mori A, Kajikawa S, Yokoyama E, Kanaya M, Izumiyama K, Morioka M, Kondo T, Tanei ZI, Shimizu A

Prospective Study

- 6431** Effect of polyene phosphatidylcholine/ursodeoxycholic acid/ademetionine on pregnancy outcomes in intrahepatic cholestasis
Dong XR, Chen QQ, Xue ML, Wang L, Wu Q, Luo TF

SYSTEMATIC REVIEWS

- 6440** Maternal diaphragmatic hernia in pregnancy: A systematic review with a treatment algorithm
Augustin G, Kovač D, Karadjole VS, Zajec V, Herman M, Hrbač P

META-ANALYSIS

- 6455** Laparoscopic *vs* open radical resection in management of gallbladder carcinoma: A systematic review and meta-analysis
He S, Yu TN, Cao JS, Zhou XY, Chen ZH, Jiang WB, Cai LX, Liang X

CASE REPORT

- 6476** Acute acquired concomitant esotropia with congenital paralytic strabismus: A case report
Zhang MD, Liu XY, Sun K, Qi SN, Xu CL
- 6483** Tumor recurrence after pathological complete response in locally advanced gastric cancer after neoadjuvant therapy: Two case reports
Xing Y, Zhang ZL, Ding ZY, Song WL, Li T
- 6491** Acute peritonitis secondary to post-traumatic appendicitis: A case report and literature review
Habachi G, Aziza B, Ben-Ammar S, Maherzi O, Houas Y, Kerkeni Y, Sahli S, Jouini R
- 6498** Fournier's gangrene after insertion of thermo-expandable prostatic stent for benign prostatic hyperplasia: A case report
Jung HC, Kim YU
- 6505** Methyl-CpG-Binding protein 2 duplication syndrome in a Chinese patient: A case report and review of the literature
Xing XH, Takam R, Bao XY, Ba-alwi NA, Ji H
- 6515** Blood purification for treatment of non-liquefied multiple liver abscesses and improvement of T-cell function: A case report
Tang ZQ, Zhao DP, Dong AJ, Li HB
- 6523** Eosinophilic granulomatosis with polyangiitis, asthma as the first symptom, and subsequent Loeffler endocarditis: A case report
He JL, Liu XY, Zhang Y, Niu L, Li XL, Xie XY, Kang YT, Yang LQ, Cai ZY, Long H, Ye GF, Zou JX
- 6531** Left atrium veno-arterial extra corporeal membrane oxygenation as temporary mechanical support for cardiogenic shock: A case report
Lamastra R, Abbott DM, Degani A, Pellegrini C, Veronesi R, Pelenghi S, Dezza C, Gazzaniga G, Belliato M

- 6537** Successful treatment of eyebrow intradermal nevi by shearing combined with electrocautery and curettage: Two case reports
Liu C, Liang JL, Yu JL, Hu Q, Li CX
- 6543** Amniotic membrane mesenchymal stromal cell-derived secretome in the treatment of acute ischemic stroke: A case report
Lin FH, Yang YX, Wang YJ, Subbiah SK, Wu XY
- 6551** Managing spindle cell sarcoma with surgery and high-intensity focused ultrasound: A case report
Zhu YQ, Zhao GC, Zheng CX, Yuan L, Yuan GB
- 6558** Triplet regimen as a novel modality for advanced unresectable hepatocellular carcinoma: A case report and review of literature
Zhao Y, He GS, Li G
- 6565** Acute diquat poisoning case with multiorgan failure and a literature review: A case report
Fan CY, Zhang CG, Zhang PS, Chen Y, He JQ, Yin H, Gong XJ
- 6573** Fungal corneal ulcer after repair of an overhanging filtering bleb: A case report
Zhao J, Xu HT, Yin Y, Li YX, Zheng YJ
- 6579** Combination therapy with toripalimab and anlotinib in advanced esophageal squamous cell carcinoma: A case report
Chen SC, Ma DH, Zhong JJ
- 6587** Removal of a pulmonary artery foreign body during pulse ablation in a patient with atrial fibrillation: A case report
Yan R, Lei XY, Li J, Jia LL, Wang HX
- 6592** Delayed-onset *micrococcus luteus*-induced postoperative endophthalmitis several months after cataract surgery: A case report
Nam KY, Lee HW
- 6597** Anesthetic management of a pregnant patient with Eisenmenger's syndrome: A case report
Zhang Y, Wei TT, Chen G
- 6603** Recurrence of unilateral angioedema of the tongue: A case report
Matsuhisa Y, Kenzaka T, Shimizu H, Hirose H, Gotoh T
- 6613** Transverse mesocolic hernia with intestinal obstruction as a rare cause of acute abdomen in adults: A case report
Zhang C, Guo DF, Lin F, Zhan WF, Lin JY, Lv GF
- 6618** Compound heterozygous mutations in tripeptidyl peptidase 1 cause rare autosomal recessive spinocerebellar ataxia type 7: A case report
Liu RH, Wang XY, Jia YY, Wang XC, Xia M, Nie Q, Guo J, Kong QX

- 6624** Treatment of posterior interosseous nerve entrapment syndrome with ultrasound-guided hydrodissection: A case report
Qin LH, Cao W, Chen FT, Chen QB, Liu XX
- 6631** Rapidly growing extensive polypoid endometriosis after gonadotropin-releasing hormone agonist discontinuation: A case report
Zhang DY, Peng C, Huang Y, Cao JC, Zhou YF
- 6640** Preserving finger length in a patient with symmetric digital gangrene under local anesthesia: A case report
Kim KH, Ko IC, Kim H, Lim SY
- 6646** Reconstruction of the lower back wound with delayed infection after spinal surgery: A case report
Kim D, Lim S, Eo S, Yoon JS
- 6653** Solitary intraosseous neurofibroma in the mandible mimicking a cystic lesion: A case report and review of literature
Zhang Z, Hong X, Wang F, Ye X, Yao YD, Yin Y, Yang HY
- 6664** Complete response of metastatic *BRAF* V600-mutant anaplastic thyroid cancer following adjuvant dabrafenib and trametinib treatment: A case report
Lee SJ, Song SY, Kim MK, Na HG, Bae CH, Kim YD, Choi YS

ABOUT COVER

Editorial Board Member of *World Journal of Clinical Cases*, Alexandru Corlateanu, MD, PhD, Reader (Associate Professor), Department of Respiratory Medicine, Nicolae Testemitanu State University of Medicine and Pharmacy, Chisinau 2001, Moldova. alexandru_corlateanu@yahoo.com

AIMS AND SCOPE

The primary aim of *World Journal of Clinical Cases* (WJCC, *World J Clin Cases*) is to provide scholars and readers from various fields of clinical medicine with a platform to publish high-quality clinical research articles and communicate their research findings online.

WJCC mainly publishes articles reporting research results and findings obtained in the field of clinical medicine and covering a wide range of topics, including case control studies, retrospective cohort studies, retrospective studies, clinical trials studies, observational studies, prospective studies, randomized controlled trials, randomized clinical trials, systematic reviews, meta-analysis, and case reports.

INDEXING/ABSTRACTING

The WJCC is now abstracted and indexed in Science Citation Index Expanded (SCIE, also known as SciSearch®), Journal Citation Reports/Science Edition, Current Contents®/Clinical Medicine, PubMed, PubMed Central, Reference Citation Analysis, China National Knowledge Infrastructure, China Science and Technology Journal Database, and Superstar Journals Database. The 2023 Edition of Journal Citation Reports® cites the 2022 impact factor (IF) for WJCC as 1.1; IF without journal self cites: 1.1; 5-year IF: 1.3; Journal Citation Indicator: 0.26; Ranking: 133 among 167 journals in medicine, general and internal; and Quartile category: Q4.

RESPONSIBLE EDITORS FOR THIS ISSUE

Production Editor: *Ying-Yi Yuan*; Production Department Director: *Xiang Li*; Editorial Office Director: *Jin-Lei Wang*.

NAME OF JOURNAL

World Journal of Clinical Cases

ISSN

ISSN 2307-8960 (online)

LAUNCH DATE

April 16, 2013

FREQUENCY

Thrice Monthly

EDITORS-IN-CHIEF

Bao-Gan Peng, Jerzy Tadeusz Chudek, George Kontogeorgos, Maurizio Serati, Ja Hyeon Ku

EDITORIAL BOARD MEMBERS

<https://www.wjgnet.com/2307-8960/editorialboard.htm>

PUBLICATION DATE

September 26, 2023

COPYRIGHT

© 2023 Baishideng Publishing Group Inc

INSTRUCTIONS TO AUTHORS

<https://www.wjgnet.com/bpg/gerinfo/204>

GUIDELINES FOR ETHICS DOCUMENTS

<https://www.wjgnet.com/bpg/GerInfo/287>

GUIDELINES FOR NON-NATIVE SPEAKERS OF ENGLISH

<https://www.wjgnet.com/bpg/gerinfo/240>

PUBLICATION ETHICS

<https://www.wjgnet.com/bpg/GerInfo/288>

PUBLICATION MISCONDUCT

<https://www.wjgnet.com/bpg/gerinfo/208>

ARTICLE PROCESSING CHARGE

<https://www.wjgnet.com/bpg/gerinfo/242>

STEPS FOR SUBMITTING MANUSCRIPTS

<https://www.wjgnet.com/bpg/GerInfo/239>

ONLINE SUBMISSION

<https://www.f6publishing.com>



Observational Study

Helicobacter pylori eradication treatment for primary gastric diffuse large B-cell lymphoma: A single-center analysis

Makoto Saito, Akio Mori, Sayaka Kajikawa, Emi Yokoyama, Minoru Kanaya, Koh Izumiyama, Masanobu Morioka, Takeshi Kondo, Zen-Ichi Tanei, Ai Shimizu

Specialty type: Medicine, research and experimental

Provenance and peer review:

Unsolicited article; Externally peer reviewed.

Peer-review model: Single blind

Peer-review report's scientific quality classification

Grade A (Excellent): 0
Grade B (Very good): B
Grade C (Good): 0
Grade D (Fair): 0
Grade E (Poor): 0

P-Reviewer: Cheng H, China

Received: June 23, 2023

Peer-review started: June 23, 2023

First decision: August 9, 2023

Revised: August 11, 2023

Accepted: August 29, 2023

Article in press: August 29, 2023

Published online: September 26, 2023



Makoto Saito, Akio Mori, Sayaka Kajikawa, Emi Yokoyama, Minoru Kanaya, Koh Izumiyama, Masanobu Morioka, Takeshi Kondo, Blood Disorders Center, Aikou Hospital, Sapporo 064-0804, Hokkaido, Japan

Zen-Ichi Tanei, Department of Cancer Pathology, Faculty of Medicine, Hokkaido University, Sapporo 060-8638, Hokkaido, Japan

Ai Shimizu, Department of Surgical Pathology, Hokkaido University Hospital, Sapporo 060-8648, Hokkaido, Japan

Corresponding author: Makoto Saito, MD, PhD, Chief Doctor, Blood Disorders Center, Aikou Hospital, Chuo-ku Minami 4 Nishi 25, Sapporo 064-0804, Hokkaido, Japan.
ikyoku@aiku-hp.or.jp

Abstract

BACKGROUND

Unlike the already established effect of *Helicobacter pylori* (*H. pylori*) eradication on gastric mucosa-associated lymphoid tissue (MALT) lymphoma, its therapeutic effect on primary gastric diffuse large B-cell lymphoma (DLBCL) is still unclear.

AIM

To clarify the efficacy of *H. pylori* eradication treatment for primary gastric DLBCL.

METHODS

We reported on 3 new cases, and added them to 3 previously reported cases. We analyzed the usefulness of *H. pylori* eradication treatment for gastric DLBCL for a total of 6 cases at our center.

RESULTS

Of the 6 patients (27-90 years old, 3 males and 3 females), all 3 patients with single lesions (one transformed from MALT lymphoma) achieved complete remission (CR) after *H. pylori* eradication. Regarding the 2 newly reported cases, CR was maintained for more than 6 years with eradication treatment alone. In contrast, none of the 3 patients with 2 lesions achieved CR. In 1 newly reported case, endoscopic CR was achieved in one lesion, while stable disease was obtained in the other lesion. Two patients with progressive disease responded to standard chemo-

therapy ± radiation and remained in CR for more than 6 years.

CONCLUSION

We believe it is worthwhile to attempt *H. pylori* eradication for elderly patients with primary gastric DLBCL in a single lesion with a small tumor burden.

Key Words: Primary gastric diffuse large B-cell lymphoma; Treatment; *Helicobacter pylori*; Eradication

©The Author(s) 2023. Published by Baishideng Publishing Group Inc. All rights reserved.

Core Tip: Unlike the already established effect of *Helicobacter pylori* (*H. pylori*) eradication on gastric mucosa-associated lymphoid tissue lymphoma, its therapeutic effect on primary gastric diffuse large B-cell lymphoma (DLBCL) is not clear. Previously, we reported 1 successful case and 2 failed cases. We report here on 3 new cases, and we considered a total of 6 cases. Three patients with a single lesion achieved complete remission, in contrast, 3 patients with multiple lesions persisted or progressed. We believe it is worthwhile to attempt *H. pylori* eradication for an elderly patient with a single lesion and a small tumor burden of primary gastric DLBCL.

Citation: Saito M, Mori A, Kajikawa S, Yokoyama E, Kanaya M, Izumiyama K, Morioka M, Kondo T, Tanei ZI, Shimizu A. *Helicobacter pylori* eradication treatment for primary gastric diffuse large B-cell lymphoma: A single-center analysis. *World J Clin Cases* 2023; 11(27): 6424-6430

URL: <https://www.wjgnet.com/2307-8960/full/v11/i27/6424.htm>

DOI: <https://dx.doi.org/10.12998/wjcc.v11.i27.6424>

INTRODUCTION

There are several reports that explain the effectiveness of eradication treatment for early-stage primary gastric diffuse large B-cell lymphoma (DLBCL), which is positive for *Helicobacter pylori* (*H. pylori*), regardless of the presence or absence of the mucosa-associated lymphoid tissue (MALT) lymphoma component[1-5]. However, unlike the already established effect of *H. pylori* eradication on gastric MALT lymphoma[6,7], its therapeutic effect on primary gastric DLBCL is still unclear. We have placed great importance on the efficacy of this noninvasive treatment, and previously, we reported on 1 successful case (short-term)[8] and 2 failed cases[9]. However, these 3 cases were mainly reported retrospectively. This time, we report on 3 new cases as a prospective study and examine the efficacy of *H. pylori* eradication for a total of 6 cases of primary gastric DLBCL.

MATERIALS AND METHODS

Study design

This was an observational study at our center with both prospective and retrospective perspectives.

Patients

Previously, we reported 3 cases of primary gastric DLBCL treated with *H. pylori* eradication between January 2014 and June 2016. One of the patients (case A[8]) was young, 27 years old. She reached complete remission (CR) but was given the established standard treatment, rituximab + cyclophosphamide, doxorubicin, vincristine and prednisone (R-CHOP) chemotherapy × 3 courses, followed by gastric irradiation (40.6 gray). One patient (70 years old, male, case B[9]) appeared to have reached CR in both the pylorus and the antrum region 3 mo after eradication treatment; however, the lesion recurred in another area (the lesser curvature of the lower corpus - ventricular angle) one year after the initial onset. The lesion had spread to the para-inferior vena cava lymph nodes (Lugano-Stage II2). The patient was administered rituximab + cyclophosphamide, pirarubicin, vincristine and prednisone chemotherapy × 6 courses, and CR was maintained for more than 6 years. In another patient (64 years old, female, case C[9]), 2 lesions in the gastric corpus were found to have enlarged (Lugano-Stage I) 8 mo after the initial onset and *H. pylori* eradication. R-CHOP chemotherapy × 3 courses followed by gastric irradiation (30 gray), and CR has been maintained for more than 6 years.

In this study, we experienced 3 new cases of primary gastric DLBCL with low tumor burden that were treated with *H. pylori* eradication therapy between July 2016 and February 2021. We prospectively investigated and reported these cases here. In addition, a total of 6 cases, including the 3 cases presented above, were comprehensively examined for the efficacy of *H. pylori* eradication treatment for primary gastric DLBCL.

RESULTS

Three case reports

Case 1: A 71-year-old man underwent esophagogastroduodenoscopy (EGD) for screening at a municipal hospital while hospitalized for diabetes. An ulcerative lesion was found in the lesser curvature of the lower corpus of the stomach (Figure 1A), and a pathological diagnosis of DLBCL was made by biopsy (Figures 1B and C). Since *H. pylori* was positive by urea breath test, eradication treatment was performed at the hospital until the diagnosis was confirmed. Eradication therapy was performed by oral administration of vonoprazan fumarate, amoxicillin hydrate and clarithromycin (20 mg, 750 mg and 200 mg, respectively, twice daily) for one week. Two months later, a re-examination by EGD at our hospital revealed that the ulcerative lesion had already regressed, and no DLBCL findings were found on biopsy (Figures 1D and E). Eradication of *H. pylori* was confirmed by rapid urease test and histopathology. Computed tomography (CT) and positron emission tomography (PET)-CT did not detect any neoplastic lesions. After that, he was followed-up again at the municipal hospital with no treatment, and he was in CR endoscopically and histopathologically for more than 6 years.

Case 2: A 67-year-old woman seen at a university hospital for immunoglobulin G4-related disease, mainly affected submandibular gland, underwent EGD for screening. A reddish change was observed on the mucosal surface at the posterior wall (Figure 2A), and a raised mucosal change was observed in the corpus of the stomach (Figure 2B). A biopsy was performed for each lesion; the former was pathologically diagnosed as DLBCL (Figures 2C and D) and the latter as MALT lymphoma (Figure 2E). CT and PET-CT did not reveal gastric lesions. The patient was referred to our center. Since *H. pylori* was positive by rapid urease test and histopathological study, eradication treatment was performed using the same method as case 1. When the patient was re-examined by EGD 3 mo later, the lesions were not clear, and a biopsy was histopathologically negative for *H. pylori* (rapid urease test was also negative), with no findings of DLBCL or MALT lymphoma (Figure 2F). Since then, CR has been maintained endoscopically and histopathologically for more than 6 years.

Case 3: A 90-year-old man underwent EGD at a nearby hospital to search for the cause of his fever and was found to have a polypoid elevated lesion (Figure 3A) in the fundus and an ulcerative lesion (Figure 3B) in the greater curvature of the gastric corpus. A biopsy was histopathologically positive for *H. pylori* and revealed an MIB-1 index of 90% for both lesions. Immunostaining was positive for c-myc, and a pathological diagnosis of non-GCB-type DLBCL was made. PET-CT detected both gastric lesions, which were not apparent on CT. No lesions were found outside the stomach on those images. A screening test detected serum M-protein, it was found that this patient had monoclonal gammopathy of undetermined significance. Eradication treatment for *H. pylori* was performed at our center using the same method as case 1 and case 2. Since then, fever was no longer observed. Three months later, a fecal *H. pylori* antigen test was negative, and an EGD was performed again. The elevated lesion at the fundus was ulcerated (Figure 3C), and the ulcerative lesion at the corpus was scarred (Figure 3D). Five months after eradication treatment, CR was able to be maintained endoscopically for the latter lesion, but the former lesion was non-CR. In addition, rituximab (375 mg/m²) was administered once a week for 4 consecutive weeks. As a result, the lesions that had already reached CR were maintained in the CR state; however, the lesions that had been non-CR eventually returned to the original polypoid tumor (stable disease). The patient refused any further treatment. Nearly 2 years have passed since then, and he is still alive with the disease.

Overview of the 6 cases

Table 1 shows the clinical features of the 6 gastric DLBCL patients (27-90 years old, 3 males and 3 females) who were treated with *H. pylori* eradication. In all cases, the tumor burden was low endoscopically at the beginning of the diagnosis, and 1 patient (case 2) was found to have coexisting MALT lymphoma, suggesting transformation from MALT lymphoma. Including this patient, CR was achieved in all 3 patients with a single lesion. The patient of case A was treated with anticancer drugs early after reaching CR, so the mid- to long-term effects of eradication were unclear. On the other hand, 2 newly reported cases (cases 1 and 2) were epoch-making patients who have been maintaining CR for more than 6 years after *H. pylori* eradication treatment alone; no additional treatment was necessary.

In contrast, all 3 patients with 2 lesions were non-CR after *H. pylori* eradication treatment. In 1 new patient (case 3), both lesions had an MIB-1 index of 90% and were non-GCB-type DLBCL positive for c-myc. For 1 lesion, CR was obtained endoscopically by eradication treatment, and for another lesion, stable disease was obtained. Two cases (case B and case C) were evaluated as progressive disease; however, chemotherapy ± irradiation was effective, and CR was maintained for more than 6 years.

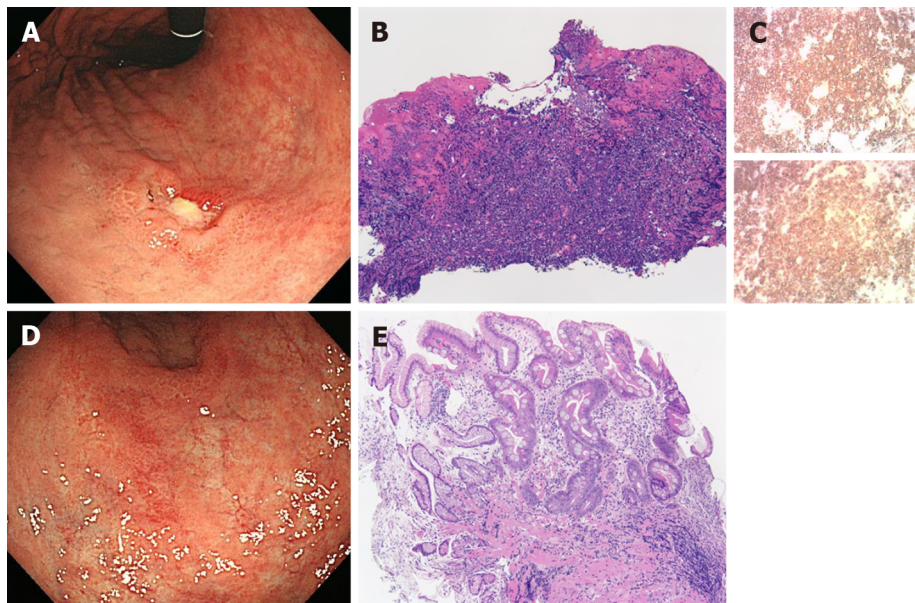
DISCUSSION

Recently, it was reported that the *H. pylori* infection rate in patients with primary gastric DLBCL was 54.7% (123/225) [10]. Another review reported that the probability of inducing CR in gastric DLBCL with *H. pylori* eradication alone was 60% (33/55) in MALT-derived DLBCL and 49.3% (40/81) in non-MALT-derived, *de novo* DLBCL; in addition, the probabilities were 50.7% (40/79) in stage I and 42.8% (6/14) in stage II [11]. Furthermore, the latter paper reported that among the 71 patients who failed to achieve remission with *H. pylori* eradication, 63 out of 64 patients (98.4%) achieved CR based on treatments including additional anticancer drugs (mainly R-CHOP) [11]. Even if the condition worsened (recurrence/progression) after *H. pylori* eradication, long-term CR could be maintained by second-line treatment, including chiefly R-CHOP chemotherapy, considering either this review [11] or our 2 successful experiences (case B and case C [9]). It is currently unknown whether eradication therapy enhances the therapeutic effect of anticancer agents.

Table 1 Clinical characteristics of 6 cases

| Case | Age | Sex | Number of lesions | Endoscopic morphology | MALT lymphoma component | Comorbidities | Therapeutic effect | Additional treatment | Current condition | Ref. |
|------|-----|--------|-------------------|-----------------------------|-------------------------|----------------------|------------------------------------|---|-------------------------------|------|
| 1 | 71 | Male | 1 | Ulcerative | (-) | Diabetes | CR | (-) | Maintaining CR (≥ 6 yr) | |
| 2 | 67 | Female | 1 | Superficial | (+) | IgG4-related disease | CR | (-) | Maintaining CR (≥ 6 yr) | |
| 3 | 90 | Male | 2 | Ulcerative. Elevated | (-) | MGUS | CR. SD | RTX (1/wk) \times 4 wk | Alive with disease (2 yr) | |
| A | 27 | Female | 1 | Ulcerative | (-) | (-) | CR | R-CHOP \times 3 courses + gastric irradiation | Maintaining CR (≥ 9 yr) | [8] |
| B | 70 | Male | 2 | Ulcerative (both 2 lesions) | (-) | Diabetes | CR (both lesions). Recurrence (PD) | R-THP-COP \times 6 courses | Maintaining CR (≥ 6 yr) | [9] |
| C | 64 | Female | 2 | Ulcerative (both 2 lesions) | (-) | (-) | PD (both lesions) | R-CHOP \times 3 courses + gastric irradiation | Maintaining CR (≥ 6 yr) | [9] |

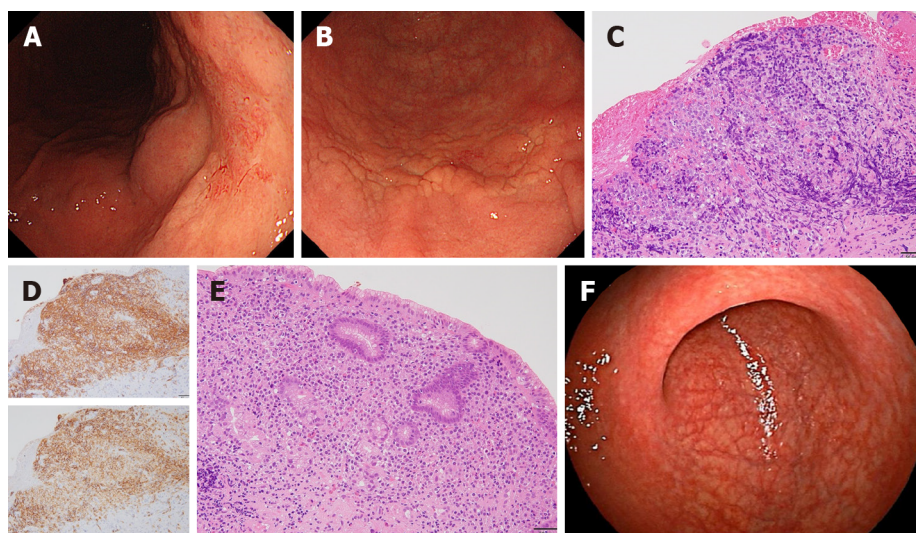
MALT: Mucosa-associated lymphoid tissue; MGUS: Monoclonal gammopathy of undetermined significance; CR: Complete remission; SD: Stable disease; PD: Progressive disease; RTX: Rituximab; R-CHOP: Rituximab + cyclophosphamide, doxorubicin, vincristine and prednisone; R-THP-COP: Rituximab + cyclophosphamide, pirarubicin, vincristine and prednisone; IgG: Immunoglobulin G.



DOI: 10.12998/wjcc.v11.i27.6424 Copyright ©The Author(s) 2023.

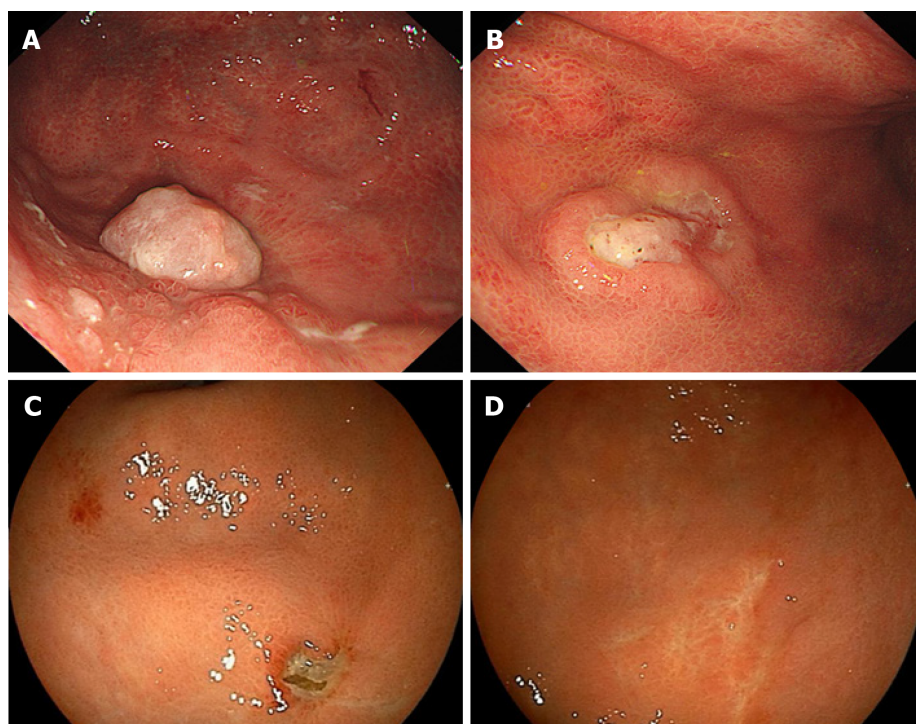
Figure 1 Case 1. A: An ulcerated lesion was revealed in the lesser curvature of the lower corpus; B: Abnormal lymphoid cells were densely proliferating in the lamina propria; C: The upper panel shows CD20 immunostaining, and the lower panel shows CD79a immunostaining. Both were clearly positive; D: Seven months after *Helicobacter pylori* eradication, the ulcerated lesion regressed; E: Scattered infiltration of small lymphocytes in the lamina propria was observed. A and D: Endoscopic findings of the stomach; B, C, and E: Microscopic findings (B and E; hematoxylin eosin staining, scale bar = 100 μ m).

The efficacy of *H. pylori* eradication in patients with DLBCL may be related to the depth of tumor invasion. As an indication for *H. pylori* eradication treatment for primary gastric DLBCL with or without the MALT lymphoma component, the depth of the lesions into the gastric wall is important, and it is essential to stay at the mucosa[12] or sub-mucosa[1]. In addition, previous reports have indicated that it takes a median of 2.1 (0.6-3.7) mo for *de novo* DLBCL and a median of 5.0 (2.8-7.5) mo for DLBCL with MALT lymphoma from eradication treatment for *H. pylori* to pathological CR [1]. In the current 3 cases, EGD was performed 2-3 mo after eradication therapy, and the therapeutic effect was evaluated.



DOI: 10.12998/wjcc.v11.i27.6424 Copyright ©The Author(s) 2023.

Figure 2 Case 2. A: The surface layer of the mucosa on the posterior wall side changed to reddish; B: A subtle ridged change in the mucosa was observed; C: Neoplastic lymphoid cells were densely proliferating in the lamina propria; D: The upper panel shows CD20 immunostaining, and the lower panel shows CD79a immunostaining. Both were clearly positive; E: Atypical lymphoid cells were proliferating in the lamina propria; F: Fourteen months after *Helicobacter pylori* eradication, a white scar was observed on the posterior wall where diffuse large B-cell lymphoma was present. A, B, and F: Endoscopic findings of the stomach; C-E: Microscopic findings (C and E; hematoxylin eosin staining, scale bar = 100 μ m).



DOI: 10.12998/wjcc.v11.i27.6424 Copyright ©The Author(s) 2023.

Figure 3 Case 3. Endoscopic findings of the stomach. A: A polypoid-like elevated lesion was found in the fundus; B: An ulcerative lesion with peripheral ridges was found in the greater curvature of the corpus; C and D: Three months after *Helicobacter pylori* eradication, the elevated lesion in the fundus was ulcerated (C), and the ulcerative lesions in the corpus became scarred (D).

It has been reported that in gastric DLBCL, the expression of BCL10, nuclear factor kappaB (p65), cytotoxin-associated gene A (CagA)[13] and CagA-signaling molecules is clinically and biologically *H. pylori*-dependent[5], or miR-200 was associated with the susceptible group for *H. pylori*[14]. Although knowledge about B-cell receptor signaling related to susceptibility to *H. pylori* eradication treatment in gastric DLBCL is advancing[15], clinical application is still difficult. In this study, molecular medical markers were not scrutinized, which was a limitation of our research.

We studied 3 new cases prospectively, which are inherently different from the 3 cases we previously reported as a retrospective study (1 successful case, but short-term observation[8], and 2 failed cases[9]). Of the current 3 patients with

4 lesions, medium- to long-term CR was obtained successfully in 3 lesions with *H. pylori* eradication alone, and stable disease was obtained in 1 lesion. However, two lesions in case 3 had a MIB-1 index of 90% and a non-GCB-type DLBCL positive for c-myc and had a high degree of biological malignancy. It is significant that CR was obtained even for 1 lesion endoscopically by eradication treatment, and this patient has been alive with the disease for approximately 2 years.

We considered the benefits of *H. pylori* eradication on gastric DLBCL with a total of 6 cases, including 3 previously reported cases. Three patients with a single lesion achieved CR, in contrast, 3 patients with multiple lesions persisted or progressed. This may be the first report showing that the number of tumors affected the efficacy of *H. pylori* eradication treatment for primary gastric DLBCL.

CONCLUSION

In conclusion, especially in elderly individuals, it is worthwhile to try *H. pylori* eradication treatment first in single primary gastric DLBCL lesions, which have a low tumor burden. The number of relevant cases is still small, and the study should be continued with more patients.

ARTICLE HIGHLIGHTS

Research background

The efficacy of *Helicobacter pylori* (*H. pylori*) eradication treatment for gastric mucosa-associated lymphoid tissue (MALT) lymphoma has been established.

Research motivation

The therapeutic efficacy of *H. pylori* eradication treatment for primary gastric diffuse large B-cell lymphoma (DLBCL) remains unclear.

Research objectives

This study aimed to clarify the efficacy of *H. pylori* eradication for primary gastric DLBCL.

Research methods

We examined the usefulness of *H. pylori* eradication treatment for gastric DLBCL in a total of 6 patients at our center, including 3 previously reported cases.

Research results

Of the 6 patients (27-90 years old, 3 males and 3 females), all 3 patients with a single lesion achieved complete remission (CR) after *H. pylori* eradication. Regarding the 2 newly reported patients (one transformed from MALT lymphoma, and the other was *de novo*), CR was maintained for more than 6 years with eradication treatment alone. In contrast, none of the 3 patients with 2 lesions achieved CR. In 1 newly reported patient, CR was achieved endoscopically in 1 lesion, while stable disease was obtained in the other lesion. Two patients with progressive disease responded to standard chemotherapy ± radiation.

Research conclusions

It is considered worthwhile to try *H. pylori* eradication first for elderly patients with a single primary gastric DLBCL lesion, which has a low tumor burden.

Research perspectives

The number of relevant cases is still small, and it is necessary to further increase the number of patients and continue the examination.

FOOTNOTES

Author contributions: Saito M designed this study; Tanei ZI and Shimizu A involved in pathological procedure; all authors made substantial contributions to acquisition of data, or analysis and interpretation of data; took part in drafting the article; and agree to be accountable for all aspects of the work.

Institutional review board statement: This study was conducted in accordance with the World Medical Association Declaration of Helsinki, and this study was reviewed and approved by the Aiiiku Hospital Clinical Research Review Board (Sapporo).

Informed consent statement: All patients provided written informed consent.

Conflict-of-interest statement: All the authors report no relevant conflicts of interest for this article.

Data sharing statement: No additional data are available.

STROBE statement: The authors have read the STROBE Statement-checklist of items, and the manuscript was prepared and revised according to the STROBE Statement-checklist of items.

Open-Access: This article is an open-access article that was selected by an in-house editor and fully peer-reviewed by external reviewers. It is distributed in accordance with the Creative Commons Attribution NonCommercial (CC BY-NC 4.0) license, which permits others to distribute, remix, adapt, build upon this work non-commercially, and license their derivative works on different terms, provided the original work is properly cited and the use is non-commercial. See: <https://creativecommons.org/licenses/by-nc/4.0/>

Country/Territory of origin: Japan

ORCID number: Makoto Saito 0000-0002-2683-9475; Akio Mori 0000-0002-2064-2145; Sayaka Kajikawa 0009-0006-1259-5947; Emi Yokoyama 0000-0002-1207-2138; Minoru Kanaya 0000-0002-0035-8657; Koh Izumiyama 0000-0002-0762-6255; Masanobu Morioka 0000-0002-0784-8114; Takeshi Kondo 0000-0001-7455-5824; Zen-Ichi Tanei 0000-0003-3474-2646; Ai Shimizu 0009-0001-7536-9799.

S-Editor: Wang JJ

L-Editor: A

P-Editor: Wang JJ

REFERENCES

- 1 Kuo SH, Yeh KH, Wu MS, Lin CW, Hsu PN, Wang HP, Chen LT, Cheng AL. Helicobacter pylori eradication therapy is effective in the treatment of early-stage H pylori-positive gastric diffuse large B-cell lymphomas. *Blood* 2012; **119**: 4838-44; quiz 5057 [PMID: 22403257 DOI: 10.1182/blood-2012-01-404194]
- 2 Ferreri AJ, Govi S, Raderer M, Mulè A, Andriani A, Caracciolo D, Devizzi L, Ilariucci F, Luminari S, Viale E, Müllauer L, Dell'Oro S, Arcidiacono PG, Ponzoni M, Patti C. Helicobacter pylori eradication as exclusive treatment for limited-stage gastric diffuse large B-cell lymphoma: results of a multicenter phase 2 trial. *Blood* 2012; **120**: 3858-3860 [PMID: 23118214 DOI: 10.1182/blood-2012-06-438424]
- 3 Ferreri AJ, Govi S, Ponzoni M. The role of Helicobacter pylori eradication in the treatment of diffuse large B-cell and marginal zone lymphomas of the stomach. *Curr Opin Oncol* 2013; **25**: 470-479 [PMID: 23942292 DOI: 10.1097/01.cco.0000432523.24358.15]
- 4 Paydas S. Helicobacter pylori eradication in gastric diffuse large B cell lymphoma. *World J Gastroenterol* 2015; **21**: 3773-3776 [PMID: 25852262 DOI: 10.3748/wjg.v21.i13.3773]
- 5 Kuo SH, Chen LT, Lin CW, Yeh KH, Shun CT, Tzeng YS, Liou JM, Wu MS, Hsu PN, Cheng AL. Expressions of the CagA protein and CagA-signaling molecules predict Helicobacter pylori dependence of early-stage gastric DLBCL. *Blood* 2017; **129**: 188-198 [PMID: 27864293 DOI: 10.1182/blood-2016-04-713719]
- 6 Nakamura S, Sugiyama T, Matsumoto T, Iijima K, Ono S, Tajika M, Tari A, Kitadai Y, Matsumoto H, Nagaya T, Kamoshida T, Watanabe N, Chiba T, Origasa H, Asaka M; JAPAN GAST Study Group. Long-term clinical outcome of gastric MALT lymphoma after eradication of Helicobacter pylori: a multicentre cohort follow-up study of 420 patients in Japan. *Gut* 2012; **61**: 507-513 [PMID: 21890816 DOI: 10.1136/gutjnl-2011-300495]
- 7 Cook JR, Isaacson PG, Chott A, Nakamura S, Müller-Hermelink HK, Harris NL. Swerdlow SH. Extranodal marginal zone lymphoma of mucosa-associated lymphoid tissue (MALT lymphoma) In: Swerdlow SH, Campo E, Harris NL, Jaffe ES, Pileri SA, Stein H, editors. WHO classification of tumours of haematopoietic and lymphoid tissues. Revised 4th ed. Lyon, France: IARC press, 2017: 259-262
- 8 Saito M, Masutani M, Mabe K, Izumiyama K, Mori A, Irie T, Tanaka M, Morioka M, Tanino M. Regression of gastric de novo diffuse large B-cell lymphoma following Helicobacter pylori eradication: a case report. *Acta Gastroenterol Belg* 2016; **79**: 367-369 [PMID: 27821034]
- 9 Saito M, Mori A, Ogasawara R, Izumiyama K, Morioka M, Kondo T, Miyashita K. Progression of Primary Gastric Diffuse Large B-Cell Lymphoma after Helicobacter pylori Eradication. *Case Rep Gastroenterol* 2020; **14**: 534-539 [PMID: 33250694 DOI: 10.1159/000508849]
- 10 Feng Y, Duan TJ, Huang Q, Li ZY, Liu YP, Luo MS, Lu GF, Shi W, Zhang ZY, Li HX. The clinicopathological characteristics of gastric cancer and precancerous conditions in gastric DLBCL and MALT lymphoma patients: a multi-center retrospective study. *Ann Med* 2023; **55**: 2193423 [PMID: 37183786 DOI: 10.1080/07853890.2023.2193423]
- 11 De Francesco V, Manta R, Marmo R, Marmo C, Rago A, Antonelli G, Hassan C, Zullo A. Efficacy of Helicobacter pylori eradication in patients with diffuse large B-cell lymphoma of the stomach: A systematic review. *Eur J Haematol* 2022; **109**: 643-647 [PMID: 36175387 DOI: 10.1111/ejh.13871]
- 12 Tari A, Asaoku H, Kashiwado K, Yoshino T, Kitadai Y, Tanaka S, Fujihara M. Predictive value of endoscopy and endoscopic ultrasonography for regression of gastric diffuse large B-cell lymphomas after Helicobacter pylori eradication. *Dig Endosc* 2009; **21**: 219-227 [PMID: 19961519 DOI: 10.1111/j.1443-1661.2009.00896.x]
- 13 Tsai HJ, Tai JJ, Chen LT, Wu MS, Yeh KH, Lin CW, Wang TE, Wang HP, Yu FJ, Liou JM, Hsiao CF, Cheng TY, Yeh HJ, Ko CW, Chen MJ, Lo GH, Hsu PI, Chang CS, Hwang WS, Chuang SS, Lee HW, Shun CT, Chiu CF, Wang WM, Hsieh CY, Liu TW, Lin JT, Kuo SH, Cheng AL; Taiwan Cooperative Oncology Group. A multicenter prospective study of first-line antibiotic therapy for early-stage gastric mucosa-associated lymphoid tissue lymphoma and diffuse large B-cell lymphoma with histological evidence of mucosa-associated lymphoid tissue. *Haematologica* 2020; **105**: e349-e354 [PMID: 31727764 DOI: 10.3324/haematol.2019.228775]
- 14 Huang WT, Kuo SH, Kuo YC, Lin CW. miR-155-regulated mTOR and Toll-like receptor 5 in gastric diffuse large B-cell lymphoma. *Cancer Med* 2022; **11**: 555-570 [PMID: 34913612 DOI: 10.1002/cam4.4466]
- 15 Torisu T, Kawano S, Miyawaki K, Yamamoto H, Ihara Y, Matsuno Y, Torisu K, Sugio T, Sasaki K, Shimakawa T, Kato K, Akashi K, Nakamura S, Kitazono T. B cell receptor signaling related to resistance to Helicobacter pylori eradication therapy in gastric diffuse large B cell lymphoma. *Hematol Oncol* 2021; **39**: 145-147 [PMID: 33034903 DOI: 10.1002/hon.2816]



Published by **Baishideng Publishing Group Inc**
7041 Koll Center Parkway, Suite 160, Pleasanton, CA 94566, USA

Telephone: +1-925-3991568

E-mail: bpgoffice@wjgnet.com

Help Desk: <https://www.f6publishing.com/helpdesk>

<https://www.wjgnet.com>

