

# World Journal of *Clinical Cases*

*World J Clin Cases* 2023 September 26; 11(27): 6318-6669



**MINIREVIEWS**

- 6318 Characteristics of amino acid metabolism in colorectal cancer

*Xu F, Jiang HL, Feng WW, Fu C, Zhou JC*

**ORIGINAL ARTICLE****Clinical and Translational Research**

- 6327 Exploring the pharmacological mechanism of Wuzhuyu decoction on hepatocellular carcinoma using network pharmacology

*Ouyang JY, Lin WJ, Dong JM, Yang Y, Yang HK, Zhou ZL, Wang RQ*

- 6344 Identification of potential diagnostic and prognostic biomarkers for breast cancer based on gene expression omnibus

*Zhang X, Mi ZH*

**Retrospective Cohort Study**

- 6363 Treatment of proximal humeral fractures accompanied by medial calcar fractures using fibular autografts: A retrospective, comparative cohort study

*Liu N, Wang BG, Zhang LF*

**Retrospective Study**

- 6374 Effectiveness of out-fracture of the inferior turbinate with reduction nasal bone fracture

*Kim SY, Nam HJ, Byeon JY, Choi HJ*

- 6383 Prognostic model of hepatocellular carcinoma based on cancer grade

*Zhang GX, Ding XS, Wang YL*

- 6398 Oncologic efficacy of gonadotropin-releasing hormone agonist in hormone receptor-positive very young breast cancer patients treated with neoadjuvant chemotherapy

*Choi HJ, Lee JH, Jung CS, Ryu JM, Chae BJ, Lee SK, Yu JH, Kim SW, Nam SJ, Lee JE, Jung YJ, Kim HY*

- 6407 Correlation analysis of serum thyroglobulin, thyroid-stimulating hormone levels, and thyroid-cancer risk in thyroid nodule surgery

*Shuai JH, Leng ZF, Wang P, Ji YC*

- 6415 Closed thoracic drainage in elderly patients with chronic obstructive pulmonary disease complicated with spontaneous pneumothorax: A retrospective study

*Wang W, Zhu DN, Shao SS, Bao J*

**Observational Study**

- 6424 *Helicobacter pylori* eradication treatment for primary gastric diffuse large B-cell lymphoma: A single-center analysis

*Saito M, Mori A, Kajikawa S, Yokoyama E, Kanaya M, Izumiyama K, Morioka M, Kondo T, Tanei ZI, Shimizu A*

**Prospective Study**

- 6431** Effect of polyene phosphatidylcholine/ursodeoxycholic acid/ademetionine on pregnancy outcomes in intrahepatic cholestasis  
*Dong XR, Chen QQ, Xue ML, Wang L, Wu Q, Luo TF*

**SYSTEMATIC REVIEWS**

- 6440** Maternal diaphragmatic hernia in pregnancy: A systematic review with a treatment algorithm  
*Augustin G, Kovač D, Karadjole VS, Zajec V, Herman M, Hrbač P*

**META-ANALYSIS**

- 6455** Laparoscopic *vs* open radical resection in management of gallbladder carcinoma: A systematic review and meta-analysis  
*He S, Yu TN, Cao JS, Zhou XY, Chen ZH, Jiang WB, Cai LX, Liang X*

**CASE REPORT**

- 6476** Acute acquired concomitant esotropia with congenital paralytic strabismus: A case report  
*Zhang MD, Liu XY, Sun K, Qi SN, Xu CL*
- 6483** Tumor recurrence after pathological complete response in locally advanced gastric cancer after neoadjuvant therapy: Two case reports  
*Xing Y, Zhang ZL, Ding ZY, Song WL, Li T*
- 6491** Acute peritonitis secondary to post-traumatic appendicitis: A case report and literature review  
*Habachi G, Aziza B, Ben-Ammar S, Maherzi O, Houas Y, Kerkeni Y, Sahli S, Jouini R*
- 6498** Fournier's gangrene after insertion of thermo-expandable prostatic stent for benign prostatic hyperplasia: A case report  
*Jung HC, Kim YU*
- 6505** Methyl-CpG-Binding protein 2 duplication syndrome in a Chinese patient: A case report and review of the literature  
*Xing XH, Takam R, Bao XY, Ba-alwi NA, Ji H*
- 6515** Blood purification for treatment of non-liquefied multiple liver abscesses and improvement of T-cell function: A case report  
*Tang ZQ, Zhao DP, Dong AJ, Li HB*
- 6523** Eosinophilic granulomatosis with polyangiitis, asthma as the first symptom, and subsequent Loeffler endocarditis: A case report  
*He JL, Liu XY, Zhang Y, Niu L, Li XL, Xie XY, Kang YT, Yang LQ, Cai ZY, Long H, Ye GF, Zou JX*
- 6531** Left atrium veno-arterial extra corporeal membrane oxygenation as temporary mechanical support for cardiogenic shock: A case report  
*Lamastra R, Abbott DM, Degani A, Pellegrini C, Veronesi R, Pelenghi S, Dezza C, Gazzaniga G, Belliato M*

- 6537** Successful treatment of eyebrow intradermal nevi by shearing combined with electrocautery and curettage: Two case reports  
*Liu C, Liang JL, Yu JL, Hu Q, Li CX*
- 6543** Amniotic membrane mesenchymal stromal cell-derived secretome in the treatment of acute ischemic stroke: A case report  
*Lin FH, Yang YX, Wang YJ, Subbiah SK, Wu XY*
- 6551** Managing spindle cell sarcoma with surgery and high-intensity focused ultrasound: A case report  
*Zhu YQ, Zhao GC, Zheng CX, Yuan L, Yuan GB*
- 6558** Triplet regimen as a novel modality for advanced unresectable hepatocellular carcinoma: A case report and review of literature  
*Zhao Y, He GS, Li G*
- 6565** Acute diquat poisoning case with multiorgan failure and a literature review: A case report  
*Fan CY, Zhang CG, Zhang PS, Chen Y, He JQ, Yin H, Gong XJ*
- 6573** Fungal corneal ulcer after repair of an overhanging filtering bleb: A case report  
*Zhao J, Xu HT, Yin Y, Li YX, Zheng YJ*
- 6579** Combination therapy with toripalimab and anlotinib in advanced esophageal squamous cell carcinoma: A case report  
*Chen SC, Ma DH, Zhong JJ*
- 6587** Removal of a pulmonary artery foreign body during pulse ablation in a patient with atrial fibrillation: A case report  
*Yan R, Lei XY, Li J, Jia LL, Wang HX*
- 6592** Delayed-onset *micrococcus luteus*-induced postoperative endophthalmitis several months after cataract surgery: A case report  
*Nam KY, Lee HW*
- 6597** Anesthetic management of a pregnant patient with Eisenmenger's syndrome: A case report  
*Zhang Y, Wei TT, Chen G*
- 6603** Recurrence of unilateral angioedema of the tongue: A case report  
*Matsuhisa Y, Kenzaka T, Shimizu H, Hirose H, Gotoh T*
- 6613** Transverse mesocolic hernia with intestinal obstruction as a rare cause of acute abdomen in adults: A case report  
*Zhang C, Guo DF, Lin F, Zhan WF, Lin JY, Lv GF*
- 6618** Compound heterozygous mutations in tripeptidyl peptidase 1 cause rare autosomal recessive spinocerebellar ataxia type 7: A case report  
*Liu RH, Wang XY, Jia YY, Wang XC, Xia M, Nie Q, Guo J, Kong QX*

- 6624** Treatment of posterior interosseous nerve entrapment syndrome with ultrasound-guided hydrodissection: A case report  
*Qin LH, Cao W, Chen FT, Chen QB, Liu XX*
- 6631** Rapidly growing extensive polypoid endometriosis after gonadotropin-releasing hormone agonist discontinuation: A case report  
*Zhang DY, Peng C, Huang Y, Cao JC, Zhou YF*
- 6640** Preserving finger length in a patient with symmetric digital gangrene under local anesthesia: A case report  
*Kim KH, Ko IC, Kim H, Lim SY*
- 6646** Reconstruction of the lower back wound with delayed infection after spinal surgery: A case report  
*Kim D, Lim S, Eo S, Yoon JS*
- 6653** Solitary intraosseous neurofibroma in the mandible mimicking a cystic lesion: A case report and review of literature  
*Zhang Z, Hong X, Wang F, Ye X, Yao YD, Yin Y, Yang HY*
- 6664** Complete response of metastatic *BRAF* V600-mutant anaplastic thyroid cancer following adjuvant dabrafenib and trametinib treatment: A case report  
*Lee SJ, Song SY, Kim MK, Na HG, Bae CH, Kim YD, Choi YS*

**ABOUT COVER**

Editorial Board Member of *World Journal of Clinical Cases*, Alexandru Corlateanu, MD, PhD, Reader (Associate Professor), Department of Respiratory Medicine, Nicolae Testemitanu State University of Medicine and Pharmacy, Chisinau 2001, Moldova. alexandru\_corlateanu@yahoo.com

**AIMS AND SCOPE**

The primary aim of *World Journal of Clinical Cases* (WJCC, *World J Clin Cases*) is to provide scholars and readers from various fields of clinical medicine with a platform to publish high-quality clinical research articles and communicate their research findings online.

WJCC mainly publishes articles reporting research results and findings obtained in the field of clinical medicine and covering a wide range of topics, including case control studies, retrospective cohort studies, retrospective studies, clinical trials studies, observational studies, prospective studies, randomized controlled trials, randomized clinical trials, systematic reviews, meta-analysis, and case reports.

**INDEXING/ABSTRACTING**

The WJCC is now abstracted and indexed in Science Citation Index Expanded (SCIE, also known as SciSearch®), Journal Citation Reports/Science Edition, Current Contents®/Clinical Medicine, PubMed, PubMed Central, Reference Citation Analysis, China National Knowledge Infrastructure, China Science and Technology Journal Database, and Superstar Journals Database. The 2023 Edition of Journal Citation Reports® cites the 2022 impact factor (IF) for WJCC as 1.1; IF without journal self cites: 1.1; 5-year IF: 1.3; Journal Citation Indicator: 0.26; Ranking: 133 among 167 journals in medicine, general and internal; and Quartile category: Q4.

**RESPONSIBLE EDITORS FOR THIS ISSUE**

Production Editor: *Ying-Yi Yuan*; Production Department Director: *Xiang Li*; Editorial Office Director: *Jin-Lei Wang*.

**NAME OF JOURNAL**

*World Journal of Clinical Cases*

**ISSN**

ISSN 2307-8960 (online)

**LAUNCH DATE**

April 16, 2013

**FREQUENCY**

Thrice Monthly

**EDITORS-IN-CHIEF**

Bao-Gan Peng, Jerzy Tadeusz Chudek, George Kontogeorgos, Maurizio Serati, Ja Hyeon Ku

**EDITORIAL BOARD MEMBERS**

<https://www.wjgnet.com/2307-8960/editorialboard.htm>

**PUBLICATION DATE**

September 26, 2023

**COPYRIGHT**

© 2023 Baishideng Publishing Group Inc

**INSTRUCTIONS TO AUTHORS**

<https://www.wjgnet.com/bpg/gerinfo/204>

**GUIDELINES FOR ETHICS DOCUMENTS**

<https://www.wjgnet.com/bpg/GerInfo/287>

**GUIDELINES FOR NON-NATIVE SPEAKERS OF ENGLISH**

<https://www.wjgnet.com/bpg/gerinfo/240>

**PUBLICATION ETHICS**

<https://www.wjgnet.com/bpg/GerInfo/288>

**PUBLICATION MISCONDUCT**

<https://www.wjgnet.com/bpg/gerinfo/208>

**ARTICLE PROCESSING CHARGE**

<https://www.wjgnet.com/bpg/gerinfo/242>

**STEPS FOR SUBMITTING MANUSCRIPTS**

<https://www.wjgnet.com/bpg/GerInfo/239>

**ONLINE SUBMISSION**

<https://www.f6publishing.com>



## Complete response of metastatic *BRAF* V600-mutant anaplastic thyroid cancer following adjuvant dabrafenib and trametinib treatment: A case report

Sang Jae Lee, Si-Youn Song, Min Kyoung Kim, Hyung Gyun Na, Chang Hoon Bae, Yong-Dae Kim, Yoon Seok Choi

### Specialty type:

Otorhinolaryngology

### Provenance and peer review:

Unsolicited article; Externally peer reviewed.

### Peer-review model: Single blind

### Peer-review report's scientific quality classification

Grade A (Excellent): 0  
Grade B (Very good): 0  
Grade C (Good): C, C  
Grade D (Fair): 0  
Grade E (Poor): 0

**P-Reviewer:** Cheng X, China; Liu J, China

**Received:** July 26, 2023

**Peer-review started:** July 26, 2023

**First decision:** August 16, 2023

**Revised:** August 24, 2023

**Accepted:** August 31, 2023

**Article in press:** August 31, 2023

**Published online:** September 26, 2023



**Sang Jae Lee, Si-Youn Song, Hyung Gyun Na, Chang Hoon Bae, Yong-Dae Kim, Yoon Seok Choi,** Department of Otorhinolaryngology-Head and Neck Surgery, College of Medicine, Yeungnam University, Daegu 42415, South Korea

**Min Kyoung Kim,** Division of Hematology-Oncology, Department of Internal Medicine, College of Medicine, Yeungnam University, Daegu 42415, South Korea

**Yong-Dae Kim,** Regional Center for Respiratory Diseases, Yeungnam University Medical Center, Daegu 42415, South Korea

**Corresponding author:** Yoon Seok Choi, MD, PhD, Associate Professor, Department of Otorhinolaryngology-Head and Neck Surgery, College of Medicine, Yeungnam University, 170, Hyeonchung-ro, Nam-Gu, Daegu 42415, South Korea. [choiys@ynu.ac.kr](mailto:choiys@ynu.ac.kr)

### Abstract

#### BACKGROUND

Anaplastic thyroid cancer (ATC) is a rare but aggressive type of thyroid carcinoma. *BRAF* V600E-mutation, which is found in 10%-50% of ATCs, is associated with poor prognosis. A recent clinical trial reported a substantial clinical benefit of concomitant treatment of dabrafenib (*BRAF* inhibitor) and trametinib (MEK inhibitor) for treating *BRAF* V600E-mutant ATC. However, reports on patients with ATC treated with this regimen following surgery are lacking.

#### CASE SUMMARY

We report the case of a 63-year-old female patient diagnosed with *BRAF* V600E-mutant ATC. Following three surgeries – total thyroidectomy, total laryngectomy, and neck dissection – she was diagnosed with lung metastasis during follow-up. The metastatic ATC was successfully treated with dabrafenib and trametinib. The patient achieved a complete response at the 32-mo follow-up.

#### CONCLUSION

Adjuvant chemotherapy with dabrafenib plus trametinib is efficacious for treatment and prevention of recurrent ATC with *BRAF* mutation following surgery.

**Key Words:** Thyroid carcinoma; Anaplastic; *BRAF*; Dabrafenib; Trametinib; Chemotherapy; Adjuvant; Case report

©The Author(s) 2023. Published by Baishideng Publishing Group Inc. All rights reserved.

**Core Tip:** Anaplastic thyroid cancer (ATC) is a rare but aggressive type of thyroid carcinoma. The *BRAF* V600E-mutation, found in 10%-50% of ATCs, is associated with a poor prognosis. A recent clinical trial reported a substantial clinical benefit of dabrafenib (*BRAF* inhibitor) plus trametinib (MEK inhibitor) in treating *BRAF* V600E-mutant ATC. This report highlights the therapeutic potential of dabrafenib plus trametinib as an adjuvant chemotherapy to treat and prevent the recurrence of ATC confirmed with *BRAF* mutation following surgical resection.

**Citation:** Lee SJ, Song SY, Kim MK, Na HG, Bae CH, Kim YD, Choi YS. Complete response of metastatic *BRAF* V600-mutant anaplastic thyroid cancer following adjuvant dabrafenib and trametinib treatment: A case report. *World J Clin Cases* 2023; 11(27): 6664-6669

**URL:** <https://www.wjgnet.com/2307-8960/full/v11/i27/6664.htm>

**DOI:** <https://dx.doi.org/10.12998/wjcc.v11.i27.6664>

## INTRODUCTION

Anaplastic thyroid cancer (ATC) is the fastest-growing and most aggressive type of undifferentiated thyroid carcinoma. All ATCs are considered stage IV, and the overall prognosis is poor, with a median survival time of less than a year, despite various available treatments. Many new targeted therapies for ATC have been reported in recent years; however, no definitive treatment has yet been established[1].

The *BRAF* V600E-mutation is found in 10%-50% of ATCs, and is associated with a poor prognosis[2,3]. Clinical phase II and open-label basket trials conducted using the combination of dabrafenib (*BRAF* inhibitor) and trametinib [mitogen-activated protein kinase kinase (MEK) inhibitor] for treatment of ATC with a *BRAF* mutation have shown substantial efficacy[2,3]. The Food and Drug Administration (FDA) of the United States has approved dabrafenib plus trametinib for the treatment of ATC with *BRAF* mutation. The 2021 American Thyroid Association's (ATA) guidelines for the management of patients with ATC have also been revised to reflect the treatment option for *BRAF*-mutant ATC[4]. However, there are few reports of patients with ATC who have been treated using this regimen following surgery[5,6].

Here, we report a case of recurrent and metastatic ATC that was successfully treated with dabrafenib plus trametinib as an adjuvant chemotherapy.

## CASE PRESENTATION

### Chief complaints

A 63-year-old female patient presented with dyspnea and a large neck mass at the emergency department of our hospital.

### History of present illness

Her symptoms were insidious and began one week prior to presentation.

### History of past illness

The patient had been diagnosed with hypertension, and was taking anti-hypertensive medication at the time of her presentation. Three days prior, the patient underwent a chest computed tomography (CT) scan and was treated with steroid medication and a salbutamol inhaler, which were unable to relieve her symptoms.

### Personal and family history

The patient denied any family history of malignant tumors.

### Physical examination

On physical examination, the patient's vital signs were as follows: Body temperature, 37.1 °C; blood pressure, 140/100 mmHg; heart rate, 122 beats per min; respiratory rate, 25 breaths per min; and oxygen saturation, 95%. Accessory respiratory muscle use was observed, and stridor was heard during inspiration. A hard, non-tender fixed mass with a diameter of 4 cm was found on the left side of the anterior neck. The patient's vocal cord mobility was normal.

### Laboratory examinations

Subclinical hypothyroidism was noted on thyroid function tests [thyroid stimulating hormone, 9.73  $\mu$ IU/mL; free thyroxine (T4), 1.4 ng/dL; triiodothyronine (T3), 1.22 ng/mL]. No abnormalities were found on routine blood analyses.

### Imaging examinations

A neck CT revealed an infiltrative mass of heterogeneous density, measuring approximately 3.1 cm × 3.0 cm, in the left thyroid lobe and invading the left side of tracheal wall (Figure 1A).

### Further diagnostic work-up

Intubation was performed and the patient was admitted to the intensive care unit. A core needle biopsy was performed at the bedside, and the mass was diagnosed as papillary thyroid carcinoma (PTC). However, gross invasion of the surrounding structures from the cricoid cartilage to 6<sup>th</sup> ring of the trachea was observed during surgery (Figure 1B and C). Considering the possibility of PTC with anaplastic dedifferentiation, we performed total thyroidectomy, total laryngectomy, central compartment neck dissection (CCND), and left selective neck dissection (SND; level II, III, and IV). The final pathology reports confirmed the presence of mixed anaplastic (70%) and papillary (30%) carcinomas in the left thyroid gland and metastatic anaplastic carcinoma in the regional lymph node and left level III lymph node, with extra-nodal extension. Anaplastic carcinoma was also observed in the larynx. The *BRAF* mutation was confirmed by an additional pathological examination. However, no mutations were observed in the telomerase reverse transcriptase (*TERT*) promoter through next-generation sequencing analysis. The absence of 18-fluorodeoxyglucose (FDG) uptake was noted on postoperative positron emission tomography/CT (PET/CT), suggesting no distant metastases, and the pathological stage was determined to be IVB (T4aN1bM0) (Figure 2A). The patient was discharged two weeks after surgery without any postoperative complications. However, two months post-surgery, a new mass was found in the right submandibular area. A PET/CT showed FDG-uptake at the right level II, and VI, and a pulmonary nodule in the right lower lobe, suggesting distant metastasis (Figure 2B and C). A salvage surgery (right modified radical neck dissection type III and CCND) was therefore performed. Adjuvant concurrent chemoradiotherapy based on a cytotoxic agent was recommended; however, owing to the patient's refusal, follow-up was performed without any additional treatment. Recurrence was then observed in the neck, and an additional salvage operation (left SND; level I and II), right upper tracheal lymph node excision) was performed.

## FINAL DIAGNOSIS

The patient was diagnosed with recurrent and metastatic *BRAF* V600E-mutant ATC.

## TREATMENT

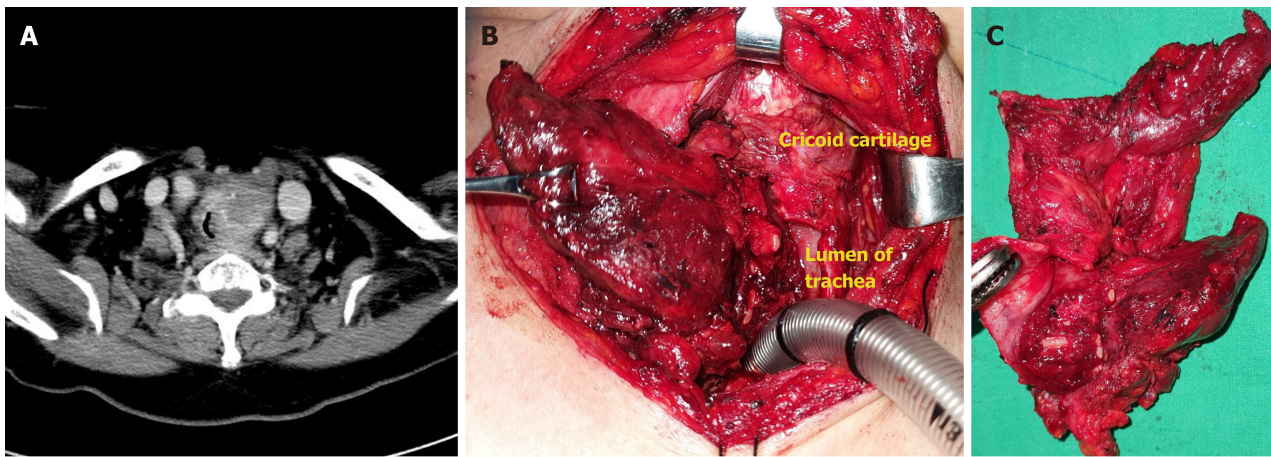
The patient started on dabrafenib (150 mg BID) plus trametinib (2 mg QD) as an adjuvant chemotherapy.

## OUTCOME AND FOLLOW-UP

Following the administration of this treatment regimen for three months, the pulmonary nodule in the right lower lobe disappeared on a follow-up chest CT scan. The patient is currently in complete response at the 32-mo follow-up. No adverse effects except for nausea, constipation and indigestion were noted during administration of the drugs. Most of symptoms improved with symptomatic treatment. After 3 and 6 mo of surgery, the thyroglobulin (TG) levels were 0.14 and 0.21 ng/mL, respectively. (reference range for TG: 2-70 ng/mL). Medication was administered from 7 mo after the first surgery. After 5 and 16 mo of the target therapy, it measured 0.07 and 0.28 ng/mL, respectively. Throughout the follow-up period, the TG levels indicated a serologically complete response state.

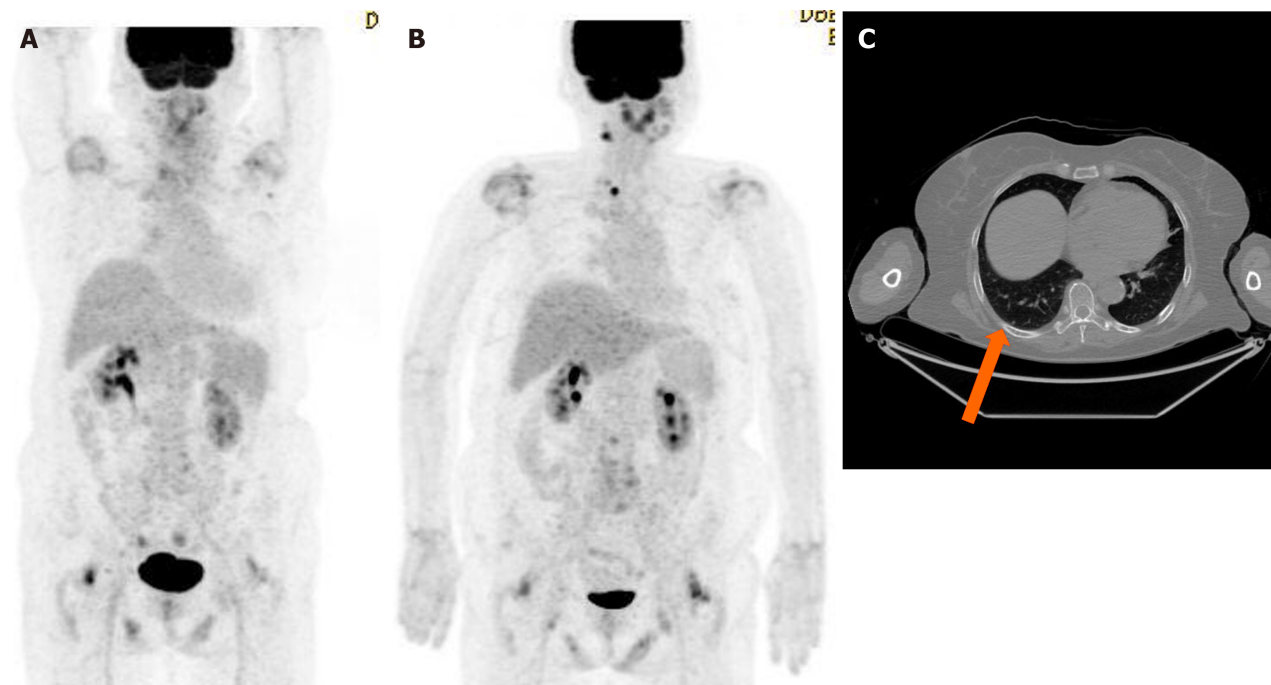
## DISCUSSION

A previous clinical trial reported that the overall response rate of dabrafenib plus trametinib treatment for *BRAF* V600E-mutant ATC was 56%, and that the 12-mo duration of the response was 50%[2,3]. Although adverse events occurred in 100% of cases, grade 3 or 4 adverse events were only noted in 58% of cases. The most common adverse event was pyrexia, and the most severe adverse events included anemia, hyponatremia, and pneumonia. Among the 34 participants in that clinical trial, medication was discontinued for six (17%) due to adverse events[2,3]. While there are some reports regarding the safety of dabrafenib and trametinib for *BRAF* V600E-mutant melanoma, there have been no studies on their safety and dose adjustment for treating ATC[7]. The drug manufacturer indicates that for dabrafenib, the dosage can be reduced to 150, 100, 75, or 50 mg BID; and for trametinib, dosages of 2, 1.5, or 1 mg QD can be adjusted while monitoring for side effects. A case has been reported where dosage adjustments (dabrafenib 150 mg QD + trametinib 1 mg QD) were made to prevent rhabdomyolysis and achieve therapeutic effects in *BRAF* V600E-mutant non-small cell lung cancer[8]. However, a study conducted on *BRAF* V600E-mutant melanoma reported higher side effects with full dose usage, but superior progression-free survival[9]. Due to the limited number of ATC cases that have been reported, studies involving dosage adjustments are lacking at this time. Although the rate of adverse events from this treatment has been found to be relatively high, the effectiveness of the treatment generally outweighs the severity of the adverse events. Therefore,



DOI: 10.12998/wjcc.v11.i27.6664 Copyright ©The Author(s) 2023.

**Figure 1 Imaging and findings of the thyroid mass.** A: Neck computed tomography showing a mass of heterogeneous density in the left thyroid gland invading left side of tracheal wall; B and C: Gross invasion of the thyroid mass into the surrounding structures was noted during surgery.



DOI: 10.12998/wjcc.v11.i27.6664 Copyright ©The Author(s) 2023.

**Figure 2 Positron emission tomography/computed tomography findings.** A: Initial positron emission tomography/computed tomography (PET/CT) showing no distant metastasis; B: PET/CT performed at two months post-surgery showing newly developed lesions in the right levels II and VI, along with a pulmonary nodule in the right lower lobe; C: PET/CT showing a 3 mm metastatic pulmonary nodule (orange arrow) in the right lower lobe.

Careful observation for adverse events and appropriate symptomatic treatment are essential during treatment with dabrafenib plus trametinib.

This case exhibits several differences from the existing clinical trials[2,3]. First, the pre-operative diagnosis through core needle biopsy was PTC; however, post-operative pathological examination confirmed mixed anaplastic (70%) and papillary (30%) carcinomas. This case provided insights into appropriate treatments for patients with PTC and anaplastic dedifferentiation. Second, we were able to secure time and achieve definitive local control through multiple neck dissections in the context of recurrent neck relapses. Additionally, adjuvant chemotherapy was administered to treat the metastatic lung nodule. The ATA guidelines recommend dabrafenib plus trametinib as the optimal initial treatment for unresectable *BRAF* V600E-mutant ATC[4]. This case is unique because we performed complete resection through surgery and the patient received new targeted chemotherapy rather than conventional concurrent chemoradiotherapy based on a cytotoxic agent. However, the therapeutic effects of dabrafenib plus trametinib for other treatment types, such as adjuvant, neoadjuvant, and palliative treatments, have not yet been fully elucidated. Given the aggressive nature of ATC, death may occur even while treatment with dabrafenib and trametinib is being considered. It is important to diagnose and initiate treatment accurately and promptly. In the case reported here, although the patient initially refused

chemotherapy, we were able to extend the survival of the patient through a salvage surgery thereby securing time. In rare but aggressive cancers such as ATC, conducting randomized controlled trials to demonstrate the efficacy of potential therapies remains a challenge. Therefore, it is important to report various clinical cases to compile global data and generate meaningful results.

PTC precedes or coexists with ATC in 50% of cases. *BRAF*-V600 mutations affect the transition from PTC to ATC[2,3]. ATC concurrent with PTC may be more responsive to treatment with dabrafenib and trametinib, as this combination specifically blocks the underlying mechanism behind the malignancy[7]. Owing to the limitations of the needle biopsy technique, PTC concurrent with ATC may often be misdiagnosed as PTC alone. As was observed in this case, when clinical findings show extensive invasion of PTC to the surrounding tissues, the possibility of misdiagnosis and transformation to ATC should be considered.

## CONCLUSION

We present a case of recurrent and metastatic ATC following three surgical resections, which was successfully treated with dabrafenib plus trametinib, suggesting that dabrafenib plus trametinib is a promising option as an adjuvant chemotherapy. In cases where a *BRAF* mutation is confirmed following surgery, treatment with dabrafenib plus trametinib may prevent additional recurrences. Further studies and case reports are necessary to compare available treatment options and establish standardized guidelines for the treatment of ATC.

## FOOTNOTES

**Author contributions:** Lee SJ and Choi YS contributed to the conceptualization, data curation, and writing-review & editing; Bae CH and Na HG contributed to the formal analysis; Song SY and Choi YS contributed to the funding acquisition; Bae CH and Song SY contributed to the investigation; Kim MK and Choi YS contributed to the methodology and supervision; Kim YD and Bae CH contributed to the project administration; Lee SJ and Na HG contributed to the visualization; Lee SJ wrote the original draft.

**Supported by** the 2023 Yeungnam University Research Grant.

**Informed consent statement:** Informed written consent was obtained from the patient for publication of this report and any accompanying images.

**Conflict-of-interest statement:** The authors have nothing to disclose pertaining to this article.

**CARE Checklist (2016) statement:** The authors have read the CARE Checklist (2016), and the manuscript was prepared and revised according to the CARE Checklist (2016).

**Open-Access:** This article is an open-access article that was selected by an in-house editor and fully peer-reviewed by external reviewers. It is distributed in accordance with the Creative Commons Attribution NonCommercial (CC BY-NC 4.0) license, which permits others to distribute, remix, adapt, build upon this work non-commercially, and license their derivative works on different terms, provided the original work is properly cited and the use is non-commercial. See: <https://creativecommons.org/licenses/by-nc/4.0/>

**Country/Territory of origin:** South Korea

**ORCID number:** Sang Jae Lee 0000-0003-2368-4524; Si-Youn Song 0000-0001-6642-8841; Min Kyoung Kim 0000-0003-0088-0995; Hyung Gyun Na 0000-0003-4017-4796; Chang Hoon Bae 0000-0002-0835-4060; Yong-Dae Kim 0000-0003-0501-966X; Yoon Seok Choi 0000-0002-0616-7122.

**S-Editor:** Yan JP

**L-Editor:** A

**P-Editor:** Xu ZH

## REFERENCES

- 1 **Ferrari SM**, Elia G, Ragusa F, Ruffilli I, La Motta C, Paparo SR, Patrizio A, Vita R, Benvenia S, Materazzi G, Fallahi P, Antonelli A. Novel treatments for anaplastic thyroid carcinoma. *Gland Surg* 2020; **9**: S28-S42 [PMID: 32055496 DOI: 10.21037/gs.2019.10.18]
- 2 **Subbiah V**, Kreitman RJ, Wainberg ZA, Cho JY, Schellens JHM, Soria JC, Wen PY, Zielinski CC, Cabanillas ME, Boran A, Ilankumaran P, Burgess P, Romero Salas T, Keam B. Dabrafenib plus trametinib in patients with BRAF V600E-mutant anaplastic thyroid cancer: updated analysis from the phase II ROAR basket study. *Ann Oncol* 2022; **33**: 406-415 [PMID: 35026411 DOI: 10.1016/j.annonc.2021.12.014]
- 3 **Subbiah V**, Kreitman RJ, Wainberg ZA, Cho JY, Schellens JHM, Soria JC, Wen PY, Zielinski C, Cabanillas ME, Urbanowitz G, Mookerjee B, Wang D, Rangwala F, Keam B. Dabrafenib and Trametinib Treatment in Patients With Locally Advanced or Metastatic BRAF V600-Mutant Anaplastic Thyroid Cancer. *J Clin Oncol* 2018; **36**: 7-13 [PMID: 29072975 DOI: 10.1200/JCO.2017.73.6785]
- 4 **Bible KC**, Kebebew E, Brierley J, Brito JP, Cabanillas ME, Clark TJ Jr, Di Cristofano A, Foote R, Giordano T, Kasperbauer J, Newbold K, Nikiforov YE, Randolph G, Rosenthal MS, Sawka AM, Shah M, Shaha A, Smallridge R, Wong-Clark CK. 2021 American Thyroid

Association Guidelines for Management of Patients with Anaplastic Thyroid Cancer. *Thyroid* 2021; **31**: 337-386 [PMID: [33728999](#) DOI: [10.1089/thy.2020.0944](#)]

- 5 **Lorimer C**, Cheng L, Chandler R, Garcez K, Gill V, Graham K, Grant W, Sardo Infirri S, Wadsley J, Wall L, Webber N, Wong KH, Newbold K. Dabrafenib and Trametinib Therapy for Advanced Anaplastic Thyroid Cancer - Real-World Outcomes From UK Centres. *Clin Oncol (R Coll Radiol)* 2023; **35**: e60-e66 [PMID: [36379836](#) DOI: [10.1016/j.clon.2022.10.017](#)]
- 6 **Arikan R**, Telli TA, Demircan NC, Başoğlu T, Ercelep Ö, Atasoy BM, Özgüven S, Dane F, Yumuk PF. Rechallenge with dabrafenib plus trametinib in anaplastic thyroid cancer: A case report and review of literature. *Curr Probl Cancer* 2021; **45**: 100668 [PMID: [33127167](#) DOI: [10.1016/j.cupr.2020.100668](#)]
- 7 **González-Barrallo I**, Castellón Rubio VE, Medina J, España S, Mujika K, Majem M, Aguado C, Cabrera Suárez MÁ, Palacio I, Osterloh L, Martínez-Fernández A, García-Castaño A. Safety of combining dabrafenib plus trametinib in elderly BRAF V600 mutation-positive advanced melanoma patients: real-world data analysis of Spanish patients (ELDERLYMEL). *Melanoma Res* 2022; **32**: 343-352 [PMID: [35762583](#) DOI: [10.1097/CMR.0000000000000837](#)]
- 8 **Adachi Y**, Yanagimura N, Suzuki C, Ootani S, Tanimoto A, Nishiyama A, Yamashita K, Ohtsubo K, Takeuchi S, Yano S. Reduced doses of dabrafenib and trametinib combination therapy for BRAF V600E-mutant non-small cell lung cancer prevent rhabdomyolysis and maintain tumor shrinkage: a case report. *BMC Cancer* 2020; **20**: 156 [PMID: [32093631](#) DOI: [10.1186/s12885-020-6626-9](#)]
- 9 **Flaherty KT**, Infante JR, Daud A, Gonzalez R, Kefford RF, Sosman J, Hamid O, Schuchter L, Cebon J, Ibrahim N, Kudchadkar R, Burris HA 3rd, Falchook G, Algazi A, Lewis K, Long GV, Puzanov I, Lebowitz P, Singh A, Little S, Sun P, Allred A, Ouellet D, Kim KB, Patel K, Weber J. Combined BRAF and MEK inhibition in melanoma with BRAF V600 mutations. *N Engl J Med* 2012; **367**: 1694-1703 [PMID: [23020132](#) DOI: [10.1056/NEJMoa1210093](#)]



Published by **Baishideng Publishing Group Inc**  
7041 Koll Center Parkway, Suite 160, Pleasanton, CA 94566, USA

**Telephone:** +1-925-3991568

**E-mail:** [bpgoffice@wjgnet.com](mailto:bpgoffice@wjgnet.com)

**Help Desk:** <https://www.f6publishing.com/helpdesk>

<https://www.wjgnet.com>

