

# World Journal of *Clinical Cases*

*World J Clin Cases* 2023 October 6; 11(28): 6670-6973



## MINIREVIEWS

- 6670 Neurotransmitters regulate  $\beta$  cells insulin secretion: A neglected factor  
*Kong CC, Cheng JD, Wang W*

## ORIGINAL ARTICLE

## Case Control Study

- 6680 Factors influencing the surveillance of re-emerging intracranial infections in elective neurosurgical patients: A single-center retrospective study  
*Wang JL, Wu XW, Wang SN, Liu X, Xiao B, Wang Y, Yu J*

## Retrospective Study

- 6688 Clinical value of chemiluminescence method for detection of antinuclear antibody profiles  
*Xiang HY, Xiang XY, Ten TB, Ding X, Liu YW, Luo CH*
- 6698 Value of ultrasound guided biopsy combined with Xpert *Mycobacterium tuberculosis*/resistance to rifampin assay in the diagnosis of chest wall tuberculosis  
*Yan QH, Chi JY, Zhang L, Xue F, Cui J, Kong HL*
- 6707 Research on the intelligent internet nursing model based on the child respiratory and asthma control test scale for asthma management of preschool children  
*Pei CF, Zhang L, Xu XY, Qin Z, Liang HM*
- 6715 Effects of different doses of long-acting growth hormone in treating children with growth hormone deficiency  
*Xia W, Wang T, Pan JY*
- 6725 Efficacy and anti-inflammatory analysis of glucocorticoid, antihistamine and leukotriene receptor antagonist in the treatment of allergic rhinitis  
*Qiu C, Feng D*
- 6733 Subchondral fatigue fracture of the femoral head in young military recruits: Potential risk factors  
*Yang JZ, Chen P, Chen BH, Zhao B*
- 6744 Anemia status of infants and young children aged six to thirty-six months in Ma'an Shan City: A retrospective study  
*Wang XM, Wang QY, Huang J*
- Observational Study
- 6754 Impact of coronary artery bypass grafting surgery on the chorioretinal biomicroscopic characteristics  
*Shahriari M, Nikkhah H, Mahjoob MP, Behnaz N, Barkhordari S, Cheraqpour K*

**Prospective Study**

- 6763** Effects of humanized nursing care on negative emotions and complications in patients undergoing hysteromyoma surgery  
*Liu L, Xiao YH, Zhou XH*

**Randomized Controlled Trial**

- 6774** Randomized controlled trial on the efficacy and safety of autologous serum eye drops in dry eye syndrome  
*Zheng N, Zhu SQ*

**SYSTEMATIC REVIEWS**

- 6782** Primary adrenal Ewing sarcoma: A systematic review of the literature  
*Manatakis DK, Tsouknidas I, Mylonakis E, Tasis NP, Antonopoulou MI, Acheimastos V, Mastoropoulou A, Korkolis DP*

**CASE REPORT**

- 6792** Pulmonary artery aneurysm protruding into the bronchus as an endobronchial mass: A case report  
*Li M, Zhu WY, Wu RR, Wang L, Mo MT, Liu SN, Zhu DY, Luo Z*
- 6797** Rare rectal gastrointestinal stromal tumor case: A case report and review of the literature  
*Dong RX, Wang C, Zhou H, Yin HQ, Liu Y, Liang HT, Pan YB, Wang JW, Cao YQ*
- 6806** Bilateral retinal nerve fiber layer thickness reduction in a 9-year-old myopic boy suffering from unilateral optic neuritis: A case report  
*Zhao FF, Yao SQ, Wang Y, Li TP, Yang JF, Pang CP, Cen LP*
- 6812** Application of negative pressure wound therapy after skin grafting in the treatment of skin cancer: A case report  
*Huang GS, Xu KC*
- 6817** Diagnosis and treatment of McCune-Albright syndrome: A case report  
*Lin X, Feng NY, Lei YJ*
- 6823** Paraneoplastic myopathy-related rhabdomyolysis and pancreatic cancer: A case report and review of the literature  
*Costantini A, Moletta L, Pierobon ES, Serafini S, Valmasoni M, Sperti C*
- 6831** Multi-organ hereditary hemorrhagic telangiectasia: A case report  
*Chen YL, Jiang HY, Li DP, Lin J, Chen Y, Xu LL, Gao H*
- 6841** Hyperprogression after anti-programmed death-1 therapy in a patient with urothelial bladder carcinoma: A case report  
*Yang HY, Du YX, Hou YJ, Lu DR, Xue P*
- 6850** Effectiveness of antidepressant repetitive transcranial magnetic stimulation in a patient with refractory psychogenic dysphagia: A case report and review of literature  
*Woo CG, Kim JH, Lee JH, Kim HJ*

- 6857** Entrapment neuropathy of common peroneal nerve by fabella: A case report  
*Lin JC, Tsai MH, Lin WP, Kuan TS, Lien WC*
- 6864** Importance of accurate diagnosis of congenital agenesis of the gallbladder from atypical gallbladder stone presentations: A case report  
*Sun HJ, Ge F, Si Y, Wang Z, Sun HB*
- 6871** Dorsal approach for isolated volar fracture-dislocation of the base of the second metacarpal: A case report  
*Kurozumi T, Saito M, Odachi K, Masui F*
- 6877** Rotationplasty type BIIIb as an effective alternative to limb salvage procedure in adults: Two case reports  
*Chen ZX, Guo XW, Hong HS, Zhang C, Xie W, Sha M, Ding ZQ*
- 6889** Primary cutaneous anaplastic large cell lymphoma with over-expressed Ki-67 transitioning into systemic anaplastic large cell lymphoma: A case report  
*Mu HX, Tang XQ*
- 6895** Confusing finding of quantitative fluorescent polymerase chain reaction analysis in invasive prenatal genetic diagnosis: A case report  
*Chen C, Tang T, Song QL, He YJ, Cai Y*
- 6902** Testicular mixed germ cell tumor: A case report  
*Xiao QF, Li J, Tang B, Zhu YQ*
- 6908** Leukemic transformation during anti-tuberculosis treatment in aplastic anemia-paroxysmal nocturnal hemoglobinuria syndrome: A case report and review of literature  
*Xiu NN, Yang XD, Xu J, Ju B, Sun XY, Zhao XC*
- 6920** Pancreatic arteriovenous malformation treated with transcatheter arterial embolization: Two case reports and review of literature  
*Shin SH, Cho CK, Yu SY*
- 6931** Cecal duplication cyst in an infant presenting as shock: A case report  
*Kim SM, Lee SH, Park GY, Kim SS, Lee CG, Jin SJ*
- 6938** Pulmonary reversed halo cycles and consolidations after immunotherapy: A case report  
*Suo H, Shi YJ, Huang ZD, Xu K, Huang H*
- 6943** Unusual case of emphysematous cystitis mimicking intestinal perforation: A case report  
*Kang HY, Lee DS, Lee D*
- 6949** Malignant proliferative ependymoma of the neck with lymph node metastasis: A case report  
*Wang K, Wen JZ, Zhou SX, Ye LF, Fang C, Chen Y, Wang HX, Luo X*
- 6955** Wandering spleen torsion with portal vein thrombosis: A case report  
*Zhu XY, Ji DX, Shi WZ, Fu YW, Zhang DK*

- 6961** Intracranial infection and sepsis in infants caused by *Salmonella derby*: A case report  
*Yu JL, Jiang LL, Dong R, Liu SY*
- 6967** Large gastric hamartomatous inverted polyp accompanied by advanced gastric cancer: A case report  
*Park G, Kim J, Lee SH, Kim Y*

**ABOUT COVER**

Editorial Board Member of *World Journal of Clinical Cases*, Hao Wang, MD, PhD, Associate Professor, Department of Emergency Medicine, John Peter Smith Health Network, Texas Christian University and University of North Texas Health Science Center, School of Medicine, Fort Worth, TX 76104, United States. [hwang@ies.healthcare](mailto:hwang@ies.healthcare)

**AIMS AND SCOPE**

The primary aim of *World Journal of Clinical Cases* (*WJCC*, *World J Clin Cases*) is to provide scholars and readers from various fields of clinical medicine with a platform to publish high-quality clinical research articles and communicate their research findings online.

*WJCC* mainly publishes articles reporting research results and findings obtained in the field of clinical medicine and covering a wide range of topics, including case control studies, retrospective cohort studies, retrospective studies, clinical trials studies, observational studies, prospective studies, randomized controlled trials, randomized clinical trials, systematic reviews, meta-analysis, and case reports.

**INDEXING/ABSTRACTING**

The *WJCC* is now abstracted and indexed in Science Citation Index Expanded (SCIE, also known as SciSearch®), Journal Citation Reports/Science Edition, Current Contents®/Clinical Medicine, PubMed, PubMed Central, Reference Citation Analysis, China National Knowledge Infrastructure, China Science and Technology Journal Database, and Superstar Journals Database. The 2023 Edition of Journal Citation Reports® cites the 2022 impact factor (IF) for *WJCC* as 1.1; IF without journal self cites: 1.1; 5-year IF: 1.3; Journal Citation Indicator: 0.26; Ranking: 133 among 167 journals in medicine, general and internal; and Quartile category: Q4.

**RESPONSIBLE EDITORS FOR THIS ISSUE**

Production Editor: *Si Zhao*; Production Department Director: *Xu Guo*; Editorial Office Director: *Jin-Lei Wang*.

**NAME OF JOURNAL**

*World Journal of Clinical Cases*

**ISSN**

ISSN 2307-8960 (online)

**LAUNCH DATE**

April 16, 2013

**FREQUENCY**

Thrice Monthly

**EDITORS-IN-CHIEF**

Bao-Gan Peng, Jerzy Tadeusz Chudek, George Kontogeorgos, Maurizio Serati, Ja Hyeon Ku

**EDITORIAL BOARD MEMBERS**

<https://www.wjgnet.com/2307-8960/editorialboard.htm>

**PUBLICATION DATE**

October 6, 2023

**COPYRIGHT**

© 2023 Baishideng Publishing Group Inc

**INSTRUCTIONS TO AUTHORS**

<https://www.wjgnet.com/bpg/gerinfo/204>

**GUIDELINES FOR ETHICS DOCUMENTS**

<https://www.wjgnet.com/bpg/GerInfo/287>

**GUIDELINES FOR NON-NATIVE SPEAKERS OF ENGLISH**

<https://www.wjgnet.com/bpg/gerinfo/240>

**PUBLICATION ETHICS**

<https://www.wjgnet.com/bpg/GerInfo/288>

**PUBLICATION MISCONDUCT**

<https://www.wjgnet.com/bpg/gerinfo/208>

**ARTICLE PROCESSING CHARGE**

<https://www.wjgnet.com/bpg/gerinfo/242>

**STEPS FOR SUBMITTING MANUSCRIPTS**

<https://www.wjgnet.com/bpg/GerInfo/239>

**ONLINE SUBMISSION**

<https://www.f6publishing.com>

# Malignant proliferative ependymoma of the neck with lymph node metastasis: A case report

Ke Wang, Jia-Zhu Wen, Shu-Xia Zhou, Lin-Feng Ye, Chun Fang, Yan Chen, Hai-Xia Wang, Xiao Luo

**Specialty type:** Medicine, research and experimental

**Provenance and peer review:** Unsolicited article; Externally peer reviewed.

**Peer-review model:** Single blind

**Peer-review report's scientific quality classification**

Grade A (Excellent): 0  
Grade B (Very good): 0  
Grade C (Good): C  
Grade D (Fair): D  
Grade E (Poor): 0

**P-Reviewer:** Garg P, India;  
Jeyaraman M, India

**Received:** July 29, 2023

**Peer-review started:** July 29, 2023

**First decision:** August 10, 2023

**Revised:** August 21, 2023

**Accepted:** September 11, 2023

**Article in press:** September 11, 2023

**Published online:** October 6, 2023



**Ke Wang, Jia-Zhu Wen, Shu-Xia Zhou, Lin-Feng Ye, Chun Fang, Yan Chen, Hai-Xia Wang,** Department of Radiology, The Second People's Hospital of Quzhou, Quzhou 324000, Zhejiang Province, China

**Xiao Luo,** Department of Radiology, The Second Affiliated Hospital of Zhejiang University School of Medicine, Hangzhou 310009, Zhejiang Province, China

**Corresponding author:** Xiao Luo, MD, Attending Doctor, Department of Radiology, The Second Affiliated Hospital of Zhejiang University School of Medicine, No. 88 Jiefang Road, Shangcheng District, Hangzhou 310009, Zhejiang Province, China. [luoxiao1990@zju.edu.cn](mailto:luoxiao1990@zju.edu.cn)

## Abstract

### BACKGROUND

Malignant proliferating trichilemmal tumor (MPTT) is an infrequent malignant neoplasm originating from cutaneous appendages, with only a handful of documented cases. This report delineates a unique instance of MPTT situated in the neck, accompanied by lymph node metastasis. A comprehensive exposition of its clinical trajectory and imaging manifestation is presented, aiming to enhance comprehension and management of this atypical ailment.

### CASE SUMMARY

Patient concerns: A 79-year-old male presented with a longstanding right neck mass persisting for over six decades, exhibiting recent enlargement over the past year. Diagnoses: Enhanced magnetic resonance imaging of the neck unveiled an elliptical mass on the right neck side, characterized by an ill-defined border and a heterogeneous signal pattern. The mass exhibited subdued signal intensity on T1-weighted imaging (T1WI) and a heterogeneous high signal on T2-weighted imaging (T2WI), interspersed with a lengthy T1 and T2 cystic signal motif. Close anatomical association with the submandibular gland joint was noted, and intravenous gadolinium diethylene triamine pentaacetic acid administration facilitated conspicuous enhancement. Substantial enhancement of the solid segment prompted an initial preoperative diagnosis of malignant nerve sheath tumor. However, post-surgery histopathological and immunohistochemical analysis conclusively confirmed the diagnosis as malignant hyperplastic external hair root sheath tumor. Intervention: Complete excision of the tumor was successfully executed. Outcomes: The patient experienced a favorable postoperative recovery.

### CONCLUSION

Malignant proliferative trichilemmal tumor external hair root sheath tumor is a cystic-solid lesion, appearing as low signal on T1WI images or high signal on T2WI with enhancement of the solid component. Suspicions of malignancy are heightened when the tumor border is indistinct, tissue planes are breached, or when linear or patchy high signals are observed in the subcutaneous tissue on T1 liver acquisition with volume acceleration enhanced images along with intermediate signal on T2WI and restricted diffusion on diffusion-weighted imaging images. Strong consideration for malignancy should arise if there are signs of compromised adjacent tissue relationships or direct invasion evident on imaging. We have incorporated the above-mentioned content into the entire manuscript.

**Key Words:** Magnetic resonance imaging; Proliferating trichilemmal tumour; Head and neck imaging; Lymph node metastasis; Computed tomography; Case report

©The Author(s) 2023. Published by Baishideng Publishing Group Inc. All rights reserved.

**Core Tip:** Malignant proliferating trichilemmal tumor (PTT) is an infrequent malignant neoplasm originating from cutaneous appendages, with only a handful of documented cases. This report delineates a unique instance of malignant PTT situated in the neck, accompanied by lymph node metastasis. A comprehensive exposition of its clinical trajectory and imaging manifestation is presented, aiming to enhance comprehension and management of this atypical ailment.

**Citation:** Wang K, Wen JZ, Zhou SX, Ye LF, Fang C, Chen Y, Wang HX, Luo X. Malignant proliferative ependymoma of the neck with lymph node metastasis: A case report. *World J Clin Cases* 2023; 11(28): 6949-6954

**URL:** <https://www.wjgnet.com/2307-8960/full/v11/i28/6949.htm>

**DOI:** <https://dx.doi.org/10.12998/wjcc.v11.i28.6949>

## INTRODUCTION

Proliferating trichilemmal tumor (PTT) is an uncommon neoplasm originating from the outer hair sheath of the follicular isthmus within the dermis. It is characterized by well-defined borders, squamous cell attributes, and hyperkeratosis of the hair sheath[1]. The etiology of PTT remains enigmatic, although potential risk factors include infection, trauma, and exposure to ultraviolet light. The inaugural documented instance of PTT dates back to Jones' report in 1966[2]. PTT predominantly emerges in sun-exposed regions of the body, with the head's skin being the most frequent site[1,3]. Epidemiologically, this condition predominantly affects middle-aged and older women[4].

PTT represents a generally benign neoplasm with rare proclivity toward malignancy. In 1983, Saida *et al*[5] documented the initial case of malignant PTT (MPTT)[6]. Distorted mitosis, cytological diversity, peripheral infiltration, and aneuploidy have been observed across various cases[7]. PTT itself is a rarity, and the occurrence of MPTT accompanied by lymph node metastasis is exceedingly infrequent[8]. This article presents an exhaustive scrutiny of the clinical manifestation, imaging attributes, and surgical intervention strategy concerning a patient exhibiting typical clinical characteristics of malignant proliferative ependymoma in the neck, featuring lymph node metastasis.

## CASE PRESENTATION

### Chief complaints

Patient presents with a lump on the right side of the neck, which has been present for over 60 years and has increased in size over the past year.

### History of present illness

The patient noticed the lump on the right side of the neck over 60 years ago, measuring approximately the size of a pigeon egg. At that time, there was no significant pain, limb numbness, voice hoarseness, chills, fever, productive cough, hemoptysis, abdominal distension, diarrhea, nausea, vomiting, chest discomfort, or dyspnea. Initial attention was not given to the lump. The neck lump has remained stable in size for over 60 years. However, during the last year, the patient observed a gradual enlargement of the lump on the right side of the neck, reaching the size of an egg.

### History of past illness

The patient's overall health has generally been good. There is no history of chronic conditions such as hypertension, diabetes, cardiovascular or cerebrovascular diseases, respiratory issues, digestive disorders, kidney diseases, infectious diseases, or endemic ailments. No surgical procedures or significant injuries have been experienced. Blood transfusions have not been undergone. The patient has reported allergies to cephalosporins and penicillin. Vaccination history is up-



to-date according to local standards.

### Personal and family history

**Personal history:** The patient was born and raised in Quzhou, Zhejiang. Current residence is in Shiping village, Dazhou town. No history of residing in epidemic-prone areas. Education level is elementary school, and the patient's occupation is farming.

**Family history:** The cause of death for both parents remains unknown. There are one brother and one sister, both in good health, denying any shared illnesses or genetically linked conditions with the patient.

### Physical examination

Vital signs: (1) Temperature 36.6 °C, pulse 78 (beats/min), respiration 19 (breaths/min), blood pressure 122/80 mmHg, numeric rating scale pain score 0; (2) General: Height 155 cm, weight 54 kg, alert and oriented, normal development, well-nourished, autonomous posture, normal gait, no signs of illness, natural expressions, cooperative during examination; (3) Skin and mucosa: Normal color, no swelling, no rash, normal temperature and humidity, normal elasticity, no ecchymosis, normal hair distribution, no ulcers or scars, superficial lymph nodes not enlarged; (4) Head: Normal size and shape, no tenderness, no masses; (5) Eyes: No abnormalities in eyelids, eyelashes, conjunctiva, eyeballs, or sclera. Pupils are equal and react to light; (6) Ears: Hearing tested roughly with no abnormalities, no abnormalities in external ear, no secretions, no tenderness in mastoid; (7) Nose and throat: No abnormalities in nose, symmetrical nasal wing movement, adequate ventilation, no tenderness in nasal area, no tonsillar or pharyngeal abnormalities, trachea centrally located, no abnormalities in jugular veins; (8) Cardiovascular: No abnormal pulsations, heart sounds normal, no murmurs; (9) Lungs: Normal breathing movements, normal vocal resonance, no pleural friction rub, no subcutaneous crepitus, resonant percussion sound, lung borders at the 10<sup>th</sup> rib at the scapular line, respiration sounds clear, no pleural friction sounds; (10) Heart: Normal cardiac impulse, no abnormal pulsations, regular heart rate at 78 beats/min, no abnormal heart sounds, no pericardial friction rub; (11) Abdomen: Normal shape, abdominal breathing present, normal umbilicus, no scars, no abdominal wall tension, no tenderness, no rebound tenderness, no fluid wave, no masses, no McBurney's point tenderness; (12) Liver: Liver not palpable below the rib, liver dullness and liver span normal, no tenderness, no pulsations, no hepatomegaly, no jugular venous reflux; (13) Gastrointestinal: Normal bowel sounds, no visible peristalsis, no abdominal masses; (14) Rectal examination: No abnormalities; (15) Genitalia: No abnormalities; (16) Spine and extremities: No abnormalities in spine, no tenderness, normal mobility, no abnormalities in limbs, no finger clubbing, no joint redness or swelling, no joint stiffness, no muscle wasting or tenderness, normal muscle strength, no varicose veins; and (17) Neurological: Normal cranial nerves, normal superficial and deep sensation, normal muscle strength, normal muscle tone, normal gait, normal reflexes.

### Laboratory examinations

Blood routine, liver and kidney function, electrolytes, coagulation function, and hepatitis B panel all show no significant abnormalities.

### Imaging examinations

Enhanced magnetic resonance imaging of the neck unveiled an elliptical mass on the right neck side, characterized by an ill-defined border and a heterogeneous signal pattern. The mass exhibited subdued signal intensity on T1-weighted imaging (T1WI) and a heterogeneous high signal on T2-weighted imaging (T2WI) interspersed with a lengthy T1 and T2 cystic signal motif. Close anatomical association with the submandibular gland joint was noted, and intravenous gadolinium diethylene triamine pentaacetic acid administration facilitated conspicuous enhancement. Substantial enhancement of the solid segment prompted an initial preoperative diagnosis of malignant nerve sheath tumor, as shown in [Figure 1](#). However, post-surgery histopathological and immunohistochemical analysis conclusively confirmed the diagnosis as malignant hyperplastic external hair root sheath tumor.

---

## FINAL DIAGNOSIS

Our final diagnosis of this case was MPTT, and the results were confirmed pathologically, as shown in [Figure 2](#).

---

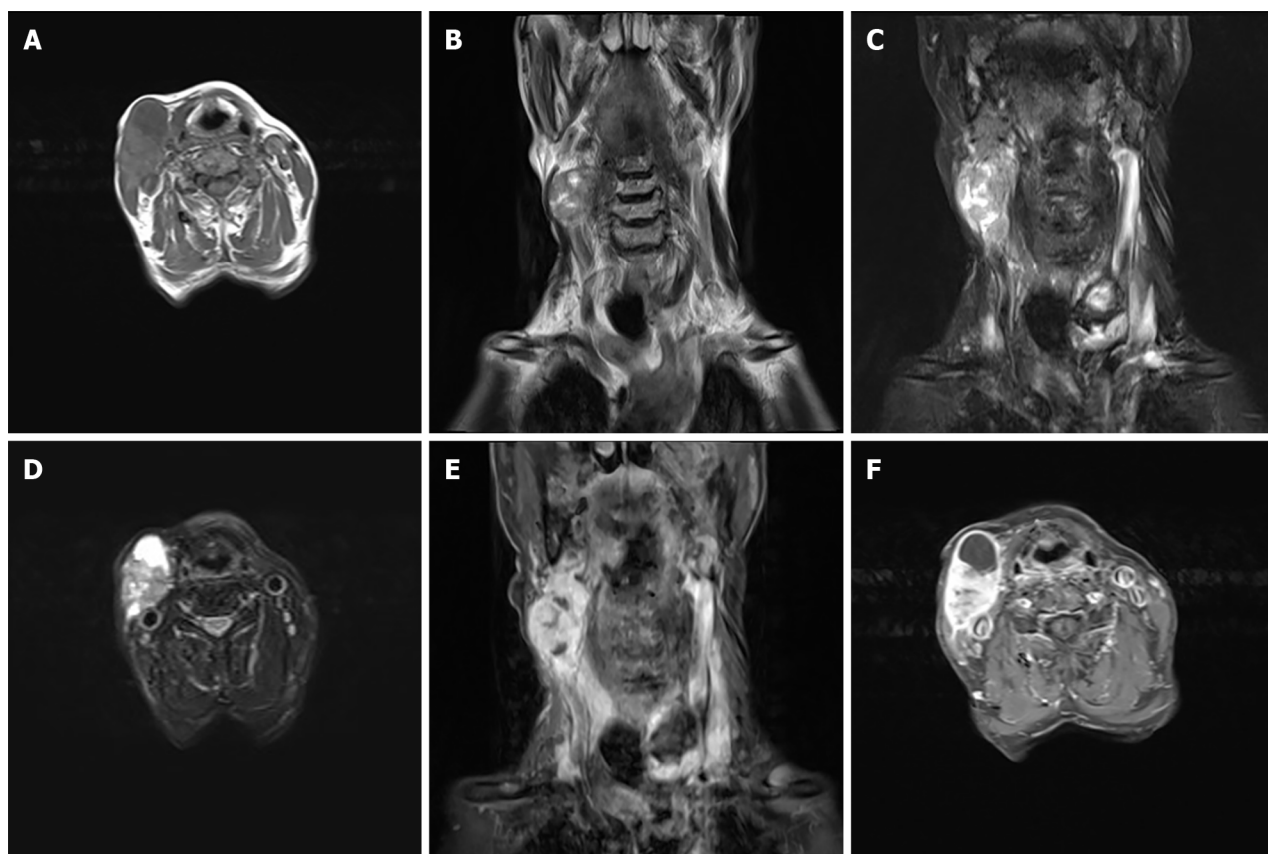
## TREATMENT

Complete excision of the tumor was successfully executed.

---

## OUTCOME AND FOLLOW-UP

The patient experienced a favorable postoperative recovery.



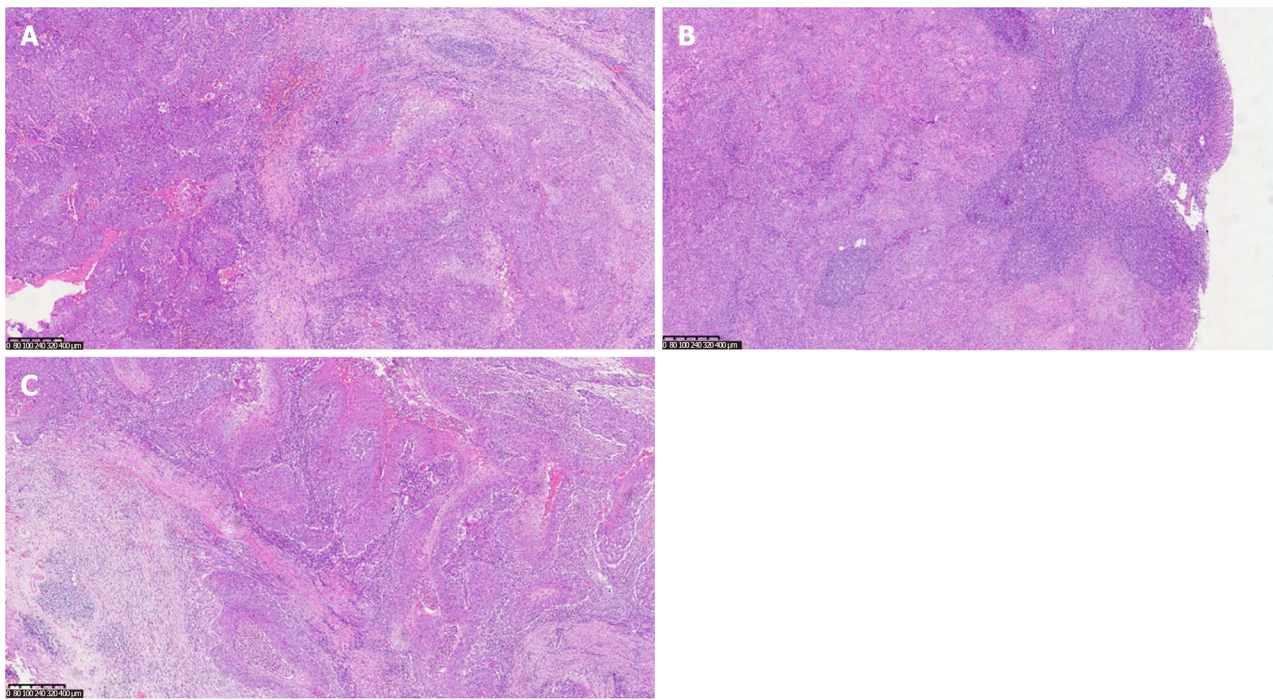
DOI: 10.12998/wjcc.v11.i28.6949 Copyright ©The Author(s) 2023.

**Figure 1 Magnetic resonance imaging scans.** A: Hypointense lesion on T1-weighted images; B and C: Predominantly hypointense and hyperintense lesion on T2-weighted images; D: Mixed signal mass on T2 compression lipid sequence, primarily isointense to hypointense; E and F: Notable heterogeneous enhancement of the mass on contrast-enhanced magnetic resonance imaging.

## DISCUSSION

PTT is a rare cutaneous tumor, with research indicating that 80% of affected individuals are women over the age of 60[3]. Predominantly, 90% of these tumors manifest on the scalp, followed by occurrences on the forehead and neck skin[9]. Moreover, most instances of MPTT are conceived as localized malignancies evolving from pre-existing PTT lesions[10]. It is noteworthy that there exist limited reports of PTT undergoing malignant transformation on the scalp. Thus far, occurrences of MPTT with lymph node metastases within the neck's skin are isolated and scarce. The radiographic representation of PTT/MPTT harmonizes with its clinical manifestation. Lesions on the head and neck typically exhibit characteristics of cystic-solid or cystic masses[10]. Appearing as low signal on T1WI images or high signal on T2WI with enhancement of the solid component. Suspicions of malignancy are heightened when the tumor border is indistinct, tissue planes are breached, or when linear or patchy high signals are observed in the subcutaneous tissue on T1 liver acquisition with volume acceleration enhanced images along with intermediate signal on T2WI and restricted diffusion on diffusion-weighted imaging images. Strong consideration for malignancy should arise if there are signs of compromised adjacent tissue relationships or direct invasion evident on imaging[11].

Proliferative ectodermal root sheath tumors are categorized into three groups: Group I (benign), marked by restricted lesions, mild nuclear heterogeneity, lack of mitotic activity, and absence of necrosis or lymphovascular infiltration; group II (low malignancy), characterized by histological irregularity, localized infiltration, and potential spread to dermal and subcutaneous tissues; and group III (highly malignant), characterized by infiltrative growth, pronounced nuclear heterogeneity, elevated mitotic and necrotic activity, and lymphatic and vascular infiltration[10,12]. Histologically, PTT masses typically display lobulated, well-defined contours without encapsulation. The tumor cells frequently resemble acanthocytes, forming irregular nests or cords, often exhibiting marked central keratinization. Small cystic or glandular lacunae containing keratinized material can be observed, resembling hair follicle differentiation. Nuclei present mild heterogeneity, occasionally with clusters of cells embedded in the mesenchyme and even beads of keratinization, a feature that can lead to confusion with squamous cell carcinoma. In contrast, MPTT tends to occupy deeper layers, mainly within the dermis or subcutaneous tissue. It displays infiltrative growth, notable nuclear heterogeneity, prominent atypical mitosis, and lymph node metastasis[13,14]. While no specific immunohistochemical markers exist for MPTT diagnosis, immunohistochemical studies continue to aid in distinguishing PTT from MPTT. In recent times, markers like p53 and Ki-67 have garnered attention, with certain studies revealing elevated expression of Ki-67 and p53 staining in MPTT. Concerning its biological behavior, PTT, especially MPTT, holds the potential for recurrence and metastasis, giving rise to local lymph node metastases or even distant systemic spread[9].



DOI: 10.12998/wjcc.v11.i28.6949 Copyright ©The Author(s) 2023.

**Figure 2 Pathological findings.** A: Vigorous tumor growth [hepatic encephalopathy (HE) × 100]; B: Lymph node metastasis; C: Tumor nests (HE × 50).

The tumor was situated within the right medial sternocleidomastoid muscle, exhibiting local infiltration, aberrant nuclear division, and lymphatic and vascular infiltration, categorically aligning with the highly malignant PTT category. In the context of the neck tumor, differentiation from lymphoma and malignant nerve sheath tumor is imperative. The primary intervention for MPTT entails surgical resection, necessitating extensive local excision of the tumor alongside approximately 1 cm of surrounding normal tissue to achieve a secure margin[4]. A stringent postoperative follow-up regimen is advisable for MPTT cases. Radiotherapy and chemotherapy have been applied for recurrent MPTT cases; however, given the rarity of this malignancy, published cases are insufficient for a comprehensive assessment of the efficacy and safety of these interventions. In summation, surgical excision remains the principal approach for MPTT management, with long-term monitoring imperative. Alternative therapeutic modalities warrant further comprehensive evaluation.

## CONCLUSION

In summary, this case highlights the rarity and complexity of highly MPTT. Despite its infrequent occurrence, MPTT can lead to lymph node metastases in the neck's skin. Radiographic and histological features correspond with clinical presentation, aiding diagnosis. Surgical resection remains the mainstay of treatment, while the efficacy of alternative therapies needs further exploration. Long-term follow-up is essential, emphasizing the need for continued research in MPTT management.

## FOOTNOTES

**Author contributions:** Wang K and Luo X designed the study, prepared drafted the manuscript; Wen JZ proofed the manuscript in language; Ye LF and Zhou SX contributed to the acquisition of imaging data; Fang C and Chen Y interpreted the findings; Luo X and Wang HX provided critical manuscript revision for important intellectual content; All authors have read and approve the final manuscript.

**Informed consent statement:** Informed written consent was obtained from the patient for publication of this report and any accompanying images.

**Conflict-of-interest statement:** The authors declare that they have no conflict of interest.

**CARE Checklist (2016) statement:** The authors have read the CARE Checklist (2016), and the manuscript was prepared and revised according to the CARE Checklist (2016).

**Open-Access:** This article is an open-access article that was selected by an in-house editor and fully peer-reviewed by external reviewers.



It is distributed in accordance with the Creative Commons Attribution NonCommercial (CC BY-NC 4.0) license, which permits others to distribute, remix, adapt, build upon this work non-commercially, and license their derivative works on different terms, provided the original work is properly cited and the use is non-commercial. See: <https://creativecommons.org/licenses/by-nc/4.0/>

**Country/Territory of origin:** China

**ORCID number:** Xiao Luo [0000-0003-1743-7842](https://orcid.org/0000-0003-1743-7842).

**S-Editor:** Qu XL

**L-Editor:** A

**P-Editor:** Yu HG

## REFERENCES

- 1 **Zhou E**, Xue X, Liu X, Zhang Y. Auricular Malignant Proliferating Trichilemmal Tumor: A Case Report. *Ear Nose Throat J* 2022; 1455613221127586 [PMID: [36123767](https://pubmed.ncbi.nlm.nih.gov/36123767/) DOI: [10.1177/01455613221127586](https://doi.org/10.1177/01455613221127586)]
- 2 **Jones EW**. Proliferating epidermoid cysts. *Arch Dermatol* 1966; **94**: 11-19 [PMID: [5938217](https://pubmed.ncbi.nlm.nih.gov/5938217/)]
- 3 **Çoban K**, Akkaya H, Aydın E. Proliferating Trichilemmal Tumor of the Auricle: A Very Rare Locus. *Indian J Otolaryngol Head Neck Surg* 2019; **71**: 1436-1438 [PMID: [31750191](https://pubmed.ncbi.nlm.nih.gov/31750191/) DOI: [10.1007/s12070-018-1522-1](https://doi.org/10.1007/s12070-018-1522-1)]
- 4 **Kemaloglu CA**, Öztürk M, Aydın B, Canöz Ö, Eğilmez O. Malignant proliferating trichilemmal tumor of the scalp: report of 4 cases and a short review of the literature. *Case Reports Plast Surg Hand Surg* 2022; **9**: 158-164 [PMID: [35634539](https://pubmed.ncbi.nlm.nih.gov/35634539/) DOI: [10.1080/23320885.2022.2077208](https://doi.org/10.1080/23320885.2022.2077208)]
- 5 **Saida T**, Oohara K, Hori Y, Tsuchiya S. Development of a malignant proliferating trichilemmal cyst in a patient with multiple trichilemmal cysts. *Dermatologica* 1983; **166**: 203-208 [PMID: [6852333](https://pubmed.ncbi.nlm.nih.gov/6852333/) DOI: [10.1159/000249868](https://doi.org/10.1159/000249868)]
- 6 **Joshi TP**, Marchand S, Tschen J. Malignant Proliferating Trichilemmal Tumor: A Subtle Presentation in an African American Woman and Review of Immunohistochemical Markers for This Rare Condition. *Cureus* 2021; **13**: e17289 [PMID: [34552829](https://pubmed.ncbi.nlm.nih.gov/34552829/) DOI: [10.7759/cureus.17289](https://doi.org/10.7759/cureus.17289)]
- 7 **Azizi M**, Ramezani M. Malignant proliferating trichilemmal tumor in abdominal wall: Report of a rare case at an uncommon site with literature review. *Clin Case Rep* 2022; **10**: e05259 [PMID: [35028148](https://pubmed.ncbi.nlm.nih.gov/35028148/) DOI: [10.1002/ccr3.5259](https://doi.org/10.1002/ccr3.5259)]
- 8 **Alshaalan ZM**, Patel P, Routt E, Ciocon D. Proliferating Pilar Tumor: Two Cases and a Review of the Literature. *J Drugs Dermatol* 2021; **20**: 1346-1348 [PMID: [34898151](https://pubmed.ncbi.nlm.nih.gov/34898151/) DOI: [10.36849/jdd.5978](https://doi.org/10.36849/jdd.5978)]
- 9 **Wang G**, Zhou X, Luo J, Hu Q, Zhang J. Case report: Malignant proliferating trichilemmal tumor of the thumb. *Front Oncol* 2022; **12**: 1005206 [PMID: [36387268](https://pubmed.ncbi.nlm.nih.gov/36387268/) DOI: [10.3389/fonc.2022.1005206](https://doi.org/10.3389/fonc.2022.1005206)]
- 10 **Kawaguchi M**, Kato H, Suzui N, Miyazaki T, Tomita H, Hara A, Matsuyama K, Seishima M, Matsuo M. Imaging findings of trichilemmal cyst and proliferating trichilemmal tumour. *Neuroradiol J* 2021; **34**: 615-621 [PMID: [34060944](https://pubmed.ncbi.nlm.nih.gov/34060944/) DOI: [10.1177/19714009211017789](https://doi.org/10.1177/19714009211017789)]
- 11 **Singh P**, Usman A, Motta L, Khan I. Malignant proliferating trichilemmal tumour. *BMJ Case Rep* 2018; **2018** [PMID: [30121565](https://pubmed.ncbi.nlm.nih.gov/30121565/) DOI: [10.1136/bcr-2018-224460](https://doi.org/10.1136/bcr-2018-224460)]
- 12 **Weiffenbach A**, Katz K, Rupley K, Carter A, Gottlieb A, Shulman K. Rapidly Enlarging Malignant Proliferating Trichilemmal Tumor in a Young Female. *J Drugs Dermatol* 2018; **17**: 1325-1327 [PMID: [30586266](https://pubmed.ncbi.nlm.nih.gov/30586266/)]
- 13 **Kearns-Turcotte S**, Thériault M, Blouin MM. Malignant proliferating trichilemmal tumors arising in patients with multiple trichilemmal cysts: A case series. *JAAD Case Rep* 2022; **22**: 42-46 [PMID: [35310136](https://pubmed.ncbi.nlm.nih.gov/35310136/) DOI: [10.1016/j.jcdr.2022.01.033](https://doi.org/10.1016/j.jcdr.2022.01.033)]
- 14 **Deshmukh BD**, Kulkarni MP, Momin YA, Sulhyan KR. Malignant proliferating trichilemmal tumor: a case report and review of literature. *J Cancer Res Ther* 2014; **10**: 767-769 [PMID: [25313781](https://pubmed.ncbi.nlm.nih.gov/25313781/) DOI: [10.4103/0973-1482.136036](https://doi.org/10.4103/0973-1482.136036)]



Published by **Baishideng Publishing Group Inc**  
7041 Koll Center Parkway, Suite 160, Pleasanton, CA 94566, USA

**Telephone:** +1-925-3991568

**E-mail:** [bpgoffice@wjgnet.com](mailto:bpgoffice@wjgnet.com)

**Help Desk:** <https://www.f6publishing.com/helpdesk>

<https://www.wjgnet.com>

