

World Journal of *Clinical Cases*

World J Clin Cases 2023 October 16; 11(29): 6974-7260



MINIREVIEWS

- 6974** Applications of time series analysis in epidemiology: Literature review and our experience during COVID-19 pandemic
Tomov L, Chervenkov L, Miteva DG, Batselova H, Velikova T

ORIGINAL ARTICLE**Retrospective Cohort Study**

- 6984** Acute cholangitis: Does malignant biliary obstruction *vs* choledocholithiasis etiology change the clinical presentation and outcomes?
Tsou YK, Su YT, Lin CH, Liu NJ

Retrospective Study

- 6995** Usefulness of analyzing endoscopic features in identifying the colorectal serrated sessile lesions with and without dysplasia
Wang RG, Ren YT, Jiang X, Wei L, Zhang XF, Liu H, Jiang B
- 7004** Roles of biochemistry data, lifestyle, and inflammation in identifying abnormal renal function in old Chinese
Chen CH, Wang CK, Wang CY, Chang CF, Chu TW
- 7017** Clinical efficacy and safety of Guipi decoction combined with escitalopram oxalate tablets in patients with depression
Yu J, Xu FQ
- 7026** Artificial intelligence technology and ultrasound-guided nerve block for analgesia in total knee arthroplasty
Tong SX, Li RS, Wang D, Xie XM, Ruan Y, Huang L
- 7034** Axenfeld-Reiger syndrome: A search for the missing links
Morya AK, Ramesh PV, Sinha S, Nishant P, Nain N, Ramavath RN, Gone C, Prasad R

Observational Study

- 7043** Self-management of osteoarthritis while waiting for total knee arthroplasty during the COVID-19 pandemic among older Malaysians
Mahdzir ANK, Mat S, Seow SR, Abdul Rani R, Che Hasan MK, Mohamad Yahaya NH
- 7053** "In situ bone flap" combined with vascular pedicled mucous flap to reconstruction of skull base defect
Qian M, Chen X, Zhang LY, Wang ZF, Zhang Y, Wang XJ
- 7061** Reference values of gait parameters in healthy Chinese university students: A cross-sectional observational study
Yu JS, Zhuang C, Guo WX, Chen JJ, Wu XK, Xie W, Zhou X, Su H, Chen YX, Wang LK, Li WK, Tian K, Zhuang RJ

- 7075** Effect of T-regulatory cells and interleukin-35, interleukin-10, and transforming growth factor-beta on diffuse large B-cell lymphoma

Wu H, Sun HC, Ouyang GF

META-ANALYSIS

- 7082** Meta-analysis on the effectiveness of parent education for children with disabilities

Jang J, Kim G, Jeong H, Lee N, Oh S

- 7091** Meta-analysis of the efficacy and safety of daratumumab in the treatment of multiple myeloma

Wang P, Jin SY

CASE REPORT

- 7101** Varicella-zoster virus meningitis with hypoglycorrhachia: A case report

Cao LJ, Zheng YM, Li F, Hao HJ, Gao F

- 7107** Unusual presentation of penile giant condyloma acuminatum with spontaneous prepuce perforation: A case report

Hsu FC, Yu DS, Pu TW, Wu MJ, Meng E

- 7113** Primary renal lymphoma presenting as renal failure: A case report and review of literature from 1989

Lee SB, Yoon YM, Hong R

- 7127** Intravascular ultrasonography assisted carotid artery stenting for treatment of carotid stenosis: Two case reports

Fu PC, Wang JY, Su Y, Liao YQ, Li SL, Xu GL, Huang YJ, Hu MH, Cao LM

- 7136** Mucoepidermoid carcinoma of the lung with hemoptysis as initial symptom: A case report

Xie WX, Liu R, Li Z, Zhou PL, Duan LN, Fu DD

- 7144** Co-infection of *Chlamydia psittaci* and *Tropheryma whippelii*: A case report

Du ZM, Chen P

- 7150** Surgical treatment of severe anterior capsular organized hard core cataract: A case report

Wang LW, Fang SF

- 7156** First platelet transfusion refractoriness in a patient with acute myelocytic leukemia: A case report

Tu SK, Fan HJ, Shi ZW, Li XL, Li M, Song K

- 7162** Rare finding of primary aortoduodenal fistula on single-photon emission computed tomography/computed tomography of gastrointestinal bleeding: A case report

Kuo CL, Chen CF, Su WK, Yang RH, Chang YH

- 7170** Rituximab combined with Bruton tyrosine kinase inhibitor to treat elderly diffuse large B-cell lymphoma patients: Two case reports

Zhang CJ, Zhao ML

- 7179** Use of Ilizarov technique for bilateral knees flexion contracture in Juvenile-onset ankylosing spondylitis: A case report
Xia LW, Xu C, Huang JH
- 7187** Case of takotsubo cardiomyopathy after surgical treatment of liver hydatid cyst: A case report
Altaş Y, Abdullayeva Ü
- 7193** Laparoscopic choledocholithotomy and transductal T-tube insertion with indocyanine green fluorescence imaging and laparoscopic ultrasound: A case report
Yoo D
- 7200** Hematopoietic stem cell transplantation of aplastic anemia by relative with mutations and normal telomere length: A case report
Yan J, Jin T, Wang L
- 7207** Emphysematous thrombophlebitis caused by a misplaced central venous catheter: A case report
Chen N, Chen HJ, Chen T, Zhang W, Fu XY, Xing ZX
- 7214** Aggressive angiomyxoma of the epididymis: A case report
Liu XJ, Su JH, Fu QZ, Liu Y
- 7221** Gastric and intestinal ectopic pancreas: Two case reports
Zhang H, Zhao HY, Zhang FH, Liang W
- 7227** Congenital leukemia: A case report and review of literature
Yang CX, Yang Y, Zhang FL, Wang DH, Bian QH, Zhou M, Zhou MX, Yang XY
- 7234** Imaging misdiagnosis and clinical analysis of significant hepatic atrophy after bilioenteric anastomosis: A case report
Liang SY, Lu JG, Wang ZD
- 7242** Surgical treatment of mixed cervical spondylosis with spontaneous cerebrospinal fluid leakage: A case report
Yu Z, Zhang HFZ, Wang YJ
- 7248** Simultaneous thyroglossal duct cyst with parathyroid cyst: A case report
Chen GY, Li T
- 7253** Submandibular solid-cystic mass as the first and sole manifestation of occult thyroid papillary carcinoma: A case report
Chen GY, Li T

LETTER TO THE EDITOR

- 7258** Artificial intelligence and machine learning in motor recovery: A rehabilitation medicine perspective
Swarnakar R, Yadav SL

ABOUT COVER

Editorial Board Member of *World Journal of Clinical Cases*, Zeid J Khitan, FACP, FASN, MBBS, MD, Academic Research, Director, Full Professor, Department of Medicine, Marshall University, Huntington, WV 25701, United States. zkhitan@marshall.edu

AIMS AND SCOPE

The primary aim of *World Journal of Clinical Cases* (WJCC, *World J Clin Cases*) is to provide scholars and readers from various fields of clinical medicine with a platform to publish high-quality clinical research articles and communicate their research findings online.

WJCC mainly publishes articles reporting research results and findings obtained in the field of clinical medicine and covering a wide range of topics, including case control studies, retrospective cohort studies, retrospective studies, clinical trials studies, observational studies, prospective studies, randomized controlled trials, randomized clinical trials, systematic reviews, meta-analysis, and case reports.

INDEXING/ABSTRACTING

The WJCC is now abstracted and indexed in Science Citation Index Expanded (SCIE, also known as SciSearch®), Journal Citation Reports/Science Edition, Current Contents®/Clinical Medicine, PubMed, PubMed Central, Reference Citation Analysis, China National Knowledge Infrastructure, China Science and Technology Journal Database, and Superstar Journals Database. The 2023 Edition of Journal Citation Reports® cites the 2022 impact factor (IF) for WJCC as 1.1; IF without journal self cites: 1.1; 5-year IF: 1.3; Journal Citation Indicator: 0.26; Ranking: 133 among 167 journals in medicine, general and internal; and Quartile category: Q4.

RESPONSIBLE EDITORS FOR THIS ISSUE

Production Editor: Hua-Ge Yin; Production Department Director: Xiang Li; Editorial Office Director: Jin-Lai Wang.

NAME OF JOURNAL

World Journal of Clinical Cases

ISSN

ISSN 2307-8960 (online)

LAUNCH DATE

April 16, 2013

FREQUENCY

Thrice Monthly

EDITORS-IN-CHIEF

Bao-Gan Peng, Jerzy Tadeusz Chudek, George Kontogeorgos, Maurizio Serati, Ja Hyeon Ku

EDITORIAL BOARD MEMBERS

<https://www.wjgnet.com/2307-8960/editorialboard.htm>

PUBLICATION DATE

October 16, 2023

COPYRIGHT

© 2023 Baishideng Publishing Group Inc

INSTRUCTIONS TO AUTHORS

<https://www.wjgnet.com/bpg/gerinfo/204>

GUIDELINES FOR ETHICS DOCUMENTS

<https://www.wjgnet.com/bpg/GerInfo/287>

GUIDELINES FOR NON-NATIVE SPEAKERS OF ENGLISH

<https://www.wjgnet.com/bpg/gerinfo/240>

PUBLICATION ETHICS

<https://www.wjgnet.com/bpg/GerInfo/288>

PUBLICATION MISCONDUCT

<https://www.wjgnet.com/bpg/gerinfo/208>

ARTICLE PROCESSING CHARGE

<https://www.wjgnet.com/bpg/gerinfo/242>

STEPS FOR SUBMITTING MANUSCRIPTS

<https://www.wjgnet.com/bpg/GerInfo/239>

ONLINE SUBMISSION

<https://www.f6publishing.com>



Retrospective Study

Axenfeld-Reiger syndrome: A search for the missing links

Arvind Kumar Morya, Prasanna Venkatesh Ramesh, Sony Sinha, Prateek Nishant, Nazia Nain, Ravi Naik Ramavath, Chetana Gone, Ripunjay Prasad

Specialty type: Ophthalmology

Provenance and peer review:

Invited article; Externally peer reviewed.

Peer-review model: Single blind

Peer-review report's scientific quality classification

Grade A (Excellent): 0
Grade B (Very good): B
Grade C (Good): 0
Grade D (Fair): 0
Grade E (Poor): 0

P-Reviewer: Mijwil MM, Iraq

Received: August 17, 2023

Peer-review started: August 17, 2023

First decision: September 4, 2023

Revised: September 12, 2023

Accepted: September 18, 2023

Article in press: September 18, 2023

Published online: October 16, 2023



Arvind Kumar Morya, Nazia Nain, Ravi Naik Ramavath, Chetana Gone, Department of Ophthalmology, All India Institute of Medical Sciences, Bibi Nagar, Hyderabad 508126, Telangana, India

Prasanna Venkatesh Ramesh, Glaucoma Medical Officer, Mahathma Eye Hospital Private Limited, Thennur, Trichy 620017, Tamil Nadu, India

Sony Sinha, Department of Ophthalmology-Vitreo-Retina and Oculoplasty, All India Institute of Medical Sciences, Patna, Patna 801507, Bihar, India

Prateek Nishant, Department of Ophthalmology, All India Institute of Medical Sciences, Patna, Patna 801507, Bihar, India

Ripunjay Prasad, Department of Ophthalmology, RP Eye Institute, Delhi 110001, Delhi, India

Corresponding author: Arvind Kumar Morya, MBBS, MNAMS, MS, Additional Professor, Department of Ophthalmology, All India Institute of Medical Sciences, Bibi Nagar, Hyderabad 508126, Telangana, India. bulbul.morya@gmail.com

Abstract

BACKGROUND

Axenfeld-Rieger syndrome (ARS) is a rare cause of congenital glaucoma and may result in loss of vision. ARS is mostly autosomal dominant in nature characterized by developmental abnormalities in the angle of anterior chamber and iris of the eye, also associated with structural abnormalities in the body.

AIM

To study and observe the demographics and clinical findings in a very rare ocular disease known as ARS.

METHODS

Case records of symptomatic patients attending Ophthalmology outpatient department and diagnosed to have ocular hypertension or glaucoma in 3 years from March 2017 to March 2020 were evaluated to search for cases diagnosed with ARS. Records of all patients diagnosed with ARS were then analysed for demographic and clinical characterization as well as management and success of therapy.

RESULTS

Eight out of ten patients with positive clinical signs were symptomatic and had

glaucoma. One of these patients had limbal stem cell deficiency and another had vernal keratoconjunctivitis.

CONCLUSION

Clinical characterization of ARS is important for making a definitive diagnosis and determining prognosis.

Key Words: Axenfeld-Reiger Syndrome; Glaucoma; Limbal stem cell deficiency; Vernal keratoconjunctivitis

©The Author(s) 2023. Published by Baishideng Publishing Group Inc. All rights reserved.

Core Tip: Clinical characteristic of Axenfeld-Reiger syndrome (ARS) is well defined and approximately 50% develop glaucoma later in life. Despite significant progress in unraveling the genetic basis of ARS, many questions still remain unanswered. One of the key challenges in studying this syndrome is the wide variability in clinical presentation, even among individuals with the same underlying genetic mutation. This suggests the involvement of additional genetic and environmental factors that modulate the phenotypic expression of the syndrome. Researchers are actively exploring epigenetic modifications, gene-gene interactions, and gene-environment interactions to uncover these missing links.

Citation: Morya AK, Ramesh PV, Sinha S, Nishant P, Nain N, Ramavath RN, Gone C, Prasad R. Axenfeld-Reiger syndrome: A search for the missing links. *World J Clin Cases* 2023; 11(29): 7034-7042

URL: <https://www.wjgnet.com/2307-8960/full/v11/i29/7034.htm>

DOI: <https://dx.doi.org/10.12998/wjcc.v11.i29.7034>

INTRODUCTION

Axenfeld-Reiger syndrome (ARS) is a rare clinical entity proposed to have an autosomal dominant inheritance with a prevalence of 1:100000 to 1:200000 population[1]. This disease is typically characterized by developmental abnormalities in the angle of the anterior chamber and iris of the eye, often associated with structural anomalies in the body[2]. It occurs as a result of the spectrum of disorders associated with failure of neural crest cell migration[1,3]. ARS is genetically heterogeneous, with 40%–60% of cases associated with heterozygous pathogenic variants in the transcription factor-encoding genes; PITX2 (4q25, OMIM*601542) or FOXC1 (6p25, OMIM*601090). However, mutations in other genes, such as PAX6, PITX3, and CYP1B1, have also been identified in a small subset of ARS patients, indicating the complex genetic landscape of this syndrome[4–6].

ARS can present with different combinations of ocular features. Commonly found features are posterior embryotoxon, sclerocornea, iris hypoplasia, corectopia/eccentric pupil, high myopia, ectopia lentis, polycoria and secondary glaucoma [6]. The condition can be defined under three subcategories[7,8]: Axenfeld anomaly characterized by a prominent Schwalbe's line with prominent iris strands extending from the peripheral iris to this line; Rieger's anomaly diagnosed in the presence of central iris changes like stromal hypoplasia, polycoria, and corectopia along with the previously mentioned features; Axenfeld Syndrome and Rieger's Syndrome, respectively referring to an association of features of Axenfeld anomaly or Rieger's anomaly with systemic manifestations. It is usually bilateral and asymmetric in presentation. Dental abnormalities like hypodontia (missing teeth), microdontia (small teeth), and enamel hypoplasia (underdeveloped tooth enamel) are commonly observed. Facial dysmorphism, such as a flat mid-face, a broad nasal bridge, and a thin upper lip, can also be present.

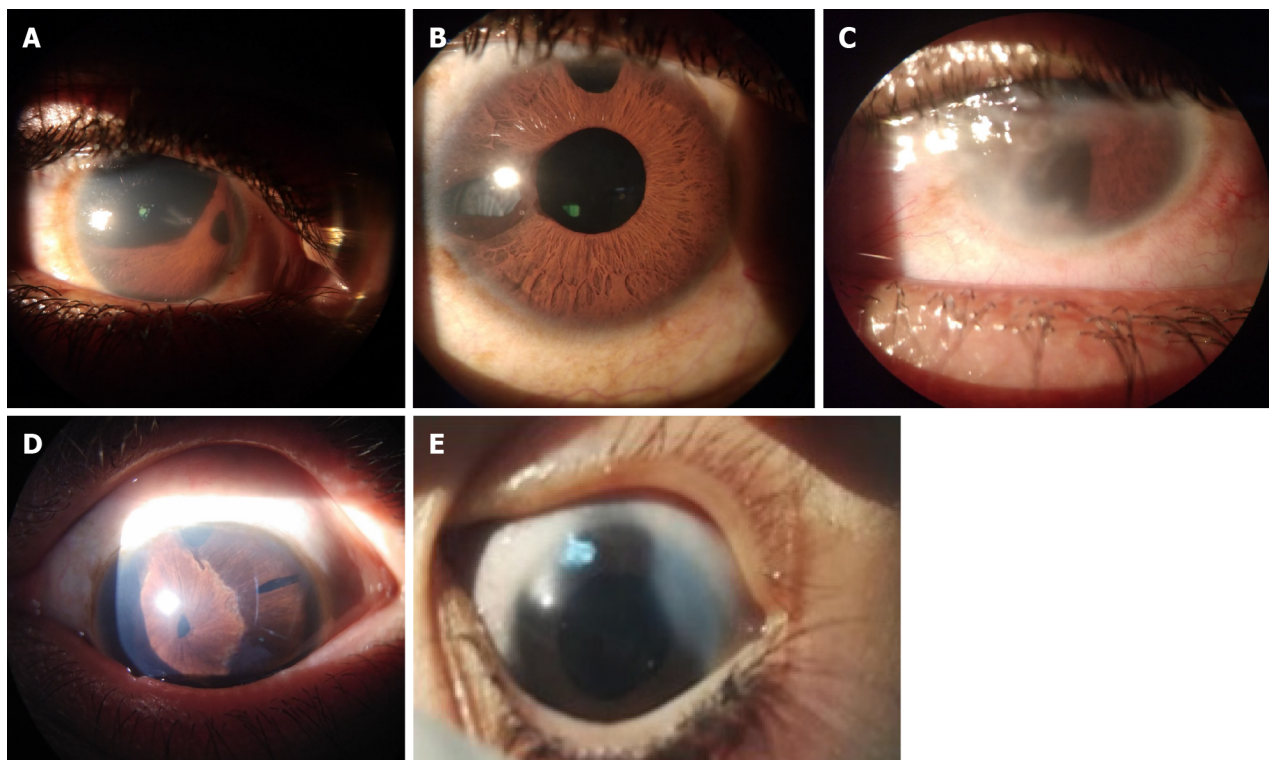
To the best of the authors' knowledge, there have been very few reports depicting the clinical features of ARS published from the Indian sub-continent[9,10]. We present a study on ARS in Indian individuals wherein, through a case records-based search for patients with diagnosed glaucoma and features of ARS over a period of three years, 8 out of 10 patients with positive clinical signs were found to have glaucoma. Demographic and clinical characterization of these patients, as well as management and success of therapy are reported, emphasizing the importance of variability of presentation and active screening of family members of index cases.

MATERIALS AND METHODS

Study design

This was a retrospective study conducted at the Ophthalmology outpatient department of a tertiary eye care hospital of Rajasthan, India. Case records of patients diagnosed to have ocular hypertension or glaucoma in 3 years from March 2017 to March 2020 were evaluated.

Records of patients with diagnosis within the spectrum of ARS were evaluated in terms of (1) demographic characters including age, sex, ethnicity, place of residence and consanguinity; and (2) clinical characters including presenting complaints and their duration, treatment history, slit-lamp findings of anterior segment structures, intraocular pressure (IOP), clinical photographs if acquired, posterior segment findings including fundus evaluation, optical coherence



DOI: 10.12998/wjcc.v11.i29.7034 Copyright ©The Author(s) 2023.

Figure 1 Slit lamp photographs. A: Polycoria with corectopia; B: Status post-trabeculectomy with iris atrophy; C: Membrane across corneal endothelium and iris; D: Posterior embryotoxon, polycoria and corectopia; E: Aniridia implant in case of Rieger's anomaly

tomography and ultrasound B-Scan whenever performed, treatment modality and response to treatment. Any associated ocular problem recorded was also considered. Case records of family members of the patients who were evaluated to look for features of ARS were also included in the study. All records of follow up of the index cases as well as asymptomatic cases diagnosed as a result of active search in relatives of index cases were evaluated to monitor the control of intra-ocular pressure and look for any new rise in IOP or other clinical features.

Ethical considerations

The study conforms to the tenets of the Declaration of Helsinki. Anonymity of subject identity was maintained at every stage of the study.

RESULTS

Of the 1826 records examined, 10 cases were found to be diagnosed with ARS based on slit-lamp biomicroscopy (0.58%). Demographic parameters (Table 1), clinical history (Table 2), visual acuity and IOP (Table 3), anterior segment findings (Table 4) and posterior segment findings (Table 5) of all these cases are presented. Of note, none of the patients were born out of consanguineous marriage. Three patients had only Axenfeld's Anomaly and the others had a combination of ocular features (Figure 1). None of these cases had any systemic associations. All the patients were advised follow-up at intervals of 1 to 3 mo.

Out of 10, eight patients were found to have glaucoma at presentation or were under treatment for the same (Table 2). Out of these eight cases, two eyes were managed surgically; Trabeculectomy was done with biodegradable collagen matrix implant (Ologen™) as an adjunct in right eye of case 1, and with 0.02% Mitomycin-C in left eye of case 2, both resulting in good control of IOP over a year of follow-up. Other eyes were managed medically. The IOP in Case 3 could not be controlled despite maximal medical therapy, and the patient was advised surgical management, which he refused and was lost to follow-up.

DISCUSSION

Clinical presentation

ARS is characterized by a diverse range of clinical features that primarily affect the eye, dental structures, and facial development. Ocular manifestations include anterior segment dysgenesis, which refers to malformation or underdevelop-

Table 1 Demographic characteristics of cases of Axenfeld-Rieger syndrome (N = 10)

| Case No. | | Age (yr) | Sex | Religion | Residence |
|----------------|--------|----------|--------|----------|-----------------------------|
| Familial cases | | | | | |
| Family 1 | Case 1 | 11 | Male | Hindu | Barmer, Rajasthan, India |
| | Case 2 | 9 | Female | Hindu | Barmer, Rajasthan, India |
| Family 2 | Case 3 | 20 | Male | Hindu | Pali, Rajasthan, India |
| | Case 4 | 17 | Male | Hindu | Pali, Rajasthan, India |
| | Case 5 | 11 | Male | Hindu | Pali, Rajasthan, India |
| | Case 6 | 6 | Male | Hindu | Pali, Rajasthan, India |
| Sporadic cases | | | | | |
| Case 7 | | 1 | Male | Hindu | Jodhpur, Rajasthan, India |
| Case 8 | | 28 | Male | Hindu | Barmer, Rajasthan, India |
| Case 9 | | 34 | Male | Hindu | Jaisalmer, Rajasthan, India |
| Case 10 | | 19 | Male | Hindu | Jodhpur, Rajasthan, India |

Table 2 Symptoms and treatment history of cases of Axenfeld-Rieger syndrome (N = 10)

| Case No. | Symptoms | Duration | Previous treatment (in both eyes) | Symptomatic | Diagnosed on active search |
|----------|---|-----------------|---|-------------|----------------------------|
| Case 1 | Decreased vision | 2 yr | Eye Drop Travoprost 0.004% HS; Eye Drop Brimonidine 0.2% + Timolol 0.5% BD; Eye Drop Dorzolamide 2% TDS | Yes | No |
| | Photophobia | 2 mo | | | |
| | Pain | 2 mo | | | |
| | Watering | 2 mo | | | |
| Case 2 | Decreased vision in left eye | Since childhood | None | Yes | Yes |
| | Right eye lost to trauma | 3 yr | | | |
| Case 3 | Decreased vision in both eyes | Since childhood | None | Yes | No |
| Case 4 | Burning sensation and itching in both eyes | 1 yr | Eye drop Travoprost 0.004% HS; Eye drop Brimonidine 0.2% + Timolol 0.5% BD | Yes | Yes |
| Case 5 | None | NA | None | No | Yes |
| Case 6 | None | NA | None | No | Yes |
| Case 7 | Blinking, crying and watering of both eyes on exposure to light | 8 mo | None | Yes | No |
| Case 8 | Decreased vision in both eyes | 15 yr | Trabeculectomy ^a | Yes | No |
| Case 9 | None; Diagnosed glaucoma in both eyes | 17 yr | Eye drop Brimonidine 0.2% BD | Yes | No |
| Case 10 | Decreased vision in both eyes | 5 yr | Eye drop Brimonidine 0.2% + 0.5% Timolol BD | Yes | Yes |

^aNo documents pertaining to this surgery were available for review.

HS: At night; BD: Twice daily; TDS: Thrice daily; NA: Not applicable.

opment of the cornea, iris, and angle. This can lead to conditions like glaucoma and corneal opacity, causing visual impairment or even blindness. Our patients did not have systemic manifestations, however, the pattern of ocular involvement was peculiar.

A potentially blinding disorder, ARS may be asymptomatic in many of the affected. Here, the cases that presented to the outpatient department were usually symptomatic. Association with limbal stem cell deficiency was found in one case and vernal keratoconjunctivitis with dry eye in another case.

Table 3 Visual acuity and intraocular pressure of cases of Axenfeld-Rieger syndrome (N = 10)

| Case No. | Vision BCVA (logMAR) | | IOP (mmHg) | |
|----------|----------------------|------|--------------|----|
| | RE | LE | RE | LE |
| Case 1 | 2.5 | 2.5 | 42 | 28 |
| Case 2 | ^a | 1.3 | ^a | 36 |
| Case 3 | 0.3 | HMCF | 22 | 42 |
| Case 4 | 0.5 | 2.5 | 14 | 16 |
| Case 5 | 0.0 | 0.0 | 16 | 14 |
| Case 6 | 0.0 | 0.0 | 32 | 26 |
| Case 7 | NA | NA | 26 | 26 |
| Case 8 | 0.5 | 2.5 | 15 | 16 |
| Case 9 | 1.8 | 1.8 | 18 | 19 |
| Case 10 | 0.4 | 0.4 | 24 | 25 |

^aEye lost to trauma.

BCVA: Best corrected visual acuity; IOP: Intraocular pressure; RE: Right eye; LE: Left eye; HMCF: Hand movements close to face; NA: Visual acuity unrecordable on logMAR chart.

Table 4 Anterior segment findings in cases of Axenfeld-Rieger syndrome based on slit-lamp biomicroscopy (N = 10)

| Sr. No. | Corneal abnormalities | | Iris tissue abnormalities | | | | | | Associated ocular features |
|---------|-----------------------|----|---------------------------|----|-----------|----|-----------------|----|---|
| | Posterior embryotoxon | | Corectopia | | Polycoria | | Iris hypoplasia | | |
| | RE | LE | RE | LE | RE | LE | RE | LE | |
| Case 1 | + | + | + | + | + | + | + | - | LSCD BE, PAS on Gonioscopy BE |
| Case 2 | NA | + | NA | - | NA | - | NA | + | Corneal oedema, Nystagmus, Aniridia LE |
| Case 3 | + | + | - | + | - | + | - | - | Mature cataract LE, 360° NVI LE |
| Case 4 | + | - | - | + | - | + | - | - | BE cobblestone papillae with RE Shield’s Ulcer s/o VKC, Cornea Plana, Corneal oedema BE |
| Case 5 | + | + | - | - | - | - | - | - | - |
| Case 6 | + | + | - | - | - | - | - | - | - |
| Case 7 | + | + | - | - | - | - | - | - | BE Corneal Haze |
| Case 8 | + | + | - | - | - | + | - | - | Nystagmus, LE Large Surgical PI, Well-formed functioning bleb BE |
| Case 9 | + | + | + | + | + | + | + | + | |
| Case 10 | + | + | + | + | + | + | + | + | |

BCVA: Best Corrected Visual Acuity; IOP: Intraocular Pressure; RE: Right eye; LE: Left eye; BE: Both eyes; LSCD: Limbal Stem Cell Deficiency; PAS: Peripheral Anterior Synchia; PI: Peripheral iridectomy; NVI: Neovascularization of iris; s/o: Suggestive of; VKC: Vernal keratoconjunctivitis; NRR: Neuroretinal rim.

Importance of family screening

In the present study, 4 out of 10 cases of ARS were diagnosed as a result of active search in family members of the index cases. This emphasizes the importance of active screening in family members of the index case. In this analysis, six among ten cases had familial association while the other four were sporadic. These cases are often misdiagnosed to have irido-corneal endothelial syndrome or buphthalmos especially if they present in childhood when thorough slit-lamp evaluation may not be possible due to lack of patient co-operation in which case examination under anaesthesia with a hand-held slit lamp biomicroscope is warranted[8]. For instance, one of our patients was treated in childhood as a case of buphthalmos. For sporadic as well as familial cases, genetic counselling and counselling regarding negative eugenics is essential. The current study emphasizes the variability in presentation and importance of active screening of family members of index cases.

Table 5 Posterior segment findings of cases of Axenfeld-Rieger syndrome (N = 10)

| Sl. No. | Fundus findings | | OCT-RNFL | | B-Scan ^b |
|---------|---|---|--------------|------|---------------------|
| | RE | LE | RE | LE | |
| Case 1 | C:D 0.9 | Glaucomatous Optic Atrophy | CNBA | CNBA | ND |
| Case 2 | ^a | No view due to hazy media | ^a | CNBA | ND |
| Case 3 | C:D 0.8 | No view due to hazy media | CNBA | CNBA | ND |
| Case 4 | C:D 0.4 | No view due to hazy media | CNBA | CNBA | WNL BE |
| Case 5 | C:D 0.3 | C:D 0.3 | WNL | WNL | WNL BE |
| Case 6 | C:D 0.6 | C:D 0.6 | WNL | WNL | WNL BE |
| Case 7 | C:D 0.9 | C:D 0.9 | CNBA | CNBA | WNL BE |
| Case 8 | C:D 0.8, Tilted Disc, Peripapillary Atrophy | C:D 0.8, Tilted Disc, Peripapillary Atrophy | CNBA | CNBA | WNL BE |
| Case 9 | C:D 0.8, Circumferential NRR thinning | C:D 0.8, Circumferential NRR thinning | CNBA | CNBA | WNL BE |
| Case 10 | C:D 0.5 | C:D 0.5 | WNL | WNL | WNL BE |

^aEye lost to trauma.^bComments on vitreous, retinochoroid and sclera on B-scan USG.

Optic nerve head findings are as clinically correlated. C:D: Cup: Disc ratio; NRR: Neuroretinal rim; CNBA: Could not be acquired; ND: Not done; WNL: Within normal limits.

What is already known?

Clinical characteristics of ARS are well-defined and approximately 50% are known to develop glaucoma later in life as described in the classical literature[8]. Appropriate and timely follow-up to ensure early detection of the development and progression of glaucoma in these patients is essential and forms the most crucial part of the management of these patients.

Understanding the missing links

ARS is a genetically heterogeneous disorder caused by mutations in different genes. Mutations in the PAX6, PITX2, and FOXC1 genes have been associated with aniridia and ARS[11]. Mutations in the genes FOXC1 and PITX2 account for about 40% of the cases, but in majority of the rest, the genetic basis of ARS is unexplained[8]. Recently, Reis *et al*[12] have demonstrated that the incidence of glaucoma in FOXC1- and PITX2-related genetic variants of ARS is higher than previously described (up to 77%)[13]. This is in concordance with the present study where 8 out of 10 cases (80%) were found to have glaucoma at presentation. Thus despite significant progress in unraveling the genetic interactions behind the pathogenesis of glaucoma in ARS, many questions remain unanswered.

One of the key challenges in studying this syndrome is the wide variability in clinical presentation, even among individuals with the same genetic mutation. This suggests the involvement of additional genetic and environmental factors that modulate the phenotypic expression of the syndrome. Researchers are actively exploring epigenetic modifications, gene-gene interactions, and gene-environment interactions to uncover these missing links[12]: Recent studies have shown that epigenetic factors, such as deoxyribonucleic acid methylation and histone modifications, can affect the expression of genes implicated in ARS. Understanding these epigenetic mechanisms may provide insights into the variability of clinical features and help explain why individuals with the same genetic mutation can exhibit different phenotypes.

In addition, it is likely that multiple genes interact with each other, either synergistically or antagonistically, to regulate eye and facial development. Investigating these gene-gene interactions through experimental models and advanced computational approaches can shed light on the intricate network of genes involved in ARS and help identify potential therapeutic targets.

Studies have suggested that certain environmental factors, such as maternal smoking during pregnancy, can increase the risk of developing glaucoma in individuals with specific genetic mutations[14]. Moreover, the severity of ocular and dental manifestations may be influenced by environmental factors such as infection, nutrition, and exposure to toxins. Unraveling these gene-environment interactions is crucial for a comprehensive understanding of ARS and developing personalized treatment strategies.

Therapeutic options in ARS

While there is currently no cure for ARS, management of glaucoma is key for long-term outcome in these cases. In our study, out of eight cases of glaucoma, two eyes were operated upon while others were medically managed. Trabeculectomy with adjunctives (antimetabolites or Ologen™ implant) have previously been reported to be successful in ARS as in our study[13,15]. However, the evidence regarding long-term IOP control and visual outcome is lacking.

Gene therapy, which involves delivering healthy copies of the mutated gene or modulating the expression of other related genes, holds promise for treating genetic disorders like ARS[16]. Preclinical studies using animal models have shown encouraging results, and ongoing research aims to translate these findings into clinical trials. Additionally, advancements in regenerative medicine and tissue engineering provide hope for the treatment of ocular abnormalities associated with ARS for restoring visual function in affected individuals[17].

Limitations of the present study

Limitations of this study include its retrospective design, inability to obtain B-scan ultrasonography for the first three cases and lack of genetic testing due to constraints of instrumentation. There were no cases of ARS with systemic manifestations in our study. Further follow-up of our patients could not be performed due to the subsequent COVID-19 pandemic.

CONCLUSION

ARS remains a challenging disorder due to its genetic heterogeneity and wide phenotypic variability. However, recent advancements in genetic and molecular research have shed light on the underlying mechanisms and brought us closer to understanding the missing links. Further exploration of epigenetic modifications, gene-gene interactions, and gene-environment interactions will likely unravel the complex nature of this syndrome. With ongoing therapeutic developments, there is hope for improved treatments that can alleviate the burden on individuals affected by ARS and improve their quality of life.

What this study adds to existing knowledge

In our study, a high proportion of cases (80%) was found to have glaucoma and we suggest having a high degree of suspicion while performing anterior segment evaluation. We recommend screening of family members for early detection and management of ARS in them. We found a rare association with limbal stem cell deficiency and vernal keratoconjunctivitis. We also recommend Trabeculectomy with adjuncts as the line of surgical management in patients refractory to maximal medical therapy, and long-term follow-up to prevent vision loss in eyes with ARS.

ARTICLE HIGHLIGHTS

Research background

A retrospective study at a tertiary eye care centre of National Importance. To study and observe the demographics and clinical findings in a very rare ocular disease known as Axenfeld-Rieger syndrome (ARS).

Research motivation

ARS has autosomal dominant inheritance and a prevalence of 1:100000 to 1:200000 population. This disease is typically characterized by developmental abnormalities in the angle of the anterior chamber and iris of the eye, often associated with structural anomalies in the body. To the best of the authors' knowledge, there have been very few reports depicting the clinical features of ARS published from the Indian sub-continent.

Research objectives

Case records of symptomatic patients attending Ophthalmology outpatient department and diagnosed to have ocular hypertension or glaucoma in 3 years from March 2017 to March 2020 were evaluated to search for cases diagnosed with ARS. Records of all patients diagnosed with ARS were then analysed for demographic and clinical characterization as well as management and success of therapy.

Research methods

Patients' presenting complaints and their duration, treatment history, slit-lamp findings of anterior segment structures, intraocular pressure, clinical photographs if acquired, posterior segment findings including fundus evaluation, optical coherence tomography and ultrasound B-Scan whenever performed, treatment modality and response to treatment were recorded. Case records of family members of the patients who were evaluated to look for features of ARS were also included in the study.

Research results

Of the 1826 records examined, 10 cases were found to be diagnosed with ARS based on slit-lamp biomicroscopy (0.58%). Three patients had only Axenfeld's Anomaly and the others had a combination of ocular features. Out of 10, eight patients (80%) were found to have glaucoma at presentation or were under treatment for the same. Out of these eight cases, two eyes were managed surgically, while other eyes were managed medically. All the patients were advised follow-up at intervals of 1 to 3 mo.

Research conclusions

In our study, a high proportion of cases (80%) was found to have glaucoma and we suggest having a high degree of suspicion while performing anterior segment evaluation. We recommend screening of family members for early detection and management of ARS in them. We found a rare association with limbal stem cell deficiency and vernal keratoconjunctivitis. We also recommend Trabeculectomy with adjuncts as the line of surgical management in patients refractory to maximal medical therapy, and long-term follow-up to prevent vision loss in eyes with ARS.

Research perspectives

ARS remains a challenging disorder due to its genetic heterogeneity and wide phenotypic variability. Recent advancements in genetic and molecular research have shed light on the underlying mechanisms and brought us closer to understanding the missing links. Further exploration of epigenetic modifications, gene-gene interactions, and gene-environment interactions will likely unravel the complex nature of this syndrome. With ongoing therapeutic developments, there is hope for improved treatments that can alleviate the burden on individuals affected by ARS and improve their quality of life.

FOOTNOTES

Author contributions: Morya AK designed and performed the research and wrote the paper; Venkatesh PV designed the research and supervised the report; Sinha S and Nishant P designed the research and contributed to the analysis; Nain N, Ramavath RN, Gone C, and Prasad R provided clinical advice.

Institutional review board statement: We are submitting an invited case series titled “Axenfeld-Rieger Syndrome: A search for the missing links”. As this is a retrospective observational study so as per our Institute norms, no institutional ethical clearance is needed for such studies and publications.

Informed consent statement: Informed written consent was obtained from the patients for publication of this report and accompanying images.

Conflict-of-interest statement: All the authors declare that they have no conflict of interest.

Data sharing statement: Appropriate consent was taken from the adult patients and from the parents of minor patients.

Open-Access: This article is an open-access article that was selected by an in-house editor and fully peer-reviewed by external reviewers. It is distributed in accordance with the Creative Commons Attribution NonCommercial (CC BY-NC 4.0) license, which permits others to distribute, remix, adapt, build upon this work non-commercially, and license their derivative works on different terms, provided the original work is properly cited and the use is non-commercial. See: <https://creativecommons.org/licenses/by-nc/4.0/>

Country/Territory of origin: India

ORCID number: Arvind Kumar Morya 0000-0003-0462-119X; Prasanna Venkatesh Ramesh 0000-0002-6105-8666; Sony Sinha 0000-0002-6133-5977; Prateek Nishant 0000-0003-3438-0040; Nazia Nain 0009-0001-3760-1067.

S-Editor: Liu JH

L-Editor: A

P-Editor: Liu JH

REFERENCES

- Idrees F, Vaideanu D, Fraser SG, Sowden JC, Khaw PT. A review of anterior segment dysgeneses. *Surv Ophthalmol* 2006; **51**: 213-231 [PMID: 16644364 DOI: 10.1016/j.survophthal.2006.02.006]
- Childers NK, Wright JT. Dental and craniofacial anomalies of Axenfeld-Rieger syndrome. *J Oral Pathol* 1986; **15**: 534-539 [PMID: 3104560 DOI: 10.1111/j.1600-0714.1986.tb00572.x]
- Alward WL. Axenfeld-Rieger syndrome in the age of molecular genetics. *Am J Ophthalmol* 2000; **130**: 107-115 [PMID: 11004268 DOI: 10.1016/s0002-9394(00)00525-0]
- Reis LM, Tyler RC, Volkmann Kloss BA, Schilter KF, Levin AV, Lowry RB, Zwijnenburg PJ, Stroth E, Broeckel U, Murray JC, Semina EV. PITX2 and FOXC1 spectrum of mutations in ocular syndromes. *Eur J Hum Genet* 2012; **20**: 1224-1233 [PMID: 22569110 DOI: 10.1038/ejhg.2012.80]
- Strungaru MH, Dinu I, Walter MA. Genotype-phenotype correlations in Axenfeld-Rieger malformation and glaucoma patients with FOXC1 and PITX2 mutations. *Invest Ophthalmol Vis Sci* 2007; **48**: 228-237 [PMID: 17197537 DOI: 10.1167/iovs.06-0472]
- Tümer Z, Bach-Holm D. Axenfeld-Rieger syndrome and spectrum of PITX2 and FOXC1 mutations. *Eur J Hum Genet* 2009; **17**: 1527-1539 [PMID: 19513095 DOI: 10.1038/ejhg.2009.93]
- Shields MB, Buckley E, Klintworth GK, Thresher R. Axenfeld-Rieger syndrome. A spectrum of developmental disorders. *Surv Ophthalmol* 1985; **29**: 387-409 [PMID: 3892740 DOI: 10.1016/0039-6257(85)90205-x]
- Seifi M, Walter MA. Axenfeld-Rieger syndrome. *Clin Genet* 2018; **93**: 1123-1130 [PMID: 28972279 DOI: 10.1111/cge.13148]

- 9 **Parikh RS**, Parikh SR, Debashish B, Harsha BL, Thomas R. Unusual presentation in Axenfeld-Rieger syndrome. *Indian J Ophthalmol* 2011; **59**: 312-314 [PMID: [21666320](#) DOI: [10.4103/0301-4738.82003](#)]
- 10 **Mandal AK**, Pehere N. Early-onset glaucoma in Axenfeld-Rieger anomaly: long-term surgical results and visual outcome. *Eye (Lond)* 2016; **30**: 936-942 [PMID: [27055677](#) DOI: [10.1038/eye.2016.66](#)]
- 11 **Hernández-Martínez N**, González-Del Angel A, Alcántara-Ortigoza MA, González-Huerta LM, Cuevas-Covarrubias SA, Villanueva-Mendoza C. Molecular characterization of Axenfeld-Rieger spectrum and other anterior segment dysgeneses in a sample of Mexican patients. *Ophthalmic Genet* 2018; **39**: 728-734 [PMID: [30457409](#) DOI: [10.1080/13816810.2018.1547911](#)]
- 12 **Reis LM**, Maheshwari M, Capasso J, Atilla H, Dudakova L, Thompson S, Zitano L, Lay-Son G, Lowry RB, Black J, Lee J, Shue A, Kremlikova Pourova R, Vaneckova M, Skalicka P, Jedlickova J, Trkova M, Williams B, Richard G, Bachman K, Seeley AH, Costakos D, Glaser TM, Levin AV, Liskova P, Murray JC, Semina EV. Axenfeld-Rieger syndrome: more than meets the eye. *J Med Genet* 2023; **60**: 368-379 [PMID: [35882526](#) DOI: [10.1136/jmg-2022-108646](#)]
- 13 **Zepeda EM**, Branham K, Moroi SE, Bohnsack BL. Surgical outcomes of Glaucoma associated with Axenfeld-Rieger syndrome. *BMC Ophthalmol* 2020; **20**: 172 [PMID: [32357855](#) DOI: [10.1186/s12886-020-01417-w](#)]
- 14 **Moore KJ**, Carmichael SL, Forestieri NE, Desrosiers TA, Meyer RE, Freedman SF, North KE, Olshan AF; National Birth Defects Prevention Study. Maternal diet as a risk factor for primary congenital glaucoma and defects of the anterior segment of the eye in the National Birth Defects Prevention Study. *Birth Defects Res* 2020; **112**: 503-514 [PMID: [32154673](#) DOI: [10.1002/bdr2.1664](#)]
- 15 **Radhakrishnan OK**, Pahuja K, Patel K, Chandna S. OLOGEN(®) implant in the management of glaucoma in an unusual case of Axenfeld-Rieger syndrome. *Oman J Ophthalmol* 2014; **7**: 90-92 [PMID: [25136237](#) DOI: [10.4103/0974-620X.137170](#)]
- 16 **Amador C**, Shah R, Ghiam S, Kramerov AA, Ljubimov AV. Gene Therapy in the Anterior Eye Segment. *Curr Gene Ther* 2022; **22**: 104-131 [PMID: [33902406](#) DOI: [10.2174/1566523221666210423084233](#)]
- 17 **Coulon SJ**, Schuman JS, Du Y, Bahrani Fard MR, Ethier CR, Stamer WD. A novel glaucoma approach: Stem cell regeneration of the trabecular meshwork. *Prog Retin Eye Res* 2022; **90**: 101063 [PMID: [35398015](#) DOI: [10.1016/j.preteyeres.2022.101063](#)]



Published by **Baishideng Publishing Group Inc**
7041 Koll Center Parkway, Suite 160, Pleasanton, CA 94566, USA

Telephone: +1-925-3991568

E-mail: bpgoffice@wjgnet.com

Help Desk: <https://www.f6publishing.com/helpdesk>

<https://www.wjgnet.com>

