

World Journal of *Clinical Cases*

World J Clin Cases 2023 November 6; 11(31): 7508-7740



Contents

Thrice Monthly Volume 11 Number 31 November 6, 2023

REVIEW

- 7508 Gut microbiome: New perspectives for type 2 diabetes prevention and treatment
Li SX, Guo Y

MINIREVIEWS

- 7521 Endoscopic management of benign biliary strictures: Looking for the best stent to place
Colombo M, Forcignanò E, Da Rio L, Spadaccini M, Andreozzi M, Giacchetto CM, Carrara S, Maselli R, Galtieri PA, Pellegatta G, Capogreco A, Massimi D, Khalaf K, Hassan C, Anderloni A, Repici A, Fugazza A
- 7530 Antibiotic resistance in patients with liver cirrhosis: Prevalence and current approach to tackle
Liakina V

ORIGINAL ARTICLE

Retrospective Study

- 7543 Analysis of risk factors for postoperative deep vein thrombosis after craniotomy and nomogram model construction
Su ZJ, Wang HR, Liu LQ, Li N, Hong XY
- 7553 Value of ultrasound and magnetic resonance imaging combined with tumor markers in the diagnosis of ovarian tumors
Yang Q, Zhang H, Ma PQ, Peng B, Yin GT, Zhang NN, Wang HB
- 7562 Measurement of combined flap thickness for reconstruction of decubitus ulcer using computed tomography
Kim EC, Park JD, Wee SY, Kim SY
- 7570 Does the advantage of transcutaneous oximetry measurements in diabetic foot ulcer apply equally to free flap reconstruction?
Lee DW, Hwang YS, Byeon JY, Kim JH, Choi HJ

Clinical Trials Study

- 7583 Effects of ulinastatin therapy in deep vein thrombosis prevention after brain tumor surgery: A single-center randomized controlled trial
Tao YN, Han Q, Jiao W, Yang LK, Wang F, Xue S, Shen M, Wang YH

Observational Study

- 7593 Network pharmacological and molecular docking study of the effect of Liu-Wei-Bu-Qi capsule on lung cancer
Yang Q, Li LY

- 7610** Efficacy of β_2 -adrenergic receptor agonist combined with corticosteroid in the treatment of children with cough variant asthma

Cao JY, Wang YC, Deng XX

Randomized Controlled Trial

- 7619** Protective effect of sevoflurane on lung function of elderly chronic obstructive pulmonary disease patients undergoing total hip arthroplasty

Yao Y, Zhang MS, Li YB, Zhang MZ

CASE REPORT

- 7629** Sunitinib-induced hyperammonemic encephalopathy in metastatic gastrointestinal stromal tumors: A case report

Hayakawa T, Funakoshi S, Hamamoto Y, Hirata K, Kanai T

- 7635** Simultaneous lateral and subxiphoid access methods for safe and accurate resection of a superior vena cava aneurysm: A case report

Kim SP, Son J

- 7640** Ultrafast power Doppler imaging for ischemic encephalopathy: A case report

Huang LJ, Jiao JF, He Q, Luo JW, Guo Y

- 7647** Intermittent spontaneous ovulation in patients with premature ovarian failure: Three case reports and review of literature

Zhang WY, Wang HB, Deng CY

- 7656** Sneddon's syndrome concurrent with cerebral venous sinus thrombosis: A case report

Heng Y, Tang YF, Zhang XW, Duan JF, Shi J, Luo Q

- 7663** Carcinosarcoma of the deep lobe of the parotid gland in the parapharyngeal region: A case report

Tang YY, Zhu GQ, Zheng ZJ, Yao LH, Wan ZX, Liang XH, Tang YL

- 7673** Malignant peripheral nerve sheath tumor with hemophilic syndrome and bone marrow fibrosis: A rare case report

Li H, Wang L, Wu YH, Chen G, Li HX, Fan LF, Gu M, Jiang CH

- 7680** Comparison of drug concentrations in blood and gastric lavage fluid before and after gastric lavage: A case report

Zhou Y, Tong JL, Peng AH, Xu SY

- 7684** Recurred forehead osteoma disseminated after previous osteoma excision: A case report

Lee DY, Lim S, Yoon JS, Eo S

- 7690** Renal pelvis sarcomatoid carcinoma with renal vein tumor thrombus: A case report and literature review

Guan HY, Wang J, Wang JX, Chen QH, Lu J, He L

- 7699** Ultrasonographic identification of lateral femoral cutaneous nerve anatomical variation in persistent meralgia paresthetica: A case report

Park HW, Ji KS, Kim JH, Kim LN, Ha KW

- 7706** Biliary hemorrhage caused by a malignant small round cell tumor in the common bile duct: A case report
Jin YL, Ruan YJ, Lu GR
- 7712** Successive development of ischemic malignant strokes in a patient with multiple fusiform aneurysms: A case report
Shin DS, Yeo DK, Choi EJ
- 7718** Isolated axillary tumor deposit consistent with primary breast carcinoma: A case report
Li T, Zhang WH, Liu J, Mao YL, Liu S
- 7724** Multiple inflammatory pseudotumor formation after craniopharyngioma resection *via* an extended nasal endoscopic approach: A case report
Wu H, Ding YW, Yan ZC, Wei M, Wang XD, Zhang HZ
- 7732** Huge Bartholin's cyst managed by primary marsupialization: A case report
Li HY, Ding DC

LETTER TO THE EDITOR

- 7738** Do not forget diet and exercise during Ramadan
Ilias I, Tselebis A

ABOUT COVER

Editorial Board Member of *World Journal of Clinical Cases*, How-Ran Guo, DSc, MD, MSc, Full Professor, Department of Environmental and Occupational Health, College of Medicine, National Cheng Kung University, Tainan 70428, Taiwan. hrguo@mail.ncku.edu.tw

AIMS AND SCOPE

The primary aim of *World Journal of Clinical Cases* (WJCC, *World J Clin Cases*) is to provide scholars and readers from various fields of clinical medicine with a platform to publish high-quality clinical research articles and communicate their research findings online.

WJCC mainly publishes articles reporting research results and findings obtained in the field of clinical medicine and covering a wide range of topics, including case control studies, retrospective cohort studies, retrospective studies, clinical trials studies, observational studies, prospective studies, randomized controlled trials, randomized clinical trials, systematic reviews, meta-analysis, and case reports.

INDEXING/ABSTRACTING

The WJCC is now abstracted and indexed in Science Citation Index Expanded (SCIE, also known as SciSearch®), Journal Citation Reports/Science Edition, Current Contents®/Clinical Medicine, PubMed, PubMed Central, Reference Citation Analysis, China National Knowledge Infrastructure, China Science and Technology Journal Database, and Superstar Journals Database. The 2023 Edition of Journal Citation Reports® cites the 2022 impact factor (IF) for WJCC as 1.1; IF without journal self cites: 1.1; 5-year IF: 1.3; Journal Citation Indicator: 0.26; Ranking: 133 among 167 journals in medicine, general and internal; and Quartile category: Q4.

RESPONSIBLE EDITORS FOR THIS ISSUE

Production Editor: Si Zhao; Production Department Director: Xiang Li; Editorial Office Director: Jin-Lei Wang.

NAME OF JOURNAL

World Journal of Clinical Cases

ISSN

ISSN 2307-8960 (online)

LAUNCH DATE

April 16, 2013

FREQUENCY

Thrice Monthly

EDITORS-IN-CHIEF

Bao-Gan Peng, Salim Surani, Jerzy Tadeusz Chudek, George Kontogeorgos, Maurizio Serati

EDITORIAL BOARD MEMBERS

<https://www.wjgnet.com/2307-8960/editorialboard.htm>

PUBLICATION DATE

November 6, 2023

COPYRIGHT

© 2023 Baishideng Publishing Group Inc

INSTRUCTIONS TO AUTHORS

<https://www.wjgnet.com/bpg/gerinfo/204>

GUIDELINES FOR ETHICS DOCUMENTS

<https://www.wjgnet.com/bpg/GerInfo/287>

GUIDELINES FOR NON-NATIVE SPEAKERS OF ENGLISH

<https://www.wjgnet.com/bpg/gerinfo/240>

PUBLICATION ETHICS

<https://www.wjgnet.com/bpg/GerInfo/288>

PUBLICATION MISCONDUCT

<https://www.wjgnet.com/bpg/gerinfo/208>

ARTICLE PROCESSING CHARGE

<https://www.wjgnet.com/bpg/gerinfo/242>

STEPS FOR SUBMITTING MANUSCRIPTS

<https://www.wjgnet.com/bpg/GerInfo/239>

ONLINE SUBMISSION

<https://www.f6publishing.com>



Sunitinib-induced hyperammonemic encephalopathy in metastatic gastrointestinal stromal tumors: A case report

Takaoki Hayakawa, Shinsuke Funakoshi, Yasuo Hamamoto, Kenro Hirata, Takanori Kanai

Specialty type: Oncology

Provenance and peer review:

Unsolicited article; Externally peer reviewed.

Peer-review model: Single blind

Peer-review report's scientific quality classification

Grade A (Excellent): A, A

Grade B (Very good): B

Grade C (Good): 0

Grade D (Fair): D

Grade E (Poor): 0

P-Reviewer: Gao F, China; Lin Q, China; Zong L, China; Govindarajan KK, India

Received: June 29, 2023

Peer-review started: June 29, 2023

First decision: September 26, 2023

Revised: October 10, 2023

Accepted: October 23, 2023

Article in press: October 23, 2023

Published online: November 6, 2023



Takaoki Hayakawa, Department of Internal Medicine, Division of Gastroenterology and Hepatology, Keio University School of Medicine, Shinjuku-ku 160-8582, Tokyo, Japan

Shinsuke Funakoshi, Division of Medical Oncology, Department of Internal Medicine, Tokyo Saiseikai Central Hospital, Minato-ku 108-0073, Tokyo, Japan

Yasuo Hamamoto, Kenro Hirata, Keio Cancer Center, Keio University School of Medicine, Shinjuku-ku 160-8582, Tokyo, Japan

Takanori Kanai, Department of Internal Medicine, Keio University School of Medicine, Shinjuku-ku 160-8582, Tokyo, Japan

Corresponding author: Yasuo Hamamoto, MD, PhD, Assistant Professor, Doctor, Keio Cancer Center, Keio University School of Medicine, 35 Shinanomachi, Shinjuku-ku 160-8582, Tokyo, Japan. yashmmt1971@gmail.com

Abstract

BACKGROUND

Sunitinib, a multi-targeted tyrosine kinase inhibitor (TKI), has been approved for the salvage treatment of gastrointestinal stromal tumors (GIST). Hyperammonemic encephalopathy is a rare but severe complication of sunitinib use. Here, we present the case of a 66-year-old male with metastatic GIST without underlying liver cirrhosis who developed sunitinib-induced hyperammonemic encephalopathy.

CASE SUMMARY

A 66-year-old male with metastatic GIST was admitted because of reduced consciousness. Imatinib was administered as the first-line systemic therapy. He experienced repeated episodes of peritonitis due to tumor perforation, and surgery was performed. Progressive disease was confirmed based on increased liver metastasis, and sunitinib was initiated as a salvage treatment. However, 23 d after the third course of sunitinib, he presented to the emergency room with an episode of altered consciousness and behavioral changes. Based on the patient clinical history and examination findings, sunitinib-induced encephalopathy was suspected. Sunitinib was discontinued, and the patient was treated for hyperammonemia. The patient had a normal level of consciousness four days later, and the serum ammonia level gradually decreased. No further neurological symptoms were reported in subsequent follow-ups.

CONCLUSION

TKI-induced hyperammonemic encephalopathy is potentially life-threatening. Patients receiving TKIs experiencing adverse reactions should undergo systemic evaluation and prompt treatment.

Key Words: Tyrosine protein kinase inhibitors; Sunitinib malate; Hyperammonemic encephalopathy; Gastrointestinal stromal tumors; Case report

©The Author(s) 2023. Published by Baishideng Publishing Group Inc. All rights reserved.

Core Tip: This case is distinctive because the patient was diagnosed with a rare hyperammonemic encephalopathy caused by sunitinib, which was administered as treatment for gastrointestinal stromal tumors. We emphasize the need for systemic evaluation and prompt action for patients receiving tyrosine kinase inhibitors who present with adverse effects.

Citation: Hayakawa T, Funakoshi S, Hamamoto Y, Hirata K, Kanai T. Sunitinib-induced hyperammonemic encephalopathy in metastatic gastrointestinal stromal tumors: A case report. *World J Clin Cases* 2023; 11(31): 7629-7634

URL: <https://www.wjgnet.com/2307-8960/full/v11/i31/7629.htm>

DOI: <https://dx.doi.org/10.12998/wjcc.v11.i31.7629>

INTRODUCTION

In clinical practice, targeted therapies such as tyrosine kinase inhibitors (TKIs) are widely used to treat several malignancies, including gastrointestinal stromal tumors (GIST). Common adverse effects of multi-targeted TKIs reported in clinical studies include hand-foot syndrome, diarrhea, hypertension, and metabolic and electrolyte imbalances[1].

One rare adverse event is hyperammonemic encephalopathy, which can lead to cerebral edema, seizures, herniation, or even death, if not recognized early[2]. However, the incidence of this side effect has rarely been reported, and its mechanism is unknown. Here we report a 66-year-old man undergoing sunitinib treatment for metastatic GIST, without underlying liver cirrhosis, who presented to the emergency department with disturbance of consciousness and was found to have hyperammonemic encephalopathy. We hope that this case will raise awareness of TKI-related hyperammonemic encephalopathy, as clinical suspicion of this condition will lead to early diagnosis and treatment.

CASE PRESENTATION

Chief complaints

A 66-year-old man was brought to our hospital with an episode of altered consciousness and behavioral changes.

History of present illness

The patient had a metastatic liver tumor of GIST.

History of past illness

The patient had a medical history of type 2 diabetes mellitus and situs inversus.

Personal and family history

The patient had a history of smoking for > 40 years. The patient had no history of alcohol consumption. There was no relevant family history.

Physical examination

Physical examination revealed hypertension (blood pressure = 193/118 mmHg) and a Glasgow Coma Scale score of 13 (eye 4, verbal 3, motor 6). The patient exhibited asterixis but was otherwise unremarkable.

Laboratory examinations

Laboratory examination results at the time of admission were as follows: Platelet count, 82000/mm³; total bilirubin level, 2.0 mg/dL; albumin level, 3.7 g/dL; aspartate aminotransferase level, 44 U/L; alanine transaminase level, 25 U/L; creatinine level, 1.25 mg/dL, and PT 97%. In addition, a markedly elevated ammonia level of 122 μmol/L (11-51 μmol/L) was observed. And there were no abnormalities in electrolytes or glucose metabolism.

Imaging examinations

Computed tomography (CT) and magnetic resonance imaging of the brain showed no findings of posterior reversible encephalopathy syndrome (PRES) or metastatic brain tumors. Contrast-enhanced CT imaging of the abdomen and pelvis revealed progressive disease with increased liver metastasis. There was no portal vein obstruction or significant portosystemic shunt, although situs inversus was observed (Figure 1).

FINAL DIAGNOSIS

The final diagnosis was drug-induced hyperammonemic encephalopathy related to sunitinib.

TREATMENT

The patient was diagnosed with GIST and liver metastases. Although the patient's progress was good, he had repeated episodes of peritonitis due to tumor perforation. Surgery was performed, including primary resection, partial resection of the small intestine, and partial resection of the colon. The pathological examination revealed a GIST (Figure 2). Imatinib was then resumed, and his disease was well controlled for 11 mo; however, abdominal CT revealed progressive disease due to increased liver metastasis, and oral sunitinib was initiated as second-line treatment. He had a history of situs inversus but no fundamental liver disease such as liver cirrhosis. However, 23 days after the third course of sunitinib, the patient was brought to the emergency room with an episode of altered consciousness and behavioral changes.

Based on his clinical history and various examinations, sunitinib-induced encephalopathy was suspected after excluding other common causes of encephalopathy, such as hypoglycemia, metastatic brain tumors, PRES, encephalopathy caused by other drugs, and encephalopathy due to shunt or portal vein obstruction. The patient was administered branched-chain amino acids for hyperammonemia. Sunitinib was discontinued based on a previous report of sunitinib-induced hyperammonemia. Four days later, the patient regained a normal level of consciousness. The patient was orally administered lactulose and rifaximin. The serum ammonia level gradually decreased to 70 $\mu\text{mol/L}$, and the patient was discharged from the hospital on day 14 with no symptom flare-up.

OUTCOME AND FOLLOW-UP

Sunitinib therapy was not resumed. The patient did not develop any neurological symptoms during the subsequent months of follow-up.

DISCUSSION

Our patient had mild thrombocytopenia, likely due to sunitinib treatment. Sunitinib is a small molecule and an inhibitor of certain receptor tyrosine kinases, including VEGFR types 1 and 2 (FLT-1 and FLK-1/KDR), PDGFR- α and PDGFR- β , stem cell factor receptor (c-KIT), and FLT-3 and RET kinases[3]. TKIs, including sunitinib, have been associated with the onset of PRES; however, few reports of hyperammonemia exist. Hyperammonemia has been frequently reported with other chemotherapeutic agents such as vincristine, doxorubicin, cytarabine, cyclophosphamide, etoposide, and 5-fluorouracil; however, its incidence is less well known and possibly underreported with TKIs[4,5]. The reported cases of drug-induced hyperammonemic encephalopathy associated with TKIs including sunitinib are presented in Table 1. The present case was characterized by a longer period from the start of treatment to the onset of hyperammonemic encephalopathy than those of cases reported in the past; however, the recovery period after sunitinib discontinuation was comparable to those reported in the past.

The mechanism of encephalopathy remains unclear; however, in light of a similar presentation, it was reasonably suspected to be the result of the class effect of these TKIs[4]. Sunitinib is thought to decrease the ability of the liver to handle NH_3 through its anti-angiogenic properties[6]. Sunitinib is primarily metabolized by the liver *via* cytochrome CYP3A4, with the formation of equally pharmacologically active N-desethyl metabolites, and a decrease in liver reserve may contribute to the development of hyperammonemia[7]. The anti-angiogenic effect of the VEGFR TKIs could also inhibit new vasculature formation in many organs including the brain, which may interfere with vascular-cerebral permeability or the "blood-brain barrier." Thus, a higher amount of ammonia may cross the blood-brain barrier and enter the central nervous system[4].

Hyperammonemia did not occur during the initial course of sunitinib treatment in this patient. Increased tumor volume in the liver may have impaired the ability to metabolize ammonia through the urea cycle. In addition, the patient had mild renal impairment and decreased urinary excretion of ammonia, which may have also contributed to hyperammonemia. Situs inversus can be complicated by the congenital absence of the portal vein, and rare cases of portal vein shunts that can cause hyperammonemia have been reported[8]. However, these could be excluded using CT scans.

Hyperammonemic encephalopathy must be urgently managed. The treatment of drug-induced hyperammonemic encephalopathy is often aimed at reducing ammonia production and absorption using an approach similar to that used

Table 1 Summary of previous case reports of multi-targeted tyrosine kinase inhibitor induced hyperammonemic encephalopathy, n (%)		
Sex	Female/Male, (n)	5/6
Age	Median (range), yr	47 (20-74)
Diagnosis (n)	GIST	5 (45)
	CRC	2 (18)
	RCC	2 (18)
	BC	1 (9)
	pNET	1 (9)
Drug (n)	Sunitinib	6 (55)
	Regorafenib	4 (36)
	Pazopanib	1 (9)
Ammonia level	Median (range), $\mu\text{mol/L}$	151 (87-278)
Time to symptom	Median (range), d	17 (1-390)
Time to recovery	Median (range), d	3 (1-12)

GIST: Gastrointestinal stromal tumor; pNET: Pancreatic neuroendocrine tumor; RCC: Renal cellular cancer; CRC: Colorectal cancer; BC: Breast cancer.

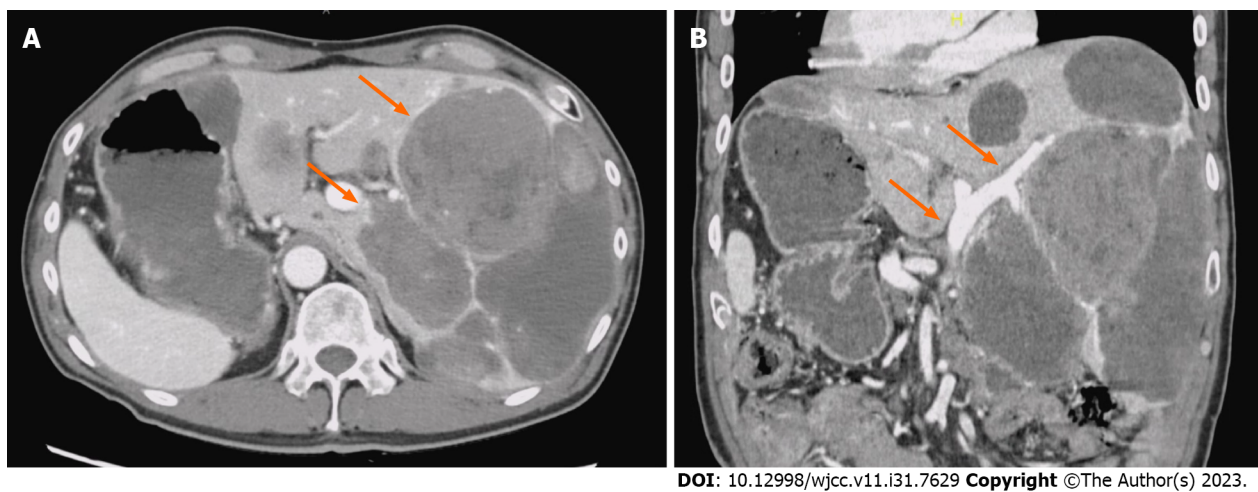


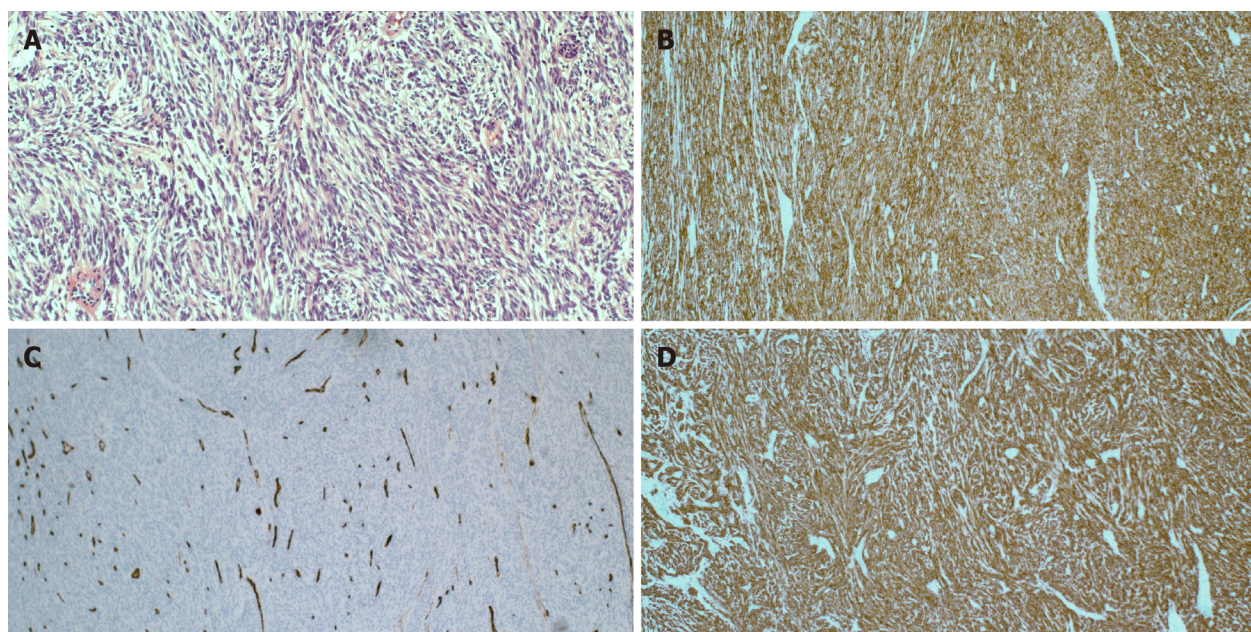
Figure 1 Computed tomography of the abdomen and pelvis with contrast images. A: Computed tomography (CT) image of the abdomen and pelvis with contrast. Axial section shows situs inversus and increased liver metastases (orange arrows); B: CT image of the abdomen and pelvis with contrast. Coronal section shows no portal vein obstruction (orange arrows) or significant portosystemic shunt.

for hepatic encephalopathy[9]. Oral and/or transrectal lactulose and branched-chain amino acids are recommended, but their benefits are uncertain. Rifaximin is a virtually unabsorbed antibiotic that is thought to reduce ammonia production by eliminating ammonia-producing colonic bacteria in the digestive tract and may also be useful. In addition, because ammonia is not protein-bound and is a low-molecular-weight molecule (17 g/mol) similar to urea, clearance with hemodialysis is extremely effective if there is no improvement with these medical treatments[10].

Based on his clinical history and various examinations, sunitinib-induced encephalopathy was suspected after excluding other common causes of consciousness disturbance. In addition to the cessation of sunitinib, branched-chain amino acids, lactulose, and rifaximin were initiated, effectively reducing the serum ammonia level with a clinical improvement in the patient’s neurological symptoms.

CONCLUSION

Here, we report a rare case of sunitinib-induced hyperammonemic encephalopathy in a man with metastatic GIST. We suggest checking the ammonia levels in patients on sunitinib who present with altered sensorium, even if there were no liver problems. Further accumulation of reports is desirable because the CNS side effects of TKIs are not well recognized and may be underreported.



DOI: 10.12998/wjcc.v11.i31.7629 Copyright ©The Author(s) 2023.

Figure 2 Histopathology of the surgically resected small intestine mass. A: A large number of spindle cells were observed, hematoxylin and eosin staining; B: The tumor was positive for CD117 (C-kit), immunohistochemical staining; C: The tumor was negative for CD34, immunohistochemical staining; D: The tumor was positive for DOG1 staining of tumor tissues, immunohistochemical staining. (All images presented in 40× magnification).

FOOTNOTES

Author contributions: Hayakawa T obtained all the required data and drafted the article after a literature review; Hamamoto Y, Funakoshi S and Hirata K, a medical oncologist, revised the article; and Kanai T, a medical gastroenterologist, critically revised the article and approved its final version.

Informed consent statement: Written informed consent was obtained from the patient for the publication of this article and any accompanying images.

Conflict-of-interest statement: All the authors report no relevant conflicts of interest.

CARE Checklist (2016) statement: The authors have read the CARE Checklist (2016), and the manuscript was prepared and revised according to the CARE Checklist (2016).

Open-Access: This article is an open-access article that was selected by an in-house editor and fully peer-reviewed by external reviewers. It is distributed in accordance with the Creative Commons Attribution NonCommercial (CC BY-NC 4.0) license, which permits others to distribute, remix, adapt, build upon this work non-commercially, and license their derivative works on different terms, provided the original work is properly cited and the use is non-commercial. See: <https://creativecommons.org/licenses/by-nc/4.0/>

Country/Territory of origin: Japan

ORCID number: Takaoki Hayakawa 0000-0002-0657-4609; Shinsuke Funakoshi 0000-0002-2012-9851; Yasuo Hamamoto 0000-0002-5737-122x; Kenro Hirata 0000-0003-4536-7781; Takanori Kanai 0000-0002-1466-4532.

S-Editor: Liu JH

L-Editor: A

P-Editor: Yuan YY

REFERENCES

- 1 Blay JY. Pharmacological management of gastrointestinal stromal tumours: an update on the role of sunitinib. *Ann Oncol* 2010; **21**: 208-215 [PMID: 19675092 DOI: 10.1093/annonc/mdp291]
- 2 Neves Briard J, Lezaic N, Keezer MR. Pearls & Oy-sters: Chemotherapy-associated hyperammonemic encephalopathy. *Neurology* 2020; **94**: e874-e877 [PMID: 31992681 DOI: 10.1212/WNL.0000000000009004]
- 3 Chow LQ, Eckhardt SG. Sunitinib: from rational design to clinical efficacy. *J Clin Oncol* 2007; **25**: 884-896 [PMID: 17327610 DOI: 10.1200/JCO.2006.06.3602]
- 4 Kongsuphon N, Soukavanitch M, Teeraumpornpunt N, Konmun J, Ativitavas T, Ngamphaiboon N. Multi-Targeted Tyrosine Kinase

- Inhibitor-Induced Hyperammonemic Encephalopathy: a Report of Two Cases Using Pazopanib, Sunitinib, and Regorafenib. *J Gastrointest Cancer* 2019; **50**: 601-603 [PMID: [29411249](#) DOI: [10.1007/s12029-018-0067-6](#)]
- 5 **Nott L**, Price TJ, Pittman K, Patterson K, Fletcher J. Hyperammonemia encephalopathy: an important cause of neurological deterioration following chemotherapy. *Leuk Lymphoma* 2007; **48**: 1702-1711 [PMID: [17786705](#) DOI: [10.1080/10428190701509822](#)]
- 6 **Lee NR**, Yhim HY, Yim CY, Kwak JY, Song EK. Sunitinib-induced hyperammonemic encephalopathy in gastrointestinal stromal tumors. *Ann Pharmacother* 2011; **45**: e56 [PMID: [21954449](#) DOI: [10.1345/aph.1Q038](#)]
- 7 **Faivre S**, Delbaldo C, Vera K, Robert C, Lozahic S, Lassau N, Bello C, Deprimo S, Brega N, Massimini G, Armand JP, Scigalla P, Raymond E. Safety, pharmacokinetic, and antitumor activity of SU11248, a novel oral multitarget tyrosine kinase inhibitor, in patients with cancer. *J Clin Oncol* 2006; **24**: 25-35 [PMID: [16314617](#) DOI: [10.1200/JCO.2005.02.2194](#)]
- 8 **Kasahara M**, Nakagawa A, Sakamoto S, Tanaka H, Shigeta T, Fukuda A, Nosaka S, Matsui A. Living donor liver transplantation for congenital absence of the portal vein with situs inversus. *Liver Transpl* 2009; **15**: 1641-1643 [PMID: [19877232](#) DOI: [10.1002/lt.21839](#)]
- 9 **Willson KJ**, Nott LM, Broadbridge VT, Price T. Hepatic encephalopathy associated with cancer or anticancer therapy. *Gastrointest Cancer Res* 2013; **6**: 11-16 [PMID: [23505573](#)]
- 10 **Haroon S**, Ko S, Wong A, Tan PS, Lee E, Lau T. Sunitinib-associated hyperammonemic encephalopathy successfully managed with higher intensity conventional hemodialysis: A case report. *Medicine (Baltimore)* 2021; **100**: e24313 [PMID: [33592876](#) DOI: [10.1097/MD.00000000000024313](#)]



Published by **Baishideng Publishing Group Inc**
7041 Koll Center Parkway, Suite 160, Pleasanton, CA 94566, USA

Telephone: +1-925-3991568

E-mail: bpgoffice@wjgnet.com

Help Desk: <https://www.f6publishing.com/helpdesk>

<https://www.wjgnet.com>

