

# World Journal of *Clinical Cases*

*World J Clin Cases* 2023 November 6; 11(31): 7508-7740



## Contents

Thrice Monthly Volume 11 Number 31 November 6, 2023

## REVIEW

- 7508 Gut microbiome: New perspectives for type 2 diabetes prevention and treatment  
*Li SX, Guo Y*

## MINIREVIEWS

- 7521 Endoscopic management of benign biliary strictures: Looking for the best stent to place  
*Colombo M, Forcignanò E, Da Rio L, Spadaccini M, Andreozzi M, Giacchetto CM, Carrara S, Maselli R, Galtieri PA, Pellegatta G, Capogreco A, Massimi D, Khalaf K, Hassan C, Anderloni A, Repici A, Fugazza A*
- 7530 Antibiotic resistance in patients with liver cirrhosis: Prevalence and current approach to tackle  
*Liakina V*

## ORIGINAL ARTICLE

## Retrospective Study

- 7543 Analysis of risk factors for postoperative deep vein thrombosis after craniotomy and nomogram model construction  
*Su ZJ, Wang HR, Liu LQ, Li N, Hong XY*
- 7553 Value of ultrasound and magnetic resonance imaging combined with tumor markers in the diagnosis of ovarian tumors  
*Yang Q, Zhang H, Ma PQ, Peng B, Yin GT, Zhang NN, Wang HB*
- 7562 Measurement of combined flap thickness for reconstruction of decubitus ulcer using computed tomography  
*Kim EC, Park JD, Wee SY, Kim SY*
- 7570 Does the advantage of transcutaneous oximetry measurements in diabetic foot ulcer apply equally to free flap reconstruction?  
*Lee DW, Hwang YS, Byeon JY, Kim JH, Choi HJ*

## Clinical Trials Study

- 7583 Effects of ulinastatin therapy in deep vein thrombosis prevention after brain tumor surgery: A single-center randomized controlled trial  
*Tao YN, Han Q, Jiao W, Yang LK, Wang F, Xue S, Shen M, Wang YH*

## Observational Study

- 7593 Network pharmacological and molecular docking study of the effect of Liu-Wei-Bu-Qi capsule on lung cancer  
*Yang Q, Li LY*

- 7610** Efficacy of  $\beta_2$ -adrenergic receptor agonist combined with corticosteroid in the treatment of children with cough variant asthma

*Cao JY, Wang YC, Deng XX*

#### Randomized Controlled Trial

- 7619** Protective effect of sevoflurane on lung function of elderly chronic obstructive pulmonary disease patients undergoing total hip arthroplasty

*Yao Y, Zhang MS, Li YB, Zhang MZ*

#### CASE REPORT

- 7629** Sunitinib-induced hyperammonemic encephalopathy in metastatic gastrointestinal stromal tumors: A case report

*Hayakawa T, Funakoshi S, Hamamoto Y, Hirata K, Kanai T*

- 7635** Simultaneous lateral and subxiphoid access methods for safe and accurate resection of a superior vena cava aneurysm: A case report

*Kim SP, Son J*

- 7640** Ultrafast power Doppler imaging for ischemic encephalopathy: A case report

*Huang LJ, Jiao JF, He Q, Luo JW, Guo Y*

- 7647** Intermittent spontaneous ovulation in patients with premature ovarian failure: Three case reports and review of literature

*Zhang WY, Wang HB, Deng CY*

- 7656** Sneddon's syndrome concurrent with cerebral venous sinus thrombosis: A case report

*Heng Y, Tang YF, Zhang XW, Duan JF, Shi J, Luo Q*

- 7663** Carcinosarcoma of the deep lobe of the parotid gland in the parapharyngeal region: A case report

*Tang YY, Zhu GQ, Zheng ZJ, Yao LH, Wan ZX, Liang XH, Tang YL*

- 7673** Malignant peripheral nerve sheath tumor with hemophilic syndrome and bone marrow fibrosis: A rare case report

*Li H, Wang L, Wu YH, Chen G, Li HX, Fan LF, Gu M, Jiang CH*

- 7680** Comparison of drug concentrations in blood and gastric lavage fluid before and after gastric lavage: A case report

*Zhou Y, Tong JL, Peng AH, Xu SY*

- 7684** Recurred forehead osteoma disseminated after previous osteoma excision: A case report

*Lee DY, Lim S, Yoon JS, Eo S*

- 7690** Renal pelvis sarcomatoid carcinoma with renal vein tumor thrombus: A case report and literature review

*Guan HY, Wang J, Wang JX, Chen QH, Lu J, He L*

- 7699** Ultrasonographic identification of lateral femoral cutaneous nerve anatomical variation in persistent meralgia paresthetica: A case report

*Park HW, Ji KS, Kim JH, Kim LN, Ha KW*

- 7706** Biliary hemorrhage caused by a malignant small round cell tumor in the common bile duct: A case report  
*Jin YL, Ruan YJ, Lu GR*
- 7712** Successive development of ischemic malignant strokes in a patient with multiple fusiform aneurysms: A case report  
*Shin DS, Yeo DK, Choi EJ*
- 7718** Isolated axillary tumor deposit consistent with primary breast carcinoma: A case report  
*Li T, Zhang WH, Liu J, Mao YL, Liu S*
- 7724** Multiple inflammatory pseudotumor formation after craniopharyngioma resection *via* an extended nasal endoscopic approach: A case report  
*Wu H, Ding YW, Yan ZC, Wei M, Wang XD, Zhang HZ*
- 7732** Huge Bartholin's cyst managed by primary marsupialization: A case report  
*Li HY, Ding DC*

**LETTER TO THE EDITOR**

- 7738** Do not forget diet and exercise during Ramadan  
*Ilias I, Tselebis A*

**ABOUT COVER**

Editorial Board Member of *World Journal of Clinical Cases*, How-Ran Guo, DSc, MD, MSc, Full Professor, Department of Environmental and Occupational Health, College of Medicine, National Cheng Kung University, Tainan 70428, Taiwan. [hrguo@mail.ncku.edu.tw](mailto:hrguo@mail.ncku.edu.tw)

**AIMS AND SCOPE**

The primary aim of *World Journal of Clinical Cases* (*WJCC*, *World J Clin Cases*) is to provide scholars and readers from various fields of clinical medicine with a platform to publish high-quality clinical research articles and communicate their research findings online.

*WJCC* mainly publishes articles reporting research results and findings obtained in the field of clinical medicine and covering a wide range of topics, including case control studies, retrospective cohort studies, retrospective studies, clinical trials studies, observational studies, prospective studies, randomized controlled trials, randomized clinical trials, systematic reviews, meta-analysis, and case reports.

**INDEXING/ABSTRACTING**

The *WJCC* is now abstracted and indexed in Science Citation Index Expanded (SCIE, also known as SciSearch®), Journal Citation Reports/Science Edition, Current Contents®/Clinical Medicine, PubMed, PubMed Central, Reference Citation Analysis, China National Knowledge Infrastructure, China Science and Technology Journal Database, and Superstar Journals Database. The 2023 Edition of Journal Citation Reports® cites the 2022 impact factor (IF) for *WJCC* as 1.1; IF without journal self cites: 1.1; 5-year IF: 1.3; Journal Citation Indicator: 0.26; Ranking: 133 among 167 journals in medicine, general and internal; and Quartile category: Q4.

**RESPONSIBLE EDITORS FOR THIS ISSUE**

Production Editor: *Si Zhao*; Production Department Director: *Xiang Li*; Editorial Office Director: *Jin-Lei Wang*.

**NAME OF JOURNAL**

*World Journal of Clinical Cases*

**ISSN**

ISSN 2307-8960 (online)

**LAUNCH DATE**

April 16, 2013

**FREQUENCY**

Thrice Monthly

**EDITORS-IN-CHIEF**

Bao-Gan Peng, Salim Surani, Jerzy Tadeusz Chudek, George Kontogeorgos, Maurizio Serati

**EDITORIAL BOARD MEMBERS**

<https://www.wjgnet.com/2307-8960/editorialboard.htm>

**PUBLICATION DATE**

November 6, 2023

**COPYRIGHT**

© 2023 Baishideng Publishing Group Inc

**INSTRUCTIONS TO AUTHORS**

<https://www.wjgnet.com/bpg/gerinfo/204>

**GUIDELINES FOR ETHICS DOCUMENTS**

<https://www.wjgnet.com/bpg/GerInfo/287>

**GUIDELINES FOR NON-NATIVE SPEAKERS OF ENGLISH**

<https://www.wjgnet.com/bpg/gerinfo/240>

**PUBLICATION ETHICS**

<https://www.wjgnet.com/bpg/GerInfo/288>

**PUBLICATION MISCONDUCT**

<https://www.wjgnet.com/bpg/gerinfo/208>

**ARTICLE PROCESSING CHARGE**

<https://www.wjgnet.com/bpg/gerinfo/242>

**STEPS FOR SUBMITTING MANUSCRIPTS**

<https://www.wjgnet.com/bpg/GerInfo/239>

**ONLINE SUBMISSION**

<https://www.f6publishing.com>



# Multiple inflammatory pseudotumor formation after craniopharyngioma resection *via* an extended nasal endoscopic approach: A case report

Hao Wu, Yu-Wei Ding, Zheng-Cun Yan, Min Wei, Xiao-Dong Wang, Heng-Zhu Zhang

**Specialty type:** Medicine, research and experimental

**Provenance and peer review:** Unsolicited article; Externally peer reviewed.

**Peer-review model:** Single blind

**Peer-review report's scientific quality classification**

Grade A (Excellent): 0  
Grade B (Very good): 0  
Grade C (Good): C  
Grade D (Fair): 0  
Grade E (Poor): 0

**P-Reviewer:** Gica N, Romania

**Received:** September 12, 2023

**Peer-review started:** September 12, 2023

**First decision:** September 19, 2023

**Revised:** September 27, 2023

**Accepted:** October 17, 2023

**Article in press:** October 17, 2023

**Published online:** November 6, 2023



**Hao Wu**, Department of Neurosurgery, The Second Affiliated Hospital of Xi'an Medical University, Xi'an 710038, Shaanxi Province, China

**Hao Wu, Zheng-Cun Yan, Min Wei, Xiao-Dong Wang, Heng-Zhu Zhang**, Department of Neurosurgery, Clinical Medical College, Yangzhou University, Yangzhou 225001, Jiangsu Province, China

**Yu-Wei Ding**, Department of Neurosurgery, The Yangzhou School of Clinical Medicine of Dalian Medical University, Yangzhou 225001, Jiangsu Province, China

**Corresponding author:** Heng-Zhu Zhang, MD, PhD, Deputy Director, Senior Researcher, Department of Neurosurgery, Clinical Medical College, Yangzhou University, No. 98 Nantong Xi Road, Yangzhou 225001, Jiangsu Province, China. [zhanghengzhu@sina.com](mailto:zhanghengzhu@sina.com)

## Abstract

### BACKGROUND

This report describes a case of intracranial multiple inflammatory pseudotumors (IP) after endoscopic resection of a craniopharyngioma, which is relatively rarely reported in the literature, and neurosurgeons should be aware of its existence.

### CASE SUMMARY

Herein, we report the case of a 56-year-old man who developed decreased visual acuity and blurred vision without obvious cause or inducement on April 27, 2020. To seek further treatment, he went to the Department of Neurosurgery, Clinical Medical College, Yangzhou University. After falling ill, there was no nausea, vomiting, limb convulsions, obvious disturbance of consciousness, speech disorders, cough, or persistent fever. The neurological examination findings were normal, and pituitary magnetic resonance imaging (MRI) revealed multiple nodules with abnormal signals in the sellar region. The diagnosis was craniopharyngioma. We performed total resection of the tumor *via* transnasal endoscopy, and the postoperative pathology suggested that the type of tumor was craniopharyngioma. Six months after the operation, the patient experienced sudden hearing loss in the right ear, tinnitus in both ears, and numbness on the right side of the face and head. Meanwhile, cranial MRI showed multiple IP. After steroid hormone and anti-inflammatory therapy, the above symptoms did not significantly improve. Finally, the patient's symptoms were well improved by

surgery, and the postoperative pathological diagnosis was multiple IP.

## CONCLUSION

Intracranial inflammatory pseudotumor is a benign disease with slow progression, but the clinical symptoms and imaging findings are not typical, there are no pathological findings, and the diagnosis is relatively difficult. Most of the cases are treated by surgical resection, and the prognosis is good after surgery.

**Key Words:** Multiple inflammatory pseudotumors; Craniopharyngioma; Treatment; Brain; Oncology; Case report

©The Author(s) 2023. Published by Baishideng Publishing Group Inc. All rights reserved.

**Core Tip:** Inflammatory pseudotumor, also known as inflammatory myofibroblastoma, is a nodular lesion with fibrous connective tissue proliferation accompanied by a large number of inflammatory cells. The disease can occur in any part of the body, most often in the lungs, but also in the liver, spleen, lymph nodes, and other parts, and intracranial occurrence is relatively rare, especially after craniopharyngioma resection *via* an extended nasal endoscopic approach. The purpose of this case report is to remind clinicians of the existence of inflammatory pseudotumors after craniocerebral surgery.

**Citation:** Wu H, Ding YW, Yan ZC, Wei M, Wang XD, Zhang HZ. Multiple inflammatory pseudotumor formation after craniopharyngioma resection *via* an extended nasal endoscopic approach: A case report. *World J Clin Cases* 2023; 11(31): 7724-7731

**URL:** <https://www.wjgnet.com/2307-8960/full/v11/i31/7724.htm>

**DOI:** <https://dx.doi.org/10.12998/wjcc.v11.i31.7724>

## INTRODUCTION

Inflammatory pseudotumors (IP) are localized, isolated, nonneoplastic, space-occupying lesions characterized histopathologically by a mixture of collagenous fibers and inflammatory cells, such as lymphocytes and plasma cells[1]. These tumors have been reported to occur most commonly in the lungs, mesentery, greater omentum, retroperitoneum, genitourinary tract, or upper respiratory tract. However, IP of the central nervous system are rare[2]. Most intracranial IP originate from the dura mater and meningeal structures[3]. There have been few reports of multiple IP (MIP) in the intracranial space after surgery for craniopharyngioma resection.

## CASE PRESENTATION

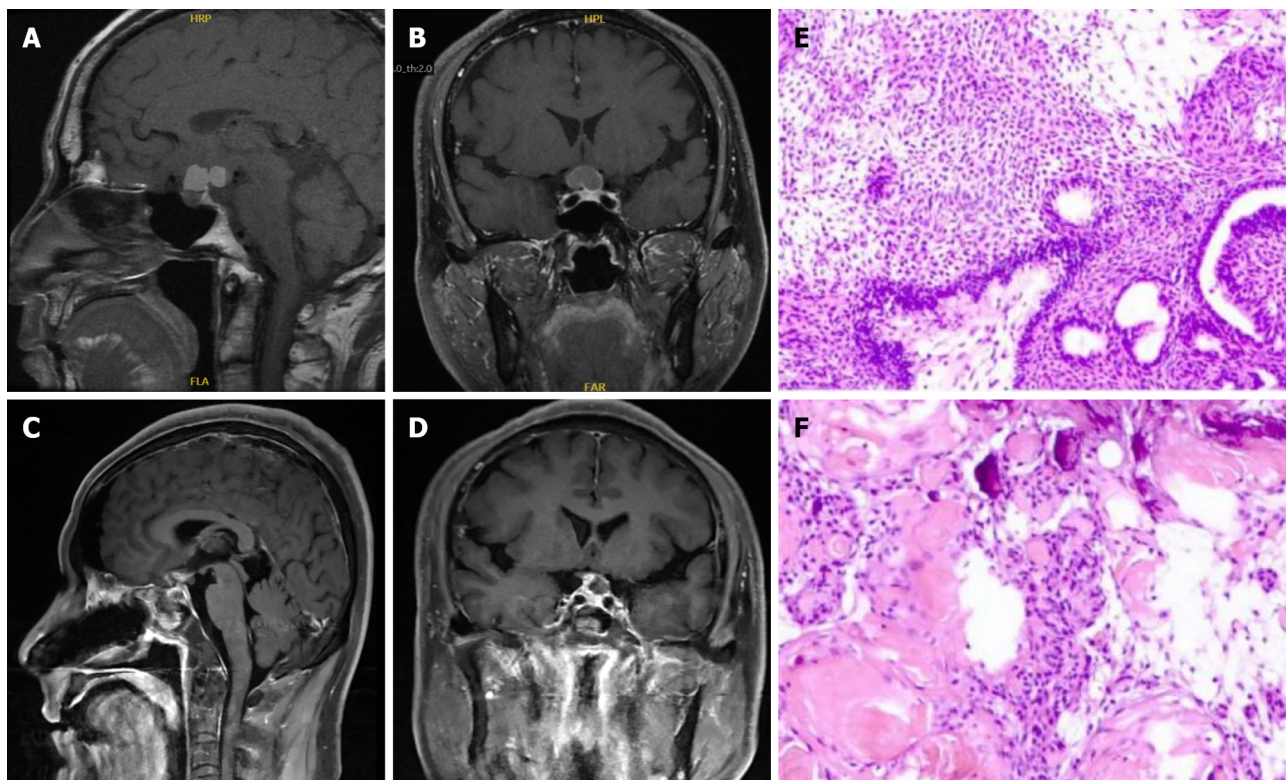
### Chief complaints

A 56-year-old man developed decreased visual acuity and blurred vision without obvious cause or inducement that lasted for 15 d.

### History of present illness

The patient presented to the Department of Neurosurgery, Clinical Medical College, Yangzhou University, with decreased visual acuity and blurred vision that lasted for 15 d. The neurological examination findings were normal, and he had previously been in good health without any infectious diseases or immune disorders. Enhanced pituitary magnetic resonance imaging (MRI) revealed multiple nodules in the suprasellar region with slightly shorter T1 signals, compression of the optic chiasma, and compression of the superior pituitary margin in a region of approximately 19 mm × 12 mm × 21 mm. The preoperative diagnosis was craniopharyngioma (Figure 1A and B). The patient's routine laboratory results were normal. The tumor was removed by an endoscopic transnasal transsellar tubercle sphenoid platform approach. Intraoperatively, the tumor was located in the suprasellar suboptic space with cystic changes and was connected to the posterior part of the pituitary gland. Postoperative MRI showed a patchy mixed signal in the sellar region (Figure 1C and D). Postoperative histopathology revealed hyperplasia, showing nests and a papillary arrangement of epithelial nests with a fenestrated arrangement of marginal cells in some areas; additionally, ghost cells were seen with calcification (Figure 1E and F). The final diagnosis was craniopharyngioma of the sellar region (enamel-forming cell type). Postoperative review MRI showed a patchy mixed signal in the sellar region, and the sellar base was incomplete. A nodal shadow was visible in the sellar region, with significant enhancement; the shadow was approximately 10 mm × 9 mm in extent and poorly demarcated from the visual cross. The patient recovered well after surgery without special discomfort. Six months after the operation, the patient suffered from sudden hearing loss in the right ear, tinnitus in both ears, and numbness of the right side of the face and head, without any signs of infection. Physical examination revealed hearing loss in the right ear. Enhanced MRI of the inner ear showed multiple patchy and nodular, distinctly enhancing abnormal shadows around the right pontocerebellar horn, right cerebellum, and quadrigeminal cistern; the largest lesion was in the right pontocerebellar horn, approximately 17 mm × 14 mm in size, with gross margins and significant thickening of the





DOI: 10.12998/wjcc.v11.i31.7724 Copyright ©The Author(s) 2023.

**Figure 1** Imaging data and pathological examination images (first operation). A and B: Preoperative magnetic resonance imaging (MRI); C and D: Postoperative MRI; E and F: Postoperative pathological findings.

right rocky meninges. Multiple IP were considered (Figure 2A-D). The patient was treated with steroid pulse therapy, and he received an initial high-dose regimen of 80 mg of methylprednisolone for 4 d, followed by a one-day drug cessation and then a maintenance dose of 40 mg of methylprednisolone for another 4 d. Despite this treatment approach, the patient's primary symptoms remained unresolved, and subsequent cranial MRI indicated no significant change in the size of the pseudotumors. Ultimately, we opted for surgical resection to remove the tumor, and during follow-up and review, there was no recurrence of the IP. A lesion in the right cerebellum and pontocerebellar horn was resected under neuronavigation. Postoperative pathological examination showed fibrocollagenous tissue hyperplasia and extensive infiltration of inflammatory cells, including lymphocytes (Figure 2E and F). Immunohistochemistry suggested the following: KP1 (scattered +), CD3 (scattered +), CD20 (scattered +), S100 (neural +), CD1a (-), GFAP (brain +), Ki67 (scattered 20%), SMA (vascular +), CD34 (vascular +), and MPO (scattered +). Special staining results were PAS (-), antacid (-), and silver stain (-). The postoperative diagnosis was IP. The patient was discharged 7 d after surgery and was reviewed 3 mo after surgery, without recurrence or significant abnormalities on neurological examination. The patient continues to be under close follow-up (Figure 2G-J).

### History of past illness

The patient had no previous history of infectious diseases, traumas, or bad habits (such as smoking or drinking).

### Personal and family history

The patient denied any family history of tumors.

### Physical examination

On physical examination, the vital signs were as follows: Body temperature, 36.4 °C; blood pressure, 110/88 mmHg; heart rate, 88 beats per min; and respiratory rate, 19 breaths per min. Annual physical examinations (including various laboratory tests and imaging examinations) indicated that the patient was healthy.

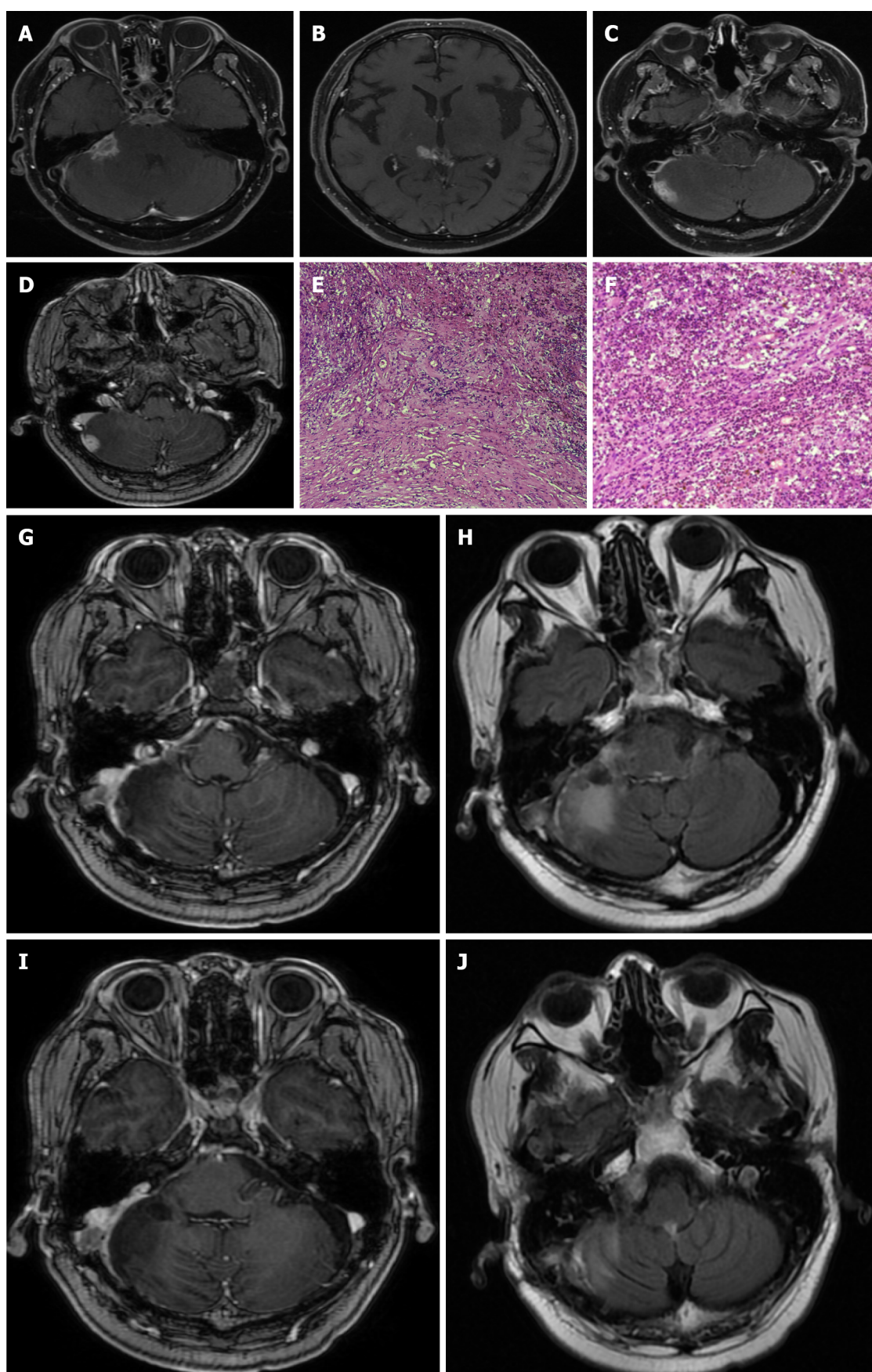
### Laboratory examinations

The white blood cell count was  $7.78 \times 10^9/L$ , and neutrophil count was  $7.37 \times 10^9/L$ . Endocrine test results were normal.

### Imaging examinations

Pre-operative pituitary MRI suggested that there were multiple nodules with abnormal signals in the sellar region. The diagnosis was craniopharyngioma.





DOI: 10.12998/wjcc.v11.i31.7724 Copyright ©The Author(s) 2023.

**Figure 2** Imaging data and postoperative pathological findings of inflammatory pseudotumor (second operation). A-D: T1-weighted enhanced magnetic resonance showed that multiple patchy and nodular reinforcing abnormalities around the right pontocerebellar angle, right cerebellum, and tegmental pool were seen, and the right rocky meninges were significantly thickened; E and F: Microscopic finding of fibrocollagenous tissue hyperplasia with infiltration of

lymphocytes and other inflammatory cells; G-J: Magnetic resonance imaging showed that the multiple reinforcing nodular shadows around the tegmental pool were significantly smaller than before, and the reinforcing foci in the original right pontocerebellar area and cerebellar area are not shown.

Pre-operative contrast-enhanced MRI of the inner ear showed multiple patchy and nodular distinctly enhancing abnormal shadows around the right pontocerebellar horn, right cerebellum, and quadrigeminal cistern, with the largest lesion in the right pontocerebellar horn, approximately 17 mm × 14 mm, with gross margins and significant thickening of the right rocky meninges. MIP were considered.

## FINAL DIAGNOSIS

Combined with the patient's medical history, the final diagnosis was MIP.

## TREATMENT

The main treatment was resection of intracranial lesions.

## OUTCOME AND FOLLOW-UP

Symptoms were relieved gradually after treatment, and complete resolution of symptoms was observed after five days. To date, there has been no recurrence, and the patient is doing well.

## DISCUSSION

### Pathogenesis

The etiology of IP remains uncertain, with three prevailing theories attempting to explain their origin[4]. In terms of their composition, IP exhibit internal fibrosis and infiltration of various inflammatory cells[3], including macrophages, plasma cells, and lymphocytes, suggesting an association with inflammation[5]. Furthermore, minor traumas, surgical interventions, smoking, vasculitis, and malignancies have been proposed as potential triggers[6], indicating an inflammatory response as a causative factor. Infections caused by viruses such as Epstein-Barr virus, cytomegalovirus, and herpes simplex virus have also been linked to the development of IP[3,7]. Moreover, IP have been associated with IgG-4-related diseases, specifically characterized by fibrotic tissue masses infiltrated by IgG-4-positive lymphoplasmacytic cells [8]. In the present case, an intracranial IP emerged subsequent to the transnasal endoscopic resection of a cranio-pharyngioma, with the patient experiencing an intracranial infection postsurgery. Consequently, it is believed that the inflammatory response triggered by an infection following the initial surgery may be responsible for the subsequent development of the intracranial IP. Neuroendoscopic transsphenoidal craniopharyngotomy has been suggested to enhance the rate of complete tumor resection; however, it also increases the incidence of cerebrospinal fluid leakage and intracranial infection and prolongs the operative time and hospital stay. Thus, for patients undergoing endoscopic transsphenoidal craniopharyngotomy, the administration of adequate antibiotics throughout the postoperative period is recommended to prevent intracranial infection. Elderly patients may require an extended duration of antibiotic treatment, and modifications to the surgical approach may be necessary if deemed appropriate. Additionally, postoperative endoscopic evaluation of the saddle base can facilitate the early detection and treatment of occult cerebrospinal fluid leaks.

### Pathology

Due to the limited number of cases, there is currently no standardized pathological classification for intracranial IP, and most reported cases exhibit a mixed predominance of cell types[9]. Microscopically, these lesions are characterized by the presence of polyclonal plasma cells intermingled with varying numbers of lymphocytes, neutrophils, eosinophils, histiocytes, and myofibroblasts[10]. Immunohistochemical analysis has shown positive expression of smooth muscle actin (SMA) in the majority of intracranial IP[9]. In the present case of MIP, microscopic examination revealed the proliferation of fibrillar tissue with significant infiltration of inflammatory cells, particularly lymphocytes. Immunohistochemistry also confirmed positive SMA expression. These pathological findings were consistent with those typically observed in conventional intracranial IP. Thus, it is essential to consider the possibility of IP in all cases of intracranial tumor-like lesions exhibiting lymphoplasmacytic infiltrates and varying densities of collagenous interstitium[11]. Pathological exam remains the gold standard for the diagnosis of intracranial IP.

### Clinical presentation

Intracranial IP are currently categorized into five distinct types[11]: Intracerebral parenchymal, meningeal, mixed parenchymal-meningeal, intracerebroventricular, and extracranial communicating types. The clinical manifestations of these tumors differ slightly depending on their locations. IP located in the skull base typically manifest as pain on the affected side of the head and face, cranial nerve palsy, or cerebrospinal fluid leakage. IP within the brain ventricles often present with symptoms such as hydrocephalus, headache, nausea, vomiting, and vision loss. IP in the brain parenchyma commonly result in increased intracranial pressure and varying degrees of neurological dysfunction based on the specific location. Lesions involving the meninges can exhibit a range of neurological manifestations, with mild cases being asymptomatic and severe cases leading to dysfunction due to compression of the brain parenchyma[12].

### Imaging manifestations

Brain CT scans often reveal a well-defined circumferential shadow with isointense or high-density characteristics, with clear margins and uniform enhancement. MRI of the head demonstrates low signal intensity on both T1- and T2-weighted imaging, with substantial enhancement observed following contrast administration. Delayed enhancement has also been reported in certain cases. It is crucial to note that the diagnosis primarily relies on histopathological examination[13].

### Differential diagnosis

Intracranial IP require differentiation from several other conditions[4], including lymphoplasmacyte-rich meningiomas, lymphomas, and plasmacytomas. Given that most intracranial IP originate from dural and meningeal structures[14], distinguishing them from lymphoplasmacyte-rich meningiomas can be challenging, often resulting in misinterpretation as meningiomas with lymphoplasmacytic infiltrates. However, careful pathological examination can differentiate between the two, primarily through the detection of the tumorigenic proliferation of meningeal cells and positive immunohistochemical staining for EMA[11].

Intracranial primary or secondary malignant lymphomas are malignant neoplasms originating from the central or peripheral lymphatic system, and secondary cases are more common, particularly B-cell non-Hodgkin's lymphoma. Immunohistochemical analysis of lymphomas reveals monoclonal expression of B or T lymphocyte antigens along with positive staining for EMA, which significantly distinguishes them from IP[11].

Plasmacytomas can be discerned through immunohistological flow cytometry, allowing for the determination of whether the plasma cells present are polyclonal or monoclonal. Polyclonal plasma cells indicate a plasmacytoid granuloma, while monoclonal plasma cells indicate a plasmacytoma[4].

### Treatment

The optimal treatment approach for intracranial IP remains uncertain, as there is a lack of a general consensus[4]. Existing treatment options include surgical resection, corticosteroid therapy, immunosuppressive therapy, and radiotherapy. Studies have indicated that a significant number of patients exhibit favorable outcomes following surgical resection, with low rates of recurrence or malignant progression[5,15]. Surgery offers the advantage of alleviating the mass effect of the pseudotumors and potentially reducing the risk of distant recurrence[14].

Many experts consider corticosteroids to be the preferred treatment for IP, particularly in the initial stages[10]. Oral corticosteroids have shown positive effects in the majority of patients, effectively improving symptoms and reducing the size of IP. A recommended initial oral steroid dose of 40 mg per day, gradually tapered to 5 mg to 10 mg per day over a month, has demonstrated efficacy. However, it is important to note that studies have revealed a relatively high recurrence rate of IP after the discontinuation of oral corticosteroids[10].

In this particular case, hormone therapy using methylprednisolone was initiated upon the diagnosis of MIP. The patient received an initial high-dose regimen of 80 mg of methylprednisolone for 4 d, followed by a 1-d drug cessation and then a maintenance dose of 40 mg of methylprednisolone for another 4 d. Despite this treatment approach, the patient's primary symptoms remained unresolved, and subsequent cranial MRI indicated no significant change in the size of the pseudotumors. Ultimately, we opted for surgical resection to remove the tumor, and during follow-up and review, there was no recurrence of the IP.

The ineffectiveness of hormone therapy in this case may be attributed to an incorrect hormone dosage and an insufficient treatment duration. The absence of a standardized dose and duration for oral hormone therapy further complicates treatment decisions, highlighting the need for comprehensive case reports to guide future practices and recommendations.

Radiation therapy has been proposed as an alternative treatment option for intracranial IP in cases where the tumors are insensitive to hormone therapy, there are contraindications to high-dose hormone therapy, relapse occurs after hormone therapy, or the tumors are unsuitable for surgery due to the location of the lesion or the possibility of incomplete surgical resection. In such scenarios, low-dose high-potential fractionated therapy is typically recommended, with a total radiation dose ranging from 20 to 40 Gy[16].

In summary, the treatment of intracranial IP remains a complex matter without a definitive treatment approach. Surgical resection and corticosteroid therapy, particularly oral glucocorticosteroid therapy, have shown positive results in improving symptoms and reducing tumor size. However, the risk of recurrence remains a concern, necessitating further research and evaluation of treatment strategies.



## CONCLUSION

Intracranial IP lack specific imaging manifestations and are easily misdiagnosed as other tumors, and pathology is currently the gold standard for the diagnosis of intracranial IP. Due to the small number of cases and the diverse histopathological classification, the best treatment plan is still inconclusive. In our opinion, surgery is preferred for IP of the central nervous system that can be completely resected without damaging important surrounding structures. If the lesion is not suitable for surgery, steroid hormone therapy or hormone therapy combined with radiotherapy can be administered as appropriate. Patients with intracranial IP should be treated individually according to the location of the lesion and the patient's own characteristics.

## FOOTNOTES

**Author contributions:** Wu H contributed to manuscript writing and editing, and data collection; Ding YW, Yan ZC, Wei M, and Wang XD contributed to data analysis; Zhang HZ contributed to conceptualization and supervision; all authors have read and approved the final manuscript.

**Informed consent statement:** The patient provided informed written consent prior to study enrollment.

**Conflict-of-interest statement:** The authors report no conflicts of interest for this work.

**CARE Checklist (2016) statement:** The authors have read the CARE Checklist (2016), and the manuscript was prepared and revised according to the CARE Checklist (2016).

**Open-Access:** This article is an open-access article that was selected by an in-house editor and fully peer-reviewed by external reviewers. It is distributed in accordance with the Creative Commons Attribution NonCommercial (CC BY-NC 4.0) license, which permits others to distribute, remix, adapt, build upon this work non-commercially, and license their derivative works on different terms, provided the original work is properly cited and the use is non-commercial. See: <https://creativecommons.org/licenses/by-nc/4.0/>

**Country/Territory of origin:** China

**ORCID number:** Hao Wu 0000-0002-0858-8430; Heng-Zhu Zhang 0000-0003-3240-5689.

**S-Editor:** Lin C

**L-Editor:** Wang TQ

**P-Editor:** Lin C

## REFERENCES

- 1 Coffin CM, Watterson J, Priest JR, Dehner LP. Extrapulmonary inflammatory myofibroblastic tumor (inflammatory pseudotumor). A clinicopathologic and immunohistochemical study of 84 cases. *Am J Surg Pathol* 1995; **19**: 859-872 [PMID: 7611533 DOI: 10.1097/0000478-199508000-00001]
- 2 Swain RS, Tihan T, Horvai AE, Di Vizio D, Loda M, Burger PC, Scheithauer BW, Kim GE. Inflammatory myofibroblastic tumor of the central nervous system and its relationship to inflammatory pseudotumor. *Hum Pathol* 2008; **39**: 410-419 [PMID: 18261625 DOI: 10.1016/j.humpath.2007.07.012]
- 3 Jung TY, Jung S, Lee MC, Moon KS, Kim IY, Kang SS, Kim SH. Hemorrhagic intracranial inflammatory pseudotumor originating from the trigeminal nerve: a case report. *J Neurooncol* 2006; **76**: 139-142 [PMID: 16132497 DOI: 10.1007/s11060-005-4173-5]
- 4 Häusler M, Schaade L, Ramaekers VT, Doenges M, Heimann G, Sellhaus B. Inflammatory pseudotumors of the central nervous system: report of 3 cases and a literature review. *Hum Pathol* 2003; **34**: 253-262 [PMID: 12673560 DOI: 10.1053/hupa.2003.35]
- 5 Lin YJ, Yang TM, Lin JW, Song MZ, Lee TC. Posterior fossa intracranial inflammatory pseudotumor: a case report and literature review. *Surg Neurol* 2009; **72**: 712-6; discussion 716 [PMID: 19608242 DOI: 10.1016/j.surneu.2009.01.029]
- 6 Spinazzi EF, Desai SV, Fang CH, Jyung RW, Liu JK, Baredes S, Eloy JA. Lateral skull base Inflammatory pseudotumor: A systematic review. *Laryngoscope* 2015; **125**: 2593-2600 [PMID: 25892586 DOI: 10.1002/lary.25308]
- 7 Fukunaga A, Yoshida K, Otani M, Ogawa Y, Horiguchi T, Ishihara M, Toya S, Kawase T. Plasma cell granuloma extending from the extracranial to the intracranial space associated with Epstein-Barr virus infection. *Neurol Med Chir (Tokyo)* 1998; **38**: 292-296 [PMID: 9640966 DOI: 10.2176/nmc.38.292]
- 8 Patnana M, Sevrakov AB, Elsayes KM, Viswanathan C, Lubner M, Menias CO. Inflammatory pseudotumor: the great mimicker. *AJR Am J Roentgenol* 2012; **198**: W217-W227 [PMID: 22358018 DOI: 10.2214/AJR.11.7288]
- 9 Leclercq D, Trunet S, Bertrand A, Galanaud D, Lehericy S, Dormont D, Drier A. Cerebral tumor or pseudotumor? *Diagn Interv Imaging* 2014; **95**: 906-916 [PMID: 25260711 DOI: 10.1016/j.diii.2014.08.004]
- 10 Perkins SJ, Gao R, Glazer TA, Zhao CX, Basura G, McKean EL. Treatment and Prognosis of Inflammatory Pseudotumor of the Skull Base. *J Neurol Surg B Skull Base* 2022; **83**: e555-e563 [PMID: 35832938 DOI: 10.1055/s-0041-1735558]
- 11 Lui PC, Fan YS, Wong SS, Chan AN, Wong G, Chau TK, Tse GM, Cheng Y, Poon WS, Ng HK. Inflammatory pseudotumors of the central nervous system. *Hum Pathol* 2009; **40**: 1611-1617 [PMID: 19656549 DOI: 10.1016/j.humpath.2009.04.016]
- 12 Narla LD, Newman B, Spottswood SS, Narla S, Kolli R. Inflammatory pseudotumor. *Radiographics* 2003; **23**: 719-729 [PMID: 12740472]

DOI: [10.1148/rg.233025073](https://doi.org/10.1148/rg.233025073)]

- 13 **Lee SG**, Shin IY, Hwang HS, Choi I. Multimodal Treatment of Skull Base Inflammatory Pseudotumor: Case Report. *Brain Tumor Res Treat* 2015; **3**: 122-126 [PMID: [26605269](https://pubmed.ncbi.nlm.nih.gov/26605269/) DOI: [10.14791/btrt.2015.3.2.122](https://doi.org/10.14791/btrt.2015.3.2.122)]
- 14 **Derrey S**, Charpentier C, Gérardin E, Langlois O, Touchais JY, Lerebours E, Proust F, Laquerrière A. Inflammatory pseudotumor of the cerebellum in a patient with Crohn's disease. *World Neurosurg* 2012; **77**: 201.e13-201.e16 [PMID: [22405397](https://pubmed.ncbi.nlm.nih.gov/22405397/) DOI: [10.1016/j.wneu.2011.05.034](https://doi.org/10.1016/j.wneu.2011.05.034)]
- 15 **Kuang PD**, Li QH, Liu ZY, Tang JL, Dong F, Wang Y, Zhu XL. Inflammatory pseudotumor of the pineal region: First reported case. *Oncol Lett* 2016; **11**: 2127-2130 [PMID: [26998134](https://pubmed.ncbi.nlm.nih.gov/26998134/) DOI: [10.3892/ol.2016.4212](https://doi.org/10.3892/ol.2016.4212)]
- 16 **Desai SV**, Spinazzi EF, Fang CH, Huang G, Tomovic S, Liu JK, Baredes S, Eloy JA. Sinonasal and ventral skull base inflammatory pseudotumor: a systematic review. *Laryngoscope* 2015; **125**: 813-821 [PMID: [25376630](https://pubmed.ncbi.nlm.nih.gov/25376630/) DOI: [10.1002/lary.24993](https://doi.org/10.1002/lary.24993)]



Published by **Baishideng Publishing Group Inc**  
7041 Koll Center Parkway, Suite 160, Pleasanton, CA 94566, USA

**Telephone:** +1-925-3991568

**E-mail:** [bpgoffice@wjgnet.com](mailto:bpgoffice@wjgnet.com)

**Help Desk:** <https://www.f6publishing.com/helpdesk>

<https://www.wjgnet.com>

