

World Journal of *Clinical Cases*

World J Clin Cases 2023 December 26; 11(36): 8434-8605



Contents

Thrice Monthly Volume 11 Number 36 December 26, 2023

EDITORIAL

- 8434 Post-trans-arterial chemoembolization hepatic necrosis and biliary stenosis: Clinical characteristics and endoscopic approach

Cocca S, Carloni L, Marocchi M, Grande G, Bianchini M, Colecchia A, Conigliaro R, Bertani H

MINIREVIEWS

- 8440 Perioperative nursing care for hip arthroplasty patients with concomitant hypertension: A minireview

Ji CY, Yang LR

ORIGINAL ARTICLE

Retrospective Study

- 8447 Evaluation of response to gemcitabine plus cisplatin-based chemotherapy using positron emission computed tomography for metastatic bladder cancer

Öztürk H, Karapolat İ

- 8458 Functional magnetic resonance imaging study of group independent components underpinning item responses to paranoid-depressive scale

Stoyanov D, Paunova R, Dichev J, Kandilarova S, Khorev V, Kurkin S

EVIDENCE-BASED MEDICINE

- 8475 Mendelian randomization provides evidence for a causal effect of serum insulin-like growth factor family concentration on risk of atrial fibrillation

Lin S, Tang J, Li X, Wu G, Lin YF, Li YF

SYSTEMATIC REVIEWS

- 8486 Significance of fostering the mental health of patients with diabetes through critical time intervention

Eseadi C, Amedu AN, Aloh HE

META-ANALYSIS

- 8498 Impact of angiotensin-converting enzyme inhibitors or angiotensin receptor blockers on the mortality in sepsis: A meta-analysis

Yang DC, Xu J, Jian L, Yu Y

CASE REPORT

- 8507 Multiple sparganosis spinal infections mainly in the thoracic region: A case report

Wen GJ, Chen J, Zhang SF, Zhou ZS, Jiao GL

- 8512** Iatrogenic flexor tendon rupture caused by misdiagnosing sarcoidosis-related flexor tendon contracture as tenosynovitis: A case report
Yan R, Zhang Z, Wu L, Wu ZP, Yan HD
- 8519** Cholecystoenteric fistula in a patient with advanced gallbladder cancer: A case report and review of literature
Wang CY, Chiu SH, Chang WC, Ho MH, Chang PY
- 8527** Intraperitoneal hyaline vascular Castleman disease: Three case reports
Gao JW, Shi ZY, Zhu ZB, Xu XR, Chen W
- 8535** Iris metastasis from clear cell renal cell carcinoma: A case report
Wang TT, Chen XY, Min QY, Han YZ, Zhao HF
- 8542** Spinal cord infarction attributed to SARS-CoV-2, with post-acute sequelae of COVID-19: A case report
Oleson CV, Olsen AC, Shermon S
- 8551** Spontaneous gastric hematoma as a rare cause of acute abdomen: A case report
Budimir I, Žulec M, Eljuga K, Židak M, Lisek V
- 8557** LiNA OperaScope™ for microwave endometrial ablation for endometrial polyps with heavy menstrual bleeding: A case report
Kakinuma K, Kakinuma T, Ueyama K, Shinohara T, Okamoto R, Yanagida K, Takeshima N, Ohwada M
- 8563** Colonoscopy-induced acute appendicitis: A case report
Song XL, Ma JY, Zhang ZG
- 8568** Post-laparotomy heterotopic ossification of the xiphoid process: A case report
Lee SS
- 8574** Balloon displacement during caesarean section with pernicious placenta previa: A case report
Gu DF, Deng C
- 8581** Synchronous carotid endarterectomy and coronary artery bypass graft: Four case reports
AlGhamdi FK, Altoijry A, AlQahtani A, Aldossary MY, AlSheikh SO, Iqbal K, Alayadhi WA
- 8589** Intraoperative cardiogenic shock induced by refractory coronary artery spasm in a patient with myasthenia gravis: A case report
Hsu CW, Chang CC, Lin CS
- 8595** Effects of video game-based therapy in an adolescent with cerebral palsy: A case report
Mohd Iqbal HA, Ho WS, Zanudin A, Hisham H, Mohd Nordin NA

LETTER TO THE EDITOR

- 8603** Lyophilized recombinant human brain natriuretic peptide: A promising therapy in patients with chronic heart failure
Kourek C, Briasoulis A, Giamouzis G, Skoularigis J, Xanthopoulos A

ABOUT COVER

Editorial Board Member of *World Journal of Clinical Cases*, Marco Infante, MD, PhD, Adjunct Professor, UniCamillus, Saint Camillus International University of Health Sciences, Rome 00131, Italy.
marco.infante@unicamillus.org

AIMS AND SCOPE

The primary aim of *World Journal of Clinical Cases* (WJCC, *World J Clin Cases*) is to provide scholars and readers from various fields of clinical medicine with a platform to publish high-quality clinical research articles and communicate their research findings online.

WJCC mainly publishes articles reporting research results and findings obtained in the field of clinical medicine and covering a wide range of topics, including case control studies, retrospective cohort studies, retrospective studies, clinical trials studies, observational studies, prospective studies, randomized controlled trials, randomized clinical trials, systematic reviews, meta-analysis, and case reports.

INDEXING/ABSTRACTING

The WJCC is now abstracted and indexed in Science Citation Index Expanded (SCIE, also known as SciSearch®), Journal Citation Reports/Science Edition, Current Contents®/Clinical Medicine, PubMed, PubMed Central, Reference Citation Analysis, China Science and Technology Journal Database, and Superstar Journals Database. The 2023 Edition of Journal Citation Reports® cites the 2022 impact factor (IF) for WJCC as 1.1; IF without journal self cites: 1.1; 5-year IF: 1.3; Journal Citation Indicator: 0.26; Ranking: 133 among 167 journals in medicine, general and internal; and Quartile category: Q4.

RESPONSIBLE EDITORS FOR THIS ISSUE

Production Editor: Zi-Hang Xu, Production Department Director: Xiang Li, Editorial Office Director: Jin-Lei Wang.

NAME OF JOURNAL

World Journal of Clinical Cases

ISSN

ISSN 2307-8960 (online)

LAUNCH DATE

April 16, 2013

FREQUENCY

Thrice Monthly

EDITORS-IN-CHIEF

Bao-Gan Peng, Salim Surani, Jerzy Tadeusz Chudek, George Kontogeorgos, Maurizio Serati

EDITORIAL BOARD MEMBERS

<https://www.wjgnet.com/2307-8960/editorialboard.htm>

PUBLICATION DATE

December 26, 2023

COPYRIGHT

© 2024 Baishideng Publishing Group Inc

INSTRUCTIONS TO AUTHORS

<https://www.wjgnet.com/bpg/gerinfo/204>

GUIDELINES FOR ETHICS DOCUMENTS

<https://www.wjgnet.com/bpg/GerInfo/287>

GUIDELINES FOR NON-NATIVE SPEAKERS OF ENGLISH

<https://www.wjgnet.com/bpg/gerinfo/240>

PUBLICATION ETHICS

<https://www.wjgnet.com/bpg/GerInfo/288>

PUBLICATION MISCONDUCT

<https://www.wjgnet.com/bpg/gerinfo/208>

ARTICLE PROCESSING CHARGE

<https://www.wjgnet.com/bpg/gerinfo/242>

STEPS FOR SUBMITTING MANUSCRIPTS

<https://www.wjgnet.com/bpg/GerInfo/239>

ONLINE SUBMISSION

<https://www.f6publishing.com>



Retrospective Study

Evaluation of response to gemcitabine plus cisplatin-based chemotherapy using positron emission computed tomography for metastatic bladder cancer

Hakan Öztürk, İnanç Karapolat

Specialty type: Oncology

Provenance and peer review:

Unsolicited article; Externally peer reviewed.

Peer-review model: Single blind

Peer-review report's scientific quality classification

Grade A (Excellent): 0
Grade B (Very good): 0
Grade C (Good): C
Grade D (Fair): 0
Grade E (Poor): 0

P-Reviewer: Pavlidis TE, Greece

Received: September 22, 2023

Peer-review started: September 22, 2023

First decision: November 9, 2023

Revised: November 10, 2023

Accepted: December 6, 2023

Article in press: December 6, 2023

Published online: December 26, 2023



Hakan Öztürk, Department of Urology, Izmir University of Economics, Karsiyaka Izmir 35330, Turkey

İnanç Karapolat, Department of Nuclear Medicine, School of Medicine, İzmir Tınaztepe University, Izmir 35000, Turkey

Corresponding author: Hakan Öztürk, MD, Adjunct Associate Professor, Associate Professor, Department of Urology, Izmir University of Economics, 1825 sok no 12 Medicalpoint Hospital, Karsiyaka Izmir 35330, Turkey. drhakanozturk@yahoo.com.tr

Abstract

BACKGROUND

The purpose of the present study was to examine retrospectively the contribution of ¹⁸Fluorodeoxyglucose positron emission tomography computed tomography (¹⁸FDG-PET/CT) to the evaluation of response to first-line gemcitabine plus cisplatin-based chemotherapy in patients with metastatic bladder cancer.

AIM

To evaluate the response to Gemcitabine plus Cisplatin -based chemotherapy using ¹⁸FDG-PET/CT imaging in patients with metastatic bladder cancer.

METHODS

Between July 2007 and April 2019, 79 patients underwent ¹⁸FDG-PET/CT imaging with the diagnosis of Metastatic Bladder Carcinoma (M-BCa). A total of 42 patients (38 male, 4 female) were included in the study, and all had been administered Gemcitabine plus Cisplatin-based chemotherapy. After completion of the therapy, the patients underwent a repeat ¹⁸FDG-PET/CT scan and the results were compared with the PET/CT findings before chemotherapy according to European Organisation for the Research and treatment of cancer criteria. Mean age was 66.1 years and standard deviation was 10.7 years (range: 41–84 years).

RESULTS

Of the patients, seven (16.6%) were in complete remission, 17 (40.5%) were in partial remission, six (14.3%) had a stable disease, and 12 (28.6%) had a progressive disease. The overall response rate was 57.1 percent.

CONCLUSION

^{18}F FDG-PET/CT can be considered as a successful imaging tool in evaluating response to first-line chemotherapy for metastatic bladder cancer. Anatomical and functional data obtained from PET/CT scans may be useful in the planning of secondline and thirdline chemotherapy.

Key Words: Metastatic bladder cancer; Response to chemotherapy; Positron emission tomography computed tomography; ^{18}F FDG-PET/CT

©The Author(s) 2023. Published by Baishideng Publishing Group Inc. All rights reserved.

Core Tip: ^{18}F Fluorodeoxyglucose positron emission tomography computed tomography can be considered as a successful imaging tool in evaluating response to first-line chemotherapy for metastatic bladder cancer. Anatomical and functional data obtained from positron emission tomography computed tomography scans can be useful in the planning of second and third-line chemotherapy.

Citation: Öztürk H, Karapolat İ. Evaluation of response to gemcitabine plus cisplatin-based chemotherapy using positron emission computed tomography for metastatic bladder cancer. *World J Clin Cases* 2023; 11(36): 8447-8457

URL: <https://www.wjgnet.com/2307-8960/full/v11/i36/8447.htm>

DOI: <https://dx.doi.org/10.12998/wjcc.v11.i36.8447>

INTRODUCTION

Bladder cancer is the ninth most common cancer all over the world with 380.000 new cases annually. Ration of male: female patients is 3.8:1[1]. According to database of Surveillance, Epidemiology and End Results, no significant change has occurred over the last 30 years in the number of patients dying of bladder cancer[2]. 10% to 15% of the patients with bladder cancer are metastatic at the time of diagnosis. The local recurrence rate after a radical cystectomy is 30% in muscle-invasive bladder carcinoma, and the rate of metastatic disease is even higher, at 60%[3,4]. Metastases are the main cause of death in this disease, and despite all therapies, 50% of patients with local disease develop metastasis within two years[5]. Metastatic bladder carcinoma is associated with extremely poor prognosis. Systematic chemotherapy is the standard therapy for metastatic disease.

Bladder transitional cell carcinoma (TCC) are usually chemosensitive tumors but response to a single agent is limited. Cisplatin, cyclophosphamide and vinblastine, cisplatin, doxorubicin and cyclophosphamide and methotrexate, vinblastine, adriamycin and cisplatin (M-VAC) induced 12% to 78% overall response rate (ORR)[6]. The combination of gemcitabine with cisplatin (GC) has become the first-line chemotherapy and has further improved results with higher ORR (57%) and complete remission (CR) (15% to 21%)[7].

Diagnosing occult metastases in bladder cancer is still a challenge, and there is much more need for a diagnostic test for monitoring response to therapy and predicting residual disease in patients after chemotherapy. ^{18}F Fluorodeoxyglucose positron emission tomography computed tomography (^{18}F FDG PET/CT) is the most important imaging modality in this regard. The re-staging of bladder cancer still constitutes a challenge using conventional techniques such as ultrasonography (US), computed tomography (CT), magnetic resonance imaging (MRI) and bone scintigraphy, with success rates approximately 70 percent in literature[8]. It has been proposed that ^{18}F FDG-PET/CT can provide additional diagnostic knowledge in the clinical management of bladder cancer[9]. We used the GC-based chemotherapy protocol described by European Association of Urology (EAU) in our patients, and the ^{18}F FDG-PET/CT findings from before and after treatment were recorded[10].

The purpose of the present study was to examine retrospectively the contribution of ^{18}F FDG-PET/CT to the evaluation of response to first-line gemcitabine plus cisplatin-based chemotherapy in patients with metastatic bladder cancer. An accurate primary staging of the disease is particularly important for the planning of second-line chemotherapy protocols and the determination of complete and incomplete response at this stage of the disease. The histological findings or the clinical and radiological workup (US, CT, MRI and bone scintigraphy) were used as a standard reference. There are a few number of studies in literature evaluating ^{18}F FDG-PET/CT in the detection of residual disease and the evaluation of response to therapy after GC-based chemotherapy in patients with metastatic bladder carcinoma.

MATERIALS AND METHODS

A total 10553 ^{18}F FDG-PET/CT scans were performed in the Nuclear Medicine Department of Sifa University and Tinaztepe University, Izmir, Turkey between July 2007 and April 2019. In this group of patients, 79 patients underwent ^{18}F FDG-PET/CT because of metastatic bladder cancer. The PET/CT findings of 42 patients before and after first-line chemotherapy were recorded.

Table 1 Characteristics of patients and disease

Characteristics	No. %
Gender	
Male	38 (90.4)
Female	4 (9.6)
Age (yr)	
Median	66.1
Range	41-84
Primary site	4 (9.6)
Bladder	38 (90.4)
Bladder, ureter, renal pelvis	4 (9.6)
Site of metastasis	
Lymph node	65 (53.2)
Bone	30 (24.6)
Lung	26 (21.3)
Liver	10 (8.1)
Soft tissue	10 (8.1)
Other ¹	3 (2.4)

¹Adrenal gland, penile.

Thirty-eight (90.4%) of these patients were male and 4 (9.6%) were female. Mean age was 66.1 years and standard deviation was 10.7 years (range: 41–84 years). Written informed consents was obtained from all patients.

All (100%) patients had data on histological sub-types of muscle-invasive bladder cancer (high-grade TCC) based on pathological investigations. In the patients, the primary tumor was confined within the bladder in 38 (90.4%) of the patients, whereas four patients (9.6%) had bladder tumors and concomitant upper tract urothelial carcinoma (UTUC). Baseline characteristics of the patients are summarized in [Table 1](#).

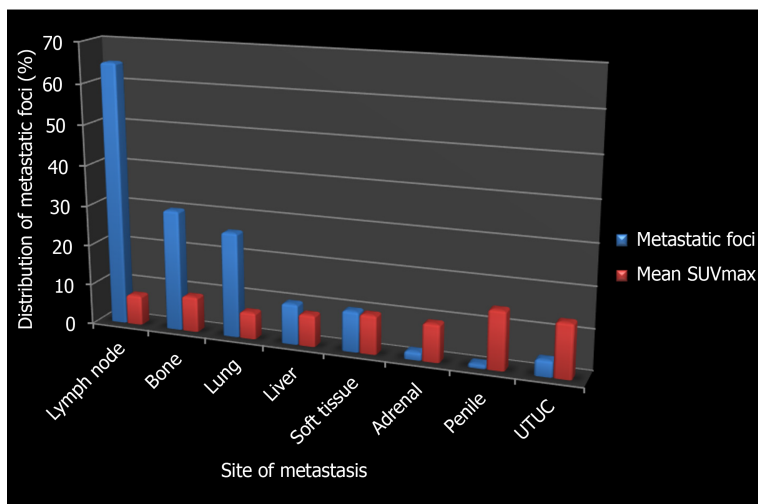
Imaging and interpretation of data

370 MBq of ¹⁸F FDG injected intravenously after at least six hours of fasting and when blood glucose level was lower than 200 mg/dL. One hour after ¹⁸F FDG injection, a total body CT scan without IV contrast agent and whole-body 3D PET acquisition with 8 bed positions of 3 min of emission scan time, covering the area from the vertex to the proximal thigh, each using a dedicated PET/CT scanner (HI-REZ Biograph 16, SIEMENS) which provides an in-plane spatial resolution of 4.8 mm, an axial field view of 16.2 cm. The PET data were reconstructed using a Gaussian filter with an ordered-subset expectation maximization algorithm (3 iterations, 8 subsets), re-oriented in transverse, coronal and sagittal planes.

PET scans were analyzed visually and semi-quantitatively using SUV_{max} measurement. One experienced nuclear medicine expert reviewed blindly and independently the FDG PET/CT scans regardless of as positive or negative for a primary tumour site. It was thought that ingestion of any radioactive substance that deviated from the physiological distribution was in favor of the spread of the disease.

RESULTS

A total of 144 metastatic foci in 42 patients with metastatic bladder carcinoma were evaluated using ¹⁸F-DG-PET/CT before chemotherapy, which 65 (53.2%) foci of lymph node's metastasis (mean SUV_{max}: 7.4), 30 (24.6%) foci of bone's metastasis (mean SUV_{max}: 8.8), 26 (21.3%) foci of lung's metastasis (mean SUV_{max}: 6.6), 10 (8.1%) foci of liver's metastasis (mean SUV_{max}: 7.8), 10 (8.1%) foci of soft tissue's metastasis (mean SUV_{max}: 9.6), two (1.6%) foci of adrenal's metastasis (mean SUV_{max}: 9.3) and one (0.8%) foci of penile's metastasis (SUV_{max}: 14.4) were detected. Additionally, four (3.2%) foci of concomitant UTUC were also detected (mean SUV_{max}: 13.3). The distribution of metastatic foci and mean SUV_{max} are summarized in [Figure 1](#). The patients underwent second ¹⁸F-DG-PET/CT scan after gemcitabine plus cisplatin-based chemotherapy to allow an evaluation of response to chemotherapy. The mean time interval between the two ¹⁸F-DG-PET/CT scans was 6 months (range: 3–14 mo), and the same chemotherapy protocol was used in all patients during this period. Responses to chemotherapy were evaluated using the criteria of the European Organisation for the Research and



DOI: 10.12998/wjcc.v11.i36.8447 Copyright ©The Author(s) 2023.

Figure 1 Distribution of metastatic foci and mean SUV_{max} . SUV: Standardised uptake value.

treatment of cancer (EORTC), which it was found that seven patients (16.6%) were in complete remission, 17 (40.5%) were in partial remission, 6 (14.3%) had a stable disease and 12 (28.6%) had a progressive disease (Figure 2). The overall response rate (ORR) was 57.1%.

DISCUSSION

Recurrent and metastatic bladder TCC has a poor prognosis. An accurate re-staging is crucial for the justification of additional toxic and expensive therapy. There is still only limited data on the benefits of ^{18}F FDG-PET/CT in the identification of recurrences and new metastases after first-line chemotherapy for metastatic bladder cancer, and evaluating responses to therapy in cancer patients is still just as challenging as before. The reason for this is that; with current imaging techniques it is not possible to detect with absolute accuracy after chemotherapy to what extent of metastatic focus has been affected by the chemotherapeutics. In 1976, Moertel and Hanley reported that a decrease of 50 percent or more in tumor size must be regarded as a complete response to chemotherapy, which was accepted by world health organization in 1979[11]. Evaluation of response to chemotherapy based solely on anatomic criteria was added to the response evaluation criteria in solid tumors (RECIST) criteria in 2000, in which a decrease < 30 percent or an increase of < 20 percent was defined as a response to chemotherapy, although the RECIST criteria have undergone two modifications since then, one in 2009 and the other in 2010[12]. False negative results caused by the use of anatomic criteria in evaluating response to chemotherapy have resulted in the incorporation of functional/metabolic criteria into the assessment. The EORTC criteria were published in 2009, followed by the PET Response Criteria in Solid Tumors criteria in 2009 [12]. The present study has been conducted based on the EORTC criteria, which are summarized in Table 2.

High uptake of FDG in cancerous lesions of the transitional carcinoma was first demonstrated by Harney *et al*[13] in rats. Drieskens *et al*[14] found that metabolism-based anatomical information gathered by the addition of FDG-PET to CT provided high diagnostic accuracy in pre-operative staging of invasive transitional cancers particularly invasive bladder carcinoma. Nowadays, FDG-positron emission tomography combined with computed tomography (FDG-PET/CT) is an established standard for pre-operative staging and detecting metastatic lesions of bladder cancer[15-17].

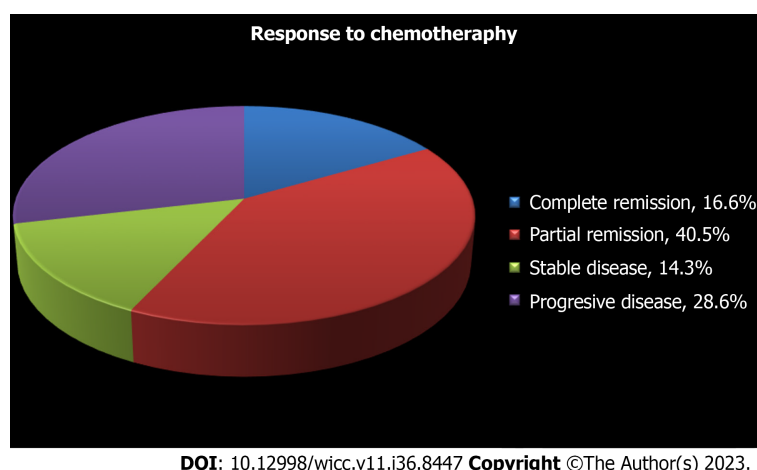
The accumulation of FDG in metastatic cells is closely related to such transport proteins as GLUT-1 and hexokinase enzyme activities. However, P-glycoprotein (MDR-1) expression, metallothionein over-expression, altered p53 expression MRP (multi-drug resistance-associated protein) mRNA induction and epidermal growth factor receptor over-expression in metastatic bladder cancer are all considered to be potential predictors of response to chemotherapy[18]. Accordingly, FDG accumulation and response to chemotherapy cannot be evaluated only with GLUT-1 and hexokinase enzyme activities in tumor cells without elucidating the molecular biologic basis of the disease, and so it is obvious that this area requires further research (Figure 3).

Why is therapy planning in cases of metastatic bladder cancer using ^{18}F FDG-PET/CT imaging so important? What contribution does ^{18}F FDG-PET/CT make in decisions to continue with second-line chemotherapy after initial chemotherapy treatment? Figure 4 shows the metabolic activity of cancer before an anatomic visualization of the tumor as a general rule, applicable for all cancers, and this stage is extremely important in diagnosis, staging, targeted therapy and the planning of radiotherapy. In order to spare the patient from additional toxic therapies, the detection of occult metastases and the evaluation of response to chemotherapy are only possible if there is a thorough understanding of the molecular/functional findings. This figure outlines the importance of molecular imaging, and the represented data is particularly important in the planning of treatments.

Table 2 Response criteria as defined by response evaluation criteria in solid tumors, world health organization, and the research and treatment of cancer

	RECIST	WHO	EORTC
Complete remission	Disappearance of all disease	Disappearance of all disease	Complete resolution of FDG uptake within the tumor volume
Partial remission	Decrease $\geq 30\%$ in the sum of the greatest dimension of all measurable disease	Decrease $\geq 50\%$ in the sum of the cross products	A reduction of a minimum of 15%-25% in tumor FDG SUV after one cycle of chemotherapy, and greater than 25% after more than one treatment cycle
Stable disease	Decrease $< 30\%$ and increase $< 20\%$ in the sum of the greatest tumor dimensions	Decrease $< 50\%$ and increase $< 20\%$ in the sum of the cross products	Increase of less than 25% or a decrease of less than 15% in tumor FDG SUV and no visible increase in extent (20% in the longest dimension)
Progressive disease	Increase $\geq 20\%$ in the sum of the greatest tumor dimensions	Increase $\geq 50\%$ in the sum of the cross products	Increase in FDG tumor SUV of greater than 25% within the tumor region, or increase of extent of FDG uptake (20% in the longest direction) or appearance of new lesions

RECIST: Response evaluation criteria in solid tumors; WHO: World health organization; EORTC: Research and treatment of cancer; FDG: F-2-fluoro-2-deoxyglucose; SUV: Standardised uptake value.

**Figure 2** Rate of response to chemotherapy.

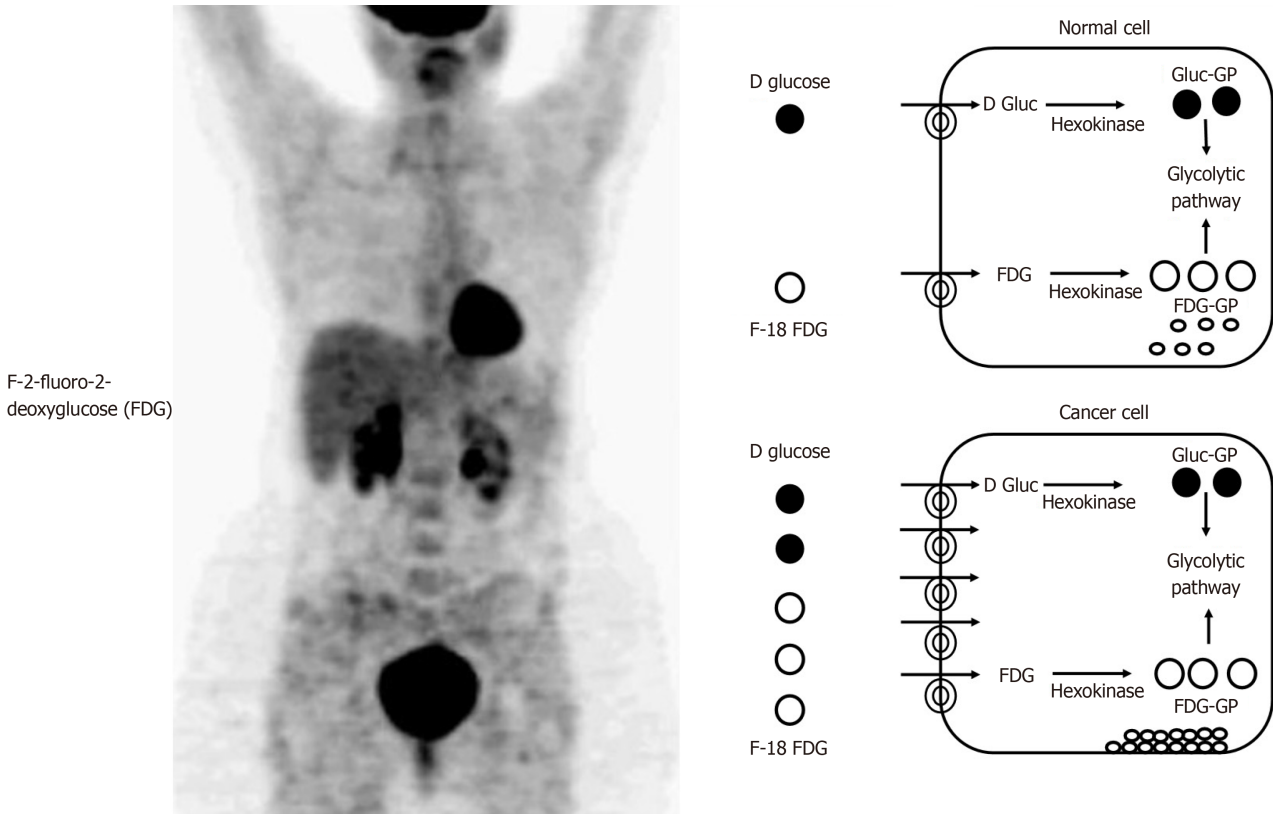
Recent Studies suggest that solid organ metastasis from bladder cancer, particularly metastasis to the liver, is an independent risk factor resulting from poor prognosis. There is a correlation between the Karnowsky score and disease specific survival, and so the detection of solid organ and occult metastases with high accuracy and the detection of residual active disease after therapy using ¹⁸F-DG-PET/CT contribute significantly to survival figures.

Bladder TCC are chemosensitive tumors. In metastatic disease, chemotherapy is the only therapeutic option. Imaging studies of metastatic urogenital malignancies are the main part of initial staging, response assessment and follow-up after systemic therapy. In particular, the clinically important question of the most accurate method to monitor therapeutic response during cytotoxic therapy or treatment with molecular approaches has been much neglected[19]. The mean ORR for metastatic bladder cancer after GC-based chemotherapy ranges between 40 and 70 percent in literature, and similar rates were reported by Bellmunt *et al*[20] in a study of 637 patients in 2007 and by Bamias *et al*[21] in a study of 175 patients in 2011. The mean ORR was 57.1 percent in the present study, which falls within the range of values in literature. Second or third-line chemotherapy is used in cases where the disease proves to be resistant to cisplatin-based chemotherapy; although there is no consensus on this issue[22]. In a recent published case study, the authors obtained a CR with FOLFOX4 chemotherapy in a metastatic urothelial cancer patient, after failure of GC combination[23]. As shown in Table 3, a precise re-staging is pivotal in the planning of second and third-line chemotherapy.

Metastasis may also appear in normal-sized lymph nodes. In bladder cancer, primary lymphatic drainage is to the internal iliac, common iliac and retroperitoneal lymph nodes. Therefore, metastasis occurs in these areas. Conventional CT is wrong 30% of the time. Conventional CT is wrong 30% of the time[24]. The functional and metabolic datas of PET/CT provide both accurate staging and evaluating of response to therapy higher sensitivity. In a population-based study in 2023, Patients with muscle-invasive bladder carcinoma (MIBC) who underwent pre-treatment staging with FDG-PET/CT were more often staged as lymph node positive, regardless of cT stage[25]. In a recent study by Voskuilen *et al*[26], FDG-PET/CT provides important incremental staging information, which potentially influences clinical management in 18% of MIBC patients, but leads to false positive results as well. In a study by Lodde *et al*[27], ¹⁸F-DG-PET/CT provided 100 percent PVV and specificity, compared to CT (33% *vs* 57%) in the detection of lymph node metastases, indicating the

Table 3 Treatment recommendations in metastatic baldder carcinoma			
First line treatment		Second and third line treatments	
Patients eligible to cisplatin	Unfit patients	Cisplatin sensitive disease	Cisplatin refractory disease
MVAC, HD-MVAC, GC, and DD-GC	GCa and MCAVI	Cisplatin based doublet not used in first line	Vinflunine, Paclitaxel-gemcitabine, and all actives drugs not used

MVAC: Methotrexate-vinblastine-doxorubicin-cisplatin; HD: High dose; GC: Gemcitabin-cisplatin; DD: Dose dense; MCAVI: Methotrexate-carboplatin-vinblastine; GCa: Gemcitabine plus carboplatin;



DOI: 10.12998/wjcc.v11.i36.8447 Copyright ©The Author(s) 2023.

Figure 3 Illustrates the metabolic relationship between F-2-fluoro-2-deoxyglucose and cancer cells. D-glucose: The d-isomer of Glucose is d-glucose; Gluc-GP: Glucose- Glycogen phosphorylase (GP); FDG-GP: F-2-fluoro-2-deoxyglucose - Glycogen phosphorylase (GP); FDG: F-2-fluoro-2-deoxyglucose.

superiority of ¹⁸FDG-PET/CT over standard CT in detecting lymph node metastasis. In a study by Taguchi *et al*[28], found that liver metastases represented the highest risk to survival when compared to other metastates. In their study, all liver metastases died within 9.3 months of diagnosis after being unresponsive to chemotherapy. This and other studies in literature suggest that the precise recognition of metastases is vitally important in predicting survival, evaluating response to chemotherapy and determining the most appropriate therapy.

Precise evaluations of metastases after chemotherapy are also particularly important. In a study by Lehmann *et al*[29] of 44 patients, a 28 percent five-year survival rate was reported in patients with metastatic bladder carcinoma. Furthermore, in a recent study conducted in 2014, Mertens *et al*[30] evaluated the relationship between ¹⁸FDG-PET/CT results and mortality in patients with MIBC (*n* = 211), in which the median follow-up period was 18 mo. Disease-specific survival was 50 mo in the PET-negative patients, and this rate decreased to 16 mo in the PET-positive patients. The presence of extravesical disease was found to be an independent prognostic factor in mortality in PET-positive patients.

Kibel *et al*[17] studied 43 patients with T2-3N0M0 stage urothelial cancer and reported a sensitivity of 70 percent, specificity of 94 percent, a positive predictive value of 78 percent and negative predictive value of 91 percent for ¹⁸FDG PET/CT. They found occult metastatic disease in 7 of 42 patients, and concluded that pre-operative ¹⁸FDG-PET/CT may affect decisions related to treatment prior to a radical cystectomy. The same study also evaluated the relationship between PET findings and survival, finding a rate of 24-mo recurrence-free survival of 24 percent in patients with positive PET findings and 55 percent in patients with negative PET findings. Drieskens *et al*[14] provided valuable data on the prognosis of patients showing a longer median survival rate after negative results from a PET examination compared to patients with positive results for bladder cancer.

Table 4 Diagnostic performance of ^{18}F Fluorodeoxyglucose positron emission tomography computed tomography studies in the literature

Ref.	Modality	n	Status of the BCa	Sensitivity, %	Specifity, %
Drieskens <i>et al</i> [14]	FDG-PET/CT	55	Metastatic BCa	60	88
Apolo <i>et al</i> [16]	FDG-PET/CT	47	Metastatic BCa	88	87
Liu <i>et al</i> [33]	FDG-PET/CT	55	Metastatic BCa	77	97
Lu <i>et al</i> [15]	FDG-PET/CT	-	Metastatic BCa	89	82

Average values from meta-analysis of 4 individual positron emission tomography/computed tomography studies. BCa: Bladder cancer; FDG-PET/CT: Fluorodeoxyglucose positron emission tomography computed tomography.

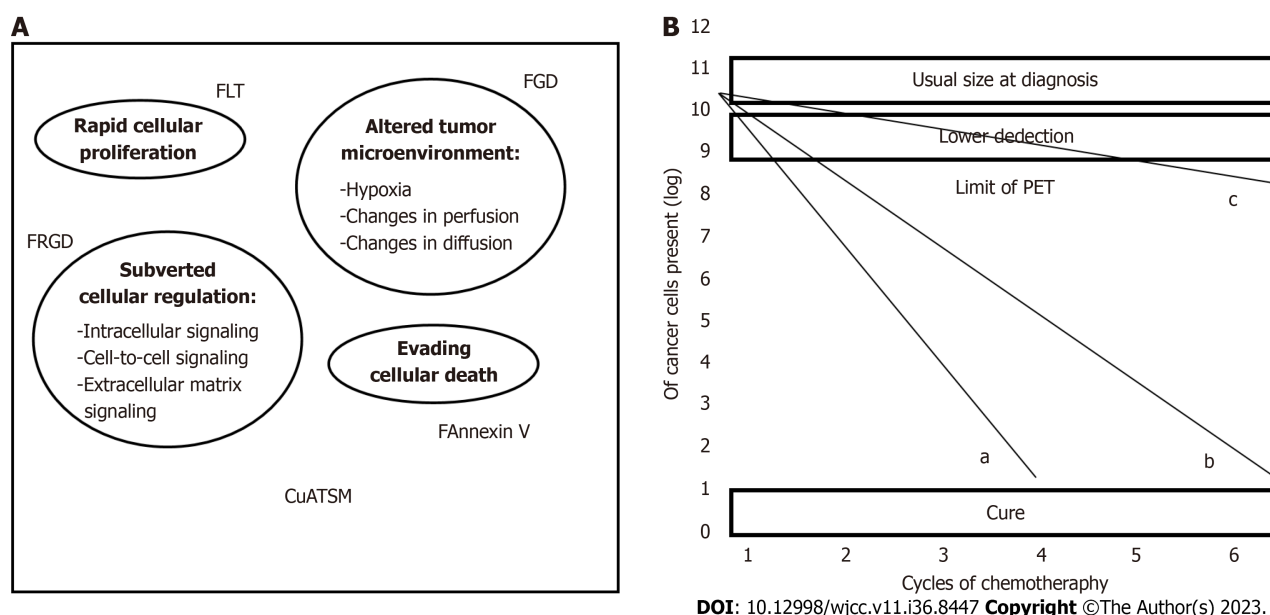


Figure 5 Shows the relationship between F-2-fluoro-2-deoxyglucose and tumor cells. A: Molecular imaging targets in oncology; B: Relationship between the death of tumor cells – number of viable tumor cells and F-2-fluoro-2-deoxyglucose positron emission tomography. FDG: Fluorodeoxyglucose; FLT1: Fms-related tyrosine kinase 1; FRGD: frgD gene; F Annexin V: ^{18}F using N-succinimidyl-4- ^{18}F -fluorobenzoic acid; Cu-ATSM: Copper(II)-diacetyl-bis(N(4)-methylthiosemicarbazone).

malignant cells (2 logarithms). After therapy, negative findings from ^{18}F FDG-PET/CT imply a lack of cancer cells or a lack of lesions harboring more than 10^7 cells. FDG-PET/CT cannot differentiate between a minimal tumor load and the lack of a tumor; however, a completely negative PET/CT scan after post-therapy indicates a good prognosis, while positive findings in PET/CT indicate the presence of a residual tumor (in the absence of inflammation). **Figure 5** shows the relationship between FDG and tumor cells.

Limitations

Disease-specific limitations: The lack of information on why known active TCC cells fail to uptake FDG as to become visible on the detector, negative predictive which has not yet reached 100%, and the lack of data on a sufficient number of patients in literature can be regarded as disease-specific limitations.

Technical limitations: Diagnostic failures in ^{18}F FDG-PET/CT are associated mostly with the lungs and liver, as PET technologies may fail to identify small lung metastases measuring less than 5 mm, even when used in conjunction with CT in the correction of anatomical location and attenuation. It is unclear if this observation of a decline in sensitivity is caused by pulmonary motion artifacts or by the low metabolic activity of the lung metastases. Respiratory gate and time-of-flight technologies might help detect motion artifacts and improve diagnostic correctness by reducing the smearing effect, and may provide a good spatial resolution, offering higher accuracy and more precise calculation of SUV[37].

Study limitations: The retrospective design of the study, the relatively small number of patients and the lack of histological correlation can be regarded as the limitations of the study.

CONCLUSION

¹⁸FDG-PET/CT seems to be a considerably successful and applicable diagnostic tool in the evaluation of response to therapy after first-line chemotherapy for metastatic bladder cancer. The addition of metabolic/functional data to the anatomical findings may allow greater accuracy in the diagnosis. The re-staging of the disease is of particular importance in the planning of second- and third-line chemotherapy protocols, as all possible additional chemotherapy protocols will increase morbidity and mortality in a patient with impaired performance status after having undergone first-line chemotherapy. It is suggested that the presented method will allow a better explanation of the requirement for additional chemotherapy protocols to both the patient and their relatives, although further studies are required in order to standardize additional therapy protocols.

ARTICLE HIGHLIGHTS

Research perspectives

More sensitive scanning methods are needed such as positron emission tomography (PET)/magnetic resonance imaging (MRI), metabolic-based imaging.

Research conclusions

Use PET/computed tomography (CT) more for accurate staging regardless of whether fluorodeoxyglucose (FDG) is excreted from the urinary tract. PET/CT can be standard in muscle-invasive bladder carcinoma

Research results

Restaging with high accuracy can protect patients from secondary or even tertiary chemotherapy. Of the patients, seven (16.6%) were in complete remission, 17 (40.5%) were in partial remission, six (14.3%) had a stable disease, and 12 (28.6%) had a progressive disease. The overall response rate was 57.1 percent. Imaging techniques that detect every behavior of the tumor will increase the success of future treatment. This study is an example of this. In fact, PET-MRI may become the standard instead of PET/CT in the future. Their contributions to the overall research in this field, and the problems that remain to be solved; There is still only limited data on the benefits of ¹⁸Fluorodeoxyglucose positron emission tomography computed tomography (¹⁸FDG PET/CT) in the identification of recurrences and new metastases after first-line chemotherapy for metastatic bladder cancer, and evaluating responses to therapy in cancer patients is still just as challenging as before. The reason for this is that; with current imaging techniques it is not possible to detect with absolute accuracy after chemotherapy to what extent of metastatic focus has been affected by the chemotherapeutics.

Research methods

The research method is data analysis.

Research objectives

To contribute to the literature in this field. We believe that, this study will guide in the future. We see that data pool is being increased in this field.

Research motivation

Urooncology and Nuclear Medicine departments study as multidisciplinary. Scientific data is discussed in the council and outputs are produced.

Research background

The purpose of the present study was to examine retrospectively the contribution of ¹⁸FDG-PET/CT to the evaluation of response to first-line gemcitabine plus cisplatin-based chemotherapy in patients with metastatic bladder cancer. An accurate primary staging of the disease is particularly important for the planning of second-line chemotherapy protocols and the determination of complete and incomplete response at this stage of the disease.

FOOTNOTES

Author contributions: Öztürk H participated in the design of the study and performed the statistical analysis; Karapolat İ carried out the nuclear medicine studies; Öztürk H and Karapolat İ drafted the manuscript; Öztürk H conceived the study, and participated in its design and coordination; all authors read and approved the final manuscript.

Institutional review board statement: There is no need approval. The research method is data analysis.

Informed consent statement: All procedures followed were in accordance with the ethical standards of the responsible committee on human experimentation and with the Helsinki Declaration of 1975, as revised in 2000. Informed consent was obtained from all patients for being included in the study. Additional information consent was obtained from all patients for which identifying information is

included in this article.

Conflict-of-interest statement: All the authors declare that they have no competing interests. Financial support has not been received.

Data sharing statement: No additional data are available.

Open-Access: This article is an open-access article that was selected by an in-house editor and fully peer-reviewed by external reviewers. It is distributed in accordance with the Creative Commons Attribution NonCommercial (CC BY-NC 4.0) license, which permits others to distribute, remix, adapt, build upon this work non-commercially, and license their derivative works on different terms, provided the original work is properly cited and the use is non-commercial. See: <https://creativecommons.org/licenses/by-nc/4.0/>

Country/Territory of origin: Turkey

ORCID number: Hakan Öztürk 0000-0002-4962-7707.

S-Editor: Liu JH

L-Editor: A

P-Editor: Xu ZH

REFERENCES

- Ploeg M, Aben KK, Kiemeny LA. The present and future burden of urinary bladder cancer in the world. *World J Urol* 2009; **27**: 289-293 [PMID: 19219610 DOI: 10.1007/s00345-009-0383-3]
- Abdollah F, Gandaglia G, Thuret R, Schmitges J, Tian Z, Jeldres C, Passoni NM, Briganti A, Shariat SF, Perrotte P, Montorsi F, Karakiewicz PI, Sun M. Incidence, survival and mortality rates of stage-specific bladder cancer in United States: a trend analysis. *Cancer Epidemiol* 2013; **37**: 219-225 [PMID: 23485480 DOI: 10.1016/j.canep.2013.02.002]
- Stein JP, Skinner DG. Radical cystectomy for invasive bladder cancer: long-term results of a standard procedure. *World J Urol* 2006; **24**: 296-304 [PMID: 16518661 DOI: 10.1007/s00345-006-0061-7]
- Rosenberg JE, Carroll PR, Small EJ. Update on chemotherapy for advanced bladder cancer. *J Urol* 2005; **174**: 14-20 [PMID: 15947569 DOI: 10.1097/01.ju.0000162039.38023.5f]
- Sengeløv L, Kamby C, von der Maase H. Metastatic urothelial cancer: evaluation of prognostic factors and change in prognosis during the last twenty years. *Eur Urol* 2001; **39**: 634-642 [PMID: 11464051 DOI: 10.1159/000052520]
- Sternberg CN, Yagoda A, Scher HI, Watson RC, Ahmed T, Weiselberg LR, Geller N, Hollander PS, Herr HW, Sogani PC. Preliminary results of M-VAC (methotrexate, vinblastine, doxorubicin and cisplatin) for transitional cell carcinoma of the urothelium. *J Urol* 1985; **133**: 403-407 [PMID: 4038749 DOI: 10.1016/S0022-5347(17)48996-8]
- Bellmunt J, Albiol S, de Olano AR, Pujadas J, Maroto P; Spanish Oncology Genitourinary Group (SOGUG). Gemcitabine in the treatment of advanced transitional cell carcinoma of the urothelium. *Ann Oncol* 2006; **17** Suppl 5: v113-v117 [PMID: 16807437 DOI: 10.1093/annonc/mdj964]
- Sternberg CN, Pansadoro V, Calabrò F, Schnetzer S, Giannarelli D, Emiliozzi P, De Paula F, Scarpone P, De Carli P, Pizzo M, Platania A, Amini M. Can patient selection for bladder preservation be based on response to chemotherapy? *Cancer* 2003; **97**: 1644-1652 [PMID: 12655521 DOI: 10.1002/cncr.11232]
- Bouchelouche K, Turkbey B, Choyke PL. PET/CT and MRI in Bladder Cancer. *J Cancer Sci Ther* 2012; **S14** [PMID: 23471167 DOI: 10.4172/1948-5956.S14-001]
- Stenzl A, Cowan NC, De Santis M, Jakse G, Kuczyk MA, Merseburger AS, Ribal MJ, Sherif A, Witjes JA. The updated EAU guidelines on muscle-invasive and metastatic bladder cancer. *Eur Urol* 2009; **55**: 815-825 [PMID: 19157687 DOI: 10.1016/j.eururo.2009.01.002]
- Moertel CG, Hanley JA. The effect of measuring error on the results of therapeutic trials in advanced cancer. *Cancer* 1976; **38**: 388-394 [PMID: 947531 DOI: 10.1002/1097-0142(197607)38:1<388::AID-CNCR2820380156>3.0.CO;2-A]
- Öztürk H. Comparing RECIST with EORTC criteria in metastatic bladder cancer. *J Cancer Res Clin Oncol* 2016; **142**: 187-194 [PMID: 26208817 DOI: 10.1007/s00432-015-2022-2]
- Harney JV, Wahl RL, Liebert M, Kuhl DE, Hutchins GD, Wedemeyer G, Grossman HB. Uptake of 2-deoxy, 2-(18F) fluoro-D-glucose in bladder cancer: animal localization and initial patient positron emission tomography. *J Urol* 1991; **145**: 279-283 [PMID: 1988718 DOI: 10.1016/S0022-5347(17)38314-3]
- Drieskens O, Oyen R, Van Poppel H, Vankan Y, Flamen P, Mortelmans L. FDG-PET for preoperative staging of bladder cancer. *Eur J Nucl Med Mol Imaging* 2005; **32**: 1412-1417 [PMID: 16133380 DOI: 10.1007/s00259-005-1886-9]
- Lu YY, Chen JH, Liang HY, Lin CC, Lin WY, Kao CH. Clinical value of FDG PET or PET/CT in urinary bladder cancer: a systemic review and meta-analysis. *Eur J Radiol* 2012; **81**: 2411-2416 [PMID: 21899971 DOI: 10.1016/j.ejrad.2011.07.018]
- Apolo AB, Riches J, Schöder H, Akin O, Trout A, Milowsky MI, Bajorin DF. Clinical value of fluorine-18 2-fluoro-2-deoxy-D-glucose positron emission tomography/computed tomography in bladder cancer. *J Clin Oncol* 2010; **28**: 3973-3978 [PMID: 20679618 DOI: 10.1200/JCO.2010.28.7052]
- Kibel AS, Dehdashti F, Katz MD, Klim AP, Grubb RL, Humphrey PA, Siegel C, Cao D, Gao F, Siegel BA. Prospective study of [18F]fluorodeoxyglucose positron emission tomography/computed tomography for staging of muscle-invasive bladder carcinoma. *J Clin Oncol* 2009; **27**: 4314-4320 [PMID: 19652070 DOI: 10.1200/JCO.2008.20.6722]
- Bellmunt J, Choueiri TK, Fougeray R, Schutz FA, Salhi Y, Winquist E, Culine S, von der Maase H, Vaughn DJ, Rosenberg JE. Prognostic factors in patients with advanced transitional cell carcinoma of the urothelial tract experiencing treatment failure with platinum-containing regimens. *J Clin Oncol* 2010; **28**: 1850-1855 [PMID: 20231682 DOI: 10.1200/JCO.2009.25.4599]
- Heidenreich A, Albers P, Classen J, Graefen M, Gschwend J, Kotzerke J, Kroke S, Lehmann J, Rohde D, Schmidberger H, Uder M, Zeeb H;

Association of Urologic Oncology of the German Cancer Society. Imaging studies in metastatic urogenital cancer patients undergoing systemic therapy: recommendations of a multidisciplinary consensus meeting of the Association of Urological Oncology of the German Cancer Society. *Urol Int* 2010; **85**: 1-10 [PMID: 20693823 DOI: 10.1159/000318985]

- 20 **Bellmunt J**, von der Maase H, Mead GM, Heyer J, Houede N, Paz-Ares LG, Winquist E, Laufman LR, de Wit R, Sylvester R. Randomized phase III study comparing paclitaxel/cisplatin/ gemcitabine (PCG) and gemcitabine/cisplatin (GC) in patients with locally advanced (LA) or metastatic (M) urothelial cancer without prior systemic therapy; EORTC30987/Intergroup Study. *J Clin Oncol* 2007 [DOI: 10.1200/jco.2007.25.18_suppl.lba5030]
- 21 **Bamias A**, Karadimou A, Lampaki S, Aravantinos G, Xanthakis I, Papandreou C, Lainakis G, Zagouri F, Soupos N, Kostouros E, Samantas E, Hatzimouratidis C, Konstantinidis C, Deliveliotis C, Pectasides DG, Fountzilas G, Dimopoulos MA; Hellenic Cooperative Oncology Group. Hellenic Cooperative Oncology Group (HeCOG), Athens, Greece. Prospective, randomized phase III study comparing two intensified regimens (methotrexate/vinblastine/doxorubicin hydrochloride/cisplatin [MVAC] vs gemcitabine/cisplatin) in patients with inoperable or recurrent urothelial cancer. *J Clin Oncol* 2011; **29** [DOI: 10.1200/jco.2011.29.15_suppl.4510]
- 22 **Ismaili N**, Amzerin M, Flechon A. Chemotherapy in advanced bladder cancer: current status and future. *J Hematol Oncol* 2011; **4**: 35 [PMID: 21906310 DOI: 10.1186/1756-8722-4-35]
- 23 **Seo YR**, Kim SH, Kim HJ, Kim CK, Park SK, Koh ES, Hong DS. Complete response to FOLFOX4 therapy in a patient with advanced urothelial cancer: a case report. *J Hematol Oncol* 2010; **3**: 4 [PMID: 20089186 DOI: 10.1186/1756-8722-3-4]
- 24 **Morisawa N**, Koyama T, Togashi K. Metastatic lymph nodes in urogenital cancers: contribution of imaging findings. *Abdom Imaging* 2006; **31**: 620-629 [PMID: 17131207 DOI: 10.1007/s00261-005-0244-5]
- 25 **Richters A**, van Ginkel N, Meijer RP, Wondergem M, Schoots I, Vis AN, Kiemeny LALM, van Rhijn BWG, Witjes JA, Aben KKH, Mertens LS. Staging fluorodeoxyglucose positron emission tomography/computed tomography for muscle-invasive bladder cancer: a nationwide population-based study. *BJU Int* 2023; **132**: 420-427 [PMID: 37246479 DOI: 10.1111/bju.16091]
- 26 **Voskuilen CS**, van Gennep EJ, Einerhand SMH, Vegt E, Donswijk ML, Bruining A, van der Poel HG, Horenblas S, Hendricksen K, van Rhijn BWG, Mertens LS. Staging (18)F-fluorodeoxyglucose Positron Emission Tomography/Computed Tomography Changes Treatment Recommendation in Invasive Bladder Cancer. *Eur Urol Oncol* 2022; **5**: 366-369 [PMID: 33583752 DOI: 10.1016/j.euo.2021.01.005]
- 27 **Lodde M**, Lacombe L, Friede J, Morin F, Saourine A, Fradet Y. Evaluation of fluorodeoxyglucose positron-emission tomography with computed tomography for staging of urothelial carcinoma. *BJU Int* 2010; **106**: 658-663 [PMID: 20151968 DOI: 10.1111/j.1464-410X.2010.09212.x]
- 28 **Taguchi S**, Nakagawa T, Hattori M, Niimi A, Nagata M, Kawai T, Fukuhara H, Nishimatsu H, Ishikawa A, Kume H, Homma Y. Prognostic factors for metastatic urothelial carcinoma undergoing cisplatin-based salvage chemotherapy. *Jpn J Clin Oncol* 2013; **43**: 923-928 [PMID: 23888082 DOI: 10.1093/jco/hyt096]
- 29 **Lehmann J**, Suttman H, Albers P, Volkmer B, Gschwend JE, Fechner G, Spahn M, Heidenreich A, Odenthal A, Seif C, Nürnberg N, Wülfing C, Greb C, Kälble T, Grimm MO, Fieseler CF, Kroke S, Retz M, Schulte-Baukloh H, Gerber M, Hack M, Kamradt J, Stöckle M. Surgery for metastatic urothelial carcinoma with curative intent: the German experience (AUO AB 30/05). *Eur Urol* 2009; **55**: 1293-1299 [PMID: 19058907 DOI: 10.1016/j.eururo.2008.11.039]
- 30 **Mertens LS**, Mir MC, Scott AM, Lee ST, Fioole-Bruining A, Vegt E, Vogel WV, Manecksha R, Bolton D, Davis ID, Horenblas S, van Rhijn BW, Lawrentschuk N. 18F-fluorodeoxyglucose-positron emission tomography/computed tomography aids staging and predicts mortality in patients with muscle-invasive bladder cancer. *Urology* 2014; **83**: 393-398 [PMID: 24468513 DOI: 10.1016/j.urology.2013.10.032]
- 31 **Herr HW**, Donat SM, Bajorin DF. Bladder cancer, the limits of surgical excision-when/how much? *Urol Oncol* 2001; **6**: 221-224 [DOI: 10.1016/S1078-1439(01)00143-0]
- 32 **Herr HW**. Is metastasectomy for urothelial carcinoma worthwhile? *Eur Urol* 2009; **55**: 1300-1301 [PMID: 19124189 DOI: 10.1016/j.eururo.2008.12.011]
- 33 **Liu JJ**, Lai YH, Espiritu JJ, Segall GM, Srinivas S, Nino-Murcia M, Terris MK. Evaluation of fluorodeoxyglucose positron emission tomography imaging in metastatic transitional cell carcinoma with and without prior chemotherapy. *Urol Int* 2006; **77**: 69-75 [PMID: 16825819 DOI: 10.1159/000092937]
- 34 **van Ginkel N**, van Gennep EJ, Oosterbaan L, Greidanus J, Boellaard TN, Wondergem M, Vis AN, de Reijke TM, van Rhijn BWG, Mertens LS. Added Clinical Value of (18)F-FDG-PET/CT to Stage Patients With High-Risk Non-Muscle Invasive Bladder Cancer Before Radical Cystectomy. *Clin Genitourin Cancer* 2023; **21**: 342-348 [PMID: 36918302 DOI: 10.1016/j.clgc.2023.02.004]
- 35 **Moussa M**, Chakra MA, Saad W, Dellis A, Papatsoris A. The role of 18F-FDG PET/CT scan compared to CT-scan alone for lymph node staging before radical cystectomy in patients with bladder cancer. *Urol Oncol* 2021; **39**: 833.e9-833.e17 [PMID: 34059435 DOI: 10.1016/j.urolonc.2021.04.027]
- 36 **Jadvar H**, Quan V, Henderson RW, Conti PS. [F-18]-Fluorodeoxyglucose PET and PET-CT in diagnostic imaging evaluation of locally recurrent and metastatic bladder transitional cell carcinoma. *Int J Clin Oncol* 2008; **13**: 42-47 [PMID: 18307018 DOI: 10.1007/s10147-007-0720-8]
- 37 **El Fakhri G**, Surti S, Trott CM, Scheuermann J, Karp JS. Improvement in lesion detection with whole-body oncologic time-of-flight PET. *J Nucl Med* 2011; **52**: 347-353 [PMID: 21321265 DOI: 10.2967/jnumed.110.080382]



Published by **Baishideng Publishing Group Inc**
7041 Koll Center Parkway, Suite 160, Pleasanton, CA 94566, USA

Telephone: +1-925-3991568

E-mail: bpgoffice@wjgnet.com

Help Desk: <https://www.f6publishing.com/helpdesk>

<https://www.wjgnet.com>

