

World Journal of *Clinical Cases*

World J Clin Cases 2023 December 26; 11(36): 8434-8605



Contents

Thrice Monthly Volume 11 Number 36 December 26, 2023

EDITORIAL

- 8434 Post-trans-arterial chemoembolization hepatic necrosis and biliary stenosis: Clinical characteristics and endoscopic approach

Cocca S, Carloni L, Marocchi M, Grande G, Bianchini M, Colecchia A, Conigliaro R, Bertani H

MINIREVIEWS

- 8440 Perioperative nursing care for hip arthroplasty patients with concomitant hypertension: A minireview

Ji CY, Yang LR

ORIGINAL ARTICLE

Retrospective Study

- 8447 Evaluation of response to gemcitabine plus cisplatin-based chemotherapy using positron emission computed tomography for metastatic bladder cancer

Öztürk H, Karapolat İ

- 8458 Functional magnetic resonance imaging study of group independent components underpinning item responses to paranoid-depressive scale

Stoyanov D, Paunova R, Dichev J, Kandilarova S, Khorev V, Kurkin S

EVIDENCE-BASED MEDICINE

- 8475 Mendelian randomization provides evidence for a causal effect of serum insulin-like growth factor family concentration on risk of atrial fibrillation

Lin S, Tang J, Li X, Wu G, Lin YF, Li YF

SYSTEMATIC REVIEWS

- 8486 Significance of fostering the mental health of patients with diabetes through critical time intervention

Eseadi C, Amedu AN, Aloah HE

META-ANALYSIS

- 8498 Impact of angiotensin-converting enzyme inhibitors or angiotensin receptor blockers on the mortality in sepsis: A meta-analysis

Yang DC, Xu J, Jian L, Yu Y

CASE REPORT

- 8507 Multiple sparganosis spinal infections mainly in the thoracic region: A case report

Wen GJ, Chen J, Zhang SF, Zhou ZS, Jiao GL

- 8512** Iatrogenic flexor tendon rupture caused by misdiagnosing sarcoidosis-related flexor tendon contracture as tenosynovitis: A case report
Yan R, Zhang Z, Wu L, Wu ZP, Yan HD
- 8519** Cholecystoenteric fistula in a patient with advanced gallbladder cancer: A case report and review of literature
Wang CY, Chiu SH, Chang WC, Ho MH, Chang PY
- 8527** Intraperitoneal hyaline vascular Castleman disease: Three case reports
Gao JW, Shi ZY, Zhu ZB, Xu XR, Chen W
- 8535** Iris metastasis from clear cell renal cell carcinoma: A case report
Wang TT, Chen XY, Min QY, Han YZ, Zhao HF
- 8542** Spinal cord infarction attributed to SARS-CoV-2, with post-acute sequelae of COVID-19: A case report
Oleson CV, Olsen AC, Shermon S
- 8551** Spontaneous gastric hematoma as a rare cause of acute abdomen: A case report
Budimir I, Žulec M, Eljuga K, Židak M, Lisek V
- 8557** LiNA OperaScope™ for microwave endometrial ablation for endometrial polyps with heavy menstrual bleeding: A case report
Kakinuma K, Kakinuma T, Ueyama K, Shinohara T, Okamoto R, Yanagida K, Takeshima N, Ohwada M
- 8563** Colonoscopy-induced acute appendicitis: A case report
Song XL, Ma JY, Zhang ZG
- 8568** Post-laparotomy heterotopic ossification of the xiphoid process: A case report
Lee SS
- 8574** Balloon displacement during caesarean section with pernicious placenta previa: A case report
Gu DF, Deng C
- 8581** Synchronous carotid endarterectomy and coronary artery bypass graft: Four case reports
AlGhamdi FK, Altoijry A, AlQahtani A, Aldossary MY, AlSheikh SO, Iqbal K, Alayadhi WA
- 8589** Intraoperative cardiogenic shock induced by refractory coronary artery spasm in a patient with myasthenia gravis: A case report
Hsu CW, Chang CC, Lin CS
- 8595** Effects of video game-based therapy in an adolescent with cerebral palsy: A case report
Mohd Iqbal HA, Ho WS, Zanudin A, Hisham H, Mohd Nordin NA

LETTER TO THE EDITOR

- 8603** Lyophilized recombinant human brain natriuretic peptide: A promising therapy in patients with chronic heart failure
Kourek C, Briasoulis A, Giamouzis G, Skoularigis J, Xanthopoulos A

ABOUT COVER

Editorial Board Member of *World Journal of Clinical Cases*, Marco Infante, MD, PhD, Adjunct Professor, UniCamillus, Saint Camillus International University of Health Sciences, Rome 00131, Italy.
marco.infante@unicamillus.org

AIMS AND SCOPE

The primary aim of *World Journal of Clinical Cases* (WJCC, *World J Clin Cases*) is to provide scholars and readers from various fields of clinical medicine with a platform to publish high-quality clinical research articles and communicate their research findings online.

WJCC mainly publishes articles reporting research results and findings obtained in the field of clinical medicine and covering a wide range of topics, including case control studies, retrospective cohort studies, retrospective studies, clinical trials studies, observational studies, prospective studies, randomized controlled trials, randomized clinical trials, systematic reviews, meta-analysis, and case reports.

INDEXING/ABSTRACTING

The WJCC is now abstracted and indexed in Science Citation Index Expanded (SCIE, also known as SciSearch®), Journal Citation Reports/Science Edition, Current Contents®/Clinical Medicine, PubMed, PubMed Central, Reference Citation Analysis, China Science and Technology Journal Database, and Superstar Journals Database. The 2023 Edition of Journal Citation Reports® cites the 2022 impact factor (IF) for WJCC as 1.1; IF without journal self cites: 1.1; 5-year IF: 1.3; Journal Citation Indicator: 0.26; Ranking: 133 among 167 journals in medicine, general and internal; and Quartile category: Q4.

RESPONSIBLE EDITORS FOR THIS ISSUE

Production Editor: Zi-Hang Xu, Production Department Director: Xiang Li, Editorial Office Director: Jin-Lei Wang.

NAME OF JOURNAL

World Journal of Clinical Cases

ISSN

ISSN 2307-8960 (online)

LAUNCH DATE

April 16, 2013

FREQUENCY

Thrice Monthly

EDITORS-IN-CHIEF

Bao-Gan Peng, Salim Surani, Jerzy Tadeusz Chudek, George Kontogeorgos, Maurizio Serati

EDITORIAL BOARD MEMBERS

<https://www.wjgnet.com/2307-8960/editorialboard.htm>

PUBLICATION DATE

December 26, 2023

COPYRIGHT

© 2024 Baishideng Publishing Group Inc

INSTRUCTIONS TO AUTHORS

<https://www.wjgnet.com/bpg/gerinfo/204>

GUIDELINES FOR ETHICS DOCUMENTS

<https://www.wjgnet.com/bpg/GerInfo/287>

GUIDELINES FOR NON-NATIVE SPEAKERS OF ENGLISH

<https://www.wjgnet.com/bpg/gerinfo/240>

PUBLICATION ETHICS

<https://www.wjgnet.com/bpg/GerInfo/288>

PUBLICATION MISCONDUCT

<https://www.wjgnet.com/bpg/gerinfo/208>

ARTICLE PROCESSING CHARGE

<https://www.wjgnet.com/bpg/gerinfo/242>

STEPS FOR SUBMITTING MANUSCRIPTS

<https://www.wjgnet.com/bpg/GerInfo/239>

ONLINE SUBMISSION

<https://www.f6publishing.com>



Balloon displacement during caesarean section with pernicious placenta previa: A case report

Deng-Feng Gu, Chao Deng

Specialty type: Medicine, research and experimental

Provenance and peer review: Unsolicited article; Externally peer reviewed.

Peer-review model: Single blind

Peer-review report's scientific quality classification

Grade A (Excellent): 0
Grade B (Very good): 0
Grade C (Good): C
Grade D (Fair): 0
Grade E (Poor): 0

P-Reviewer: Yarmahmoodi F, Iran

Received: October 17, 2023

Peer-review started: October 17, 2023

First decision: November 20, 2023

Revised: November 26, 2023

Accepted: December 15, 2023

Article in press: December 15, 2023

Published online: December 26, 2023



Deng-Feng Gu, Chao Deng, Department of Anesthesiology, The First Affiliated Hospital of Shihezi University, Shihezi 832000, Xinjiang Uighur Autonomous Region, China

Corresponding author: Chao Deng, MM, Chief Physician, Doctor, Department of Anesthesiology, the First Affiliated Hospital of Shihezi University, No. 107 North Second Road, Shihezi 832000, Xinjiang Uighur Autonomous Region, China. 1452793572@qq.com

Abstract

BACKGROUND

For the past few years, preventive interventional therapy has been widely used domestically and overseas, bringing great benefits to pregnant women at high-risk for complications, such as pernicious placenta previa (PPP) and placenta accreta. Nevertheless, there are still few reports on surgical complications related to interventional therapy, and its safety should be a concern.

CASE SUMMARY

We report a 36-year-old pregnant woman with PPP who underwent balloon implantation in the lower segment of the abdominal aorta before caesarean section. However, the balloon shifted during the operation, which damaged the arterial vessels after filling, resulting in severe postpartum haemorrhage in the patient. Fortunately, after emergency interventional stent implantation, the patient was successfully relieved of the massive haemorrhage crisis.

CONCLUSION

It seems that massive postoperative bleeding has been largely avoided in preventive interventional therapy in high-risk pregnant women with placenta-related diseases, but surgical complications related to intervention therapy can also cause adverse consequences. It is equally important for clinical doctors to learn how to promptly identify and effectively treat these rare complications.

Key Words: Pernicious placenta previa; Caesarean section; Abdominal aortic balloon; Case report

©The Author(s) 2023. Published by Baishideng Publishing Group Inc. All rights reserved.

Core Tip: It is well known that postpartum haemorrhage is one of the most serious complications in malignant placenta previa caesarean section, and it is also the most concerning problem for medical staff. Currently, preventive interventional therapy has been able to prevent postpartum haemorrhage to a large extent, but its surgical complications need to be acknowledged, given that they are often overlooked. This article introduces a case of adverse consequences caused by an interventional therapy complication to provide some information for medical staff's clinical work.

Citation: Gu DF, Deng C. Balloon displacement during caesarean section with pernicious placenta previa: A case report. *World J Clin Cases* 2023; 11(36): 8574-8580

URL: <https://www.wjgnet.com/2307-8960/full/v11/i36/8574.htm>

DOI: <https://dx.doi.org/10.12998/wjcc.v11.i36.8574>

INTRODUCTION

Pernicious placenta previa (PPP) is placenta previa that occurs at the uterine scar incision from a previous caesarean section[1]. Uncontrolled and fatal postpartum haemorrhage is the main threat to such pregnant women. Research statistics have shown that[2] it is common for patients with placenta previa undergoing caesarean section to experience intraoperative bleeding of up to 3000 mL, this occurs in up to 90%, and approximately 10% of them even experience bleeding exceeding the rare 10000 mL. Massive postpartum haemorrhage can easily lead to complications such as haemorrhagic shock, disseminated intravascular coagulation, and multiple organ failure, endangering the safety of pregnant women and newborns[3]. Even in severe cases, some patients have to undergo hysterectomy, which can cause great harm to their physical and mental health[4]. In recent years, the use of abdominal aortic balloons to control bleeding has been widely used in caesarean section for placenta previa[5,6]. Temporarily filling the arterial balloon before stripping the placenta not only effectively reduces intraoperative blood loss, and provides a clear surgical field, but also more importantly, reduces the rate of hysterectomy[7]. However, this kind of intervention also has corresponding surgical complications[8], such as vascular injury, pseudoaneurysm, arterial thrombosis[9], ischaemia reperfusion injury, and foetal radiation exposure. We describe a rare complication that occurred during abdominal aortic balloon occlusion combined with caesarean section in a pregnant woman with PPP and give some opinions on this phenomenon.

CASE PRESENTATION

Chief complaints

A 36-year-old woman was admitted to the hospital to terminate her pregnancy due to a recurrence of brucellosis after 20 + 4 wk of pregnancy.

History of present illness

The patient experienced an elevated body temperature two weeks earlier, even reaching a maximum of 41 °C. She took antibiotics and antipyretic analgesics for symptomatic treatment of her brucellosis. At the same time, this pregnant woman reported that the foetal movement response significantly decreased 10 d ago. Due to fear of medication leading to foetal intrauterine death or abnormalities, after her body temperature returned to normal, she went to our hospital to ask for termination of pregnancy.

History of past illness

The patient was diagnosed with brucellosis 6 mo ago. After symptomatic treatment in other hospitals, her condition improved, and since then, the patient stopped taking the medicine herself.

Personal and family history

The patient denied any infectious disease and any relevant family history of placenta previa.

Physical examination

On physical examination, the patient's vital signs were as follows: Body temperature, 36.1 °C; blood pressure (BP), 113/79 mmHg; heart rate (HR), 91 beats per min; respiratory rate, 16 breaths per min, height, 165 cm; weight, 70 kg. Specialist inspection: The pregnant woman's abdomen showed a gestational bulge with an abdominal circumference of 96 cm, and her pelvic floor was at the navel level. At this time, the foetal HR was 148 beats/min, but the contractions were not palpable. In gynaecological diagnosis, the cervical canal was not ruled out, the uterine orifice was not open, and the foetal membrane was not broken.

Laboratory examinations

Routine blood tests showed a haemoglobin level of 85 g/L and a C-reactive protein level of 19.95 mg/L. Blood

biochemical analysis indicated an albumin level of 28.5 g/L and a blood alkaline phosphatase level of 189.0 mmol/L.

Imaging examinations

Prenatal ultrasound examination revealed that the pregnant woman had central placenta previa and currently had subchorionic haemorrhage.

Marital and reproductive history

The patient was married at the age of 21 years. She had been pregnant a total of 5 times thus far, with two previous deliveries being caesarean sections (in 2008 and 2017) and two induced abortions.

FINAL DIAGNOSIS

The patient was diagnosed with placenta accreta without bleeding, central placenta previa, pregnancy with uterine scars, mid-term induced abortion, brucellosis, subchorionic haematoma, pregnancy with liver damage, pregnancy with hypoproteinaemia, pregnancy with anaemia and pregnancy 5, delivery 2, and pregnancy 20 + 4 wk.

TREATMENT

The patient experienced fever again after admission and sustained lower abdominal pain without any underlying cause. Urgent pelvic ultrasound examination revealed local detachment of the placenta. Considering the changes in the patient's condition, it is recommended to undergo caesarean section and embryo removal surgery. Due to the clear diagnosis of central placenta previa and placenta accreta in the patient, there is a high possibility of acute massive bleeding during surgery. Therefore, to reduce the amount of bleeding, a balloon placement surgery in the lower segment of the abdominal aorta (**Figure 1**) was performed before the caesarean section, and immediately after the intervention surgery, a "transverse incision caesarean section for embryo retrieval in the lower segment of the uterus" was performed.

After entering the abdomen, it was found that the bladder peritoneum was tightly adhered to the the previous uterine scar. The placenta was implanted in the scar of the previous caesarean section of the uterus, and the surface blood vessels were dilated (**Figure 2**), making it impossible to push down the bladder peritoneum. The uterus was transversely cut 1cm above the scar, and a large amount of brownish-red purulent thread-like blood gushed out of the uterine cavity. After puncturing the amniotic membrane, a 470 g baby boy was delivered, but the foetus died, most likely due to intrauterine infection, then the pungent, pale yellow-green was immediately aspirated. After the delivery of the dead foetus, extensive implantation and adhesions of placental tissue were observed in the posterior wall, left and right walls, and lower segment of the uterus. Bleeding was active at the dissection site, and the obstetrician immediately filled the abdominal aortic balloon at this time. The blocking effect was observed to be poor, and the amount of bleeding did not decrease. Then, after the tourniquet was tied in the vascular free zone of the broad ligament in the lower segment of the uterus, the ascending branches of the bilateral uterine arteries were ligated, the posterior wall and the lower segment of the uterus were sutured with "8" shaped sutures for haemostasis and symptomatic treatment to promote uterine contraction, and the bleeding of the wound caused by the separation of uterus and placenta was reduced. Due to the time of filling of the abdominal aortic balloon up to 15 min, the balloon was immediately emptied. At this time, the patient's BP suddenly dropped to 60/30 mmHg. Blood transfusion and fluid replacement were immediately performed to treat shock. At the same time, bilateral appendages and abdominal cavities were examined, and a dark red haematoma with a diameter of approximately 10 cm was found on the right side of the sacral promontory of the posterior peritoneum, with irregular range and significant fluctuations and no significant increase in BP after deep pressure treatment. We palpated the patient's bilateral dorsalis pedis arteries, and the pulsation of the right artery was significantly weaker than that of the left. We had reason to suspect that the patient's abdominal aortic balloon shifted and injured the artery after filling it. Immediate angiography was performed to confirm the diagnosis, and it was observed that the patient's right common iliac artery was torn and bleeding, with blood extravasation forming a haematoma (**Figure 3**). Immediately, we requested that an interventional physician perform the right common iliac artery covered stent implantation surgery. Postoperative angiography showed that the lumen of the right common iliac artery was unobstructed, the stent was well unfolded, and no definite contrast agent leakage was observed. The ruptured vessel was successfully repaired (**Figure 4**), and the patient's vital signs gradually stabilized. The total duration of this surgery was 5 h, with a blood loss of approximately 3000 mL. During the surgery, 10 U of red blood cell suspension and 1000 mL of plasma were transfused.

OUTCOME AND FOLLOW-UP

After the surgery, the patient was transferred to an intensive care unit for continued close monitoring, and received active treatment, such as anti-infection therapy, promotion of uterine contractions, and correction of anaemia. After recovery, the patient was discharged from the hospital.

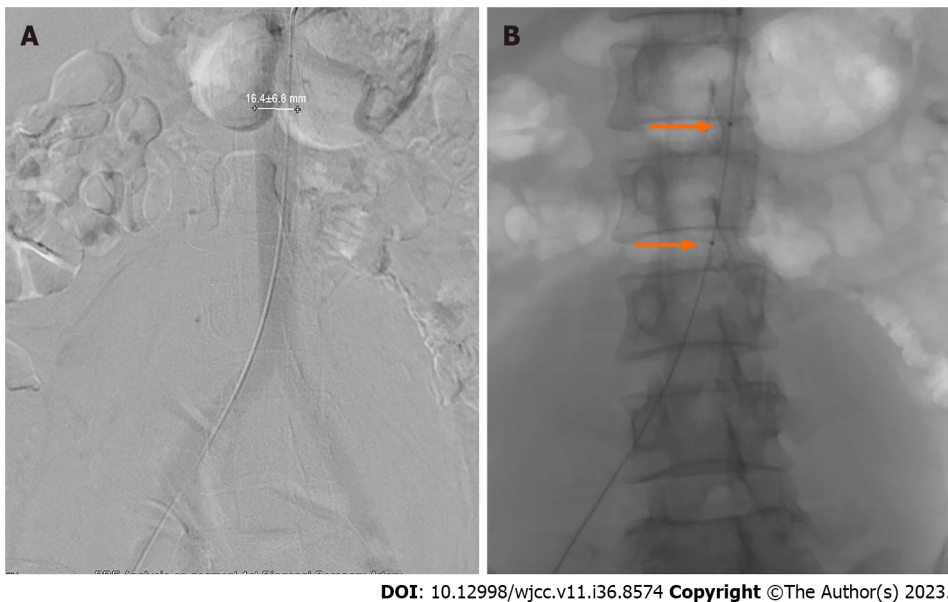


Figure 1 Prophylactic placement of the abdominal aortic balloon before cesarean section. A: Abdominal aortography; B: Balloon catheter marker point (orange arrows).

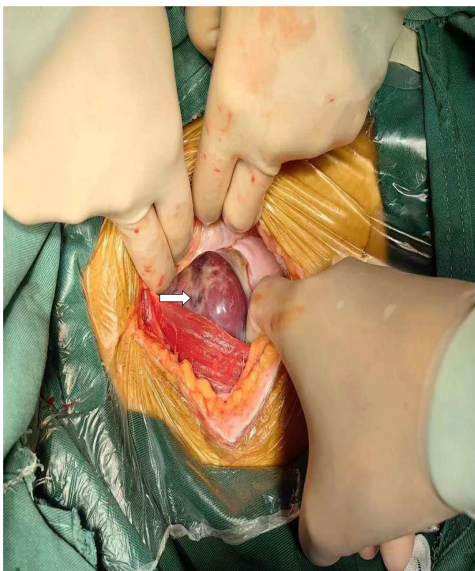
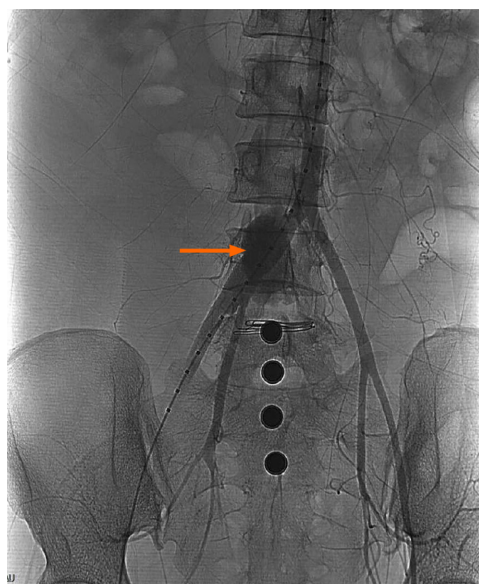

Figure 2 Placenta is implanted in the scar of the previous cesarean section (white arrow).

DISCUSSION

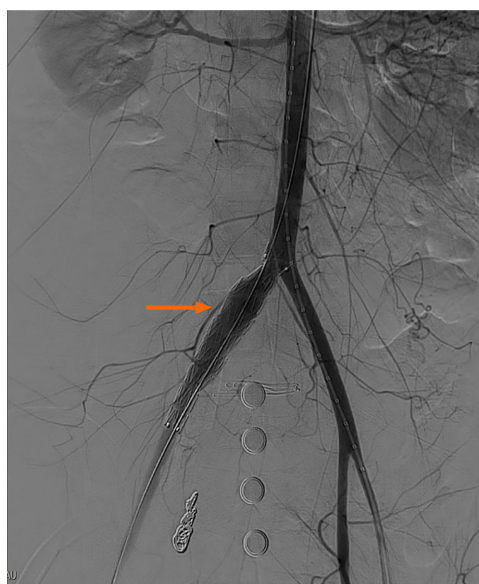
With the reform of China's family planning policy, the number of caesarean sections and the difficulty of surgery are constantly increasing, especially for high-risk pregnant women with placenta previa and placenta accreta spectrum (PAS) diseases. It has been reported that the incidence rate of PPP patients in China is 0.31%-0.89%, and approximately 53.3% of PPP patients have PAS[10], which means that obstetricians and anaesthesiologists face greater challenges. For pregnant women with placenta previa or placental implantation diseases, preoperative preventive intervention treatments such as abdominal aortic balloon implantation and uterine artery embolization allow doctors rescue patients with postpartum haemorrhage and have achieved significant results both domestically and internationally[11]. However, inevitably, there are still many worrisome aspects to interventional therapy, such as whether X-ray exposure is harmful to the foetus, whether preventive intervention surgery can completely avoid postpartum haemorrhage, and whether arterial blockade can cause ischaemi damage to other organs, which are all worthy of attention.

The main feature of our case is the occurrence of a rare complication, injury to the common iliac artery caused by filling the abdominal aortic balloon after unforeseen displacement.



DOI: 10.12998/wjcc.v11.i36.8574 Copyright ©The Author(s) 2023.

Figure 3 Blebbling of the right common iliac artery (orange arrow).



DOI: 10.12998/wjcc.v11.i36.8574 Copyright ©The Author(s) 2023.

Figure 4 Right common iliac vessel stent placement (orange arrow).

The possible reasons for the occurrence of this rare complication are as follows: (1) The preoperative abdominal aortic balloon implantation surgery for patients undergoing caesarean section is performed using digital subtraction angiography equipment in the interventional surgery room. After completion, the patient needs to be transported to the operating room for caesarean embryo removal. During this period, multiple handling of the patient is inevitable, and frequent and nonstandard bed transfer processes lead to the displacement of the abdominal aortic balloon; (2) during caesarean section, the delivery of the foetus requires external force to compress the fundus of the uterus, and the surgeon usually pushes directly above the abdominal aortic balloon. Inappropriate force may also be one of the reasons for balloon displacement; (3) pregnant women have a different abdominal pressure from ordinary people. When the foetal placenta is delivered and amniotic fluid flows out, the uterine volume decreases, and the abdominal pressure drops suddenly. The changes in pressure before and after can cause the fixed balloon to shift; (4) after the balloon was correctly placed in position, the arterial sheath at the femoral artery puncture point and balloon catheter were not well fixed. Although the adhesive used for fixation during the surgery in this case did not fail, it is still possible that the catheter had moved outwards and (5) the discrepancy between the size of the balloon catheter and the patient's blood vessels, as well as the inadequate placement of the balloon catheter, are also reasons for this shift.

Summary of experience and lessons learned from this case: (1) For the delivery of fetuses of pregnant women with PPP accompanied by placental implantation, it is necessary to pay attention to the prevention and treatment of severe postpartum haemorrhage, and multidisciplinary cooperation is essential. All departments should make comprehensive preoperative preparations and take corresponding measures, including preinstall abdominal aorta or bilateral common iliac artery balloon blockers in the interventional radiology department to prevent bleeding during placenta removal. The obstetrics department should develop a rigorous surgical plan and be equipped with sufficient qualified and experienced surgeons. The anaesthesia department should prepare for the rescue of intraoperative massive bleeding, such as invasive BP monitoring, multiple infusion pathways, rapid airway establishment plans, blood products, and liquid resuscitation supplies. At the same time, the intensive care department and nursing team should conduct rigorous postoperative observations and meticulous care; (2) at present, preoperative arterial balloon implantation has been performed under ultrasound guidance instead of X-ray[12]. Ultrasound monitoring equipment not only prevents physicians and patients from receiving radiation but also fetuses. Moreover, this technology does not require specialized hybrid operating rooms, greatly saving operating time and reducing the occurrence of balloon catheter displacement due to transportation. At the same time, ultrasound can be used to dynamically monitor the position of the balloon, adjust the position deviation in a timely manner, avoid complications caused by this, and ensure the safety of the mother and baby; (3) the catheter needs to be fixed in a more meticulous manner, such as marking the catheter and skin at the puncture point after successful placement, to observe its position at any time, determine whether it is dislodged and determine whether the balloon is displaced; and (4) even a perfect preoperative preparation cannot completely avoid the occurrence of all unexpected situations. PPP and balloon displacement can both lead to the occurrence of severe bleeding in patients. As in this case, the combination of two risk factors further increases the risk and volume of bleeding, leading to uncontrollable massive bleeding during surgery, making the patient's condition even more dangerous. Therefore, surgeons should maintain a vigilant mentality, handle possible critical situations with cautious and meticulous surgical operations, and summarize experiences and lessons in a timely manner. Only in this way can we ensure the safety of patients' lives.

CONCLUSION

Pregnant women with PPP often need preventive interventional therapy before undergoing caesarean section, which can significantly reduce the incidence of postpartum haemorrhage and a series of serious adverse consequences. However, the patient experienced a rare complication of balloon displacement, which led to more severe postpartum haemorrhage. Yet, after timely identification and multidisciplinary collaboration in diagnosis and treatment, the life of this pregnant woman was ultimately saved. Thus, any treatment method has complications, so regardless of the probability of occurrence, clinical doctors should remain vigilant, be prepared to face all possible critical situations, gain clinical experience, and protect the patient's life.

FOOTNOTES

Author contributions: Gu DF contributed to manuscript writing and editing, Deng C contributed to conceptualization and supervision; all authors have read and approved the final manuscript.

Supported by Curriculum Case Base Construction Project of the First Affiliated Hospital of Xinjiang Shihezi University, No. 2021Y-AL15.

Informed consent statement: Informed consent was obtained from the patients for publication of this case report details.

Conflict-of-interest statement: The authors declare that they have no conflict of interest.

CARE Checklist (2016) statement: The authors have read the CARE Checklist (2016), and the manuscript was prepared and revised according to the CARE Checklist (2016).

Open-Access: This article is an open-access article that was selected by an in-house editor and fully peer-reviewed by external reviewers. It is distributed in accordance with the Creative Commons Attribution NonCommercial (CC BY-NC 4.0) license, which permits others to distribute, remix, adapt, build upon this work non-commercially, and license their derivative works on different terms, provided the original work is properly cited and the use is non-commercial. See: <https://creativecommons.org/licenses/by-nc/4.0/>

Country/Territory of origin: China

ORCID number: Chao Deng 0009-0004-5228-7282.

S-Editor: Qu XL

L-Editor: A

P-Editor: Qu XL

REFERENCES

- 1 **Kollmann M**, Gaulhofer J, Lang U, Klaritsch P. Placenta praevia: incidence, risk factors and outcome. *J Matern Fetal Neonatal Med* 2016; **29**: 1395-1398 [PMID: [26043298](#) DOI: [10.3109/14767058.2015.1049152](#)]
- 2 **Soyama H**, Miyamoto M, Ishibashi H, Takano M, Sasa H, Furuya K. Relation between Birth Weight and Intraoperative Hemorrhage during Cesarean Section in Pregnancy with Placenta Previa. *PLoS One* 2016; **11**: e0167332 [PMID: [27902772](#) DOI: [10.1371/journal.pone.0167332](#)]
- 3 **Matsuzaki S**, Mandelbaum RS, Sangara RN, McCarthy LE, Vestal NL, Klar M, Matsushima K, Amaya R, Ouzounian JG, Matsuo K. Trends, characteristics, and outcomes of placenta accreta spectrum: a national study in the United States. *Am J Obstet Gynecol* 2021; **225**: 534.e1-534.e38 [PMID: [33894149](#) DOI: [10.1016/j.ajog.2021.04.233](#)]
- 4 **Horng HC**, Lai MJ, Chang WH, Wang PH. Placenta accreta spectrum (PAS) and peripartum hysterectomy. *Taiwan J Obstet Gynecol* 2021; **60**: 395-396 [PMID: [33966717](#) DOI: [10.1016/j.tjog.2021.03.001](#)]
- 5 **Wei Y**, Luo J, Luo D. Comparison of Efficacy between Internal Iliac Artery and Abdominal Aorta Balloon Occlusions in Pernicious Placenta Previa Patients with Placenta Accrete. *Gynecol Obstet Invest* 2019; **84**: 343-349 [PMID: [30625467](#) DOI: [10.1159/000494493](#)]
- 6 **Huo F**, Liang H, Feng Y. Prophylactic temporary abdominal aortic balloon occlusion for patients with pernicious placenta previa: a retrospective study. *BMC Anesthesiol* 2021; **21**: 134 [PMID: [33926381](#) DOI: [10.1186/s12871-021-01354-1](#)]
- 7 **Wang Y**, Huang G, Jiang T, Han X. Application of abdominal aortic balloon occlusion followed by uterine artery embolization for the treatment of pernicious placenta previa complicated with placenta accreta during cesarean section. *J Interv Med* 2019; **2**: 113-117 [PMID: [34805883](#) DOI: [10.1016/j.jimed.2019.09.010](#)]
- 8 **Ben-David B**, Kaligozhin Z, Viderman D. Quadratus lumborum block in management of severe pain after uterine artery embolization. *Eur J Pain* 2018; **22**: 1032-1034 [PMID: [29336523](#) DOI: [10.1002/ejp.1171](#)]
- 9 **Wang ZX**, Zhao YF, Li L. Is prophylactic intraoperative abdominal aortic balloon occlusion beneficial in pregnancies with placenta previa and placenta accreta spectrum during cesarean section? A 5-year retrospective study. *Int J Gynaecol Obstet* 2023; **163**: 572-578 [PMID: [37183630](#) DOI: [10.1002/ijgo.14852](#)]
- 10 **Zhou Y**, Song Z, Wang X, Zhang M, Chen X, Zhang D. Ultrasound-based nomogram for postpartum hemorrhage prediction in pernicious placenta previa. *Front Physiol* 2022; **13**: 982080 [PMID: [36072853](#) DOI: [10.3389/fphys.2022.982080](#)]
- 11 **Zhang LL**, Wang WH, Hou YL. Analysis of the Risk Factors for Massive Hemorrhage in Pernicious Placenta Previa and Evaluation of the Efficacy of Internal Iliac Artery Balloon Occlusion. *Int J Womens Health* 2022; **14**: 1769-1776 [PMID: [36575728](#) DOI: [10.2147/IJWH.S379965](#)]
- 12 **Li N**, Yang T, Liu C, Qiao C. Feasibility of Infrarenal Abdominal Aorta Balloon Occlusion in Pernicious Placenta Previa Coexisting with Placenta Accrete. *Biomed Res Int* 2018; **2018**: 4596189 [PMID: [29977912](#) DOI: [10.1155/2018/4596189](#)]



Published by **Baishideng Publishing Group Inc**
7041 Koll Center Parkway, Suite 160, Pleasanton, CA 94566, USA

Telephone: +1-925-3991568

E-mail: bpgoffice@wjgnet.com

Help Desk: <https://www.f6publishing.com/helpdesk>

<https://www.wjgnet.com>

