

World Journal of *Clinical Cases*

World J Clin Cases 2023 December 26; 11(36): 8434-8605



Contents

Thrice Monthly Volume 11 Number 36 December 26, 2023

EDITORIAL

- 8434 Post-trans-arterial chemoembolization hepatic necrosis and biliary stenosis: Clinical characteristics and endoscopic approach

Cocca S, Carloni L, Marocchi M, Grande G, Bianchini M, Colecchia A, Conigliaro R, Bertani H

MINIREVIEWS

- 8440 Perioperative nursing care for hip arthroplasty patients with concomitant hypertension: A minireview

Ji CY, Yang LR

ORIGINAL ARTICLE

Retrospective Study

- 8447 Evaluation of response to gemcitabine plus cisplatin-based chemotherapy using positron emission computed tomography for metastatic bladder cancer

Öztürk H, Karapolat İ

- 8458 Functional magnetic resonance imaging study of group independent components underpinning item responses to paranoid-depressive scale

Stoyanov D, Paunova R, Dichev J, Kandilarova S, Khorev V, Kurkin S

EVIDENCE-BASED MEDICINE

- 8475 Mendelian randomization provides evidence for a causal effect of serum insulin-like growth factor family concentration on risk of atrial fibrillation

Lin S, Tang J, Li X, Wu G, Lin YF, Li YF

SYSTEMATIC REVIEWS

- 8486 Significance of fostering the mental health of patients with diabetes through critical time intervention

Eseadi C, Amedu AN, Aloh HE

META-ANALYSIS

- 8498 Impact of angiotensin-converting enzyme inhibitors or angiotensin receptor blockers on the mortality in sepsis: A meta-analysis

Yang DC, Xu J, Jian L, Yu Y

CASE REPORT

- 8507 Multiple sparganosis spinal infections mainly in the thoracic region: A case report

Wen GJ, Chen J, Zhang SF, Zhou ZS, Jiao GL

- 8512** Iatrogenic flexor tendon rupture caused by misdiagnosing sarcoidosis-related flexor tendon contracture as tenosynovitis: A case report
Yan R, Zhang Z, Wu L, Wu ZP, Yan HD
- 8519** Cholecystoenteric fistula in a patient with advanced gallbladder cancer: A case report and review of literature
Wang CY, Chiu SH, Chang WC, Ho MH, Chang PY
- 8527** Intraperitoneal hyaline vascular Castleman disease: Three case reports
Gao JW, Shi ZY, Zhu ZB, Xu XR, Chen W
- 8535** Iris metastasis from clear cell renal cell carcinoma: A case report
Wang TT, Chen XY, Min QY, Han YZ, Zhao HF
- 8542** Spinal cord infarction attributed to SARS-CoV-2, with post-acute sequelae of COVID-19: A case report
Oleson CV, Olsen AC, Shermon S
- 8551** Spontaneous gastric hematoma as a rare cause of acute abdomen: A case report
Budimir I, Žulec M, Eljuga K, Židak M, Lisek V
- 8557** LiNA OperaScope™ for microwave endometrial ablation for endometrial polyps with heavy menstrual bleeding: A case report
Kakinuma K, Kakinuma T, Ueyama K, Shinohara T, Okamoto R, Yanagida K, Takeshima N, Ohwada M
- 8563** Colonoscopy-induced acute appendicitis: A case report
Song XL, Ma JY, Zhang ZG
- 8568** Post-laparotomy heterotopic ossification of the xiphoid process: A case report
Lee SS
- 8574** Balloon displacement during caesarean section with pernicious placenta previa: A case report
Gu DF, Deng C
- 8581** Synchronous carotid endarterectomy and coronary artery bypass graft: Four case reports
AlGhamdi FK, Altoijry A, AlQahtani A, Aldossary MY, AlSheikh SO, Iqbal K, Alayadhi WA
- 8589** Intraoperative cardiogenic shock induced by refractory coronary artery spasm in a patient with myasthenia gravis: A case report
Hsu CW, Chang CC, Lin CS
- 8595** Effects of video game-based therapy in an adolescent with cerebral palsy: A case report
Mohd Iqbal HA, Ho WS, Zanudin A, Hisham H, Mohd Nordin NA

LETTER TO THE EDITOR

- 8603** Lyophilized recombinant human brain natriuretic peptide: A promising therapy in patients with chronic heart failure
Kourek C, Briasoulis A, Giamouzis G, Skoularigis J, Xanthopoulos A

ABOUT COVER

Editorial Board Member of *World Journal of Clinical Cases*, Marco Infante, MD, PhD, Adjunct Professor, UniCamillus, Saint Camillus International University of Health Sciences, Rome 00131, Italy.
marco.infante@unicamillus.org

AIMS AND SCOPE

The primary aim of *World Journal of Clinical Cases* (WJCC, *World J Clin Cases*) is to provide scholars and readers from various fields of clinical medicine with a platform to publish high-quality clinical research articles and communicate their research findings online.

WJCC mainly publishes articles reporting research results and findings obtained in the field of clinical medicine and covering a wide range of topics, including case control studies, retrospective cohort studies, retrospective studies, clinical trials studies, observational studies, prospective studies, randomized controlled trials, randomized clinical trials, systematic reviews, meta-analysis, and case reports.

INDEXING/ABSTRACTING

The WJCC is now abstracted and indexed in Science Citation Index Expanded (SCIE, also known as SciSearch®), Journal Citation Reports/Science Edition, Current Contents®/Clinical Medicine, PubMed, PubMed Central, Reference Citation Analysis, China Science and Technology Journal Database, and Superstar Journals Database. The 2023 Edition of Journal Citation Reports® cites the 2022 impact factor (IF) for WJCC as 1.1; IF without journal self cites: 1.1; 5-year IF: 1.3; Journal Citation Indicator: 0.26; Ranking: 133 among 167 journals in medicine, general and internal; and Quartile category: Q4.

RESPONSIBLE EDITORS FOR THIS ISSUE

Production Editor: Zi-Hang Xu, Production Department Director: Xiang Li, Editorial Office Director: Jin-Lei Wang.

NAME OF JOURNAL

World Journal of Clinical Cases

ISSN

ISSN 2307-8960 (online)

LAUNCH DATE

April 16, 2013

FREQUENCY

Thrice Monthly

EDITORS-IN-CHIEF

Bao-Gan Peng, Salim Surani, Jerzy Tadeusz Chudek, George Kontogeorgos, Maurizio Serati

EDITORIAL BOARD MEMBERS

<https://www.wjgnet.com/2307-8960/editorialboard.htm>

PUBLICATION DATE

December 26, 2023

COPYRIGHT

© 2024 Baishideng Publishing Group Inc

INSTRUCTIONS TO AUTHORS

<https://www.wjgnet.com/bpg/gerinfo/204>

GUIDELINES FOR ETHICS DOCUMENTS

<https://www.wjgnet.com/bpg/GerInfo/287>

GUIDELINES FOR NON-NATIVE SPEAKERS OF ENGLISH

<https://www.wjgnet.com/bpg/gerinfo/240>

PUBLICATION ETHICS

<https://www.wjgnet.com/bpg/GerInfo/288>

PUBLICATION MISCONDUCT

<https://www.wjgnet.com/bpg/gerinfo/208>

ARTICLE PROCESSING CHARGE

<https://www.wjgnet.com/bpg/gerinfo/242>

STEPS FOR SUBMITTING MANUSCRIPTS

<https://www.wjgnet.com/bpg/GerInfo/239>

ONLINE SUBMISSION

<https://www.f6publishing.com>



Synchronous carotid endarterectomy and coronary artery bypass graft: Four case reports

Faisal Khader AlGhamdi, Abdulmajeed Altojry, Abdulrahman AlQahtani, Mohammed Yousef Aldossary, Sultan Omar AlSheikh, Kaisor Iqbal, Walid Abdulaziz Alayadhi

Specialty type: Medicine, research and experimental

Provenance and peer review: Unsolicited article; Externally peer reviewed.

Peer-review model: Single blind

Peer-review report's scientific quality classification

Grade A (Excellent): 0
Grade B (Very good): 0
Grade C (Good): C
Grade D (Fair): D
Grade E (Poor): 0

P-Reviewer: Lakusic N, Croatia;
Ueda H, Japan

Received: October 18, 2023

Peer-review started: October 18, 2023

First decision: November 13, 2023

Revised: November 19, 2023

Accepted: December 13, 2023

Article in press: December 13, 2023

Published online: December 26, 2023



Faisal Khader AlGhamdi, Walid Abdulaziz Alayadhi, Department of Cardiac Surgery, King Saud University, Riyadh 11322, Saudi Arabia

Abdulmajeed Altojry, Sultan Omar AlSheikh, Kaisor Iqbal, Department of Surgery, King Saud University, Riyadh 11322, Saudi Arabia

Abdulrahman AlQahtani, King Fahad Cardiac Center, King Saud University Medical City, Riyadh 11322, Saudi Arabia

Mohammed Yousef Aldossary, Department of General Surgery, King Saud University, Riyadh 11322, Saudi Arabia

Mohammed Yousef Aldossary, Department of Surgery, Dammam Medical Complex, Dammam 32245, Saudi Arabia

Corresponding author: Faisal Khader AlGhamdi, MBBS, Surgeon, Department of Cardiac Surgery, King Saud University, 7804 Street No. 18, Riyadh 11322, Saudi Arabia.
falghamdi3@ksu.edu.sa

Abstract

BACKGROUND

One of the major perioperative complications for coronary artery bypass graft (CABG) is stroke. The risk of perioperative stroke after CABG is approximately 2%. Carotid stenosis (CS) is considered an independent predictor of perioperative stroke risk in CABG patients. The optimal management of such patients has been a source of controversy. One of the possible surgical options is synchronous carotid endarterectomy (CEA) and CABG. Here, we have presented 4 cases of successful synchronous CEA and CABG.

CASE SUMMARY

Our center's experience with 4 cases of significant carotid artery stenosis, which were successfully managed with combined CEA and CABG, are detailed. The first case was a female who presented for CABG after a ST-elevation myocardial infarction. She had right internal carotid artery (ICA) occlusion and 90% left ICA stenosis. The second case was a male who was electively admitted for CABG. It was discovered that he had left ICA occlusion and 90% right ICA stenosis. The third case was a male with a history of stroke, two months prior to admission. He presented with non-ST-elevation myocardial infarction. Preoperatively, it was

discovered that he had > 90% right ICA stenosis. The final case was a male who was electively admitted for CABG. It was discovered that he had bilateral > 90% ICA stenosis. We have also reviewed the current evidence and guidelines for managing CS in patients undergoing CABG.

CONCLUSION

Our case series demonstrated that synchronous CEA and CABG was safe. A multicenter study with additional patients is needed. It is necessary for clinicians to screen for CS in high-risk patients with features.

Key Words: Carotid artery stenosis; Carotid endarterectomy; Coronary artery bypass grafting; Coronary artery disease; Synchronous; Case report

©The Author(s) 2023. Published by Baishideng Publishing Group Inc. All rights reserved.

Core Tip: The risk of perioperative stroke after coronary artery bypass graft (CABG) is 2%. A hemodynamically significant carotid artery stenosis is found in 7% of patients undergoing CABG. Carotid stenosis is considered an independent predictor for the risk of perioperative stroke in CABG patients. The optimal management of such patients has been a source of controversy, but one of the possible surgical options is combined carotid endarterectomy and CABG. Our case series suggested that this option is safe for the management of this population of patients.

Citation: AlGhamdi FK, Altoijry A, AlQahtani A, Aldossary MY, AlSheikh SO, Iqbal K, Alayadhi WA. Synchronous carotid endarterectomy and coronary artery bypass graft: Four case reports. *World J Clin Cases* 2023; 11(36): 8581-8588

URL: <https://www.wjgnet.com/2307-8960/full/v11/i36/8581.htm>

DOI: <https://dx.doi.org/10.12998/wjcc.v11.i36.8581>

INTRODUCTION

Ischemic heart disease and ischemic stroke are the two leading causes of death worldwide[1]. Due to similar pathophysiologic processes, coronary artery disease and carotid artery disease can coexist. A hemodynamically significant carotid artery stenosis (> 50% stenosis) is found in 7% of patients undergoing coronary artery bypass grafting (CABG)[2]. One of the major perioperative complications for CABG is stroke. The risk of perioperative stroke after CABG is around 2%[2]. Carotid stenosis (CS) is considered an independent predictor for the risk of perioperative stroke in CABG patients[3]. The optimal management of such patients has been a source of controversy. One of the possible surgical options for treatment is synchronous carotid endarterectomy (CEA) and CABG. In this work, we reported the experience of 4 cases of successful combined CEA and CABG at a single center and briefly reviewed the literature.

CASE PRESENTATION

Chief complaints

Case 1: A 64-year-old female presented with typical ischemic chest pain.

Case 2: A 76-year-old male presented with the complaint of chronic chest discomfort that was related to physical exertion.

Case 3: A 63-year-old male presented with severe chest pain that started 6 h prior to presentation to the emergency department.

Case 4: A 71-year-old male presented with shortness of breath and orthopnea that started the morning of his presentation.

History of present illness

Case 1: The patient presented to our emergency department with chest pain that was retrosternal and radiating to the left. She previously had similar pain that was related to physical activity. The previous pain was aggravated by physical activity and relieved by rest. However, the pain at presentation was more severe and occurred during rest.

Case 2: The patient presented to the clinic with a 6-mo history of chest discomfort and tightness that was triggered by physical exertion and relieved by rest. He denied any shortness of breath, palpitations, or loss of consciousness. The patient was electively admitted to our center for diagnostic coronary angiography (CAG).

Case 3: The patient presented to our emergency department with severe left-sided chest pain that was radiating to the back and left shoulder. The chest pain started while the patient was at rest and was associated with shortness of breath

and sweating. He was admitted with an initial diagnosis of non-ST elevation myocardial infarction (NSTEMI).

Case 4: The patient presented to our emergency department with shortness of breath that started that morning while at rest. He was also experiencing chest heaviness and sweating. He was admitted with an initial diagnosis of NSTEMI.

History of past illness

Case 1: The patient had diabetes, which was poorly controlled, and hypertension. In addition, she had hypothyroidism. She previously had an infected foot ulcer that was treated by amputation of the right big toe.

Case 2: The patient had end-stage renal disease and hypertension.

Case 3: The patient had hypertension. He also had a history of pulmonary embolism that was treated with oral anticoagulation medication. He suffered a stroke 2 mo prior to presentation and experienced residual left-sided weakness.

Case 4: The patient had hypothyroidism and bilateral carotid artery stenosis.

Personal and family history

There were no family history of cardiac disease or stroke of all patients.

Physical examination

Case 1: The patient was alert, conscious, and oriented with stable vital signs. She had normal bilateral vesicular breathing sounds. Heart sounds were normal with no murmurs or added sounds. Peripheral pulses were palpable with normal volume on both upper and lower limbs.

Case 2: The patient was alert, conscious, and oriented with stable vital signs. He had normal bilateral vesicular breathing sounds. Heart sounds were normal with no murmurs or added sounds. Peripheral pulses were palpable with normal volume on both upper and lower limbs. He had an arteriovenous fistula on his left arm that was used for dialysis.

Case 3: The patient was alert, conscious, and oriented with stable vital signs. He had normal bilateral vesicular breathing sounds. Heart sounds were normal with no murmurs or added sounds. Peripheral pulses were palpable with normal volume on both upper and lower limbs. The motor power of the patient's upper and lower limbs on the left side was reduced. However, sensation and proprioception were preserved.

Case 4: The patient was alert, conscious, and oriented with stable vital signs. He had normal bilateral vesicular breathing sounds. Heart sounds were normal with no murmurs or added sounds. Peripheral pulses were palpable with normal volume on both upper and lower limbs.

Laboratory examinations

Case 1: The patient's routine blood work was normal with the exception of the hemoglobin A1c level, which was 9.9% (normal range: < 5.7%).

Case 2: The patient's routine blood work was normal with the exception of the creatinine level, which was 575 mmol/L (normal range: 53-106 mmol/L). The estimated glomerular filtration rate was very low (8.4 mL/min/1.73 m²; normal range: ≥ 90 mL/min/1.73 m²).

Case 3: The patient's routine blood work was normal with the exception of the high-sensitivity troponin-T level which was 126 ng/L (normal range: 0.0002-58.9 ng/L).

Case 4: The patient's routine blood work was normal with the exception of the high-sensitivity troponin-T level which was 200 ng/L. The patient's hemoglobin A1c level was slightly elevated (6.1%).

Imaging examinations

Case 1: Echocardiography showed a 30%-35% left ventricular ejection fraction (LVEF) with no significant valvular abnormalities. CAG showed triple vessel disease. Carotid Doppler showed total occlusion of the right internal carotid artery (ICA) and > 90% stenosis of the left ICA (Figure 1).

Case 2: Echocardiography showed a > 50% LVEF with mild mitral regurgitation. CAG showed triple vessel disease. Carotid Doppler showed total occlusion of the left ICA and > 90% stenosis of the right ICA (Figure 2).

Case 3: Echocardiography showed a 30% LVEF with mild aortic regurgitation. CAG showed left main coronary artery stenosis (> 50%). Carotid Doppler showed 90%-99% stenosis of the right ICA and normal left ICA (Figure 3).

Case 4: Echocardiography a 35%-40% LVEF with mild mitral regurgitation. CAG showed significant triple vessel disease. Carotid Doppler showed 90% stenosis of the left ICA and > 90% stenosis of the right ICA (Figure 4).

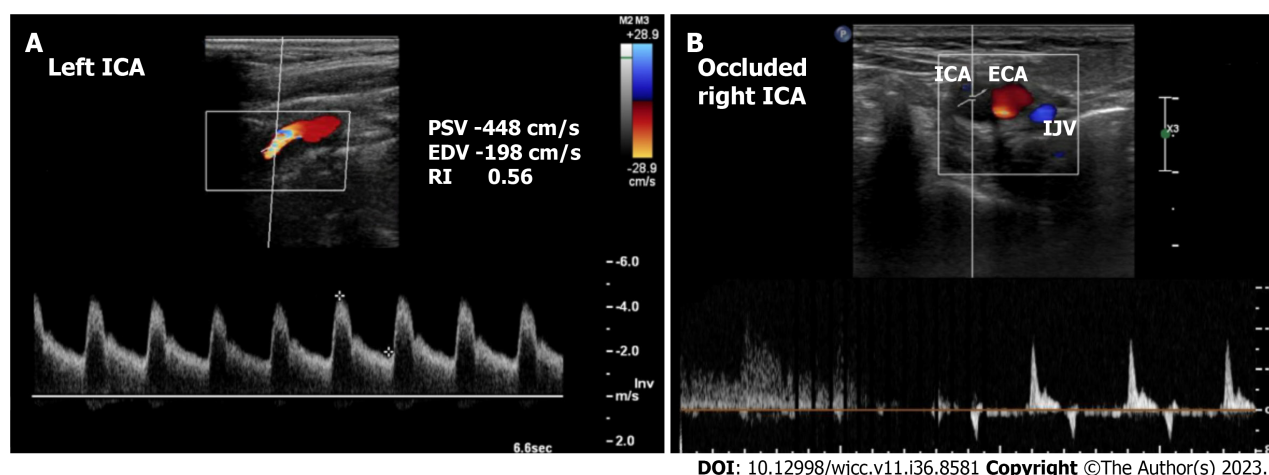


Figure 1 Preoperative carotid ultrasound duplex in case 1. A: Left internal carotid artery stenosis of > 90%; B: Totally occluded right interval carotid artery. ECA: External carotid artery; EDV: End-diastolic velocity; IJV: Internal jugular vein; PSV: Peak systolic velocity; RI: Resistance index; ICA: Internal carotid artery.

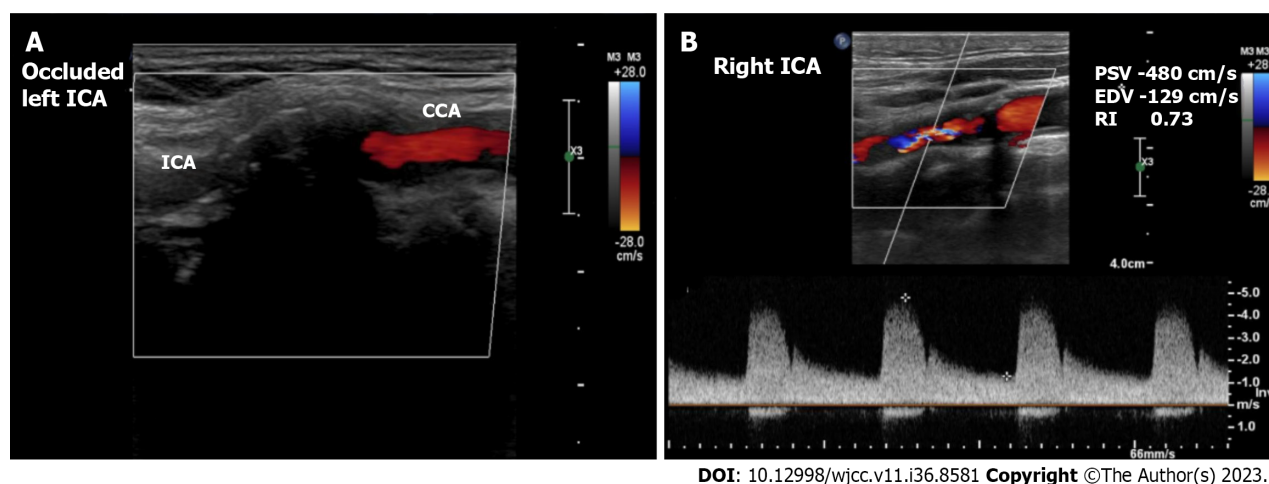


Figure 2 Preoperative carotid ultrasound duplex in case 2. A: Totally occluded left internal carotid artery; B: Right interval carotid artery stenosis of > 90%. CCA: Common carotid artery; EDV: End-diastolic velocity; PSV: Peak systolic velocity; RI: Resistance index; ICA: Internal carotid artery.

FINAL DIAGNOSIS

Case 1: The patient was diagnosed with triple vessel coronary artery disease with low ejection fraction and total occlusion of the right ICA and 90% stenosis of the left ICA.

Case 2: The patient was diagnosed with triple vessel coronary artery disease with preserved ejection fraction and total occlusion of the left ICA and > 90% stenosis of the right ICA.

Case 3: The patient was diagnosed with left main coronary artery stenosis with reduced LVEF, NSTEMI, and > 90% stenosis of the right ICA.

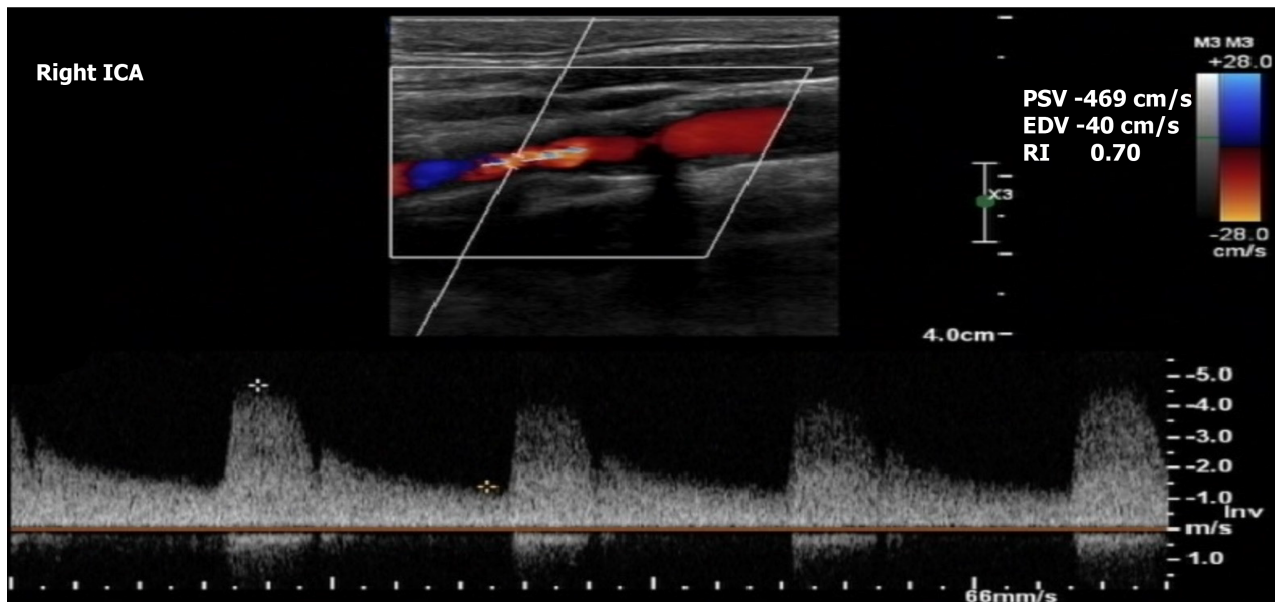
Case 4: The patient was diagnosed with triple vessel coronary artery disease presenting as NSTEMI with reduced ejection fraction and bilateral > 90% ICA stenosis.

TREATMENT

Case 1: The patient underwent left CEA and on-pump CABG.

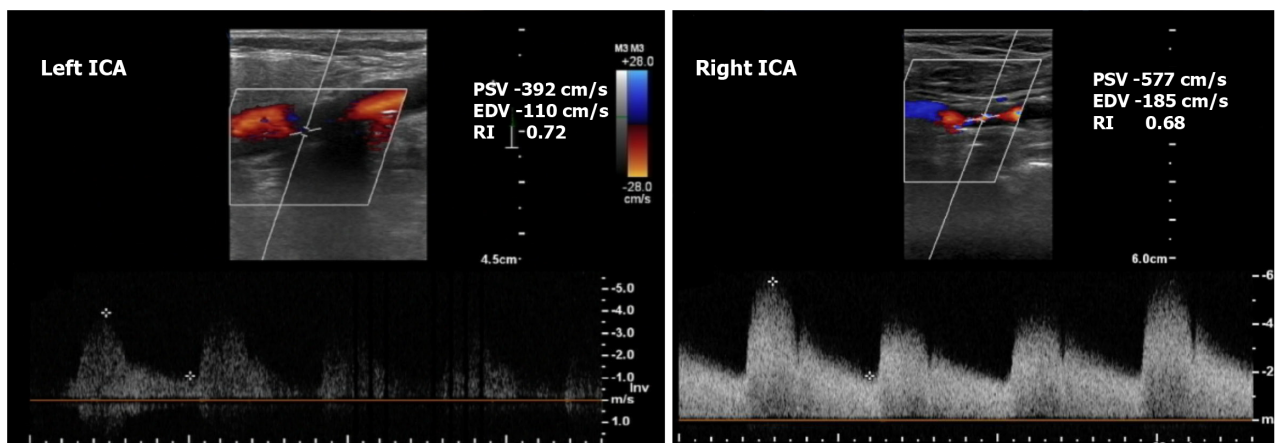
Case 2: The patient underwent right CEA and on-pump CABG.

Case 3: The patient underwent right CEA and on-pump CABG.



DOI: 10.12998/wjcc.v11.i36.8581 Copyright ©The Author(s) 2023.

Figure 3 Preoperative carotid ultrasound duplex showed right internal carotid artery stenosis of > 90% in case 3. EDV: End-diastolic velocity; PSV: Peak systolic velocity; RI: Resistance index; ICA: Internal carotid artery.



DOI: 10.12998/wjcc.v11.i36.8581 Copyright ©The Author(s) 2023.

Figure 4 Preoperative carotid ultrasound duplex in case 4. Bilateral internal carotid artery stenosis of > 90%. EDV: End-diastolic velocity; PSV: Peak systolic velocity; RI: Resistance index; ICA: Internal carotid artery.

Case 4: The patient underwent left CEA and on-pump CABG, with planned right CEA 12 mo after the CABG.

OUTCOME AND FOLLOW-UP

Case 1: The patient's postoperative course was uneventful and was discharged 1 wk after her surgery. Her last follow-up was 5 years after the surgery. She did not experience stroke or myocardial infarction (MI) during the follow-up period.

Case 2: The patient's postoperative course was uneventful, he was discharged after 2 wk. His last follow up was 4 years after the surgery. He did not experience stroke or MI during the follow-up period.

Case 3: The patient had no complications postoperatively and was discharged 5 d after the surgery. His last follow up was 1 year after the surgery. He did not experience stroke or MI during the follow-up period.

Case 4: The patient's intensive care unit stay was uneventful and he was transferred to the ward 4 d after the surgery and discharged on the 6th d postoperatively. His last follow-up was 1 year after the surgery. He did not experience stroke or MI during the follow-up period.

DISCUSSION

The risk of perioperative stroke in patients who are treated with CABG is around 2% [2]. CS is considered an independent predictor for the risk of perioperative stroke in CABG patients [3]. There are multiple causes of perioperative stroke in patients undergoing CABG, including CS, aortic embolism during manipulation, cannulation and decannulation, graft anastomosis to the aorta, platelet aggregation on cardiopulmonary bypass, hypercoagulable states, postoperative arrhythmias, and hemodynamic instability [4]. CS > 80% is found in 7% of CABG patients [2]. The risk of perioperative stroke in CABG patients with > 50% and > 80% CS is 7% and 9%, respectively [5]. The impact of perioperative stroke on patient survival is significant when compared to the survival of cardiac surgery patients with no stroke. In a meta-analysis of 174000 cardiac operations, the operative mortality of patients who suffered perioperative stroke was 29.0% *vs* 2.4% in patients who did not suffer from perioperative stroke ($P < 0.001$) [6].

The routine screening of CS in patients who are candidates for cardiac surgery is controversial. Most of the international societies support selective screening for high-risk patients [4,7]. The European Society of Cardiology (ESC) recommends screening patients who are undergoing CABG with duplex ultrasound if they have a history of recent (< 6 mo) transient ischemic attack (TIA) or stroke [4]. They also recommend screening patients with no history of recent TIA or stroke but are ≥ 70 -years-old, have multivessel coronary artery disease, have concomitant peripheral arterial disease, or have carotid bruit on examination [4]. The ESC does not recommend screening patients if they require urgent CABG and have no history of recent TIA/stroke [4]. The European Society for Vascular Surgery (ESVS) recommends screening patients who are aged > 70-years-old, have a history of TIA or stroke, carotid bruit, or left mainstem disease [7].

Prophylactic carotid intervention in patients with carotid artery stenosis is controversial. There is no strong evidence to support carotid intervention in all CABG patients with asymptomatic CS [4]. Select patients may benefit significantly from carotid intervention because it could reduce their risk of stroke-related morbidity and mortality and of a prolonged hospital stay [2]. Patients who could benefit are at a high risk of postoperative stroke, such as patients with asymptomatic severe (70%-99%) bilateral stenosis, asymptomatic severe stenosis with contralateral occlusion, or a history of prior stroke or TIA [4,7].

The surgical and endovascular options for patients are staged CEA then CABG, staged CABG then CEA, synchronous CEA plus CABG, staged carotid artery stenting (CAS) then CABG, and same day CAS then CABG. Most of the data comparing these options are from observational studies and meta-analyses. In a meta-analysis that involved 25021 patients who had undergone either combined or staged CEA and CABG, there was no difference between the two approaches in early mortality (relative risk: 1.36; 95% confidence interval: 0.78-2.36; $P = 0.27$) and postoperative stroke (relative risk: 1.14; 95% confidence interval: 0.99-1.31; $P = 0.07$) [8].

There are only two randomized controlled trials that evaluated synchronous or staged CEA in CABG patients with unilateral asymptomatic CS. Illuminati *et al* [9] randomized 185 patients with severe unilateral asymptomatic CS to one of three groups: CEA synchronous with CABG; staged CEA before CABG; or isolated CABG then delayed CEA. They concluded that staged CEA then CABG or synchronous CEA and CABG prevented stroke better than delayed CEA. The CABACS (*i.e.*, Coronary Artery Bypass graft surgery in patients with Asymptomatic Carotid Stenosis) trial randomized 129 CABG patients from 17 centers. The enrolled patients had unilateral asymptomatic severe (80%-99%) CS. They were randomized to either synchronous CEA and CABG or CABG alone. The 30-d death/stroke rate among patients who underwent the synchronous procedure was 18.5% *vs* 9.7% in patients with isolated CABG [10]. Unfortunately, this trial was terminated prematurely after funding withdrawal. However, the authors concluded that the very high rate of perioperative stroke does not justify the synchronous approach in patients with severe asymptomatic CS [10].

One of the options to manage this population of patients is either same-day or staged CAS. This modality may be beneficial because it is less invasive compared to conventional CEA. However, CAS can complicate the management of CABG patients because dual-antiplatelet therapy is needed after CAS. This could increase the risk of bleeding during the CABG procedure or increase the risk of MI if CABG was delayed for the administration of dual-antiplatelets. In a systematic review that included 11 studies that evaluated the outcome of 760 staged or same-day CAS plus CABG procedures, the majority of the patients (87%) were asymptomatic. The overall mortality rate was 5.5%, and the risk of suffering any stroke was 4.2% [11]. This review also observed that CABG performed within 48 h of a CAS procedure was not associated with a significant risk compared to CABG performed 2 wk after a CAS procedure [11].

The most recent guidelines emphasize that the management of patients should be individualized and determined by a multidisciplinary team [4]. The ESC recommends that patients who will be treated with a CABG procedure and who have a recent history of stroke or TIA should be considered for carotid revascularization if there is 50%-99% CS, without specifying the means for revascularization [4]. They also recommend that prophylactic carotid revascularization may be considered in a patient with bilateral 70%-99% CS or 70%-99% CS and contralateral occlusion [4]. On the other hand, the most recent ESVS guidelines were more specific in regard to the modality and timing of revascularization [7]. The ESVS recommends staged or synchronous CEA and CABG in patients who have a recent history of TIA or stroke with ipsilateral 50%-99% CS [7]. It also recommends staged or synchronous CAS/CEA and CABG in patients who are asymptomatic and who have either bilateral 70%-99% CS or 70%-99% CS and contralateral occlusion [7].

CONCLUSION

In conclusion, CS is prevalent among patients with coronary artery disease who are undergoing CABG. Screening for CS is indicated in patients with high-risk features, such as old age and left mainstem disease. The indications, modality, and timing for carotid revascularization in CABG patients is still controversial, and more evidence is needed to decide on the

best management plan for this patient population.

FOOTNOTES

Author contributions: AlGhamdi FK, Altoijry A, AlQahtani A, Aldossary MY, AlSheikh SO, Iqbal K, and Alayadhi WA contributed to the study design, literature review, and manuscript writing; AlGhamdi FK, AlQahtani A, and Aldossary MY contributed to the data collection and analysis; and all authors read and approved the final manuscript.

Informed consent statement: Written informed consent was obtained from all of the patients for publication of this case series and accompanying images. A copy of the written consent is available for review upon request.

Conflict-of-interest statement: All the authors report no relevant conflicts of interest for this article.

CARE Checklist (2016) statement: The authors have read the CARE Checklist (2016), and the manuscript was prepared and revised according to the CARE Checklist (2016).

Open-Access: This article is an open-access article that was selected by an in-house editor and fully peer-reviewed by external reviewers. It is distributed in accordance with the Creative Commons Attribution NonCommercial (CC BY-NC 4.0) license, which permits others to distribute, remix, adapt, build upon this work non-commercially, and license their derivative works on different terms, provided the original work is properly cited and the use is non-commercial. See: <https://creativecommons.org/licenses/by-nc/4.0/>

Country/Territory of origin: Saudi Arabia

ORCID number: Faisal Khader AlGhamdi 0000-0001-5966-888X; Abdulmajeed Altoijry 0000-0002-1868-0265; Mohammed Yousef Aldossary 0000-0002-7580-341X; Sultan Omar AlSheikh 0000-0003-4528-1662; Kaisor Iqbal 0000-0002-9797-6485.

S-Editor: Wang JJ

L-Editor: A

P-Editor: Zhao S

REFERENCES

- 1 **Vaduganathan M**, Mensah GA, Turco JV, Fuster V, Roth GA. The Global Burden of Cardiovascular Diseases and Risk: A Compass for Future Health. *J Am Coll Cardiol* 2022; **80**: 2361-2371 [PMID: 36368511 DOI: 10.1016/j.jacc.2022.11.005]
- 2 **Naylor AR**, Mehta Z, Rothwell PM, Bell PR. Carotid artery disease and stroke during coronary artery bypass: a critical review of the literature. *Eur J Vasc Endovasc Surg* 2002; **23**: 283-294 [PMID: 11991687 DOI: 10.1053/ejvs.2002.1609]
- 3 **Poi MJ**, Echeverria A, Lin PH. Contemporary Management of Patients with Concomitant Coronary and Carotid Artery Disease. *World J Surg* 2018; **42**: 272-282 [PMID: 28785837 DOI: 10.1007/s00268-017-4103-7]
- 4 **Aboyans V**, Ricco JB, Bartelink MEL, Björck M, Brodmann M, Cohnert T, Collet JP, Czerny M, De Carlo M, Debus S, Espinola-Klein C, Kahan T, Kownator S, Mazzolai L, Naylor AR, Roffi M, Röther J, Sprynger M, Tendera M, Tepe G, Venermo M, Vlachopoulos C, Desormais I; ESC Scientific Document Group. 2017 ESC Guidelines on the Diagnosis and Treatment of Peripheral Arterial Diseases, in collaboration with the European Society for Vascular Surgery (ESVS): Document covering atherosclerotic disease of extracranial carotid and vertebral, mesenteric, renal, upper and lower extremity arteries Endorsed by: the European Stroke Organization (ESO) The Task Force for the Diagnosis and Treatment of Peripheral Arterial Diseases of the European Society of Cardiology (ESC) and of the European Society for Vascular Surgery (ESVS). *Eur Heart J* 2018; **39**: 763-816 [PMID: 28886620 DOI: 10.1093/eurheartj/ehx095]
- 5 **Naylor AR**, Bown MJ. Stroke after cardiac surgery and its association with asymptomatic carotid disease: an updated systematic review and meta-analysis. *Eur J Vasc Endovasc Surg* 2011; **41**: 607-624 [PMID: 21396854 DOI: 10.1016/j.ejvs.2011.02.016]
- 6 **Gaudino M**, Rahouma M, Di Mauro M, Yanagawa B, Abouarab A, Demetres M, Di Franco A, Arisha MJ, Ibrahim DA, Baudo M, Girardi LN, Fremes S. Early Versus Delayed Stroke After Cardiac Surgery: A Systematic Review and Meta-Analysis. *J Am Heart Assoc* 2019; **8**: e012447 [PMID: 31215306 DOI: 10.1161/JAHA.119.012447]
- 7 **Naylor R**, Rantner B, Ancetti S, de Borst GJ, De Carlo M, Halliday A, Kakkos SK, Markus HS, McCabe DJH, Sillesen H, van den Berg JC, Vega de Ceniga M, Venermo MA, Vermassen FEG; Esvs Guidelines Committee, Antoniou GA, Bastos Goncalves F, Björck M, Chakfe N, Coscas R, Dias NV, Dick F, Hinchliffe RJ, Kolh P, Koncar IB, Lindholt JS, Mees BME, Resch TA, Trimarchi S, Tulamo R, Twine CP, Wanhainen A, Document Reviewers, Bellmunt-Montoya S, Bulbulia R, Darling RC 3rd, Eckstein HH, Giannoukas A, Koelemay MJW, Lindström D, Schermerhorn M, Stone DH. Editor's Choice - European Society for Vascular Surgery (ESVS) 2023 Clinical Practice Guidelines on the Management of Atherosclerotic Carotid and Vertebral Artery Disease. *Eur J Vasc Endovasc Surg* 2023; **65**: 7-111 [PMID: 35598721 DOI: 10.1016/j.ejvs.2022.04.011]
- 8 **Sharma V**, Deo SV, Park SJ, Joyce LD. Meta-analysis of staged versus combined carotid endarterectomy and coronary artery bypass grafting. *Ann Thorac Surg* 2014; **97**: 102-109 [PMID: 24090581 DOI: 10.1016/j.athoracsur.2013.07.091]
- 9 **Illuminati G**, Ricco JB, Calio F, Pacile MA, Miraldi F, Frati G, Macrina F, Toscano M. Short-term results of a randomized trial examining timing of carotid endarterectomy in patients with severe asymptomatic unilateral carotid stenosis undergoing coronary artery bypass grafting. *J Vasc Surg* 2011; **54**: 993-9; discussion 998 [PMID: 21703806 DOI: 10.1016/j.jvs.2011.03.284]
- 10 **Weimar C**, Bilbils K, Rekowski J, Holst T, Beyersdorf F, Breuer M, Dahm M, Diegeler A, Kowalski A, Martens S, Mohr FW, Ondrášek J, Reiter B, Roth P, Seipelt R, Siggekow M, Steinhoff G, Moritz A, Wilhelm M, Wimmer-Greinecker G, Diener HC, Jakob H, Ose C, Scherag A, Knipp SC; CABACS Trial Investigators. Safety of Simultaneous Coronary Artery Bypass Grafting and Carotid Endarterectomy Versus

Isolated Coronary Artery Bypass Grafting: A Randomized Clinical Trial. *Stroke* 2017; **48**: 2769-2775 [PMID: 28916664 DOI: 10.1161/STROKEAHA.117.017570]

- 11 **Naylor AR**, Mehta Z, Rothwell PM. A systematic review and meta-analysis of 30-day outcomes following staged carotid artery stenting and coronary bypass. *Eur J Vasc Endovasc Surg* 2009; **37**: 379-387 [PMID: 19201215 DOI: 10.1016/j.ejvs.2008.12.011]



Published by **Baishideng Publishing Group Inc**
7041 Koll Center Parkway, Suite 160, Pleasanton, CA 94566, USA

Telephone: +1-925-3991568

E-mail: bpgoffice@wjgnet.com

Help Desk: <https://www.f6publishing.com/helpdesk>

<https://www.wjgnet.com>

