

World Journal of *Clinical Cases*

World J Clin Cases 2023 February 6; 11(4): 719-978



MINIREVIEWS

- 719 Development and refinement of diagnostic and therapeutic strategies for managing patients with cardiogenic stroke: An arduous journey
Fan ZX, Liu RX, Liu GZ
- 725 Portal vein aneurysm-etiology, multimodal imaging and current management
Kurtcehajic A, Zerem E, Alibegovic E, Kunosic S, Hujdurovic A, Fejzic JA

ORIGINAL ARTICLE

Clinical and Translational Research

- 738 CD93 serves as a potential biomarker of gastric cancer and correlates with the tumor microenvironment
Li Z, Zhang XJ, Sun CY, Fei H, Li ZF, Zhao DB

Retrospective Study

- 756 Chest computed tomography findings of the Omicron variants of SARS-CoV-2 with different cycle threshold values
Ying WF, Chen Q, Jiang ZK, Hao DG, Zhang Y, Han Q
- 764 Major depressive disorders in patients with inflammatory bowel disease and rheumatoid arthritis
Haider MB, Basida B, Kaur J
- 780 Selective laser trabeculoplasty as adjunctive treatment for open-angle glaucoma *vs* following incisional glaucoma surgery in Chinese eyes
Zhu J, Guo J
- 788 Efficacy of transvaginal ultrasound-guided local injections of absolute ethanol for ectopic pregnancies with intrauterine implantation sites
Kakinuma T, Kakinuma K, Matsuda Y, Yanagida K, Ohwada M, Kaijima H

Clinical Trials Study

- 797 Efficacy of incremental loads of cow's milk as a treatment for lactose malabsorption in Japan
Hasegawa M, Okada K, Nagata S, Sugihara S

Observational Study

- 809 Transdiagnostic considerations of mental health for the post-COVID era: Lessons from the first surge of the pandemic
Goldstein Ferber S, Shoval G, Rossi R, Trezza V, Di Lorenzo G, Zalsman G, Weller A, Mann JJ
- 821 Effect of patient COVID-19 vaccine hesitancy on hospital care team perceptions
Caspi I, Freund O, Pines O, Elkana O, Ablin JN, Bornstein G

Randomized Clinical Trial

- 830 Improvement of inflammatory response and gastrointestinal function in perioperative of cholelithiasis by Modified Xiao-Cheng-Qi decoction
Sun BF, Zhang F, Chen QP, Wei Q, Zhu WT, Ji HB, Zhang XY

CASE REPORT

- 844 Metagenomic next-generation sequencing for pleural effusions induced by viral pleurisy: A case report
Liu XP, Mao CX, Wang GS, Zhang MZ
- 852 *Clostridium perfringens* gas gangrene caused by closed abdominal injury: A case report and review of the literature
Li HY, Wang ZX, Wang JC, Zhang XD
- 859 Is lymphatic invasion of microrectal neuroendocrine tumors an incidental event?: A case report
Ran JX, Xu LB, Chen WW, Yang HY, Weng Y, Peng YM
- 866 *Pneumocystis jirovecii* diagnosed by next-generation sequencing of bronchoscopic alveolar lavage fluid: A case report and review of literature
Cheng QW, Shen HL, Dong ZH, Zhang QQ, Wang YF, Yan J, Wang YS, Zhang NG
- 874 Identification of 1q21.1 microduplication in a family: A case report
Huang TT, Xu HF, Wang SY, Lin WX, Tung YH, Khan KU, Zhang HH, Guo H, Zheng G, Zhang G
- 883 Double pigtail catheter reduction for seriously displaced intravenous infusion port catheter: A case report
Liu Y, Du DM
- 888 Thyroid storm in a pregnant woman with COVID-19 infection: A case report and review of literatures
Kim HE, Yang J, Park JE, Baek JC, Jo HC
- 896 Computed tomography diagnosed left ovarian venous thrombophlebitis after vaginal delivery: A case report
Wang JJ, Hui CC, Ji YD, Xu W
- 903 Preoperative 3D reconstruction and fluorescent indocyanine green for laparoscopic duodenum preserving pancreatic head resection: A case report
Li XL, Gong LS
- 909 Unusual presentation of systemic lupus erythematosus as hemophagocytic lymphohistiocytosis in a female patient: A case report
Peng LY, Liu JB, Zuo HJ, Shen GF
- 918 Polyarteritis nodosa presenting as leg pain with resolution of positron emission tomography-images: A case report
Kang JH, Kim J
- 922 Easily misdiagnosed complex Klippel-Trenaunay syndrome: A case report
Li LL, Xie R, Li FQ, Huang C, Tuo BG, Wu HC

- 931** Benign lymphoepithelial cyst of parotid gland without human immunodeficiency virus infection: A case report
Liao Y, Li YJ, Hu XW, Wen R, Wang P
- 938** Epithelioid trophoblastic tumor of the lower uterine segment and cervical canal: A case report
Yuan LQ, Hao T, Pan GY, Guo H, Li DP, Liu NF
- 945** Treatment of portosystemic shunt-borne hepatic encephalopathy in a 97-year-old woman using balloon-occluded retrograde transvenous obliteration: A case report
Nishi A, Kenzaka T, Sogi M, Nakaminato S, Suzuki T
- 952** Development of Henoch-Schoenlein purpura in a child with idiopathic hypereosinophilia syndrome with multiple thrombotic onset: A case report
Xu YY, Huang XB, Wang YG, Zheng LY, Li M, Dai Y, Zhao S
- 962** Three cases of jejunal tumors detected by standard upper gastrointestinal endoscopy: A case series
Lee J, Kim S, Kim D, Lee S, Ryu K
- 972** Omental infarction diagnosed by computed tomography, missed with ultrasonography: A case report
Hwang JK, Cho YJ, Kang BS, Min KW, Cho YS, Kim YJ, Lee KS

ABOUT COVER

Editorial Board Member of *World Journal of Clinical Cases*, Sahand Samieirad, DDS, MS, MSc, Associate Professor, Oral and Maxillofacial Surgery Department, Mashhad Dental School, Mashhad University of Medical Sciences, Mashhad 9178613111, Iran. samieerads@mums.ac.ir

AIMS AND SCOPE

The primary aim of *World Journal of Clinical Cases* (WJCC, *World J Clin Cases*) is to provide scholars and readers from various fields of clinical medicine with a platform to publish high-quality clinical research articles and communicate their research findings online.

WJCC mainly publishes articles reporting research results and findings obtained in the field of clinical medicine and covering a wide range of topics, including case control studies, retrospective cohort studies, retrospective studies, clinical trials studies, observational studies, prospective studies, randomized controlled trials, randomized clinical trials, systematic reviews, meta-analysis, and case reports.

INDEXING/ABSTRACTING

The WJCC is now abstracted and indexed in Science Citation Index Expanded (SCIE, also known as SciSearch®), Journal Citation Reports/Science Edition, Current Contents®/Clinical Medicine, PubMed, PubMed Central, Scopus, Reference Citation Analysis, China National Knowledge Infrastructure, China Science and Technology Journal Database, and Superstar Journals Database. The 2022 Edition of Journal Citation Reports® cites the 2021 impact factor (IF) for WJCC as 1.534; IF without journal self cites: 1.491; 5-year IF: 1.599; Journal Citation Indicator: 0.28; Ranking: 135 among 172 journals in medicine, general and internal; and Quartile category: Q4. The WJCC's CiteScore for 2021 is 1.2 and Scopus CiteScore rank 2021: General Medicine is 443/826.

RESPONSIBLE EDITORS FOR THIS ISSUE

Production Editor: Si Zhao; Production Department Director: Xu Guo; Editorial Office Director: Jin-Lei Wang.

NAME OF JOURNAL

World Journal of Clinical Cases

ISSN

ISSN 2307-8960 (online)

LAUNCH DATE

April 16, 2013

FREQUENCY

Thrice Monthly

EDITORS-IN-CHIEF

Bao-Gan Peng, Jerzy Tadeusz Chudek, George Kontogeorgos, Maurizio Serati, Ja Hyeon Ku

EDITORIAL BOARD MEMBERS

<https://www.wjgnet.com/2307-8960/editorialboard.htm>

PUBLICATION DATE

February 6, 2023

COPYRIGHT

© 2023 Baishideng Publishing Group Inc

INSTRUCTIONS TO AUTHORS

<https://www.wjgnet.com/bpg/gerinfo/204>

GUIDELINES FOR ETHICS DOCUMENTS

<https://www.wjgnet.com/bpg/GerInfo/287>

GUIDELINES FOR NON-NATIVE SPEAKERS OF ENGLISH

<https://www.wjgnet.com/bpg/gerinfo/240>

PUBLICATION ETHICS

<https://www.wjgnet.com/bpg/GerInfo/288>

PUBLICATION MISCONDUCT

<https://www.wjgnet.com/bpg/gerinfo/208>

ARTICLE PROCESSING CHARGE

<https://www.wjgnet.com/bpg/gerinfo/242>

STEPS FOR SUBMITTING MANUSCRIPTS

<https://www.wjgnet.com/bpg/GerInfo/239>

ONLINE SUBMISSION

<https://www.f6publishing.com>

Treatment of portosystemic shunt-borne hepatic encephalopathy in a 97-year-old woman using balloon-occluded retrograde transvenous obliteration: A case report

Akihiro Nishi, Tsuneaki Kenzaka, Misa Sogi, Shuichiro Nakaminato, Takahiro Suzuki

Specialty type: Gastroenterology and hepatology

Provenance and peer review: Unsolicited article; Externally peer reviewed.

Peer-review model: Single blind

Peer-review report's scientific quality classification

Grade A (Excellent): 0
Grade B (Very good): B, B
Grade C (Good): 0
Grade D (Fair): D
Grade E (Poor): 0

P-Reviewer: Methawasin K, Thailand; Wang YT, China

Received: October 17, 2022

Peer-review started: October 17, 2022

First decision: December 26, 2022

Revised: December 30, 2022

Accepted: January 12, 2023

Article in press: January 12, 2023

Published online: February 6, 2023



Akihiro Nishi, Misa Sogi, General Medicine, Awa Regional Medical Center, Tateyama 2940014, Chiba, Japan

Tsuneaki Kenzaka, Division of Community Medicine and Career Development, Kobe University Graduate School of Medicine, Kobe 6500017, Hyogo, Japan

Shuichiro Nakaminato, Takahiro Suzuki, Department of Radiology, Kameda Medical Center, Kamogawa 2968602, Chiba, Japan

Corresponding author: Akihiro Nishi, MD, Doctor, General Medicine, Awa Regional Medical Center, 1155 Yamamoto, Tateyama 2940014, Chiba, Japan. akihiro.nishi24@gmail.com

Abstract

BACKGROUND

Hyperammonemia and hepatic encephalopathy are common in patients with portosystemic shunts. Surgical shunt occlusion has been standard treatment, although recently the less invasive balloon-occluded retrograde transvenous obliteration (B-RTO) has gained increasing attention. Thus far, there have been no reports on the treatment of portosystemic shunts with B-RTO in patients aged over 90 years. In this study, we present a case of hepatic encephalopathy caused by shunting of the left common iliac and inferior mesenteric veins, successfully treated with B-RTO.

CASE SUMMARY

A 97-year-old woman with no history of liver disease was admitted to our hospital because of disturbance of consciousness. She had no jaundice, spider angioma, palmar erythema, hepatosplenomegaly, or asterixis. Her blood tests showed hyperammonemia, and abdominal contrast-enhanced computed tomography revealed a portosystemic shunt running between the left common iliac vein and the inferior mesenteric vein. She was diagnosed with hepatic encephalopathy secondary to a portosystemic shunt. The patient did not improve with conservative treatment: Lactulose, rifaximin, and a low-protein diet. B-RTO was performed, which resulted in shunt closure and improvement in hyperammonemia and disturbance of consciousness. Moreover, there was no abdominal pain or elevated levels of liver enzymes due to complications. The patient was discharged without further consciousness disturbance.

CONCLUSION

Portosystemic shunt-borne hepatic encephalopathy must be considered in the differential diagnosis for consciousness disturbance, including abnormal behavior and speech.

Key Words: Hepatic encephalopathy; Hyperammonemia; Portosystemic shunt; Balloon-occluded retrograde transvenous obliteration; Elderly; Case report

©The Author(s) 2023. Published by Baishideng Publishing Group Inc. All rights reserved.

Core Tip: Hyperammonemia and hepatic encephalopathy are common with portosystemic shunts. In this case, hepatic encephalopathy caused by shunting of the left common iliac and inferior mesenteric veins was successfully treated with balloon-occluded retrograde transvenous obliteration (B-RTO). A 97-year-old woman was diagnosed with hepatic encephalopathy secondary to a portosystemic shunt. The patient did not improve with conservative treatment: Lactulose, rifaximin, and a low-protein diet. B-RTO was performed, resulting in shunt closure and improvement in hyperammonemia and disturbance of consciousness. The patient was discharged without further consciousness disturbance. Portosystemic shunt-borne hepatic encephalopathy must be considered in the differential diagnosis for consciousness disturbance, including abnormal behavior and speech.

Citation: Nishi A, Kenzaka T, Sogi M, Nakaminato S, Suzuki T. Treatment of portosystemic shunt-borne hepatic encephalopathy in a 97-year-old woman using balloon-occluded retrograde transvenous obliteration: A case report. *World J Clin Cases* 2023; 11(4): 945-951

URL: <https://www.wjgnet.com/2307-8960/full/v11/i4/945.htm>

DOI: <https://dx.doi.org/10.12998/wjcc.v11.i4.945>

INTRODUCTION

Hepatic encephalopathy is defined as impaired brain function caused by liver insufficiency and/or portosystemic shunt[1]. Portosystemic shunts are known to cause hyperammonemia without liver dysfunction[2]. A portosystemic shunt is a condition in which portal blood flows directly into the systemic circulatory system. In such a condition, ammonia produced in the digestive tract is not metabolized in the liver, resulting in hyperammonemia and hepatic encephalopathy. Treatment methods include medical therapy, surgical shunt occlusion, and shunt embolization with interventional radiology (IVR)[2]. Surgical shunt occlusion or IVR is the treatment of choice when there is no improvement with medical treatment, or when complete cure is desired. In recent years, balloon-occluded retrograde transvenous obliteration (B-RTO) has attracted attention owing to its less invasive nature. However, thus far, there have been no reports of B-RTO treatment for cases of portosystemic shunts in very elderly patients, *i.e.*, those aged above 90 years.

In this study, we report a case of hepatic encephalopathy caused by shunting of the left common iliac and inferior mesenteric veins in a 97-year-old patient whose condition improved after B-RTO treatment.

CASE PRESENTATION

Chief complaints

A 97-year-old Japanese woman exhibited abnormal behavior and disorganized speech for 10 d before admission.

History of present illness

Ten days prior to admission, the patient was agitated and spoke incomprehensible words to a neighbor. Her family met her 6 d prior to admission but noticed no unusual behavior or speech. Four days prior to admission, she exhibited strange behavior, saying that she did not know how to eat eggs and walking out with an egg clutched in her hand. Two days prior to admission, she lost spontaneity and had urinary incontinence, which she normally does not have. On the day of admission, her speech was impaired, and her family admitted her to the emergency room of our hospital.

History of past illness

She had a medical history of cholecystectomy and distal gastrectomy for gastric cancer, with no history

of liver disease or cognitive dysfunction.

Personal and family history

She did not take any medications or consume alcohol. She lived alone and had independent activities of daily living; her food intake and defecation status were unknown.

Physical examination

Upon examination, she was disorientated, only answered “yes” to questions, and could not follow directions. Her vital signs were as follows: Glasgow Coma Scale score, 13 (E4V4M5); blood pressure, 157/111 mmHg; body temperature, 36.6 °C; pulse rate, 100 beats/min; respiratory rate, 20 breaths/min; and oxygen saturation, 99% on ambient air. Physical examination revealed no jaundice, spider angioma, palmar erythema, hepatosplenomegaly, or asterixis.

Laboratory examinations

Blood test results showed elevated serum ammonia levels at 125 µg/dL (normal range: 12–66 µg/dL) (Table 1). Cerebrospinal fluid examination results were normal, and blood cultures were negative.

Imaging examinations

Computed tomography (CT) of the head and magnetic resonance imaging showed no abnormalities.

FURTHER DIAGNOSTIC WORK-UP

On day 2 after admission, her serum ammonia levels were further elevated to 251 µg/dL and electroencephalography showed triphasic waves. On day 3, an abdominal contrast-enhanced CT scan revealed shunting between the left common iliac vein and the inferior mesenteric vein (Figure 1).

FINAL DIAGNOSIS

Based on the extent of hyperammonemia and abdominal contrast-enhanced CT findings, a diagnosis of hepatic encephalopathy due to an extrahepatic portosystemic shunt was made.

TREATMENT

As conservative therapy, 39 g/d oral lactulose was started on day 4, and 1200 mg/d oral rifaximin and a low-protein diet were started on day 13. Her serum ammonia levels decreased to 80 µg/dL on day 14. However, there was little improvement in the patient’s level of consciousness. Therefore, B-RTO was performed under local anesthesia on day 20, and coils were placed in the shunts between the left common iliac vein and the inferior mesenteric vein (Figure 2). On day 21, contrast-enhanced CT confirmed no coil displacement, and shunt closure was achieved. By contrast, mild edematous changes were observed in the descending and sigmoid colons. Moreover, there was a partial thrombus in the inferior mesenteric vein; however, anticoagulants were not administered because of the patient’s advanced age. We followed the patient carefully, noting abdominal pain and elevated liver enzymes.

OUTCOME AND FOLLOW-UP

Her level of consciousness improved on day 21 (the day after B-RTO). Her serum ammonia levels were 21 µg/dL on day 28 and remained within the normal range throughout subsequent hospitalizations. There was no abdominal pain or elevated levels of liver enzymes due to complications. The patient was discharged on day 65 without any further disturbance of consciousness.

DISCUSSION

We report the case of a 97-year-old patient with hepatic encephalopathy due to shunting of the left common iliac and inferior mesenteric veins. To the best of our knowledge, this is the first case in which B-RTO was performed for a portosystemic shunt in a very elderly patient aged above 90 years.

On the basis of physical examination, hematology, and imaging findings, this case had no liver dysfunction or cirrhosis. The imaging findings showed shunting of the left common iliac vein and the

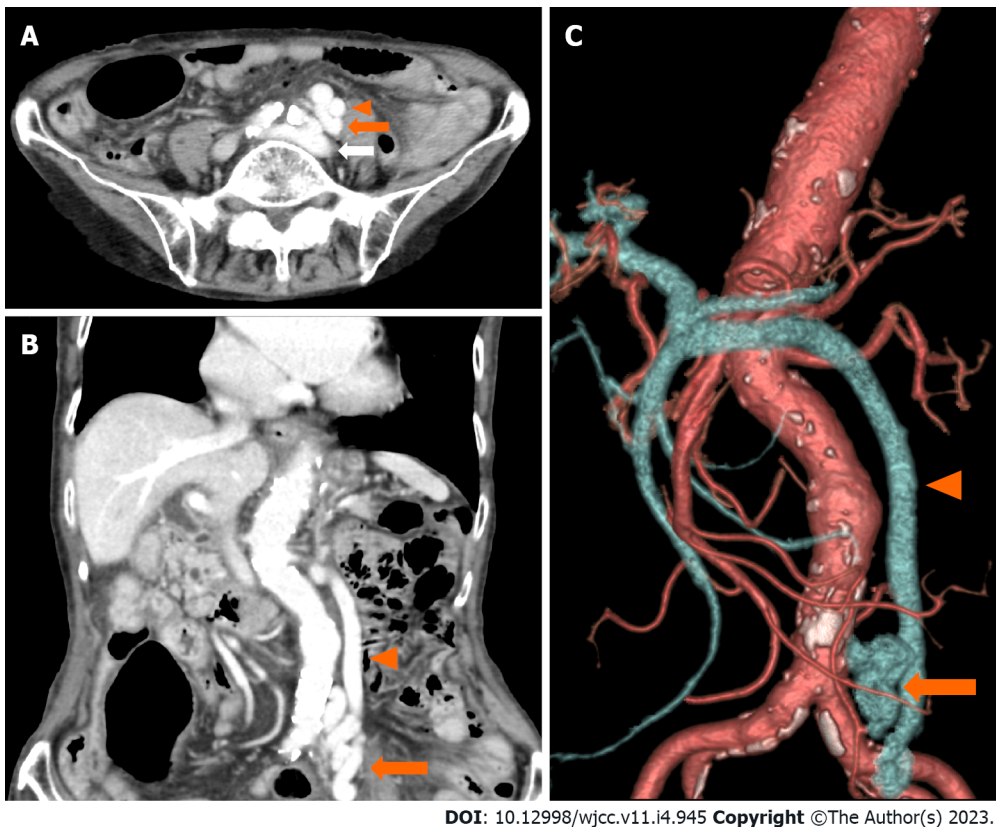
Table 1 Laboratory data on admission

Parameter	Recorded value	Standard value
White blood cell count	8500/ μ L	3500-8500/ μ L
Hemoglobin	14.5 g/dL	12-16 g/dL
Platelet count	16.5×10^4 / μ L	$12-28 \times 10^4$ / μ L
Prothrombin time	15.2 s	10-13 s
Prothrombin time	60.8%	70-130%
Activated partial thromboplastin time	30.8 s	25.3-37.6 s
C-reactive protein	0.1 mg/L	≤ 0.5 mg/dL
Total protein	7.1 g/dL	6.5-8.3 g/dL
Albumin	4.2 g/dL	3.8-5.3 g/dL
Total bilirubin	1.4 mg/dL	0.2-1.2 mg/dL
Aspartate aminotransferase	35 U/L	7-34 U/L
Alanine aminotransferase	22 U/L	4-43 U/L
Lactate dehydrogenase	299 U/L	119-229 U/L
Alkaline phosphatase	128 U/L	38-113 U/L
γ -Glutamyl transpeptidase	16 U/L	6-30 U/L
Blood urea nitrogen	24 mg/dL	8-20 mg/dL
Creatinine	0.66 mg/dL	≤ 0.80 mg/dL
Sodium	145 mEq/L	139-146 mEq/L
Potassium	4.1 mEq/L	3.7-4.8 mEq/L
Chloride	109 mEq/L	101-109 mEq/L
Calcium	9.3 mg/dL	8.6-10.2 mg/dL
Glucose	102 mg/dL	70-109 mg/dL
TSH	1.06 μ IU/mL	0.35-4.94 μ IU/mL
Free T4	1.24 ng/dL	0.70-1.48 ng/dL
Cortisol	20.8 μ g/dL	5.6-21.3 μ g/dL
Vitamin B1	3.0 μ g/dL	2.6-5.8 μ g/dL
Ammonia	125 μ g/dL	12-66 μ g/dL
HBs-Ag	(-)	
HCV-Ab	(-)	

TSH: Thyroid-stimulating hormone; HBs-Ag: Hepatitis B virus surface antigen; HCV-Ab: Hepatitis C virus antibody.

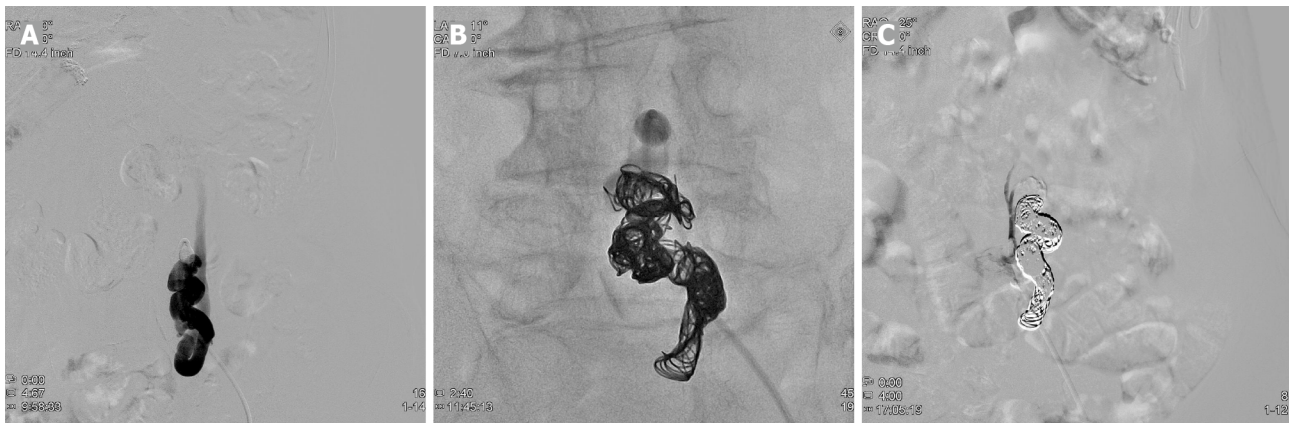
inferior mesenteric vein, suggesting that the portosystemic shunt was the cause of hepatic encephalopathy. Portosystemic shunts are classified according to their location as type I (intrahepatic), type II (intrahepatic and extrahepatic), type III (extrahepatic), type IV (extrahepatic, portal hypertension), and type V (extrahepatic, absence of the portal vein)[2]. A type III (extrahepatic) portosystemic shunt, to which this case belongs, is the most frequent, accounting for 48.9% of all types, with an average age of onset of 57.4 years[2]. There are congenital and acquired causes of this type of shunt formation, with congenital causes being malformations or retained embryonal vascular vessels and the acquired causes being complications related to abdominal surgery[2]. The patient in this case had a history of cholecystectomy and distal gastrectomy, which may have resulted in the formation of an acquired shunt; however, the cause was difficult to determine because of the lack of comparative images from the past.

Surgical shunt occlusion is the curative treatment for portosystemic shunts; however, it is generally invasive and does not necessarily provide good outcomes[1]. In our case, complications and prolonged hospitalization were concerning. In such cases, IVR is an alternative treatment, and recently cases wherein patients were treated with B-RTO have been reported[3-6]. B-RTO is considered less invasive



DOI: 10.12998/wjcc.v11.i4.945 Copyright ©The Author(s) 2023.

Figure 1 Abdominal computed tomography scan with contrast enhancement. A-C: Images showing a portosystemic shunt (orange arrow) running between the left common iliac vein (white arrow) and the inferior mesenteric vein (arrowhead).



DOI: 10.12998/wjcc.v11.i4.945 Copyright ©The Author(s) 2023.

Figure 2 Angiography images before and after embolization. A: A balloon catheter is advanced into the portosystemic shunt through the left femoral vein; B: The shunt is filled with the coil; C: The shunt is completely obliterated.

than surgical treatment, although it may cause complications, such as pleural effusion, ascites, thrombosis, pulmonary embolism, and worsening of esophageal varices[2,7-9]. Anticoagulant administration to elderly patients is particularly challenging owing to the risk of bleeding, and indications should be carefully considered. To the best of our knowledge, the oldest patient who underwent B-RTO for a portosystemic shunt was 86 years old[5]. B-RTO has no age-related restrictions on its indications and does not require special treatment on account of patients' advanced age[10]. Although this patient was 97 years old, she had no serious comorbidities and was able to perform her daily activities. Therefore, we thought that there was great merit in performing curative treatment and B-RTO.

Hepatic encephalopathy is one of the differential diagnoses of disturbance of consciousness, and it is common to measure serum ammonia levels when there is a history of liver disease or physical findings suggestive of liver dysfunction[11]. By contrast, shock, gastrointestinal bleeding, vesicorectal fistulas, drugs such as valproic acid, and obstructive urinary tract infections caused by urease-producing

bacteria may lead to hyperammonemia, even in the absence of liver diseases[12,13]. Portosystemic shunts also cause hyperammonemia[14].

Although there was no history of liver disease or findings suggestive of liver dysfunction in this case, measurement of serum ammonia levels led to diagnosis and subsequent treatment.

CONCLUSION

This is the first report of B-RTO performed in a patient aged > 90 years with a portosystemic shunt. It is important to consider hepatic encephalopathy due to a portosystemic shunt as a differential diagnosis of disturbance of consciousness, including abnormal behavior and disorganized speech.

FOOTNOTES

Author contributions: Nishi A managed the case and wrote and revised the manuscript; Kenzaka T, Sogi M, Nakaminato S, and Suzuki T assisted with the preparation and revision of the manuscript; all authors read and approved the final manuscript.

Informed consent statement: Informed written consent was obtained from the patients for the publication of this report and any accompanying images.

Conflict-of-interest statement: The authors declare that they have no competing interests.

CARE Checklist (2016) statement: The authors have read the CARE Checklist (2016), and the manuscript was prepared and revised according to the CARE Checklist (2016).

Open-Access: This article is an open-access article that was selected by an in-house editor and fully peer-reviewed by external reviewers. It is distributed in accordance with the Creative Commons Attribution NonCommercial (CC BY-NC 4.0) license, which permits others to distribute, remix, adapt, build upon this work non-commercially, and license their derivative works on different terms, provided the original work is properly cited and the use is non-commercial. See: <https://creativecommons.org/licenses/by-nc/4.0/>

Country/Territory of origin: Japan

ORCID number: Akihiro Nishi 0000-0003-4140-4880; Tsuneaki Kenzaka 0000-0002-3120-6605; Misa Sogi 0000-0001-6555-2015; Shuichi Nakaminato 0000-0003-3413-1941; Takahiro Suzuki 0000-0003-2126-5959.

S-Editor: Chen YL

L-Editor: A

P-Editor: Chen YL

REFERENCES

- 1 Vilstrup H, Amodio P, Bajaj J, Cordoba J, Ferenci P, Mullen KD, Weissenborn K, Wong P. Hepatic encephalopathy in chronic liver disease: 2014 Practice Guideline by the American Association for the Study of Liver Diseases and the European Association for the Study of the Liver. *Hepatology* 2014; **60**: 715-735 [PMID: 25042402 DOI: 10.1002/hep.27210]
- 2 Watanabe A. Portal-systemic encephalopathy in non-cirrhotic patients: classification of clinical types, diagnosis and treatment. *J Gastroenterol Hepatol* 2000; **15**: 969-979 [PMID: 11059925 DOI: 10.1046/j.1440-1746.2000.02283.x]
- 3 Asakura T, Ito N, Sohma T, Mori N. Portosystemic Encephalopathy without Liver Cirrhosis Masquerading as Depression. *Intern Med* 2015; **54**: 1619-1622 [PMID: 26134193 DOI: 10.2169/internalmedicine.54.3800]
- 4 Yamagami T, Yoshimatsu R, Miura H, Hasebe T, Koide K. Hepatic encephalopathy due to intrahepatic portosystemic venous shunt successfully treated by balloon occluded retrograde transvenous embolization with GDCs. *Acta Radiol Short Rep* 2012; **1** [PMID: 23986827 DOI: 10.1258/arsr.2012.120041]
- 5 Miyata K, Tamai H, Uno A, Nakao R, Muroki T, Nasu T, Kawashima A, Nakao T, Kondo M, Ichinose M. Congenital portal systemic encephalopathy misdiagnosed as senile dementia. *Intern Med* 2009; **48**: 321-324 [PMID: 19252354 DOI: 10.2169/internalmedicine.48.1777]
- 6 Tanaka O, Ishihara K, Oyama H, Harusato A, Yamaguchi T, Ozawa M, Nakano K, Yamagami T, Nishimura T. Successful portal-systemic shunt occlusion with balloon-occluded retrograde transvenous obliteration for portosystemic encephalopathy without liver cirrhosis. *J Vasc Interv Radiol* 2006; **17**: 1951-1955 [PMID: 17185692 DOI: 10.1097/01.RVI.0000250890.38012.38]
- 7 Shimoda R, Horiuchi K, Hagiwara S, Suzuki H, Yamazaki Y, Kosone T, Ichikawa T, Arai H, Yamada T, Abe T, Takagi H, Mori M. Short-term complications of retrograde transvenous obliteration of gastric varices in patients with portal hypertension: effects of obliteration of major portosystemic shunts. *Abdom Imaging* 2005; **30**: 306-313 [PMID: 15688111]

DOI: [10.1007/s00261-004-0270-8](https://doi.org/10.1007/s00261-004-0270-8)]

- 8 **Cho SK**, Shin SW, Do YS, Park KB, Choo SW, Kim SS, Choo IW. Development of thrombus in the major systemic and portal veins after balloon-occluded retrograde transvenous obliteration for treating gastric variceal bleeding: its frequency and outcome evaluation with CT. *J Vasc Interv Radiol* 2008; **19**: 529-538 [PMID: [18375297](https://pubmed.ncbi.nlm.nih.gov/18375297/) DOI: [10.1016/j.jvir.2007.10.012](https://doi.org/10.1016/j.jvir.2007.10.012)]
- 9 **Yoshimatsu R**, Yamagami T, Tanaka O, Miura H, Okuda K, Hashiba M, Nishimura T. Development of thrombus in a systemic vein after balloon-occluded retrograde transvenous obliteration of gastric varices. *Korean J Radiol* 2012; **13**: 324-331 [PMID: [22563270](https://pubmed.ncbi.nlm.nih.gov/22563270/) DOI: [10.3348/kjr.2012.13.3.324](https://doi.org/10.3348/kjr.2012.13.3.324)]
- 10 **Saad WE**, Kitano T, Koizumi J, Hirota S. The conventional balloon-occluded retrograde transvenous obliteration procedure: indications, contraindications, and technical applications. *Tech Vasc Interv Radiol* 2013; **16**: 101-151 [PMID: [23830671](https://pubmed.ncbi.nlm.nih.gov/23830671/) DOI: [10.1053/j.tvir.2013.02.003](https://doi.org/10.1053/j.tvir.2013.02.003)]
- 11 **Han JH**, Wilber ST. Altered mental status in older patients in the emergency department. *Clin Geriatr Med* 2013; **29**: 101-136 [PMID: [23177603](https://pubmed.ncbi.nlm.nih.gov/23177603/) DOI: [10.1016/j.cger.2012.09.005](https://doi.org/10.1016/j.cger.2012.09.005)]
- 12 **Hawkes ND**, Thomas GA, Jurewicz A, Williams OM, Hillier CE, McQueen IN, Shortland G. Non-hepatic hyperammonaemia: an important, potentially reversible cause of encephalopathy. *Postgrad Med J* 2001; **77**: 717-722 [PMID: [11677282](https://pubmed.ncbi.nlm.nih.gov/11677282/) DOI: [10.1136/pmj.77.913.717](https://doi.org/10.1136/pmj.77.913.717)]
- 13 **Kenzaka T**, Kato K, Kitao A, Kosami K, Minami K, Yahata S, Fukui M, Okayama M. Hyperammonemia in Urinary Tract Infections. *PLoS One* 2015; **10**: e0136220 [PMID: [26292215](https://pubmed.ncbi.nlm.nih.gov/26292215/) DOI: [10.1371/journal.pone.0136220](https://doi.org/10.1371/journal.pone.0136220)]
- 14 **Walker V**. Severe hyperammonaemia in adults not explained by liver disease. *Ann Clin Biochem* 2012; **49**: 214-228 [PMID: [22349554](https://pubmed.ncbi.nlm.nih.gov/22349554/) DOI: [10.1258/acb.2011.011206](https://doi.org/10.1258/acb.2011.011206)]



Published by **Baishideng Publishing Group Inc**
7041 Koll Center Parkway, Suite 160, Pleasanton, CA 94566, USA

Telephone: +1-925-3991568

E-mail: bpgoffice@wjgnet.com

Help Desk: <https://www.f6publishing.com/helpdesk>

<https://www.wjgnet.com>

