

# World Journal of *Clinical Cases*

*World J Clin Cases* 2023 February 16; 11(5): 979-1223



## Contents

Thrice Monthly Volume 11 Number 5 February 16, 2023

## MINIREVIEWS

- 979 Non-clostridium difficile induced pseudomembranous colitis  
*Jagirdhar GSK, Surani S*
- 989 Pleural effusion in critically ill patients and intensive care setting  
*Bediwy AS, Al-Biltagi M, Saeed NK, Bediwy HA, Elbeltagi R*

## ORIGINAL ARTICLE

## Retrospective Study

- 1000 Investigation of litigation in trauma orthopaedic surgery  
*Salimi M, Heidari MB, Ravandi Z, Mosalamiaghili S, Mirghaderi P, Jafari Kafiabadi M, Biglari F, Salimi A, Sabaghzadeh Irani A, Khabiri SS*
- 1009 Type 2 diabetes mellitus characteristics affect hepatocellular carcinoma development in chronic hepatitis B patients with cirrhosis  
*Li MY, Li TT, Li KJ, Zhou C*
- 1019 Relationship between glycemic variability and cognitive function in lacune patients with type 2 diabetes  
*Meng QZ, Wang Y, Li B, Xi Z, Wang M, Xiu JQ, Yang XP*
- 1031 COVID-19-related cardiomyopathy: Can dual-energy computed tomography be a diagnostic tool?  
*Aydin F, Kantarci M, Aydin S, Karavaş E, Ceyhan G, Ogul H, Şahin ÇE, Eren S*

## Observational Study

- 1040 Multiple regression analysis of risk factors related to radiation pneumonitis  
*Shi LL, Yang JH, Yao HF*
- 1049 Right hemicolectomy combined with duodenum-jejunum Roux-en-Y anastomosis for hepatic colon carcinoma invading the duodenum: A single-center case series  
*Liu PG, Feng PF, Chen XF*
- 1058 Analysis of the value and safety of thyroid-stimulating hormone in the clinical efficacy of patients with thyroid cancer  
*Liang JJ, Feng WJ, Li R, Xu RT, Liang YL*

## CASE REPORT

- 1068 Effect of liver transplantation with primary hyperoxaluria type 1: Five case reports and review of literature  
*Wang XY, Zeng ZG, Zhu ZJ, Wei L, Qu W, Liu Y, Tan YL, Wang J, Zhang HM, Shi W, Sun LY*
- 1077 Diagnosis of an intermediate case of maple syrup urine disease: A case report  
*Lin YT, Cai YN, Ting TH, Liu L, Zeng CH, Su L, Peng MZ, Li XZ*

- 1086** Angioimmunoblastic T-cell lymphoma induced hemophagocytic lymphohistiocytosis and disseminated intravascular coagulopathy: A case report  
*Jiang M, Wan JH, Tu Y, Shen Y, Kong FC, Zhang ZL*
- 1094** Giant myxofibrosarcoma of the esophagus treated by endoscopic submucosal dissection: A case report  
*Wang XS, Zhao CG, Wang HM, Wang XY*
- 1099** Novel gene mutation in maturity-onset diabetes of the young: A case report  
*Zhang N, Zhao H, Li C, Zhang FZ*
- 1106** Orthodontic-surgical treatment for severe skeletal class II malocclusion with vertical maxillary excess and four premolars extraction: A case report  
*Zhou YW, Wang YY, He ZF, Lu MX, Li GF, Li H*
- 1115** Envafolelimab combined with chemotherapy in the treatment of combined small cell lung cancer: A case report  
*Liu MH, Li YX, Liu Z*
- 1122** Thyrotoxicosis in patients with a history of Graves' disease after SARS-CoV-2 vaccination (adenovirus vector vaccine): Two case reports  
*Yan BC, Luo RR*
- 1129** Administration of modified Gegen Qinlian decoction for hemorrhagic chronic radiation proctitis: A case report and review of literature  
*Liu SY, Hu LL, Wang SJ, Liao ZL*
- 1137** Surgical resection of a giant thymolipoma causing respiratory failure: A case report  
*Gong LH, Wang WX, Zhou Y, Yang DS, Zhang BH, Wu J*
- 1144** Successful treatment of granulomatosis with polyangiitis using tocilizumab combined with glucocorticoids: A case report  
*Tang PF, Xu LC, Hong WT, Shi HY*
- 1152** Langerhans cell histiocytosis misdiagnosed as thyroid malignancy: A case report  
*Shi JJ, Peng Y, Zhang Y, Zhou L, Pan G*
- 1158** Combined treatment of refractory benign stricture after esophageal endoscopic mucosal dissection: A case report  
*Pu WF, Zhang T, Du ZH*
- 1165** Bladder preservation in complicated invasive urothelial carcinoma following treatment with cisplatin/gemcitabine plus tislelizumab: A case report  
*Yang R, Chen JX, Luo SH, Chen TT, Chen LW, Huang B*
- 1175** *Nocardia cyriacigeorgica* infection in a patient with repeated fever and CD4<sup>+</sup> T cell deficiency: A case report  
*Hong X, Ji YQ, Chen MY, Gou XY, Ge YM*

- 1182** Closed loop ileus caused by a defect in the broad ligament: A case report  
*Zucal I, Nebiker CA*
- 1188** Early postsurgical lethal outcome due to splenic littoral cell angioma: A case report  
*Jia F, Lin H, Li YL, Zhang JL, Tang L, Lu PT, Wang YQ, Cui YF, Yang XH, Lu ZY*
- 1198** Combinations of nerve blocks in surgery for post COVID-19 pulmonary sequelae patient: A case report and review of literature  
*Jin Y, Lee S, Kim D, Hur J, Eom W*
- 1206** Incidental right atrial mass in a patient with secondary pancreatic cancer: A case report and review of literature  
*Fioretti AM, Leopizzi T, La Forgia D, Scicchitano P, Oreste D, Fanizzi A, Massafra R, Oliva S*
- 1217** Difficult airway due to cervical haemorrhage caused by spontaneous rupture of a parathyroid adenoma: A case report  
*Han YZ, Zhou Y, Peng Y, Zeng J, Zhao YQ, Gao XR, Zeng H, Guo XY, Li ZQ*

**ABOUT COVER**

Editorial Board Member of *World Journal of Clinical Cases*, Tian-Biao Zhou, MD, PhD, Chief Doctor, Professor, Department of Nephrology, Second Affiliated Hospital, Shantou University Medical College, Shantou 515041, Guangdong Province, China. zhoutb@aliyun.com

**AIMS AND SCOPE**

The primary aim of *World Journal of Clinical Cases* (WJCC, *World J Clin Cases*) is to provide scholars and readers from various fields of clinical medicine with a platform to publish high-quality clinical research articles and communicate their research findings online.

WJCC mainly publishes articles reporting research results and findings obtained in the field of clinical medicine and covering a wide range of topics, including case control studies, retrospective cohort studies, retrospective studies, clinical trials studies, observational studies, prospective studies, randomized controlled trials, randomized clinical trials, systematic reviews, meta-analysis, and case reports.

**INDEXING/ABSTRACTING**

The WJCC is now abstracted and indexed in Science Citation Index Expanded (SCIE, also known as SciSearch®), Journal Citation Reports/Science Edition, Current Contents®/Clinical Medicine, PubMed, PubMed Central, Scopus, Reference Citation Analysis, China National Knowledge Infrastructure, China Science and Technology Journal Database, and Superstar Journals Database. The 2022 Edition of Journal Citation Reports® cites the 2021 impact factor (IF) for WJCC as 1.534; IF without journal self cites: 1.491; 5-year IF: 1.599; Journal Citation Indicator: 0.28; Ranking: 135 among 172 journals in medicine, general and internal; and Quartile category: Q4. The WJCC's CiteScore for 2021 is 1.2 and Scopus CiteScore rank 2021: General Medicine is 443/826.

**RESPONSIBLE EDITORS FOR THIS ISSUE**

Production Editor: Hua-Ge Yin; Production Department Director: Xiang Li; Editorial Office Director: Jin-Lei Wang.

**NAME OF JOURNAL**

*World Journal of Clinical Cases*

**ISSN**

ISSN 2307-8960 (online)

**LAUNCH DATE**

April 16, 2013

**FREQUENCY**

Thrice Monthly

**EDITORS-IN-CHIEF**

Bao-Gan Peng, Jerzy Tadeusz Chudek, George Kontogeorgos, Maurizio Serati, Ja Hyeon Ku

**EDITORIAL BOARD MEMBERS**

<https://www.wjgnet.com/2307-8960/editorialboard.htm>

**PUBLICATION DATE**

February 16, 2023

**COPYRIGHT**

© 2023 Baishideng Publishing Group Inc

**INSTRUCTIONS TO AUTHORS**

<https://www.wjgnet.com/bpg/gerinfo/204>

**GUIDELINES FOR ETHICS DOCUMENTS**

<https://www.wjgnet.com/bpg/GerInfo/287>

**GUIDELINES FOR NON-NATIVE SPEAKERS OF ENGLISH**

<https://www.wjgnet.com/bpg/gerinfo/240>

**PUBLICATION ETHICS**

<https://www.wjgnet.com/bpg/GerInfo/288>

**PUBLICATION MISCONDUCT**

<https://www.wjgnet.com/bpg/gerinfo/208>

**ARTICLE PROCESSING CHARGE**

<https://www.wjgnet.com/bpg/gerinfo/242>

**STEPS FOR SUBMITTING MANUSCRIPTS**

<https://www.wjgnet.com/bpg/GerInfo/239>

**ONLINE SUBMISSION**

<https://www.f6publishing.com>



## Successful treatment of granulomatosis with polyangiitis using tocilizumab combined with glucocorticoids: A case report

Peng-Fang Tang, Long-Chuan Xu, Wen-Ting Hong, Hong-Ying Shi

**Specialty type:** Rheumatology

**Provenance and peer review:**

Unsolicited article; Externally peer reviewed.

**Peer-review model:** Single blind

**Peer-review report's scientific quality classification**

Grade A (Excellent): 0

Grade B (Very good): B

Grade C (Good): 0

Grade D (Fair): D

Grade E (Poor): 0

**P-Reviewer:** Rostaing L, France; Shrestha MR, Nepal

**Received:** October 27, 2022

**Peer-review started:** October 27, 2022

**First decision:** November 25, 2022

**Revised:** December 3, 2022

**Accepted:** January 28, 2023

**Article in press:** January 28, 2023

**Published online:** February 16, 2023



**Peng-Fang Tang, Wen-Ting Hong,** Department of Rheumatology, Second Affiliated Hospital of Fujian Medical University, Quanzhou 362000, Fujian Province, China

**Long-Chuan Xu,** Department of Pathology, Second Affiliated Hospital of Fujian Medical University, Quanzhou 362000, Fujian Province, China

**Hong-Ying Shi,** Department of Immunology, Second Affiliated Hospital of Fujian Medical University, Quanzhou 362000, Fujian Province, China

**Corresponding author:** Hong-Ying Shi, PhD, Chief Physician, Department of Immunology, Second Affiliated Hospital of Fujian Medical University, Donghai Street, Fengze District, Quanzhou 362000, Fujian Province, China. [shyfly@163.com](mailto:shyfly@163.com)

### Abstract

#### BACKGROUND

Tocilizumab is a humanized monoclonal antibody against the interleukin-6 (IL-6) receptor that is commonly used to treat large vessel vasculitis and antineutrophil cytoplasmic antibody-related small vessel vasculitis. However, tocilizumab in combination with glucocorticoids for successfully treating granulomatosis with polyangiitis (GPA) has rarely been reported.

#### CASE SUMMARY

Here, we report a 40-year-old male patient who suffered GPA for 4 years. He was treated with multiple rounds of drugs, including cyclophosphamide, Tripterium wilfordii, mycophenolate mofetil, and belimumab, with no improvement. In addition, he exhibited persistently high IL-6 levels. After tocilizumab treatment, his symptoms improved, and his inflammatory marker levels returned to normal.

#### CONCLUSION

Tocilizumab may be effective for treating GPA.

**Key Words:** Tocilizumab; Granulomatosis with polyangiitis; Antineutrophil cytoplasmic antibody; Case report

©The Author(s) 2023. Published by Baishideng Publishing Group Inc. All rights reserved.

**Core Tip:** Granulomatosis with polyangiitis (GPA), formerly called Wegener's granulomatosis, is a necrotizing granulomatous vasculitis that involves small arteries, veins, and capillaries throughout the body. The upper respiratory tract, lower respiratory tract, and kidney are most commonly affected. Clinically, glucocorticoid combined with cyclophosphamide is the first treatment for GPA. Herein, we report a case of refractory GPA. Combined with the literature review, we found that interleukin-6 (IL-6) levels were generally elevated in GPA patients. IL-6 is involved in the pathogenesis of antineutrophil cytoplasmic antibody-related small vessel vasculitis. We successfully treated a patient with refractory GPA using the IL-6 inhibitor-tocilizumab. Tocilizumab is an option when conventional immunosuppressants and rituximab are not effective in treating GPA.

**Citation:** Tang PF, Xu LC, Hong WT, Shi HY. Successful treatment of granulomatosis with polyangiitis using tocilizumab combined with glucocorticoids: A case report. *World J Clin Cases* 2023; 11(5): 1144-1151

**URL:** <https://www.wjgnet.com/2307-8960/full/v11/i5/1144.htm>

**DOI:** <https://dx.doi.org/10.12998/wjcc.v11.i5.1144>

## INTRODUCTION

Antineutrophil cytoplasmic antibody (ANCA)-related small vessel vasculitis (AAV) refers to a set of systemic small vessel vasculitis diseases associated with antineutrophil cytoplasmic antibodies, including microscopic polyangiitis (MPA), granulomatosis with polyangiitis (GPA), and eosinophilic granulomatosis with polyangiitis (EGPA). Patients with GPA are mainly positive for classic ANCA (C-ANCA) and proteinase 3-ANCA (PR3-ANCA), and GPA tends to involve the upper and lower respiratory tracts, kidney, and systemic arterioles, venules, and capillaries. According to guideline recommendations[1], cyclophosphamide (CTX) or rituximab is the drug of choice for inducing remission in patients with AAV. Tocilizumab has been reported in the literature for treating primary and secondary small vessel vasculitis[2]. However, the use of tocilizumab for treating GPA has rarely been reported. Here, we report a case of successful treatment of GPA with tocilizumab in combination with glucocorticoids, suggesting that tocilizumab may be useful for treating GPA.

## CASE PRESENTATION

### Chief complaints

A 40-year-old man presented to the Rheumatology Department on October 8, 2021, with the main complaints of 4-year pulmonary nodules and 3-year repeated haemoptysis.

### History of present illness

On October 8, 2021, the patient was admitted for recurrent haemoptysis without apparent cause.

### History of past illness

Four years before admission (January 2017), the patient visited a local hospital for trauma (specific unknown). Pulmonary computed tomography (CT) revealed multiple bilateral pulmonary nodules and mass shadows, inflammatory flaked shadows, and significantly thickened pleura. Lung biopsy pathology showed granulomatous inflammatory flaked necrosis. Pulmonary tumours were excluded according to immunohistochemical findings. At follow-up, pulmonary CT demonstrated more pulmonary nodules and flaked shadows.

On June 2017, the patient visited a tertiary hospital in Beijing, China due to low fever, joint pain, and maculopapular rash. Laboratory examination showed an erythrocyte sedimentation rate (ESR) of 47 mm/h; C-reactive protein (CRP) level of 18.6 mg/L; rheumatoid factor (RF) level of 225 IU/mL; normal levels of antinuclear antibodies (ANAs), anti-ENA antibodies, anti-double-stranded DNA antibodies, immunoglobulins (IgA, IgM, and IgG), complement, and anti-cyclic citrullinated peptide antibodies; and C-ANCA and PR3-ANCA positivity. AAV was considered. Immunosuppression was obtained using methylprednisolone (80 mg/d) plus CTX 0.2 g qod. In addition, human immunoglobulins (20 g/d) were administered for 5 d with satisfactory results. Some pulmonary lesions disappeared, while the inflammatory indicators remained at a high level. After discharge from the hospital, the patient's maintenance regimen consisted of oral prednisone 20 mg/d combined with CTX 0.2 g qod.

On July 2018, the patient returned to the tertiary hospital for cough and haemoptysis. He was positive for C-ANCA and exhibited significantly increased inflammatory levels, and more pulmonary nodules and mass shadows. According to the 2017 European League against Rheumatism/American College of Rheumatology classification criteria for granulomatosis with polyangiitis, GPA was diagnosed. Anti-



inflammatory methylprednisolone 40 mg/d and oral CTX (150 mg for one day and 100 mg for two consecutive days) were administered. The symptoms improved, while he had intermittent cough and shortness of breath after activity.

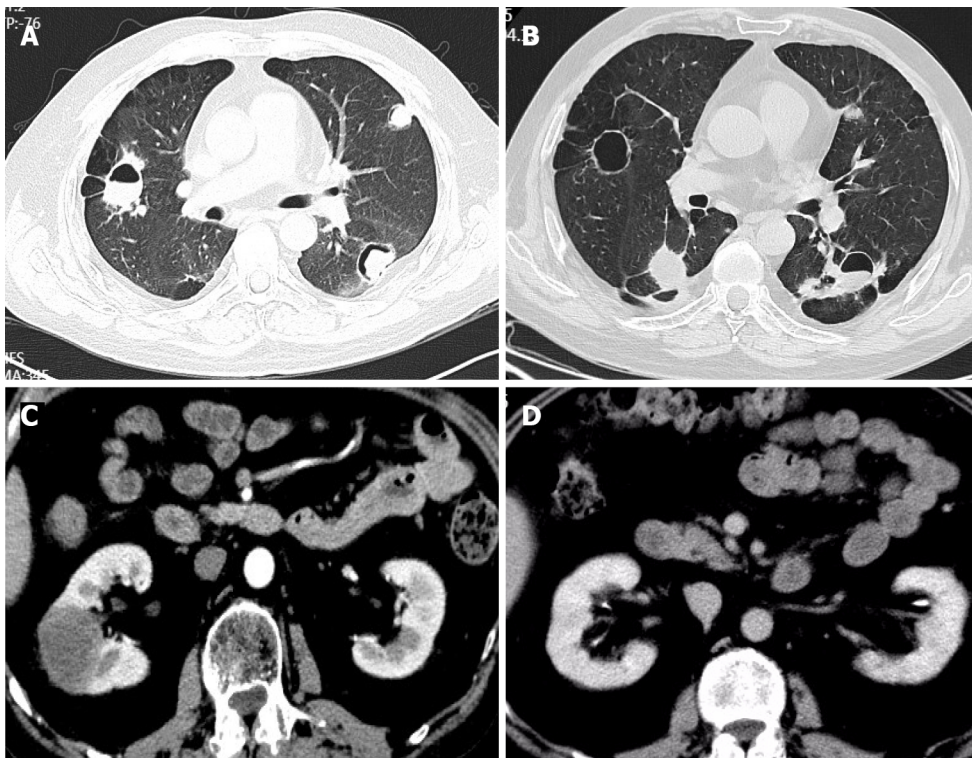
On August 13, 2018, the patient visited our hospital with the main complaint of cough with yellow sputum. Laboratory examination revealed a WBC count of  $11.8 \times 10^9/L$ , neutrophil count of  $7.6 \times 10^9/L$ , and lymphocyte count of  $2.6 \times 10^9/L$ . Analysis of lymphocyte subsets showed the following results: B lymphocyte antigen (CD3-CD19<sup>+</sup>) 102/ $\mu$ L, CD4 875/ $\mu$ L, CD8 1300/ $\mu$ L, and CD4/CD8 0.67. In addition, the patient exhibited C-ANCA positivity, PR3-ANCA 94.86 nmol/L ( $< 20$  nmol/L), ESR 55 mm/h (normal,  $< 15.0$ ), CRP 14.1 mg/L (normal,  $< 0.5$ ), interleukin-6 (IL-6) 17.11 pg/mL (normal,  $< 7.0$ ), and normal procalcitonin (PCT). Negative results were obtained for the sputum culture, serum G ((1-3)- $\beta$ -d-glucan), galactomannan (GM), cytomegalovirus, Epstein-Barr virus (EBV) virus, and T-spot tests. Nine respiratory pathogen antibody IgM tests, namely, tests for *Legionella pneumophila*, *Mycoplasma pneumoniae*, *Chlamydia pneumoniae*, *Rickettsia* Q fever, influenza A and B viruses, parainfluenza virus, respiratory syncytial virus, and adenovirus, were normal. On pulmonary CT, multiple patchy shadows, nodular higher-density shadows, multiple cavities, heterogeneous wall thickness, and air crescent signs and flat lipids in some lesions were observed (Figure 1A). After Respiratory Department consultation, the possibility of lung infection (bacteria + fungi) was considered. *Pneumocystis* infection could not be ruled out. CTX was discontinued, and the glucocorticoid doses were reduced. In addition, moxifloxacin (antibacterial), voriconazole (antifungal), and prophylactic anti-*Pneumocystis jiroveci* treatments were administered for 2 wk with improved symptoms and decreased inflammatory levels. After discharge, CTX 100 mg was administered on alternate days, with a cumulative dose of 28 g. During the outpatient follow-up, the inflammatory marker levels were within the normal range, and the pulmonary lesions increasingly disappeared. However, the G test was positive twice, while the GM was negative. The vasculitis was considered to be controlled, but the pulmonary fungal infection persisted. Dose reduction was obtained, and methylprednisolone 6 mg/d was administered. CTX was replaced with Tripterygium wilfordii (TW) for immunosuppression. Oral antifungal agents were concurrently administered and discontinued within one year.

On March 19, 2019, September 5, 2019, November 23, 2019, and June 12, 2020, the patient visited the Rheumatology Department of our hospital for fever, fatigue, and systemic muscle soreness. Laboratory examination revealed increased CRP and ESR levels, IL-6 33.43 pg/mL, and normal PCT. EBV DNA was  $5.09E + 4$  copies/mL. Negative results were obtained for the pathological examination of tracheal lavage fluid, and TORCH test analysis of lymphocyte subsets revealed B lymphocytes (CD3-CD19<sup>+</sup>) 62/ $\mu$ L and CD4/CD8 0.6. On pulmonary CT, there were new and larger bilateral pulmonary nodules (Figure 1B). Anti-infectious moxifloxacin and antiviral peramivir were successively applied. The body temperature was normal, while the sensation of fatigue was retained. Elevation of the PR3-ANCA titre was examined, suggesting vasculitis activity. Since the patient had a low level of B lymphocytes and a history of deep mould infection, rituximab was not recommended. Therefore, the treatment plan was changed to a glucocorticoid dose increase combined with mycophenolate mofetil (MMF). The patient's fatigue symptoms improved. PR3-ANCA and inflammatory marker levels decreased.

On September 15, 2020, the patient was treated at the Rheumatology Department of our hospital again for fatigue, muscle soreness at the extremities and joints, cough with yellow sputum, and shortness of breath. He exhibited CRP 51.09 mg/L, ESR 84 mm/h, C-ANCA positivity, PR3-ANCA (++), and G-test, GM-test, cryptococcal antigen, and TORCH test negativity. Pulmonary CT demonstrated more bilateral pulmonary nodules and cavities and some larger nodular lesions. Renal CT showed a space-occupying lesion in the right middle kidney. Puncture pathology of the space-occupying lesion revealed fibrous tissue proliferation with infiltration of tissue cells, plasma cells, and lymphocytes, focal necrosis, and no IGG4-positive plasma cell infiltration (Figure 2A and B). Vasculitis activity with the involvement of the kidney was considered. Referring to the literature, we noted that the level of circulating B lymphocyte factor increases in patients with AAV. Given the role of the B lymphocyte factor in the onset of AAV, the patient was treated with methylprednisolone 40 mg/d combined with MMF 500 mg bid and belimumab 840 mg (I.V.). The symptoms improved, but the fatigue and soreness at the extremities relapsed due to the dose reduction of glucocorticoids.

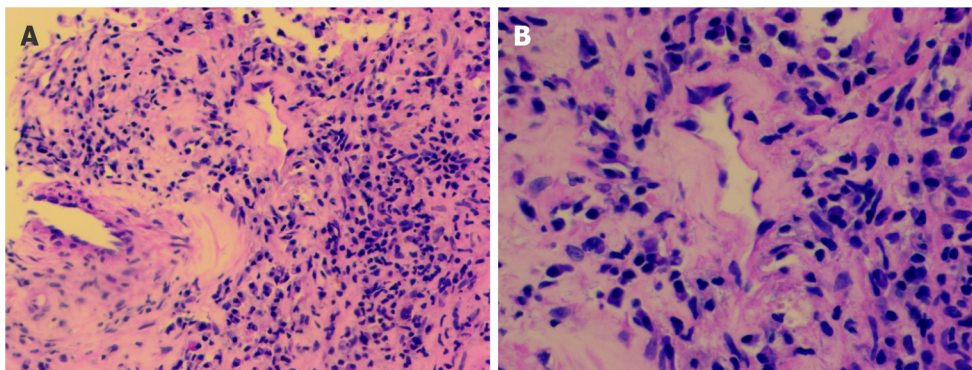
On March 21, 2021, the patient was admitted to our hospital for haemoptysis. Pulmonary CTA manifestations were normal, while the air crescent sign was observed on CT. The haemoptysis was then considered a result of pulmonary infection. MMF and belimumab were discontinued. Anti-infectious moxifloxacin was administered. There was no evidence of recurrence while reducing the use of glucocorticoids, and more pulmonary lesions disappeared. After discharge, the patient was treated with belimumab 840 mg (I.V.) once every month for a total of 8 times. Then, renal CT was performed and revealed a space-occupying lesion in the right middle kidney, which was larger than before (Figure 1C). In the meantime, the pulmonary nodules and cavities were similar. The patient experienced repeated elevation of inflammatory indicators, with a poorly controlled disease. The IL-6 Level during the treatment was high, ranging between 32 pg/mL and 49 pg/mL. Referring to the literature, tocilizumab 640 mg (I.V., once monthly) was administered. After dose reduction of the glucocorticoids, there was no evidence of recurrence of fatigue or muscle soreness at the extremities and joints. In addition, the right middle kidney-occupying lesion was smaller (Figure 1D), and the ESR recovered to normal (Figure 3A).





DOI: 10.12998/wjcc.v11.i5.1144 Copyright ©The Author(s) 2023.

**Figure 1 Computed tomography.** A: On pulmonary computed tomography (CT), multiple patchy shadows, nodular higher-density shadows, multiple cavities, heterogeneous wall thickness, and air crescent sign and flat lipid in some lesions were observed (August 13, 2018); B: On pulmonary CT, there were new and larger bilateral pulmonary nodules (June 12, 2020); C: Renal CT was performed and revealed a space-occupying lesion in the right middle kidney, which was larger than before (June 15, 2021); D: The right middle kidney-occupying lesion was significantly absorbed after tocilizumab treatment (August 20, 2021).



DOI: 10.12998/wjcc.v11.i5.1144 Copyright ©The Author(s) 2023.

**Figure 2 Puncture pathology.** A and B: Puncture pathology of the space-occupying lesion revealed infiltration of tissue cells, plasma cells, and lymphocytes (A: magnification  $\times 200$ ; B: Magnification  $\times 400$ ).

### Personal and family history

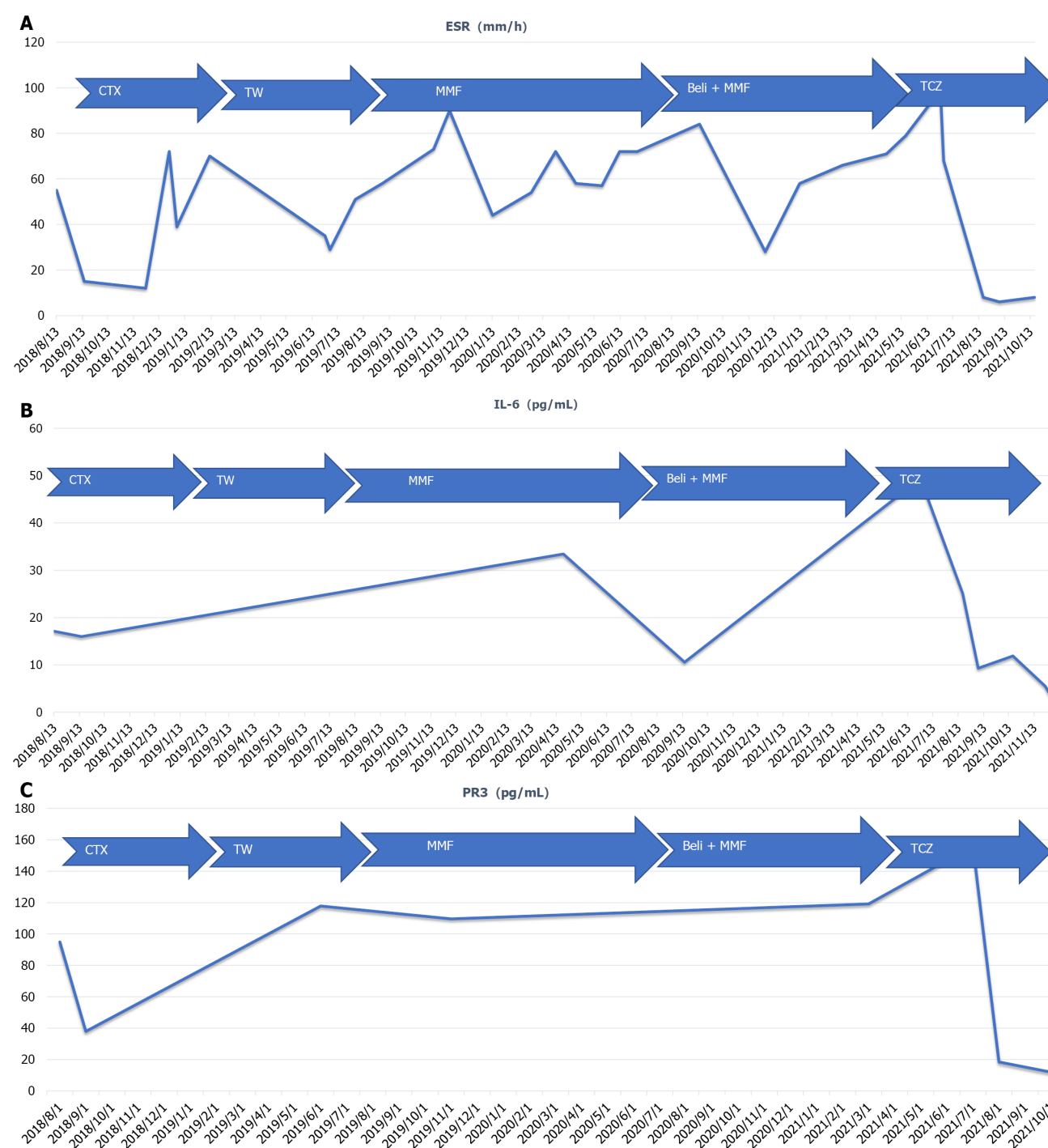
The patient had no previous underlying diseases, such as hypertension, nor a bad habit of smoking. He denied any family history of rheumatic diseases.

### Physical examination

On physical examination, the vital signs were as follows: Body temperature, 36.8 °C; blood pressure, 130/70 mmHg; heart rate, 90 beats per min; respiratory rate, 20 breaths per min. In addition, heart, lung, and abdominal examinations showed no remarkable changes.

### Laboratory examinations

Second-generation gene sequencing revealed growth of *Pseudomonas aeruginosa* in bronchoalveolar lavage fluid.



**Figure 3** Erythrocyte sedimentation rate and the levels of interleukin-6 and proteinase 3-antineutrophil cytoplasmic antibody. A: Erythrocyte sedimentation rate; B: Interleukin-6; C: Proteinase 3-antineutrophil cytoplasmic antibody. ESR: Erythrocyte sedimentation rate; IL-6: Interleukin-6; CTX: Cyclophosphamide; TW: Tripterygium wilfordii; MMF: Mycophenolate mofetil; TCZ: Tocilizumab.

### Imaging examinations

Arteriography demonstrated more and thickened bilateral bronchial arterial branches.

### FINAL DIAGNOSIS

GPA with pulmonary mixed infection (bacteria + fungi) was considered.

## TREATMENT

The bacteria were sensitive to piperacillin sodium and tazobactam sodium administered by injection. Tocilizumab was discontinued, and anti-infection therapy was administered due to drug susceptibility. There was no haemoptysis, and the infection was controlled. Tocilizumab was continued at 640 mg (I.V.) once every month, in combination with methylprednisolone 12 mg/d.

## OUTCOME AND FOLLOW-UP

After treatment, there was no fatigue or muscle soreness, while there was occasional cough with yellow sputum. The patient was discharged after improvement on November 5, 2021. The ESR was normal (Figure 3A), and the levels of IL-6 (Figure 3B) and PR3-ANCA (Figure 3C) were decreased after the use of tocilizumab. The patient remains under outpatient follow-up. His general condition is normal, and his indicator levels are relatively stable.

## DISCUSSION

At present, there is no literature review of the underlying mechanisms by which IL-6 suppression is effective; notably, IL-6 acts on T cells, B cells, monocyte macrophages, *etc.* The patient reported here mainly exhibited fever and pulmonary nodules/cavities. He had a significant increase in serum PR3-ANCA titre during the disease active phase, and the serum IL-6 Level was increased as well. Serum IL-6 elevation in AAV patients has been reported in the literature. For instance, Berti *et al*[3] reported abnormal IL-6 Levels in 81% of 78 patients with AAV and found associations with PR3-ANCA positivity, fever, pulmonary nodules/cavities, and urine red cell count. Similarly, the main clinical manifestations of the patient here were pulmonary nodules/cavities and fever, accompanying elevation of serum IL-6 and PR3-ANCA titres. IL-6 is one of the B-cell differentiation factors that can advance the in situ activation of macrophages, T lymphocyte differentiation, and synthesis of other proinflammatory cytokines. Patients with MPA and GPA have been reported to have serum IL-6 elevation during the active phase, and IL-6 expression has been documented in renal biopsy tissue samples[2]. These findings suggest that IL-6 plays a core role during the pathogenesis of AAV, but the specific involved pathways need to be further identified in a larger cohort.

According to the Joint EULAR and European Renal Association-European Dialysis and Transplant Association (EULAR/ERA-EDTA) recommendations for the management of AAV (2016), a combination of glucocorticoids and CTX or rituximab is preferred for remission induction in cases with organ involvement or in critical medical conditions, followed by methotrexate, azathioprine, or MMF applied for maintenance therapy; other drugs can be considered upon recurrence. In the present case, sufficient CTX was initially administered. The patient then developed pulmonary mould infection, and CTX was replaced by Tripterygium glycosides with persistent disease activity. Referring to the literature[4], where MMF was proven to be effective for the induction of remission in AAV, the patient was then treated with MMF, but the efficacy remained poor. In addition, given the low B-lymphocyte level and a history of deep mould infection, rituximab was not considered. The literature has shown that IL-6 levels are increased in patients with AAV and are involved in the pathogenesis of this disease[5]. The patient was then treated with belimumab with recurrence of symptoms and repeated haemoptysis during the disease course. Pulmonary embolism and bronchial vascular malformation were ruled out. *Pseudomonas aeruginosa* was grown in BALF. Immunosuppressive agents were discontinued, and anti-infection treatment was intensified. There was no haemoptysis after the treatment. Combining the previous medical history, we considered that the repeated haemoptysis might be a result of AAV combined with infections. In addition, concurrent immunosuppression and infection could also be a major cause of multiple recurrences and poor therapeutic effects.

Tocilizumab is a humanized monoclonal antibody against the IL-6 receptor that has shown effectiveness in the treatment of large vessel vasculitis, including giant cell arteritis and Takayasu arteritis[6]. A foreign prospective, single-arm, single-centre clinical trial reported the therapeutic effect of tocilizumab in MPA patients[7]. Additionally, another literature review assessed the effectiveness and safety of tocilizumab in this population when combined with large-dose CS and reported its potential for treating primary and secondary vasculitis[8]. There was also a case of MPA that was successfully treated with tocilizumab alone[9]. Nevertheless, whether tocilizumab is still active in EGPA remains unclear. It has been established that EGPA tends to involve the respiratory tract (primarily the small- and medium-sized vessels) and is associated with asthma and eosinophilia. It was reported that the use of tocilizumab to treat rheumatoid arthritis could lead to the incidence of critical eosinophilia[10]. Thus, IL-6 inhibitors may not be a good option for treating EGPA. Sumida *et al*[11] reported good therapeutic outcomes in patients with MPO-ANCA-positive vasculitis and rheumatoid arthritis after receiving tocilizumab plus a rapid reduction in glucocorticoids. Tocilizumab as an induction therapy for leukocytoclastic vasculitis in rheumatoid arthritis has also been reported. The present paper describes a patient

with repeated symptoms after multiple rounds of treatment with immunosuppressive agents. After treatment with tocilizumab, the patient was stable, with normal inflammatory indicator levels, decreased IL-6 levels, and smaller right kidney-occupying lesions.

## CONCLUSION

This case report demonstrates the important role of IL-6 in the pathogenesis of AAV. In patients unresponsive to traditional immunosuppressive agents or with contraindications, tocilizumab can be a good treatment option. However, more case studies are required to verify the effectiveness and safety of tocilizumab for treating patients with AAV.

## FOOTNOTES

**Author contributions:** Tang PF contributed to manuscript writing and editing, and data collection; Xu LC contributed to data analysis; Shi HY and Hong WT contributed to conceptualization and supervision; all authors have read and approved the final manuscript.

**Informed consent statement:** Informed written consent was obtained from the patient for publication of this report and any accompanying images.

**Conflict-of-interest statement:** The authors declare that they have no conflict of interest to disclose.

**CARE Checklist (2016) statement:** The authors have read the CARE Checklist (2016), and the manuscript was prepared and revised according to the CARE Checklist (2016).

**Open-Access:** This article is an open-access article that was selected by an in-house editor and fully peer-reviewed by external reviewers. It is distributed in accordance with the Creative Commons Attribution NonCommercial (CC BY-NC 4.0) license, which permits others to distribute, remix, adapt, build upon this work non-commercially, and license their derivative works on different terms, provided the original work is properly cited and the use is non-commercial. See: <https://creativecommons.org/licenses/by-nc/4.0/>

**Country/Territory of origin:** China

**ORCID number:** Peng-Fang Tang 0000-0003-2276-6974; Hong-Ying Shi 0000-0003-4282-0579.

**S-Editor:** Chen YL

**L-Editor:** Wang TQ

**P-Editor:** Chen YL

## REFERENCES

- 1 Yates M, Watts RA, Bajema IM, Cid MC, Crestani B, Hauser T, Hellmich B, Holle JU, Laudien M, Little MA, Luqmani RA, Mahr A, Merkel PA, Mills J, Mooney J, Segelmark M, Tesar V, Westman K, Vaglio A, Yalçındağ N, Jayne DR, Mukhtyar C. EULAR/ERA-EDTA recommendations for the management of ANCA-associated vasculitis. *Ann Rheum Dis* 2016; **75**: 1583-1594 [PMID: 27338776 DOI: 10.1136/annrheumdis-2016-209133]
- 2 Berti A, Cavalli G, Campochiaro C, Guglielmi B, Baldissera E, Cappio S, Sabbadini MG, Doglioni C, Dagna L. Interleukin-6 in ANCA-associated vasculitis: Rationale for successful treatment with tocilizumab. *Semin Arthritis Rheum* 2015; **45**: 48-54 [PMID: 25841802 DOI: 10.1016/j.semarthrit.2015.02.002]
- 3 Berti A, Warner R, Johnson K, Cornec D, Schroeder DR, Kabat BF, Langford CA, Kallenberg CGM, Seo P, Spiera RF, St Clair EW, Fervenza FC, Stone JH, Monach PA, Specks U, Merkel PA; RAVE-ITN Research Group. The association of serum interleukin-6 levels with clinical outcomes in antineutrophil cytoplasmic antibody-associated vasculitis. *J Autoimmun* 2019; **105**: 102302 [PMID: 31320177 DOI: 10.1016/j.jaut.2019.07.001]
- 4 Berti A, Alsawas M, Jawaid T, Prokop LJ, Lee JM, Jeong GH, Quintana LF, Moiseev S, Vaglio A, Tesar V, Geetha D, Shin JIL, Kronbichler A. Induction and maintenance of remission with mycophenolate mofetil in ANCA-associated vasculitis: a systematic review and meta-analysis. *Nephrol Dial Transplant* 2022; **37**: 2190-2200 [PMID: 34910216 DOI: 10.1093/ndt/gfab357]
- 5 Jayne D, Blockmans D, Luqmani R, Moiseev S, Ji B, Green Y, Hall L, Roth D, Henderson RB, Merkel PA; BREVAS Study Collaborators. Efficacy and Safety of Belimumab and Azathioprine for Maintenance of Remission in Antineutrophil Cytoplasmic Antibody-Associated Vasculitis: A Randomized Controlled Study. *Arthritis Rheumatol* 2019; **71**: 952-963 [PMID: 30666823 DOI: 10.1002/art.40802]
- 6 Takenaka K, Ohba T, Suhara K, Sato Y, Nagasaka K. Successful treatment of refractory aortitis in antineutrophil cytoplasmic antibody-associated vasculitis using tocilizumab. *Clin Rheumatol* 2014; **33**: 287-289 [PMID: 24357324 DOI: 10.1007/s10067-013-2457-2]



- 7 **Sakai R**, Kondo T, Kikuchi J, Shibata A, Chino K, Okuyama A, Takei H, Amano K. Corticosteroid-free treatment of tocilizumab monotherapy for microscopic polyangiitis: a single-arm, single-center, clinical trial. *Mod Rheumatol* 2016; **26**: 900-907 [PMID: [26934300](#) DOI: [10.3109/14397595.2016.1160968](#)]
- 8 **Sakai R**, Kondo T, Kurasawa T, Nishi E, Okuyama A, Chino K, Shibata A, Okada Y, Takei H, Nagasawa H, Amano K. Current clinical evidence of tocilizumab for the treatment of ANCA-associated vasculitis: a prospective case series for microscopic polyangiitis in a combination with corticosteroids and literature review. *Clin Rheumatol* 2017; **36**: 2383-2392 [PMID: [28733791](#) DOI: [10.1007/s10067-017-3752-0](#)]
- 9 **Sakai R**, Shibata A, Chino K, Kondo T, Okuyama A, Takei H, Amano K. Corticosteroid- and cyclophosphamide-free treatment of anti-neutrophil cytoplasmic antibody-associated vasculitis using tocilizumab. *Mod Rheumatol* 2015; **25**: 810-811 [PMID: [25736354](#) DOI: [10.3109/14397595.2015.1021138](#)]
- 10 **Morrisroe K**, Wong M. Drug-induced hypereosinophilia related to tocilizumab therapy for rheumatoid arthritis. *Rheumatology (Oxford)* 2015; **54**: 2113-2114 [PMID: [26224305](#) DOI: [10.1093/rheumatology/kev275](#)]
- 11 **Sumida K**, Ubara Y, Suwabe T, Hayami N, Hiramatsu R, Hasegawa E, Yamanouchi M, Hoshino J, Sawa N, Takemoto F, Takaichi K, Ohashi K. Complete remission of myeloperoxidase-anti-neutrophil cytoplasmic antibody-associated crescentic glomerulonephritis complicated with rheumatoid arthritis using a humanized anti-interleukin 6 receptor antibody. *Rheumatology (Oxford)* 2011; **50**: 1928-1930 [PMID: [21719417](#) DOI: [10.1093/rheumatology/ker222](#)]



Published by **Baishideng Publishing Group Inc**  
7041 Koll Center Parkway, Suite 160, Pleasanton, CA 94566, USA

**Telephone:** +1-925-3991568

**E-mail:** [bpgoffice@wjgnet.com](mailto:bpgoffice@wjgnet.com)

**Help Desk:** <https://www.f6publishing.com/helpdesk>

<https://www.wjgnet.com>

