

# World Journal of *Clinical Cases*

*World J Clin Cases* 2023 February 26; 11(6): 1224-1433



## Contents

Thrice Monthly Volume 11 Number 6 February 26, 2023

### OPINION REVIEW

- 1224** Collagen matrix scaffolds: Future perspectives for the management of chronic liver diseases  
*Martinez-Castillo M, Altamirano-Mendoza I, Zielinski R, Priebe W, Piña-Barba C, Gutierrez-Reyes G*

### MINIREVIEWS

- 1236** Sex dimorphism and metabolic profiles in management of metabolic-associated fatty liver disease  
*Martin-Grau M, Monleon D*
- 1245** Epidemiology and etiology of chemical ocular injury: A brief review  
*Akgun Z, Selver OB*
- 1252** Review of the prevalence, diagnostics, and containment measures of the current mpox outbreak  
*Sanyaolu A, Marinkovic A, Okorie C, Prakash S, Haider N, Dixon Y, Izurieta R, Badaru O, Smith S*
- 1261** Clinical and pathophysiological understanding of the hepatorenal syndrome: Still wrong or still not exactly right?  
*Wilde B, Canbay A, Katsounas A*
- 1267** Flare of the silent pandemic in the era of the COVID-19 pandemic: Obstacles and opportunities  
*Rayan RA*
- 1275** Implications of metabolic dysfunction associated fatty liver disease in COVID-19  
*Chakraborty R, Sharma D, Kapoor DU, Dwivedi A, Khabiya R, Sen S*

### ORIGINAL ARTICLE

#### Retrospective Study

- 1287** Hyperglycemia in COVID-19 infection without diabetes mellitus: Association with inflammatory markers  
*Geetha HS, Singh G, Sekar A, Gogtay M, Singh Y, Abraham GM, Trivedi N*

#### Clinical Trials Study

- 1299** Efficacy of invisible advancement correction for mandibular retraction in adolescents based on Pancherz analysis  
*Kong L, Liu XQ*

#### Observational Study

- 1310** Survey study of the etiology of non-traumatic altered consciousness in the Emergency Department at Suez Canal University Hospital in Egypt  
*Moussa BS, Abd Elatiff ZM, Kamal Eldin Elhadary GM*

- 1318** Metformin effect on internal carotid artery blood flow assessed by area under the curve of carotid artery Doppler in women with polycystic ovarian syndrome

*Akram W, Nori W, Abdul Ghani Zghair M*

- 1330** Effect of continuous nursing combined with respiratory exercise nursing on pulmonary function of postoperative patients with lung cancer

*Qiu QX, Li WJ, Ma XM, Feng XH*

### CASE REPORT

- 1341** Functioning gonadotroph adenoma with hyperestrogenemia and ovarian hyperstimulation in a reproductive-aged woman: A case report and review of literature

*He Y, Gao YT, Sun L*

- 1349** Clinical manifestations of adult hereditary spherocytosis with novel *SPTB* gene mutations and hyperjaundice: A case report

*Jiang N, Mao WY, Peng BX, Yang TY, Mao XR*

- 1356** Post-traumatic cauda equina nerve calcification: A case report

*Liu YD, Deng Q, Li JJ, Yang HY, Han XF, Zhang KD, Peng RD, Xiang QQ*

- 1365** Endometriosis-associated endometrioid adenocarcinoma of the fallopian tube synchronized with endometrial adenocarcinoma: A case report

*Feng JY, Jiang QP, He H*

- 1372** Gemcitabine-induced peripheral vascular disease and prolonged response in a patient with metastatic pancreatic adenocarcinoma: A case report

*Fabien MB, Elodie P, Anna S, Addeo P, Meher B*

- 1379** Epidemic Japanese B encephalitis combined with contactin-associated protein-like 2 antibody-positive autoimmune encephalitis: A case report

*Huang P*

- 1385** Acute pancreatitis as initial presentation of acute myeloid leukemia-M2 subtype: A case report

*Yang WX, An K, Liu GF, Zhou HY, Gao JC*

- 1393** Postoperative jaundice related to *UGT1A1* and *ABCB11* gene mutations: A case report and literature review

*Jiang JL, Liu X, Pan ZQ, Jiang XL, Shi JH, Chen Y, Yi Y, Zhong WW, Liu KY, He YH*

- 1403** Hidrotic ectodermal dysplasia in a Chinese pedigree: A case report

*Liao MY, Peng H, Li LN, Yang T, Xiong SY, Ye XY*

- 1410** Hepatitis A virus-associated acute acalculous cholecystitis in an adult-onset Still's disease patient: A case report and review of the literature

*Chang CH, Wang YY, Jiao Y*

- 1419** Transverse myelitis caused by herpes zoster following COVID-19 vaccination: A case report

*Cho SY, Jang BH, Seo JW, Kim SW, Lim KJ, Lee HY, Kim DJ*

- 1426** Primary malignant melanoma of the esophagus: A case report

*Wang QQ, Li YM, Qin G, Liu F, Xu YY*

**ABOUT COVER**

Editorial Board Member of *World Journal of Clinical Cases*, Goran Augustin, MD, MSc, PhD, Assistant Professor, Senior Scientist, Surgeon, Department of Surgery, University Hospital Centre Zagreb, Zagreb 10000, Croatia. [augustin.goran@gmail.com](mailto:augustin.goran@gmail.com)

**AIMS AND SCOPE**

The primary aim of *World Journal of Clinical Cases* (WJCC, *World J Clin Cases*) is to provide scholars and readers from various fields of clinical medicine with a platform to publish high-quality clinical research articles and communicate their research findings online.

WJCC mainly publishes articles reporting research results and findings obtained in the field of clinical medicine and covering a wide range of topics, including case control studies, retrospective cohort studies, retrospective studies, clinical trials studies, observational studies, prospective studies, randomized controlled trials, randomized clinical trials, systematic reviews, meta-analysis, and case reports.

**INDEXING/ABSTRACTING**

The WJCC is now abstracted and indexed in Science Citation Index Expanded (SCIE, also known as SciSearch®), Journal Citation Reports/Science Edition, Current Contents®/Clinical Medicine, PubMed, PubMed Central, Scopus, Reference Citation Analysis, China National Knowledge Infrastructure, China Science and Technology Journal Database, and Superstar Journals Database. The 2022 Edition of Journal Citation Reports® cites the 2021 impact factor (IF) for WJCC as 1.534; IF without journal self cites: 1.491; 5-year IF: 1.599; Journal Citation Indicator: 0.28; Ranking: 135 among 172 journals in medicine, general and internal; and Quartile category: Q4. The WJCC's CiteScore for 2021 is 1.2 and Scopus CiteScore rank 2021: General Medicine is 443/826.

**RESPONSIBLE EDITORS FOR THIS ISSUE**

Production Editor: *Ying-Yi Yuan*; Production Department Director: *Xu Guo*; Editorial Office Director: *Jin-Lei Wang*.

**NAME OF JOURNAL**

*World Journal of Clinical Cases*

**ISSN**

ISSN 2307-8960 (online)

**LAUNCH DATE**

April 16, 2013

**FREQUENCY**

Thrice Monthly

**EDITORS-IN-CHIEF**

Bao-Gan Peng, Jerzy Tadeusz Chudek, George Kontogeorgos, Maurizio Serati, Ja Hyeon Ku

**EDITORIAL BOARD MEMBERS**

<https://www.wjnet.com/2307-8960/editorialboard.htm>

**PUBLICATION DATE**

February 26, 2023

**COPYRIGHT**

© 2023 Baishideng Publishing Group Inc

**INSTRUCTIONS TO AUTHORS**

<https://www.wjnet.com/bpg/gerinfo/204>

**GUIDELINES FOR ETHICS DOCUMENTS**

<https://www.wjnet.com/bpg/GerInfo/287>

**GUIDELINES FOR NON-NATIVE SPEAKERS OF ENGLISH**

<https://www.wjnet.com/bpg/gerinfo/240>

**PUBLICATION ETHICS**

<https://www.wjnet.com/bpg/GerInfo/288>

**PUBLICATION MISCONDUCT**

<https://www.wjnet.com/bpg/gerinfo/208>

**ARTICLE PROCESSING CHARGE**

<https://www.wjnet.com/bpg/gerinfo/242>

**STEPS FOR SUBMITTING MANUSCRIPTS**

<https://www.wjnet.com/bpg/GerInfo/239>

**ONLINE SUBMISSION**

<https://www.f6publishing.com>

## Postoperative jaundice related to *UGT1A1* and *ABCB11* gene mutations: A case report and literature review

Jin-Lian Jiang, Xia Liu, Zhong-Qin Pan, Xiao-Ling Jiang, Jun-Hua Shi, Ya Chen, Yu Yi, Wei-Wei Zhong, Kang-Yan Liu, Yi-Huai He

**Specialty type:** Medicine, research and experimental

**Provenance and peer review:**

Unsolicited article; Externally peer reviewed.

**Peer-review model:** Single blind

**Peer-review report's scientific quality classification**

Grade A (Excellent): 0

Grade B (Very good): 0

Grade C (Good): C, C

Grade D (Fair): D

Grade E (Poor): 0

**P-Reviewer:** Furugen M, Japan; Sanal MG, India; Yao G, China

**Received:** November 8, 2022

**Peer-review started:** November 8, 2022

**First decision:** November 24, 2022

**Revised:** December 7, 2022

**Accepted:** February 2, 2023

**Article in press:** February 2, 2023

**Published online:** February 26, 2023



**Jin-Lian Jiang, Xia Liu, Xiao-Ling Jiang, Ya Chen, Yu Yi, Kang-Yan Liu, Yi-Huai He**, Department of Infectious Diseases, Affiliated Hospital of Zunyi Medical University, Zunyi 563000, Guizhou Province, China

**Zhong-Qin Pan**, Department of Infectious Diseases, People's Hospital Qiandongnan Miao and Dong Autonomous Prefecture, Kaili 556000, Guizhou Province, China

**Jun-Hua Shi**, Department of Radiology, Affiliated Hospital of Zunyi Medical University, Zunyi 563000, Guizhou Province, China

**Wei-Wei Zhong**, Department of Gastroenterology, First People's Hospital of Jinmen, Jinmen 448000, Hubei Province, China

**Corresponding author:** Yi-Huai He, MD, Director, Department of Infectious Diseases, Affiliated Hospital of Zunyi Medical University, No. 149 Dalian Road, Huichuan District, Zunyi 563000, Guizhou Province, China. [993565989@qq.com](mailto:993565989@qq.com)

### Abstract

#### BACKGROUND

Patients with obstructive jaundice caused by intrahepatic bile duct stones can be effectively managed by surgery. However, some patients may develop postoperative complications, liver failure, and other life-threatening situations. Here, we report a patient with mutations in the uridine 5'-diphospho-glucuronosyltransferase 1A1 (*UGT1A1*) and bile salt export pump (adenosine triphosphate-binding cassette subfamily B member 11, *ABCB11*) genes who presented multiple intrahepatic bile duct stones and cholestasis, and the jaundice of the patient increased after partial hepatectomy.

#### CASE SUMMARY

A 52-year-old male patient admitted to the hospital on October 23, 2021, with a progressive exacerbation of jaundice, was found to have multiple intrahepatic bile duct stones with the diagnoses of obstructive jaundice and acute cholecystitis. Subsequently, the patient underwent left hepatectomy with biliary exploration, stone extraction, T-tube drainage, and cholecystectomy without developing any intraoperative complications. The patient had a dark urine color with worsening jaundice postoperatively and did not respond well to plasma exchange and other symptomatic and supportive treatments. Since the progressive increase in postoperative bilirubin could not be clinically explained with any potential

reason, including, if not at all, viral infection, cholangitis, autoimmune liver disease, and other causes, the patient underwent whole-exon screening for any genetic diseases, which surprisingly identified *UGT1A1* and *ABCB11* gene mutations related to glucuronidation of indirect bilirubin as well as bile acid transport in hepatocytes, respectively. Thus, we hypothesized that postoperative refractory cholestasis might result from *UGT1A1* and *ABCB11* gene mutations and further recommended liver transplantation to the patient, who eventually declined it and died from liver failure six months later.

### CONCLUSION

Surgery may aggravate cholestasis in patients with multiple intrahepatic bile duct stones and cholestasis associated with *UGT1A1* and *ABCB11* gene mutations. A liver transplant may be the best option if active medical treatment fails.

**Key Words:** Cholestasis; Intrahepatic bile duct stones; Postoperative jaundice; adenosine triphosphate-binding cassette subfamily B member 11; Uridine 5'-diphospho-glucuronosyltransferase 1A1; Case report

©The Author(s) 2023. Published by Baishideng Publishing Group Inc. All rights reserved.

**Core Tip:** We presented a case of multiple intrahepatic bile duct stones, cholestasis, and progressive jaundice after surgical treatment, which was diagnosed upon the finding of adenosine triphosphate-binding cassette subfamily B member 11 (*ABCB11*) and uridine 5'-diphospho-glucuronosyltransferase 1A1 (*UGT1A1*) gene mutation from the genetic study. Since the patient refused to undergo liver transplantation, his postoperative aggravating jaundice was medically managed, but he soon died due to liver failure. The *UGT1A1* gene is related to the glucuronidation of indirect bilirubin. Its mutation leads to increased indirect bilirubin, while the *ABCB11* gene is involved in bile transport, and its mutation may lead to disturbance of bile acid transport, changes in bile composition, cholestasis, and the formation of intrahepatic bile duct stones. Surgical treatment in such patients may induce exacerbation of cholestasis, and liver transplantation should be the preferred treatment if medical management fails.

**Citation:** Jiang JL, Liu X, Pan ZQ, Jiang XL, Shi JH, Chen Y, Yi Y, Zhong WW, Liu KY, He YH. Postoperative jaundice related to *UGT1A1* and *ABCB11* gene mutations: A case report and literature review. *World J Clin Cases* 2023; 11(6): 1393-1402

**URL:** <https://www.wjgnet.com/2307-8960/full/v11/i6/1393.htm>

**DOI:** <https://dx.doi.org/10.12998/wjcc.v11.i6.1393>

## INTRODUCTION

Obstructive jaundice caused by intrahepatic bile duct stones is relatively common, and its chief symptoms entail progressive, painless jaundice, occasionally accompanied by right upper quadrant pain, anorexia and greasy skin, itchy skin, dark yellow urine, and clay-colored stool. Primary intrahepatic stone disease (PIS) tends to occur regionally with familial aggregation[1] and carries a higher incidence in Southeast Asia than in Western countries[2,3]. Recurrent episodes and continued progression to advanced stages of PIS may lead to biliary cirrhosis or intrahepatic cholangiocarcinoma [4], two of which account for the most important causes of death from benign biliary tract disease.

PIS requires complex management with multiple surgical interventions, and hepatectomy has been the primary choice. However, less than 1% of patients may experience increased postoperative jaundice, liver failure, and even life-threatening conditions, which are related to various factors, including the underlying liver disease, the number of liver segments removed, intraoperative liver ischemia time, intraoperative continuous blood transfusion, postoperative hematoma, parenteral nutrition, anesthetics and drugs (such as antibiotics, analgesics), and sepsis and oxidative stress[5-7]. Moreover, although the PIS pathogenesis remains undefined, the disease possesses distinct ethnic and regional characteristics. Therefore, genetic factors may also be involved in the pathogenesis of PIS. Currently, gene mutation-related multiple intrahepatic bile duct stones, cholestasis, and postoperative jaundice aggravation have not received much clinical attention. We report a case of uridine diphosphate glucuronosyltransferase 1A1 (*UGT1A1*) and adenosine triphosphate-binding cassette subfamily B member 11 (*ABCB11*) gene mutations with multiple intrahepatic bile duct stones, cholestasis, and progressive jaundice after surgical treatment. Furthermore, we present a literature review on the potential effect, mechanism, and prognosis of *UGT1A1* and *ABCB11* gene mutations on intrahepatic bile duct stones and postoperative jaundice.



## CASE PRESENTATION

### Chief complaints

A 52-year-old male was admitted to the hospital on October 23, 2021, with yellowish skin and sclera for three months and a progressive exacerbation of postoperative jaundice for one month.

### History of present illness

Three months ago, the patient noticed yellowish skin/sclera and dark-brown urine without any apparent predisposition, which had worsened with abdominal pain a month later, so he was admitted to a local hospital for further management. The post-admission examination of liver function test revealed normal transaminases but elevated levels of direct bilirubin, indirect bilirubin, gamma-glutamyl transpeptidase (GGT), and total bile acid (Table 1). Upper abdominal computed tomography (CT) examination showed multiple intrahepatic and extrahepatic bile duct stones and obstructions, cholestasis, and gallbladder enlargement. The patient was diagnosed with obstructive jaundice having multiple intrahepatic bile duct stones with acute cholecystitis, so he underwent left external hepatectomy with bile duct exploration, stone extraction, T-tube drainage, and cholecystectomy on September 9, 2021. The abdominal pain was significantly relieved postoperatively without fever, nausea, vomiting, or any sign of abdominal distension, but the urine color had been persistently getting darker with aggravation of jaundice of skin and sclera. Liver function re-examination showed a progressive increase in the bilirubin level compared to before the operation. Thus, the patient was further managed with plasma exchange and symptomatic and supportive treatments. However, the effect was not good, and he was admitted to our service for further diagnosis and treatment.

### History of past illness

He reported a history of hypertension for ten years and did not take medication regularly. However, he denied a history of long-term heavy drinking, exposure to poisons and traditional Chinese medicines, and trauma.

### Personal and family history

The patient denied any family history of malignancy and other hereditary disorders.

### Physical examination

The patient had a Body Mass Index of 23.44, and his vital signs were stable, with clear consciousness. Moreover, the patient presented with the face of chronic liver disease and severe jaundice of the skin and sclera but did not have liver palm and spider nevus. Heart and lung examinations did not find any obvious abnormality, while the abdominal physical localized a T-tube drainage tube in place at the right abdomen with palpable tenderness at the right upper quadrant in the absence of rebound pain, muscle tension, and shifting dullness.

### Laboratory examinations

Dynamic changes in biochemical indicators of liver function tests were listed as follows (Table 1): On Sep 6, 2021, preoperative LFTs were triglyceride (TG) as 3.62 mmol/L (Ref: < 1.7 mmol/L), total cholesterol (TC) as 4.46 mmol/L (Ref: < 5.2 mmol/L), high density lipoprotein cholesterol (HDL-C) as 0.17 mmol/L (Ref: 0.91-1.55 mmol/L), and low density lipoprotein cholesterol (LDL-C): 3.14 mmol/L (Ref: < 3.12 mmol/L).

On October 23, 2021, postoperative LFTs showed TG as 3.46 mmol/L, TC as 5.16 mmol/L, HDL-C as 0.64 mmol/L, and LDL-C as 3.23 mmol/L.

On October 23, 2021, C-reactive protein and coagulation function were checked with normal findings, hepatitis B and viral infection were ruled out with negative antigen in the serum antibody tests, and a negative autoimmune antibody panel ruled out autoimmune hepatitis. Other tests were in the normal ranges, including thyroid function tests, ceruloplasmin, total iron binding capacity, and unsaturated iron binding capacity.

On October 23, 2021, bile drainage fluid was sent for culture, which came back with positive *Pseudomonas putida*, being sensitive to antibiotics such as piperacillin, ceftriaxone, and ceftazidime.

On November 17, 2021, the culture came back with negative gram-negative bacilli lipopolysaccharide and fungal (1-3)-B-D glucan.

On November 19, 2021, metagenomics next-generation sequencing (mNGS) on peripheral blood was reported back without detections of bacteria, mycobacteria, fungi, viruses, mycoplasma, Chlamydia, rickettsia, and parasites.

### Imaging examinations

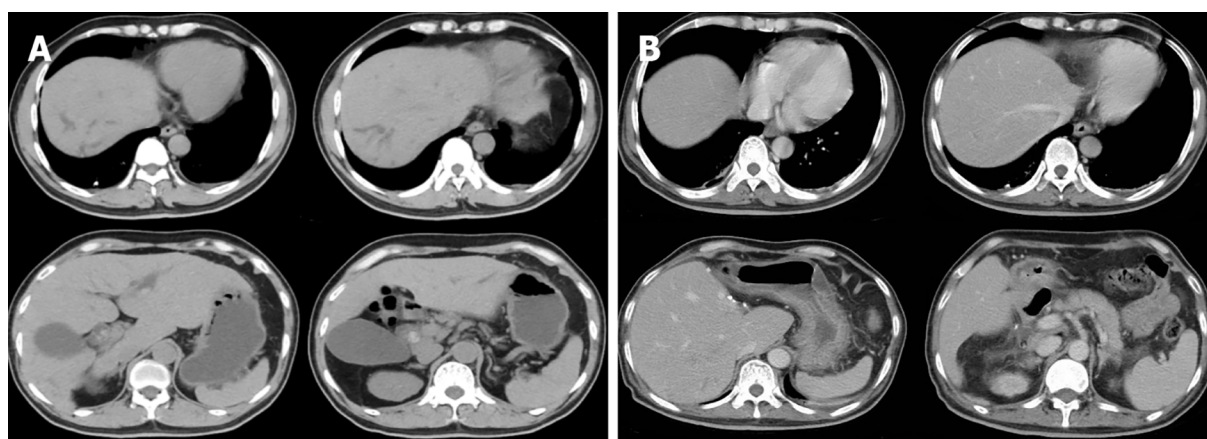
A preoperative non-contrast CT scan of the upper abdomen unveiled left intrahepatic and multiple bile duct stones with dilated intra- and extrahepatic bile ducts and an enlarged gallbladder (Figure 1A). Postoperative non-contrast CT scan and magnetic resonance imaging of the upper abdomen illustrated



**Table 1** Dynamic changes of biochemical indexes of liver function in patients

Date	ALT, U/L	AST, U/L	TBIL, $\mu\text{mol/L}$	DBIL, $\mu\text{mol/L}$	IBIL, $\mu\text{mol/L}$	GGT, U/L	ALP, U/L	TBA, U/L
	Ref: 0-40	Ref: 0-34	Ref: 5.1-19.0	Ref: 1.7-6.8	Ref: 1.7-13.2	Ref: 10-60	Ref: 45-120	Ref: 0-50
2021-09-06 (Pre-operative)	33.0	28.0	135.1↑	84.1↑	51.0↑	77.0↑	105.0	208.0↑
2021-09-10 (Post-operative)	311↑	545↑	167.6↑	106.9↑	60.7↑	48.0	126.0↑	120.8↑
2021-09-22	39.0	23.0	187.1↑	109.4↑	77.7↑	32.0	78.0	53.0↑
2021-09-28 (Before discharge)	47.0↑	32.0	286.2↑	166.2↑	120.0↑	34.0	97.0	80.9↑
2021-10-23 (On readmission)	43.0↑	32.0	593.3↑	285.9↑	307.4↑	36.0	109.0	131.4↑
2021-10-30 (After drug treatment)	30.0	27.0	602.2↑	283.2↑	319.0↑	23.0	97.0	213.6↑
2021-11-14 (After plasma exchange)	22.0	33.0	230.6↑	141.1↑	89.5↑	28.0	76.0	151.9↑
2021-11-17 (Before discharge)	29.0	44.0↑	336.7↑	193.5↑	143.2↑	34.0	88.0	183.0↑

ALP: Alkaline phosphatase; ALT: Alanine transaminase; AST: Aspartate aminotransferase; DBIL: Direct bilirubin; GGT: Gamma-glutamyl transpeptidase; IBIL: Indirect bilirubin; TBIL: Total bilirubin; TBA: Total bile acids.



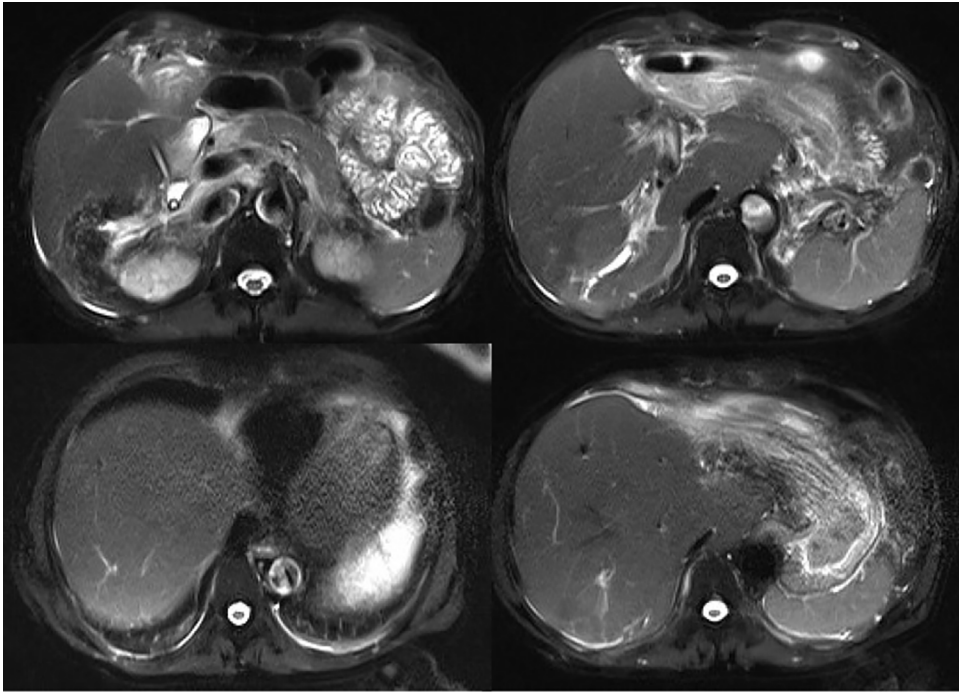
DOI: 10.12998/wjcc.v11.i6.1393 Copyright ©The Author(s) 2023.

**Figure 1** Computed tomography image. A: The preoperative computed tomography (CT) image of the upper abdomen of the patient: Normal liver parenchyma with dilated intrahepatic as well as common bile duct (about 18 mm) and enlarged gallbladder without wall-thickening; B: Postoperative CT image of the upper abdomen: the enlarged and deformed remnant liver with dilated intrahepatic bile duct in the upper segment of the right posterior; the portal vein is widened, the widest diameter is about 1.4 cm. The spleen was normal in size and shape.

signs of liver cirrhosis with multiple intrahepatic bile duct stones in the upper right posterior lobe of the liver with cholangitis, peri-cholangitis, and portal hypertension (Figure 1B) and (Figure 2). Besides, postoperative magnetic resonance cholangiopancreatography further confirmed multiple intrahepatic bile duct stones with mild dilatation in the upper right posterior lobe of the liver (Figure 3A), and T-tube angiography could not visualize the right and left hepatic duct but the lower end of the common bile duct (Figure 3B). Postoperative histopathologic examination exhibited cholestatic liver disease and intrahepatic bile duct dilatation with chronic inflammation (Figure 4). Furthermore, sequential immuno-histochemical staining unveiled mild and delicate hyperplasia along biliary ducts, then Alpha-Smooth Muscle Actin staining spotted a few activated hepatic stellate cells, Masson and Sirius red staining revealed fibrous tissue hyperplasia in the portal area with an interlobular short fibrous septum, Periodic Acid Schiff Diastase Stain displayed a little waxy substance in Kupffer cells, and Prussian blue signified a little iron granules deposition in hepatocytes and Kupffer cells. Besides, copper staining was negative.

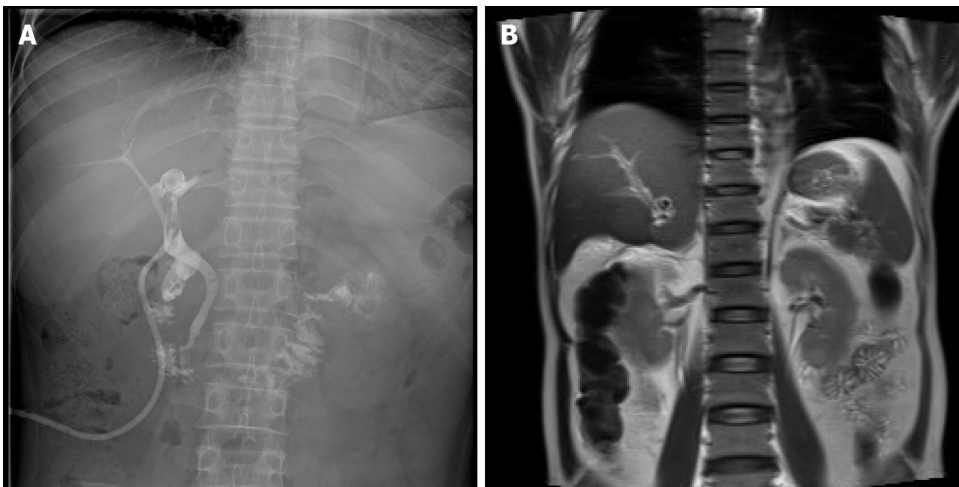
#### **Intra-hospital management**

During hospitalization, the patient was managed on the diagnoses of cholestatic hepatitis, biliary tract infection, and decompensated liver cirrhosis with piperacillin-tazobactam sodium, dexamethasone, and supportive medications for protecting the liver and eliminating jaundice. After the treatments, re-examining white blood cells and C-reactive protein did not confirm any ongoing infection. However, the bilirubin was significantly higher than before. Afterward, intermittent plasma exchange replacement



DOI: 10.12998/wjcc.v11.i6.1393 Copyright ©The Author(s) 2023.

**Figure 2 Postoperative magnetic resonance imaging of the upper abdomen.** Enlarged and deformed liver with uneven signals in the liver parenchyma and dilated intrahepatic bile duct in the upper right posterior lobe of the liver. Multiple nodular short T2 signal in the dilated and rigid bile duct with increased T2 weighted imaging signal in the surrounding liver parenchyma. The portal vein is widened with a size of 1.4 cm.



DOI: 10.12998/wjcc.v11.i6.1393 Copyright ©The Author(s) 2023.

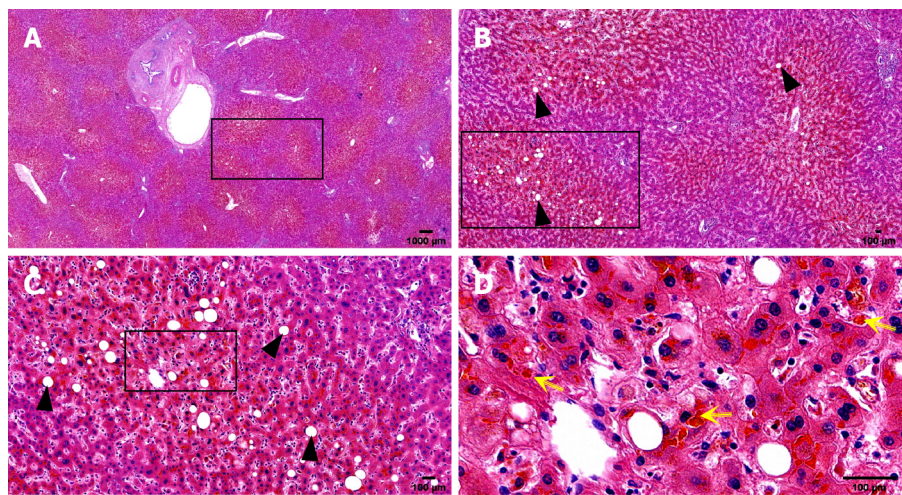
**Figure 3 T-tube and magnetic resonance cholangiopancreatography images.** A: T-tube angiography: the left and right hepatic ducts were not visualized, the bile duct was rigid, and the lower end of the common bile duct was unobstructed; B: Magnetic resonance cholangiopancreatography: The intrahepatic bile duct in the upper right posterior lobe of the liver was dilated, and multiple nodular short T2 signals were seen in the lumen. Gallbladder not shown.

therapy with double plasma molecular absorption system (DPMAS) was administered to the patient four times to control progressive jaundice but failed to stop the progression.

CT examination was repeated after this admission to unveil the signs of cirrhosis, which was paradoxical to the preoperative finding of normal liver. Further pathological examination of the resected liver tissue revealed fibrous tissue hyperplasia in the hepatic portal area, suggesting that the patient only possessed early hepatic fibrosis before surgery. Taken together, we advised the patient of whole-exon screening to fish out any genetic disorder to search for the cause of cirrhosis, which surprisingly revealed *UGT1A1* and *ABCB11* gene mutations (Table 2 and Figure 5).

Table 2 Results of whole-exon genetic testing for the genetic disorders				
Gene	Chromosomal position	Basic variation information	Zygote type	Inheritance patterns
UGT1A1	chr2:234669144	NM_000463.3:c.211G>A (p.Gly71Arg)	Hom	AR
	chr2:234681059	NM_000463.3:c.1456T>G (p.Tyr486Asp)	Het	AR
ABCB11	chr2:169787353	NM_003742.4:c.3233T>C (p.Ile1078Thr)	Het	AR
	chr2:169869837	NM_003742.4:c.334A>G (p.Ile112Val)	Het	AR

AR: Autosomal recessive; Hom: Homozygous; Het: Heterozygous.



DOI: 10.12998/wjcc.v11.i6.1393 Copyright ©The Author(s) 2023.

**Figure 4 Histopathological biopsy of the liver.** The portal area was enlarged to varying degrees, with hyperplasia of fibrous tissue, infiltration of a moderate amount of lymphocytes and a small number of plasma cells, minor bile duct damage, fibrosis around a small number of small bile ducts, and mild bile duct hyperplasia, mild edema of hepatocytes, a few balloon-like degenerated hepatocytes, a few glycogenuclear hepatocytes, bulicular and microbulicular steatosis of hepatocytes (hepatic steatosis cells < 5%), irregular distribution, rare punctate necrosis. Some hepatocytes cholestatic pigment granules can be seen, and some bile ducts are dilated and cholestatic. Yellow arrow: Cholestatic pigment particles; Black triangle: Hepatocyte adipose change. A: Hematoxylin-eosin (HE) (× 1); B: HE (× 4); C: HE (× 10); D: HE (× 40).

## FINAL DIAGNOSIS

Based on the clinical, pathological, and genetic findings, the patient was diagnosed with intrahepatic bile duct stones with cholestasis associated with *UGT1A1* and *ABCB11* gene mutations, biliary tract infection, and decompensated liver cirrhosis.

## TREATMENT

Piperacillin and tazobactam sodium were first given to prevent infection, dexamethasone to reduce inflammation, compound glycyrrhizic acid monoamine S, adenosine methionine and ursodeoxycholic acid to protect the liver and eliminate jaundice, and plasma exchange therapy DPMAS was given later, but the effect was poor. Liver transplantation was recommended, but the patient and his family refused for financial reasons.

## OUTCOME AND FOLLOW-UP

Since the patient and his family refused liver transplantation, his condition quickly deteriorated after discharge, and he died of liver failure six months later.



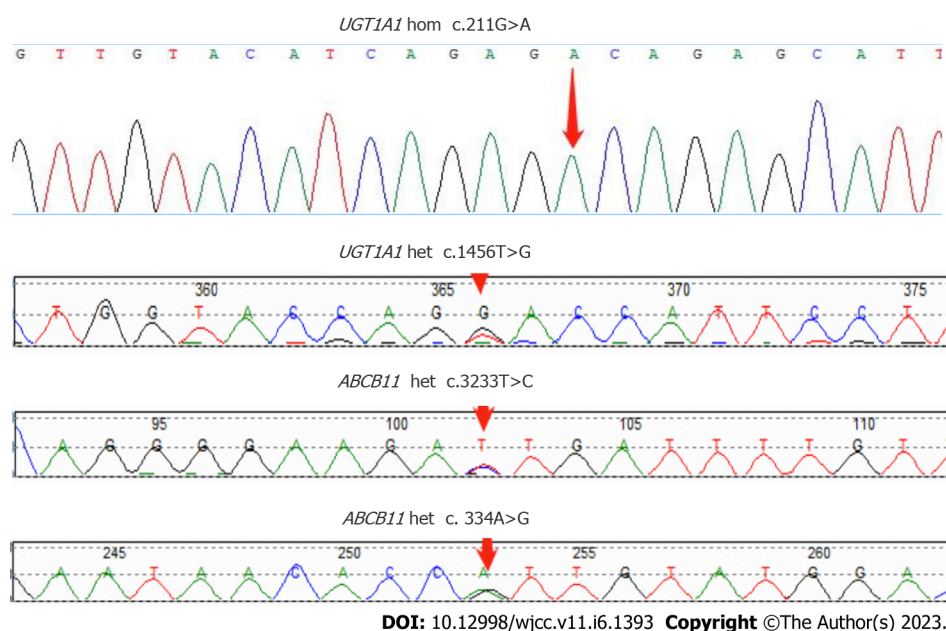


Figure 5 Sanger sequencing map of the patient's *ABCB11* and *UGT1A1* genes with designated mutation sites.

## DISCUSSION

The patient, diagnosed with obstructive jaundice from multiple intrahepatic bile duct stones, underwent left hepatectomy combined with biliary exploration, T-tube drainage, and cholecystectomy. However, he developed aggravation of postoperative jaundice, featured as the progressive increase of bilirubin, imaging signs of liver cirrhosis without blatant biliary obstruction, and ineffective medical therapy, including plasma exchange DPMAS. This postoperative jaundice with significant cellular injuries was pathologically characterized by cholestasis on the resected left liver, which was further examined with the whole-exon examination, identifying hereditary disease genes that showed *UGT1A1* and *ABCB11* gene mutations. The *UGT1A1* gene encodes the enzyme to glucuronidate indirect bilirubin for its removal from the body. Hence, its mutation causes indirect bilirubin elevation as the main feature. *ABCB11* gene encodes the bile salt export pump (BSEP), and its mutation leads to bile acid transport disorder, changes in bile composition, cholestasis, and the formation of cholesterol stones with the elevation of direct bilirubin. In this case, both direct and indirect bilirubin were significantly elevated. Therefore, by comprehensive analysis, multiple intrahepatic bile duct stones and cholestasis, in this case, may be related to *UGT1A1* and *ABCB11* gene mutations.

The *UGT1A1* gene is located at 2q37 of the human genome and encodes uridine 5'-diphosphate-glucuronidase, the only enzyme to glucuronidate bilirubin in the liver[8,9]. *UGT1A1* gene mutations cause unconjugated hyperbilirubinemia in both Crigler-Najjar syndrome (CN) and Gilbert syndrome (GS)[10]. Crigler-Najjar syndrome is classified as type I and type II variants, which reduce *UGT1A1* enzymatic activity to 0% and 10%, respectively, while the enzyme in GS can only release 30% of its activity[10]. The *ABCB11* gene is located at locus 2q24 in the human genome and contains 28 exons[11], which can be translated into BSEP with a molecular weight of approximately 150–170 kDa. The BSEP proteins, which can be found along the canalicular membrane of hepatocytes, consist of two tandem homologous moieties to harbor an intracellular nucleotide-binding domain (NBD) and six transmembrane domains, which can be energized for transporting bile acids out of the cells upon hydrolysis of ATP by NBD. Mutations in the *ABCB11* gene result in the accumulation of primary bile acids in the intercellular space of the liver, thereby increasing the levels of bilirubin in serum and bile salts in the liver and blood. Studies have shown that mutations in the *ABCB11* gene are closely associated with cholestasis, including benign recurrent intrahepatic cholestasis[12,13], progressive familial intrahepatic cholestasis[14,15] and intrahepatic cholestasis of pregnancy[16,17]. In addition, beyond its transporting capacity, BSEP can facilitate cholesterol solubilization and inhibit its supersaturated crystallization[18,19]. Taken together, decreased bile salt secretion due to the BSEP alteration from the mutation of the *ABCB11* gene subsequently superimposes the formation of cholesterol gallstones along with abnormal bile metabolism and composition changes, which contribute to the pathogenesis of PIS[20]. Furthermore, cholestasis assists in depositing bile components to form intrahepatic bile duct stones and accumulates toxic bile acids, which lead to biliary wall injury and inflammation[21]. Long-term inflammation can lead to the thickening and stenosis of the biliary wall, thereby exacerbating cholestasis and promoting the formation of intrahepatic bile duct stones, further exacerbating cholestasis. This vicious cycle thus leads to disease progression[22,23]. In our patient, the

point mutation of c.211G>A (p.Gly71Arg) and c.1456T>G (p.Tyr486Asp) was found in exon 1 and exon 5 of the *UGT1A1* gene, respectively, which are most frequently seen in CN-II[24,25]. Along with the *ABCB11* gene mutation, both genes cooperatively aggravate intrahepatic cholestasis and hepatocellular injury before and after the surgery.

Intrahepatic bile duct stones and cholestasis can be managed with hepatic lobectomy, choledochojejunostomy, Roux-Y anastomosis, simple choledocholithotomy, T-tube drainage, or liver transplantation according to the different intra- and extrahepatic biliary stones and clinical manifestations of each patient. After the obstructive pathologies in most patients with obstructive jaundice are removed surgically, the bilirubin levels drop, and the liver function gradually improves. However, in a few patients, bilirubin levels do not decrease but increase after surgery with the aggravation of jaundice and persistent intrahepatic cholestasis[26]. Postoperative cholestasis has many predisposing factors, including ischemia-reperfusion injury, the basis of liver cirrhosis, biliary tract infection, and the down-regulation of the expression level of bile acid efflux transporter in liver tissue. Long-term intrahepatic and extrahepatic biliary stones complicated by repeated suppurative cholangitis along the intrahepatic bile duct cause hepatic parenchyma fibrosis, hyperplasia, and pseudolobular formation, subsequently leading to the development of cholestatic liver cirrhosis[27,28], which dysfunctions hepatic uptake, transport, esterification and absorption of bilirubin and further elevates bilirubin level to make the pathogenesis fall into a vicious circle. Although the factors of biliary obstruction can be relieved by the operation, the hepatic injury from the persistent obstruction was deteriorated by anesthesia, ischemia, and inflammatory reactions. In addition to liver cirrhosis, sepsis with endotoxemia can also contribute to postoperative intrahepatic cholestasis by breaching the bile excretion function of hepatocytes[29,30], impairing the ability of hepatocytes to uptake bile salts, affecting the permeability of the cell membrane, and de-functioning bile transport. Furthermore, post-hepatectomy hyperbilirubinemia may be associated with hepatic mitochondrial dysfunction or impaired expression of bile excretion pumps on hepatocyte canalicular membranes[31-33].

In this report, our patient did not exhibit any evidence of liver cirrhosis in the preoperative upper abdominal imaging studies but had the feature of liver cirrhosis in the upper abdominal CT and magnetic resonance imaging one month after the operation. Normally, cirrhosis cannot develop in such a short time unless we might preoperatively omit the existence of this disease entity so that the patient underwent the inappropriate liver resection without classifying the patient according to Child's criteria. Otherwise, another hidden pathology was blinded until the postoperative stage. The postoperative pathological examination of the specimen from the surgery showed signs of early hepatic fibrosis, and the postoperative molecular pathology identified *UGT1A1* and *ABCB11* gene mutations, thereby giving us another perspective on the underlying causes of postoperative developments of cholestasis and cirrhosis. While managing the postoperative cholestasis of this patient, we not only performed T-tube angiography, which showed no obvious intra- and extrahepatic biliary obstruction but also treated the patient with antibiotics according to the drug sensitivity results to the infection and hormone therapy to reduce inflammation. However, since his bilirubin had progressively increased and was not controlled even with plasma exchange DPMAS replacement therapy, we sent the patient to receive genetic testing to identify the underlying causes, which showed the genetic defects in *UGT1A1* and *ABCB11*, thus singling out liver transplantation as the only effective method to the patient.

Interestingly, during the postoperative management, the coagulation function of the patient was always in the normal range, suggesting that the synthesis function of his liver was never perturbed. Such clinical uniqueness could be explained by the fact that his *UGT1A1* and *ABCB11* genes affect bilirubin metabolism and bile transport rather than significantly damaging liver cells and obstructing intra- and extrahepatic bile ducts for postoperative liver decompensation and lack of efficacy in the given treatment. Another issue related to our patient was low serum GGT levels that were paradoxical to its elevation in patients with biliary obstruction. Low GGT could be considered a potential laboratory indicator for non-obstruction caused while working up the patients with cholestasis.

## CONCLUSION

*UGT1A1* and *ABCB11* gene mutations associated with multiple intrahepatic bile duct stones and cholestasis are rare, so they are easy to ignore in clinical practice. Such patients have poor surgical treatment effects, which may induce aggravation of cholestasis, a progressive increase in bilirubin, and rapid progression of liver fibrosis. Therefore, liver transplantation may be the first choice for patients with multiple intrahepatic bile duct stones and cholestasis related to *UGT1A1* and *ABCB11* gene mutations after active medical treatments are ineffective. Patients with clinically found cholestasis should pay attention to whether the GGT level is elevated, which is more valuable for the preliminary judgment of hereditary metabolic intrahepatic cholestasis.

## FOOTNOTES

**Author contributions:** Jiang JL and Liu X contributed equally to this work; Jiang JL, Liu X, Jiang XL, and Yi Y collected medical history; Chen Y and Zhong WW summarized and analyzed the medical history data; He YH and Jiang JL conceived and designed the content of the article; Jiang JL and Liu X wrote the initial paper; He YH, Liu KY, Shi JH, and Pan ZQ revised the paper; He YH had primary responsibility for final content; All authors read and approved the final manuscript.

**Supported by** The Science and Technology Planning Projects of Guizhou Province and Zunyi City, No. QKHJC-ZK[2022]YB642, No. ZSKH-HZ(2022)344, No. gzwjkj2021-071, ZMC-YZ[2018]38, No. ZSKH-HZ[2021]58, and No. ZSKH-HZ[2021]60; The General Project of Hubei Province and Jingmen City, No. 2021YFYB074.

**Informed consent statement:** Written informed consent was obtained from the patient for the publication of this case report.

**Conflict-of-interest statement:** All the authors report no relevant conflicts of interest for this article.

**CARE Checklist (2016) statement:** The authors have read the CARE Checklist (2016), and the manuscript was prepared and revised according to the CARE Checklist (2016).

**Open-Access:** This article is an open-access article that was selected by an in-house editor and fully peer-reviewed by external reviewers. It is distributed in accordance with the Creative Commons Attribution NonCommercial (CC BY-NC 4.0) license, which permits others to distribute, remix, adapt, build upon this work non-commercially, and license their derivative works on different terms, provided the original work is properly cited and the use is non-commercial. See: <https://creativecommons.org/licenses/by-nc/4.0/>

**Country/Territory of origin:** China

**ORCID number:** Jin-Lian Jiang 0000-0002-0791-9680; Xia Liu 0000-0003-4140-184X; Zhong-Qin Pan 0000-0003-1028-4986; Xiao-Ling Jiang 0000-0002-7232-9791; Ya Chen 0000-0002-5618-8124; Yu Yi 0000-0003-0995-4479; Wei-Wei Zhong 0000-0002-9736-8148; Kang-Yan Liu 0000-0002-1286-0943; Yi-Huai He 0000-0002-8639-3436.

**S-Editor:** Liu GL

**L-Editor:** A

**P-Editor:** Liu GL

## REFERENCES

- Meier Y, Pauli-Magnus C, Zanger UM, Klein K, Schaeffeler E, Nussler AK, Nussler N, Eichelbaum M, Meier PJ, Stieger B. Interindividual variability of canalicular ATP-binding-cassette (ABC)-transporter expression in human liver. *Hepatology* 2006; **44**: 62-74 [PMID: 16799996 DOI: 10.1002/hep.21214]
- Lorio E, Patel P, Rosenkranz L, Patel S, Sayana H. Management of Hepatolithiasis: Review of the Literature. *Curr Gastroenterol Rep* 2020; **22**: 30 [PMID: 32383039 DOI: 10.1007/s11894-020-00765-3]
- Li C, Wen T. Surgical management of hepatolithiasis: A minireview. *Intractable Rare Dis Res* 2017; **6**: 102-105 [PMID: 28580209 DOI: 10.5582/ir.2017.01027]
- Meng ZW, Han SH, Zhu JH, Zhou LY, Chen YL. Risk Factors for Cholangiocarcinoma After Initial Hepatectomy for Intrahepatic Stones. *World J Surg* 2017; **41**: 835-843 [PMID: 27766397 DOI: 10.1007/s00268-016-3752-2]
- Tandon A, Roorda AK, Legha P, Sangoi A, Triadafilopoulos G. Mellow Yellow: Diagnosis and Management of Multifactorial Postoperative Jaundice. *Dig Dis Sci* 2016; **61**: 2226-2230 [PMID: 26518416 DOI: 10.1007/s10620-015-3946-8]
- Chung C, Buchman AL. Postoperative jaundice and total parenteral nutrition-associated hepatic dysfunction. *Clin Liver Dis* 2002; **6**: 1067-1084 [PMID: 12516207 DOI: 10.1016/s1089-3261(02)00057-0]
- Pauli-Magnus C, Meier PJ. Hepatobiliary transporters and drug-induced cholestasis. *Hepatology* 2006; **44**: 778-787 [PMID: 17006912 DOI: 10.1002/hep.21359]
- van Es HH, Bout A, Liu J, Anderson L, Duncan AM, Bosma P, Oude Elferink R, Jansen PL, Chowdhury JR, Schurr E. Assignment of the human UDP glucuronosyltransferase gene (UGT1A1) to chromosome region 2q37. *Cytogenet Cell Genet* 1993; **63**: 114-116 [PMID: 8467709 DOI: 10.1159/000133513]
- Memon N, Weinberger BI, Hegyi T, Aleksunes LM. Inherited disorders of bilirubin clearance. *Pediatr Res* 2016; **79**: 378-386 [PMID: 26595536 DOI: 10.1038/pr.2015.247]
- Aiso M, Yagi M, Tanaka A, Miura K, Miura R, Arizumi T, Takamori Y, Nakahara S, Maruo Y, Takikawa H. Gilbert Syndrome with Concomitant Hereditary Spherocytosis Presenting with Moderate Unconjugated Hyperbilirubinemia. *Intern Med* 2017; **56**: 661-664 [PMID: 28321066 DOI: 10.2169/internalmedicine.56.7362]
- Borst P, Elferink RO. Mammalian ABC transporters in health and disease. *Annu Rev Biochem* 2002; **71**: 537-592 [PMID: 12045106 DOI: 10.1146/annurev.biochem.71.102301.093055]
- Hayashi H, Naoi S, Hirose Y, Matsuzaka Y, Tanikawa K, Igarashi K, Nagasaka H, Kage M, Inui A, Kusuhara H. Successful treatment with 4-phenylbutyrate in a patient with benign recurrent intrahepatic cholestasis type 2 refractory to

- biliary drainage and bilirubin absorption. *Hepatol Res* 2016; **46**: 192-200 [PMID: 26223708 DOI: 10.1111/hepr.12561]
- 13 **Thoeni C**, Walderherr R, Scheuerer J, Schmitteckert S, Roeth R, Niesler B, Cutz E, Flechtenmacher C, Goeppert B, Schirmacher P, Lasitschka F. Expression Analysis of ATP-Binding Cassette Transporters ABCB11 and ABCB4 in Primary Sclerosing Cholangitis and Variety of Pediatric and Adult Cholestatic and Noncholestatic Liver Diseases. *Can J Gastroenterol Hepatol* 2019; **2019**: 1085717 [PMID: 31886153 DOI: 10.1155/2019/1085717]
- 14 **Waisbourd-Zinman O**, Surrey LF, Schwartz AE, Russo PA, Wen J. A Rare BSEP Mutation Associated with a Mild Form of Progressive Familial Intrahepatic Cholestasis Type 2. *Ann Hepatol* 2017; **16**: 465-468 [PMID: 28425419 DOI: 10.5604/16652681.1235494]
- 15 **Keitel V**, Burdelski M, Warskulat U, Kuhlkamp T, Keppler D, Häussinger D, Kubitz R. Expression and localization of hepatobiliary transport proteins in progressive familial intrahepatic cholestasis. *Hepatology* 2005; **41**: 1160-1172 [PMID: 15841457 DOI: 10.1002/hep.20682]
- 16 **Anzivino C**, Odoardi MR, Meschiari E, Baldelli E, Facchinetti F, Neri I, Ruggiero G, Zampino R, Bertolotti M, Loria P, Carulli L. ABCB4 and ABCB11 mutations in intrahepatic cholestasis of pregnancy in an Italian population. *Dig Liver Dis* 2013; **45**: 226-232 [PMID: 23022423 DOI: 10.1016/j.dld.2012.08.011]
- 17 **Lim TY**, Coltart I, Foksett P, Thompson R, Strautnieks S, Penna L, Williamson C, Miquel R, Heneghan MA. Donor transmitted mutation of the ABCB11 gene and ensuing intrahepatic cholestasis of pregnancy in a liver transplant recipient. *Liver Transpl* 2017; **23**: 1229-1232 [PMID: 28524363 DOI: 10.1002/lt.24776]
- 18 **Kubitz R**, Dröge C, Kluge S, Stindt J, Häussinger D. Genetic variations of bile salt transporters. *Drug Discov Today Technol* 2014; **12**: e55-e67 [PMID: 25027376 DOI: 10.1016/j.ddtec.2014.03.006]
- 19 **Chen R**, Wang J, Tang S, Zhang Y, Lv X, Wu S, Yang Z, Xia Y, Chen D, Zhan S. Role of polymorphic bile salt export pump (BSEP, ABCB11) transporters in anti-tuberculosis drug-induced liver injury in a Chinese cohort. *Sci Rep* 2016; **6**: 27750 [PMID: 27293027 DOI: 10.1038/srep27750]
- 20 **Caplan MS**, Cohn RA, Langman CB, Conway JA, Shkolnik A, Brouillette RT. Favorable outcome of neonatal aortic thrombosis and renovascular hypertension. *J Pediatr* 1989; **115**: 291-295 [PMID: 2666628 DOI: 10.1016/s0022-3476(89)80088-5]
- 21 **Li T**, Apte U. Bile Acid Metabolism and Signaling in Cholestasis, Inflammation, and Cancer. *Adv Pharmacol* 2015; **74**: 263-302 [PMID: 26233910 DOI: 10.1016/bs.apha.2015.04.003]
- 22 **Ran X**, Yin B, Ma B. Four Major Factors Contributing to Intrahepatic Stones. *Gastroenterol Res Pract* 2017; **2017**: 7213043 [PMID: 28163717 DOI: 10.1155/2017/7213043]
- 23 **Zollner G**, Trauner M. Mechanisms of cholestasis. *Clin Liver Dis* 2008; **12**: 1-26, vii [PMID: 18242495 DOI: 10.1016/j.cld.2007.11.010]
- 24 **Aono S**, Yamada Y, Keino H, Hanada N, Nakagawa T, Sasaoka Y, Yazawa T, Sato H, Koiwai O. Identification of defect in the genes for bilirubin UDP-glucuronosyl-transferase in a patient with Crigler-Najjar syndrome type II. *Biochem Biophys Res Commun* 1993; **197**: 1239-1244 [PMID: 8280139 DOI: 10.1006/bbrc.1993.2610]
- 25 **Maruo Y**, Nakahara S, Yanagi T, Nomura A, Mimura Y, Matsui K, Sato H, Takeuchi Y. Genotype of UGT1A1 and phenotype correlation between Crigler-Najjar syndrome type II and Gilbert syndrome. *J Gastroenterol Hepatol* 2016; **31**: 403-408 [PMID: 26250421 DOI: 10.1111/jgh.13071]
- 26 **Modha K**. Clinical Approach to Patients With Obstructive Jaundice. *Tech Vasc Interv Radiol* 2015; **18**: 197-200 [PMID: 26615159 DOI: 10.1053/j.tvir.2015.07.002]
- 27 **Liu FB**, Yu XJ, Wang GB, Zhao YJ, Xie K, Huang F, Cheng JM, Wu XR, Liang CJ, Geng XP. Preliminary study of a new pathological evolution-based clinical hepatolithiasis classification. *World J Gastroenterol* 2015; **21**: 2169-2177 [PMID: 25717253 DOI: 10.3748/wjg.v21.i7.2169]
- 28 **Wijarnpreecha K**, Thongprayoon C, Sanguankeo A, Upala S, Ungprasert P, Cheungpasitporn W. Hepatitis C infection and intrahepatic cholestasis of pregnancy: A systematic review and meta-analysis. *Clin Res Hepatol Gastroenterol* 2017; **41**: 39-45 [PMID: 27542514 DOI: 10.1016/j.clinre.2016.07.004]
- 29 **Aslan AN**, Sari C, Baştuğ S, Sari SÖ, Akçay M, Durmaz T, Bozkurt E. Severe jaundice due to intrahepatic cholestasis after initiating anticoagulation with rivaroxaban. *Blood Coagul Fibrinolysis* 2016; **27**: 226-227 [PMID: 26569514 DOI: 10.1097/MBC.0000000000000442]
- 30 **Corrêa TD**, Cavalcanti AB, Assunção MS. Balanced crystalloids for septic shock resuscitation. *Rev Bras Ter Intensiva* 2016; **28**: 463-471 [PMID: 28099643 DOI: 10.5935/0103-507X.20160079]
- 31 **Arai T**, Nagino M, Nimura Y. [Hepatic failure following resection of cholestatic liver]. *Nihon Geka Gakkai Zasshi* 2004; **105**: 664-668 [PMID: 15521383]
- 32 **Peralta C**, Jiménez-Castro MB, Gracia-Sancho J. Hepatic ischemia and reperfusion injury: effects on the liver sinusoidal milieu. *J Hepatol* 2013; **59**: 1094-1106 [PMID: 23811302 DOI: 10.1016/j.jhep.2013.06.017]
- 33 **Bernhardt GA**, Zollner G, Cerwenka H, Kornprat P, Fickert P, Bacher H, Werkgartner G, Müller G, Zatloukal K, Mischinger HJ, Trauner M. Hepatobiliary transporter expression and post-operative jaundice in patients undergoing partial hepatectomy. *Liver Int* 2012; **32**: 119-127 [PMID: 22098322 DOI: 10.1111/j.1478-3231.2011.02625.x]





Published by **Baishideng Publishing Group Inc**  
7041 Koll Center Parkway, Suite 160, Pleasanton, CA 94566, USA

**Telephone:** +1-925-3991568

**E-mail:** [bpgoffice@wjgnet.com](mailto:bpgoffice@wjgnet.com)

**Help Desk:** <https://www.f6publishing.com/helpdesk>

<https://www.wjgnet.com>

