

World Journal of *Clinical Cases*

World J Clin Cases 2023 March 26; 11(9): 1888-2122



REVIEW

- 1888 Endoscopic transluminal drainage and necrosectomy for infected necrotizing pancreatitis: Progress and challenges

Zeng Y, Yang J, Zhang JW

MINIREVIEWS

- 1903 Functional role of frontal electroencephalogram alpha asymmetry in the resting state in patients with depression: A review

Xie YH, Zhang YM, Fan FF, Song XY, Liu L

- 1918 COVID-19 related liver injuries in pregnancy

Sekulovski M, Bogdanova-Petrova S, Peshevska-Sekulovska M, Velikova T, Georgiev T

- 1930 Examined lymph node count for gastric cancer patients after curative surgery

Zeng Y, Chen LC, Ye ZS, Deng JY

- 1939 Laparoscopic common bile duct exploration to treat choledocholithiasis in situs inversus patients: A technical review

Chiu BY, Chuang SH, Chuang SC, Kuo KK

- 1951 Airway ultrasound for patients anticipated to have a difficult airway: Perspective for personalized medicine

Nakazawa H, Uzawa K, Tokumine J, Lefor AK, Motoyasu A, Yorozu T

ORIGINAL ARTICLE

Observational Study

- 1963 Clinicopathological features and expression of regulatory mechanism of the Wnt signaling pathway in colorectal sessile serrated adenomas/polyps with different syndrome types

Qiao D, Liu XY, Zheng L, Zhang YL, Que RY, Ge BJ, Cao HY, Dai YC

Randomized Controlled Trial

- 1974 Effects of individual shock wave therapy vs celecoxib on hip pain caused by femoral head necrosis

Zhu JY, Yan J, Xiao J, Jia HG, Liang HJ, Xing GY

CASE REPORT

- 1985 Very low calorie ketogenic diet and common rheumatic disorders: A case report

Rondanelli M, Patelli Z, Gasparri C, Mansueto F, Ferraris C, Nichetti M, Alalwan TA, Sajoux I, Maugeri R, Perna S

- 1992 Delayed versus immediate intervention of ruptured brain arteriovenous malformations: A case report

Bintang AK, Bahar A, Akbar M, Soraya GV, Gunawan A, Hammado N, Rachman ME, Ulhaq ZS

- 2002** Children with infectious pneumonia caused by *Ralstonia insidiosa*: A case report
Lin SZ, Qian MJ, Wang YW, Chen QD, Wang WQ, Li JY, Yang RT, Wang XY, Mu CY, Jiang K
- 2009** Transient ischemic attack induced by pulmonary arteriovenous fistula in a child: A case report
Zheng J, Wu QY, Zeng X, Zhang DF
- 2015** Motor cortex transcranial magnetic stimulation to reduce intractable postherpetic neuralgia with poor response to other therapies: Report of two cases
Wang H, Hu YZ, Che XW, Yu L
- 2021** Small bowel adenocarcinoma in neoterminal ileum in setting of stricturing Crohn's disease: A case report and review of literature
Karthikeyan S, Shen J, Keyashian K, Gubatan J
- 2029** Novel combined endoscopic and laparoscopic surgery for advanced T2 gastric cancer: Two case reports
Dai JH, Qian F, Chen L, Xu SL, Feng XF, Wu HB, Chen Y, Peng ZH, Yu PW, Peng GY
- 2036** Acromicric dysplasia caused by a mutation of fibrillin 1 in a family: A case report
Shen R, Feng JH, Yang SP
- 2043** Ultrasound-guided intra-articular corticosteroid injection in a patient with manubriosternal joint involvement of ankylosing spondylitis: A case report
Choi MH, Yoon IY, Kim WJ
- 2051** Granulomatous prostatitis after bacille Calmette-Guérin instillation resembles prostate carcinoma: A case report and review of the literature
Yao Y, Ji JJ, Wang HY, Sun LJ, Zhang GM
- 2060** Unusual capitate fracture with dorsal shearing pattern and concomitant carpometacarpal dislocation with a 6-year follow-up: A case report
Lai CC, Fang HW, Chang CH, Pao JL, Chang CC, Chen YJ
- 2067** Live births from *in vitro* fertilization-embryo transfer following the administration of gonadotropin-releasing hormone agonist without gonadotropins: Two case reports
Li M, Su P, Zhou LM
- 2074** Spontaneous conus infarction with "snake-eye appearance" on magnetic resonance imaging: A case report and literature review
Zhang QY, Xu LY, Wang ML, Cao H, Ji XF
- 2084** Transseptal approach for catheter ablation of left-sided accessory pathways in children with Marfan syndrome: A case report
Dong ZY, Shao W, Yuan Y, Lin L, Yu X, Cui L, Zhen Z, Gao L
- 2091** Occipital artery bypass importance in unsuitable superficial temporal artery: Two case reports
Hong JH, Jung SC, Ryu HS, Kim TS, Joo SP

- 2098** Anesthetic management of a patient with preoperative R-on-T phenomenon undergoing laparoscopic-assisted sigmoid colon resection: A case report
Li XX, Yao YF, Tan HY
- 2104** Pembrolizumab combined with axitinib in the treatment of skin metastasis of renal clear cell carcinoma to nasal ala: A case report
Dong S, Xu YC, Zhang YC, Xia JX, Mou Y
- 2110** Successful treatment of a rare subcutaneous emphysema after a blow-out fracture surgery using needle aspiration: A case report
Nam HJ, Wee SY

LETTER TO THE EDITOR

- 2116** Are biopsies during endoscopic ultrasonography necessary for a suspected esophageal leiomyoma? Is laparoscopy always feasible?
Beji H, Chtourou MF, Zribi S, Kallel Y, Bouassida M, Touinsi H
- 2119** Vaginal microbes confounders and implications on women's health
Nori W, H-Hameed B

ABOUT COVER

Editorial Board Member of *World Journal of Clinical Cases*, Marilia Carabotti, MD, PhD, Academic Research, Medical-Surgical Department of Clinical Sciences and Translational Medicine, University Sapienza Rome, Rome 00189, Italy. mariliacarabotti@gmail.com

AIMS AND SCOPE

The primary aim of *World Journal of Clinical Cases* (WJCC, *World J Clin Cases*) is to provide scholars and readers from various fields of clinical medicine with a platform to publish high-quality clinical research articles and communicate their research findings online.

WJCC mainly publishes articles reporting research results and findings obtained in the field of clinical medicine and covering a wide range of topics, including case control studies, retrospective cohort studies, retrospective studies, clinical trials studies, observational studies, prospective studies, randomized controlled trials, randomized clinical trials, systematic reviews, meta-analysis, and case reports.

INDEXING/ABSTRACTING

The WJCC is now abstracted and indexed in Science Citation Index Expanded (SCIE, also known as SciSearch®), Journal Citation Reports/Science Edition, Current Contents®/Clinical Medicine, PubMed, PubMed Central, Scopus, Reference Citation Analysis, China National Knowledge Infrastructure, China Science and Technology Journal Database, and Superstar Journals Database. The 2022 Edition of Journal Citation Reports® cites the 2021 impact factor (IF) for WJCC as 1.534; IF without journal self cites: 1.491; 5-year IF: 1.599; Journal Citation Indicator: 0.28; Ranking: 135 among 172 journals in medicine, general and internal; and Quartile category: Q4. The WJCC's CiteScore for 2021 is 1.2 and Scopus CiteScore rank 2021: General Medicine is 443/826.

RESPONSIBLE EDITORS FOR THIS ISSUE

Production Editor: *Ying-Yi Yuan*; Production Department Director: *Xiang Li*; Editorial Office Director: *Jin-Lei Wang*.

NAME OF JOURNAL

World Journal of Clinical Cases

ISSN

ISSN 2307-8960 (online)

LAUNCH DATE

April 16, 2013

FREQUENCY

Thrice Monthly

EDITORS-IN-CHIEF

Bao-Gan Peng, Jerzy Tadeusz Chudek, George Kontogeorgos, Maurizio Serati, Ja Hyeon Ku

EDITORIAL BOARD MEMBERS

<https://www.wjnet.com/2307-8960/editorialboard.htm>

PUBLICATION DATE

March 26, 2023

COPYRIGHT

© 2023 Baishideng Publishing Group Inc

INSTRUCTIONS TO AUTHORS

<https://www.wjnet.com/bpg/gerinfo/204>

GUIDELINES FOR ETHICS DOCUMENTS

<https://www.wjnet.com/bpg/GerInfo/287>

GUIDELINES FOR NON-NATIVE SPEAKERS OF ENGLISH

<https://www.wjnet.com/bpg/gerinfo/240>

PUBLICATION ETHICS

<https://www.wjnet.com/bpg/GerInfo/288>

PUBLICATION MISCONDUCT

<https://www.wjnet.com/bpg/gerinfo/208>

ARTICLE PROCESSING CHARGE

<https://www.wjnet.com/bpg/gerinfo/242>

STEPS FOR SUBMITTING MANUSCRIPTS

<https://www.wjnet.com/bpg/GerInfo/239>

ONLINE SUBMISSION

<https://www.f6publishing.com>



COVID-19 related liver injuries in pregnancy

Metodija Sekulovski, Simona Bogdanova-Petrova, Monika Peshevska-Sekulovska, Tsvetelina Velikova, Tsvetoslav Georgiev

Specialty type: Gastroenterology and hepatology

Provenance and peer review: Invited article; Externally peer reviewed.

Peer-review model: Single blind

Peer-review report's scientific quality classification

Grade A (Excellent): 0
Grade B (Very good): 0
Grade C (Good): C, C
Grade D (Fair): 0
Grade E (Poor): 0

P-Reviewer: Papalexis PG, Greece; Rotondo JC, Italy

Received: November 22, 2022

Peer-review started: November 22, 2022

First decision: January 3, 2023

Revised: January 17, 2023

Accepted: February 21, 2023

Article in press: February 21, 2023

Published online: March 26, 2023



Metodija Sekulovski, Department of Anesthesiology and Intensive Care, University Hospital Lozenetz, Sofia 1407, Bulgaria

Metodija Sekulovski, Monika Peshevska-Sekulovska, Tsvetelina Velikova, Medical Faculty, Sofia University St. Kliment Ohridski, Sofia 1407, Bulgaria

Simona Bogdanova-Petrova, Tsvetoslav Georgiev, First Department of Internal Medicine, Medical University-Varna, Varna 9010, Bulgaria

Simona Bogdanova-Petrova, Tsvetoslav Georgiev, Clinic of Rheumatology, University Hospital "St. Marina", Varna 9010, Bulgaria

Monika Peshevska-Sekulovska, Department of Gastroenterology, University Hospital Lozenetz, Sofia 1407, Bulgaria

Tsvetelina Velikova, Department of Clinical Immunology, University Hospital Lozenetz, Sofia 1407, Bulgaria

Corresponding author: Tsvetoslav Georgiev, MD, PhD, Associate Professor, First Department of Internal Medicine, Medical University-Varna, 1 Hristo Smirnenski str., Varna 9010, Bulgaria. tsetso@medfaculty.org

Abstract

While severe acute respiratory syndrome coronavirus 2 (SARS-CoV-2) quickly spread across the globe, our understanding of its pathogenic mechanisms evolved. Importantly, coronavirus disease 2019 (COVID-19) is now considered a syndromic multisystem inflammatory disease involving not only the respiratory system but also the cardiovascular, excretory, nervous, musculoskeletal, and gastrointestinal systems. Moreover, a membrane-bound form of angiotensin-converting enzyme 2, the entry receptor for SARS-CoV-2, is expressed on the surface of cholangiocytes and hepatocytes, suggesting the potential of COVID-19 to involve the liver. With the widespread distribution of SARS-CoV-2 throughout the population, infection during pregnancy is no longer a rare occurrence; however, little is known about the course of hepatic injuries and related outcomes in pregnant SARS-CoV-2-positive women. Thus, the understudied topic of COVID-related liver disease during pregnancy poses a great challenge for the consulting gynecologist and hepatologist. In this review, we aim to describe and summarize potential liver injuries in pregnant women with COVID-19.

Key Words: COVID-19; Liver injury; Pregnancy; SARS-CoV-2; Angiotensin-converting

enzyme 2 receptors

©The Author(s) 2023. Published by Baishideng Publishing Group Inc. All rights reserved.

Core Tip: Angiotensin-converting enzyme 2 receptors are expressed in hepatocytes and cholangiocytes, suggesting the potential for liver involvement by coronavirus disease 2019 (COVID-19). Liver dysfunction is mainly observed in patients with severe or critical disease. However, little is known about the course of liver involvement and its sequelae in pregnant women positive for severe acute respiratory syndrome coronavirus 2. Several cases of hepatic injury in pregnant women with severe COVID-19 have been reported, making the liver the second most commonly affected organ following the lung.

Citation: Sekulovski M, Bogdanova-Petrova S, Peshevska-Sekulovska M, Velikova T, Georgiev T. COVID-19 related liver injuries in pregnancy. *World J Clin Cases* 2023; 11(9): 1918-1929

URL: <https://www.wjgnet.com/2307-8960/full/v11/i9/1918.htm>

DOI: <https://dx.doi.org/10.12998/wjcc.v11.i9.1918>

INTRODUCTION

The end of 2019 was marked by the emergence of a novel disease caused by the severe acute respiratory syndrome coronavirus 2 (SARS-CoV-2). Unprecedentedly, modern societies have faced the threat of coronavirus disease (COVID-19), resulting in over 649 million confirmed cases and 6.5 million deaths worldwide as of 18 Dec 2022[1]. While COVID-19 quickly spread across the globe, our understanding of its pathogenic mechanisms began to evolve. Considered a flu-like illness initially, the pathogenesis of this disease underwent a radical change[2]. As of now, COVID-19 is perceived as a syndromic multi-system inflammatory disease involving primarily the respiratory and cardiovascular systems, but also the endocrine, nervous, gastrointestinal, and hepatobiliary systems.

SARS-CoV-2 utilizes the angiotensin-2 converting enzyme (ACE2) receptor protein to attack the host system[3]. The cell entry receptor, ACE2, is widely expressed in the human body, including in the lungs (type II alveolar cells), the gastrointestinal tract (esophageal epithelial cells and absorptive enterocytes of the ileum and colon)[4], the hepatobiliary system (hepatocytes and cholangiocytes), the cardiovascular system (myocardial cells), the renal system (proximal tubule cells and bladder urothelial cells), and the pancreas[3].

SARS-CoV-2 can directly bind to ACE2 on the surface of cholangiocytes and hepatocytes to exert a cytopathic effect[5]. In fact, several studies have reported injury to the hepatobiliary system[6], making it one of the most commonly affected systems aside from the respiratory system[7].

With the widespread distribution of SARS-CoV-2 throughout the population, infection during pregnancy is no longer a rare event. However, liver disease during pregnancy is relatively poorly studied, and poses a challenge for consulting gynecologists and hepatologists[8].

There are many physiological, mechanical, and immunologic changes that occur during pregnancy that may influence susceptibility to and severity of COVID-19. Ever-accumulating evidence suggests that SARS-CoV-2 infection during pregnancy, especially in women with severe COVID-19, is linked to various adverse outcomes, including preeclampsia (PE), preterm delivery, and stillbirth[9]. Pregnant women are also prone to involvement of several organs and organ systems with severe COVID-19 infection, including the gastrointestinal tract and the liver. Therefore, we aimed to describe and summarize potential liver injuries in pregnant women with COVID-19.

SEARCH STRATEGY

Our search methodology follows predefined rules for writing a narrative biomedical review[10]. A comprehensive search was performed on 15 August 2022 in the LitCovid (PubMed) and Scopus databases. These databases were queried using the keywords “COVID-19” or “coronavirus” or “SARS-CoV” AND “liver” OR “hepat*” OR “cholang*” and articles were extracted from inception to 15 August 2022. Bibliographies of retrieved publications were also hand-searched for important information. Relevant data were also included from preprints, papers, and guidelines of relevant professional associations to provide contextual background. Only case reports, original articles, reviews, and considerations of official societies written in English were included. Relevant papers were selected according to the professional expertise, experience, and opinions of the authors in preparation of this narrative review[10].

LIVER INJURIES IN COVID-19 PATIENTS

ACE2 receptors are expressed in hepatocytes and cholangiocytes, suggesting the potential for liver involvement by COVID-19. Liver dysfunction is mainly observed in patients with severe or critical disease[11] or in those with altered liver biochemistry tests [*e.g.*, elevated total bilirubin, gamma-glutamyl transferase (GGT), aspartate aminotransferase/alanine aminotransferase (AST/ALT)][12]. Aberrations in other commonly-performed laboratory tests such as alkaline phosphatase and ferritin may also suggest liver injury[13]. Pathoanatomically, microvesicular steatosis has been observed, with mild lobular and portal inflammation[14]. Liver injury in COVID-19 is likely related to the immune response, including cytokine storm development[15]. Hepatic damage during SARS-CoV-2 infection is very diverse, ranging from mild and harmless elevation of transaminases to acute liver failure. To encompass the whole spectrum of liver disease, the clinical entity “COVID-19-associated liver injury” was recently introduced[16,17].

ACE2 expression in cholangiocyte clusters has been reported to be significantly higher than that in the hepatocytes (59.7% *vs* 2.6%)[5]. Cholangiocytes are involved in many aspects of liver physiology, including regeneration mechanisms, adaptive immune response; disruption of cholangiocyte function can cause hepatobiliary injury. This injury is detected by monitoring for any increase in cholestatic markers (*e.g.*, including gamma-glutamyl transferase), and is observed in about 54% of COVID-19 cases [12,18]. In addition, SARS-CoV-2 can lead to disruption of the barrier and bile acid (BA) transport functions of cholangiocytes *via* dysregulation of genes involved in BA formation and transport[19].

Four potential causes of liver damage have been proposed. The first is the direct invasion of hepatocytes by SARS-CoV-2, leading to abnormal levels of liver enzymes. Although this hypothesis is the most accepted, hepatocytes have not been shown to express a high level of ACE2, making the liver itself an unlikely target for infection by SARS-CoV-2[20]. However, other studies have shown a high level of ACE2 expression in cholangiocytes, suggesting an indirect cause of elevated liver enzymes *via* cholangiocyte dysfunction[5]. Furthermore, elevated alkaline phosphatase levels have not been consistently demonstrated in patients with COVID-19, supporting the hypothesis of indirect liver injury. As of now, pathoanatomic data provide no evidence of direct SARS-CoV-2 infection of hepatocytes, suggesting this is an unlikely cause of liver damage[21]. The second possible mechanism of liver damage in COVID-19 is the hepatotoxicity of drugs used to treat the disease. Abnormal liver tests may occur in women treated with multiple medications including systemic glucocorticoids, antiviral, anti-inflammatory and anticoagulant drugs during pregnancy[22]. Nonsteroidal anti-inflammatory drugs, antipyretics, and analgesics are often used in COVID-19 patients for symptomatic control in the acute phase of the disease. Antibiotics are also frequently used. Additionally, the systemic inflammatory response and multiorgan dysfunction seen with severe COVID-19 may contribute to the development of a cytokine storm, which is associated with liver damage. Finally, the occurrence of severe acute respiratory syndrome can lead to severe hypoxia, which can also contribute to liver dysfunction[18]. An essential role is also played by the body's overwhelming and often life-threatening response to infection [23].

Cases of severe hepatitis with pronounced hepatocytolysis leading to acute liver failure have also been described[24]. The prognosis in these cases is poor; the more severe the disease, the greater the probability of liver involvement and impairment.

There are few reports and little research on COVID-19 infection in children who already have chronic liver disease. It is unclear whether infections in the pediatric population are linked to decompensation of cirrhosis and the onset of acute or chronic liver failure, which alone is a risk factor for a severe COVID-19 course. Furthermore, comorbidities in adults such as diabetes, hypertension, and obesity frequently result in non-alcoholic hepatosteatosis (fatty liver disease), but this has not been reported in children. Recently, liver involvement has been added to the many factors scrutinized in determining the severity of COVID-19 or multisystem inflammatory syndrome in children. Indeed, the use of liver enzymes as a predictive indicator for the prognosis of these diseases has been proposed[25].

PREGNANCY AS A RISK FACTOR FOR SEVERE COVID-19

The prevalence of SARS-CoV-2 infection among pregnant women presenting for management of labor and delivery is estimated at 3%-20%, depending on patient age and reproductive and socioeconomic settings[26,27]. Even after controlling for age, race, and sex, the risk of asymptomatic infection in obstetric patients was 15 times greater than in surgical patients[28].

In one study, pregnant women with COVID-19 were 3 times more likely than nonpregnant women with COVID-19 to be admitted to an intensive care unit (10.5 per 1000 cases *vs* 3.9 per 1000 cases), 2.9 times more likely to require invasive ventilation (2.9 per 1000 cases *vs* 1.1 per 1000 cases), 2.4 times more likely to require extracorporeal membrane oxygenation (0.7 per 1000 cases *vs* 0.3 per 1000 cases), and 1.7 times more likely to die (1.5 per 1000 cases *vs* 1.2 per 1000 cases)[29].

Underlying medical conditions, such as obesity, chronic lung disease (*e.g.*, asthma), and chronic hypertension were related to more severe COVID-19 in pregnancy. Contributing factors that are

exacerbated by comorbidities include inflammation, altered immune system function, and decreased ability to combat infection[30,31]. Susceptibility to respiratory viral infections has been demonstrated in pregnant women[32], attributed in part to the phenomenon of immune modulation occurring during pregnancy[33]. The most important factors related to severe COVID-19 in pregnant women and pregnancy outcomes are presented in **Figure 1**.

In general, the clinical management of COVID-19 in pregnancy is comparable to that in nonpregnant women, and effective medications should not be delayed based on pregnancy status[34]. However, in addition to the direct effective of COVID-19 on pregnancy outcomes, the pandemic and its impact on healthcare systems have had negative pregnancy-related consequences, including higher rates of stillbirth and maternal death[9,35]. Furthermore, SARS-CoV-2 infection during the first trimester of pregnancy is related to a higher risk of miscarriage[36].

LIVER INJURIES IN PREGNANT COVID-19 PATIENTS

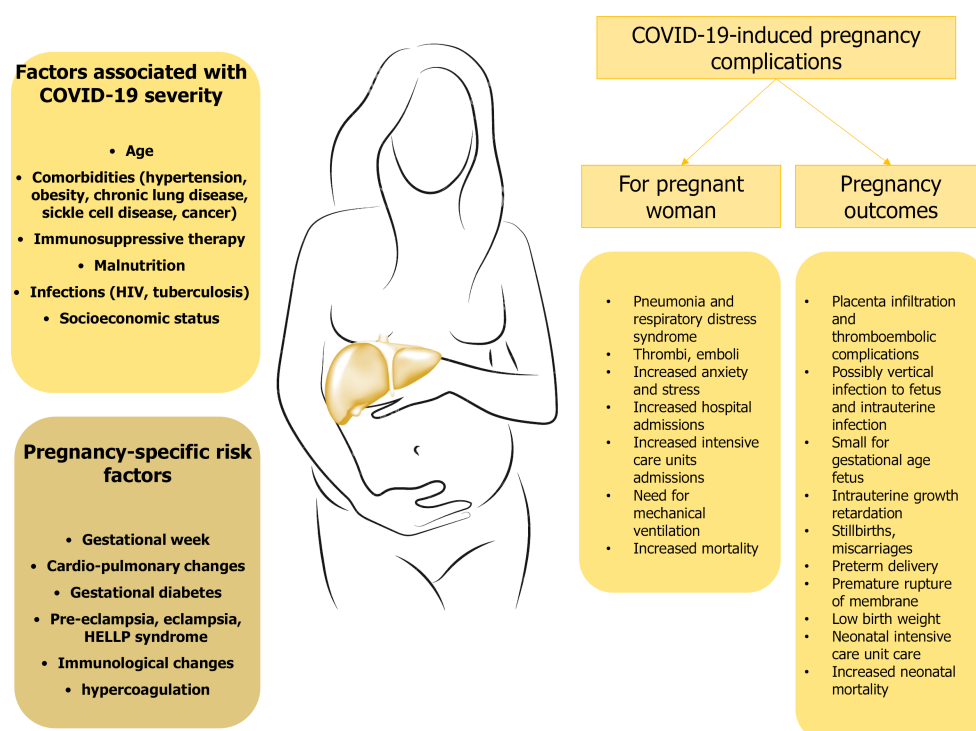
Immunological reactions and cardiovascular changes brought on by pregnancy may accelerate the progression of COVID-19. However, little is known about the course of liver disease and its associated outcomes in pregnant SARS-CoV-2-positive women. Cases of severe COVID-19 disease and associated hepatic injury have been reported[6,37-39], making the liver the second most commonly affected organ following the lung. Transient elevations in serum aminotransferases are common. Several factors, including severe hypoxemia due to acute respiratory failure, drug interactions, septic shock, and multiorgan dysfunction have been linked to acute liver damage in severe COVID-19[6].

Much of the research on COVID-19 and its effects on pregnant patients with hepatic injury is currently under investigation. One study by Deng *et al*[40] compared pregnant patients without liver injury following SARS-CoV-2 infection to those with liver injury. This study demonstrated higher levels of procalcitonin, interleukin-6, liver enzymes, and lactate dehydrogenase in pregnant patients with hepatic involvement by the disease. There were no statistical differences between the two groups with respect to the severity of COVID-19, time from disease onset to hospitalization, length of hospital stay, radiological findings, or obstetric management. Four patients with liver injury in the third trimester voluntarily chose cesarean section, two had a vaginal delivery, and the rest did not deliver. The 6 live births resulted in no fetal death, neonatal death, or asphyxia. The authors found a 29.7% prevalence of liver injury in pregnant COVID-19 patients, with worse inflammation than those who did not have liver injury[40]. Another interesting case was reported by Anness *et al*[41] in which a pregnant woman at 28 wk gestation had COVID-19 complicated by hepatic dysfunction. However, in this case, the authors did find a correlation between the severity of COVID-19 disease and liver injury. After excluding PE and intrahepatic cholestasis (IHC) during pregnancy, because of the anamnesis of gestational diabetes and past history of IHC in the first pregnancy, they concluded that the abnormal liver tests were attributable to severe COVID-19. The normalization of liver function tests in the patient accompanied her clinical improvement in terms of viral symptoms, confirming the viral etiology of the liver disease. Another enduring hypothesis with respect to COVID-19 and hepatic injury with abnormal liver function tests is presented in a retrospective cohort study by Can *et al*[42]. This study considered that the aminotransferase elevation in COVID-19 pregnant women might be drug-induced, as the use of lopinavir/ritonavir and hydroxychloroquine were significantly higher at the beginning of pandemic and duration of treatment was longer in pregnant women with abnormal aminotransferases. Hence, liver function in SARS-CoV-2 infected pregnant women who received antiviral treatment should be closely monitored.

A similar case of drug-induced liver cytolysis in a pregnant woman with COVID-19 was reported by Lamazou *et al*[43]. This study presented a case of severe SARS-CoV-2 infection in the first trimester in a patient treated with hydroxychloroquine. Due to history of multiple implantation failure, an immunological treatment, aspirin, enoxaparin and filgrastim were used daily for 10 mo before an embryo transfer. The patient had no pregestational comorbidities such as hypertension, diabetes, or cardiovascular disease. In the 7th gestational wk (GW), the patient was noted to have abnormal liver function tests (AST, ALT and GGT 3, 5, and 2 times the upper limit of normal, respectively). Despite ruling out viral etiology (*e.g.*, viral hepatitis, cytomegalovirus, or Epstein-Barr virus), the patient's liver function deteriorated and improved only after stopping hydroxychloroquine. This case raises concerns regarding the possible association between COVID-19, prolonged usage of hydroxychloroquine, and drug-induced hepatitis[43].

Managing liver injury during pregnancy is a significant challenge and requires a multispecialty approach. Established classifications help obstetric specialists diagnose and treat pregnancy-related liver diseases efficiently. Among the most common of these are hyperemesis gravidarum, IHC during pregnancy, PE, HELLP (hemolysis, elevated liver enzymes, low platelets) syndrome and last but not least, acute fatty liver of pregnancy (AFLP)[44].

However, as mentioned above, although COVID-19 infection is gaining momentum as a possible factor contributing to hepatic dysfunction, little is known about its influence on women with pregnancy-related liver diseases.



DOI: 10.12998/wjcc.v11.i9.1918 Copyright ©The Author(s) 2023.

Figure 1 Severe coronavirus disease 2019 in pregnancy and associated complications for mother and fetus. COVID-19: Coronavirus disease 2019; HELLP: Hemolysis, elevated liver enzymes, low platelets; HIV: Human immunodeficiency virus.

PE

According to current data, it is clear that pregnant women with COVID-19 have an increased risk of hypertensive disorders, and the characteristics of these disorders are similar to those of non-pregnant hypertensive patients[45]. There is a growing body of evidence that raises concerns regarding the significant percentage of PE in pregnant COVID-19 patients. One of the most common complications in pregnant COVID-19 patients is PE[46]. Like the lungs and gastrointestinal tract, the placenta also has high expression of ACE2 receptors; therefore, SARS-CoV-2 infection could lead to placental dysregulation. This is in line with the fact that both PE and COVID-19 can affect the microcirculation, resulting in thrombotic incidents. High rates of PE have been reported in cases of severe and critical COVID-19 in pregnant women[47]. Among the most promising diagnostic markers for PE are soluble endoglin, pregnancy-associated plasma protein-A, soluble fms-like tyrosine kinase 1 (sFlt-1), and placental growth factor (PlGF). Because of placental hypoxia, a common finding in PE, there is often sFlt-1 overproduction with inhibition of PlGF. This can be observed in the circulation 5 wk or more before the onset of PE symptoms. Furthermore, the sFlt-1/PlGF ratio might also be affected by various infectious agents, including SARS-CoV-2. Unregulated levels of these mediators are related to placental insufficiency[48].

Another study by Mendoza *et al*[49] found that 11.9% of pregnant COVID-19 patients develop signs of PE and that these signs were only observed in severe COVID-19 pneumonia cases. However, the authors suspected that the signs and symptoms consistent with PE, which were present in 4 of 5 PE cases, may have resulted from the use of complex pharmacotherapy or the renal and cardiovascular dysfunction associated with SARS-CoV-2 infection. Abnormal angiogenic status (sFlt-1/PlGF ratio), increased lactate dehydrogenase (LDH), and poor placental perfusion typical of PE were confirmed in only 1 of the patients, indicating that this case was probably an actual case of PE, while the others were classified as PE-like syndrome. Cesarean section was performed on only this single patient with definitive PE. In contrast, the PE-like syndrome was not considered an absolute indication for earlier delivery due to the potential for spontaneous resolution of the syndrome after recovery from severe pneumonia. In summary, pregnant women with COVID-19 may develop a PE-like syndrome that, despite the similarities, can be appropriately differentiated from true PE by angiogenic markers to avoid unnecessary interventions such as preterm induction of labor.

AFLP

AFLP is a rare, potentially fatal complication that occurs in the peripartum period. The Swansea criteria are widely used for the diagnosis of AFLP and include results from both clinical and instrumental findings as well as pathological examination[50]. Choudhary *et al*[51] reported an interesting case of a PE patient with COVID-19 whose condition deteriorated after diagnosis of AFLP by Swansea criteria.

The patient also exhibited renal failure and severe COVID-19 pneumonia. The authors pointed out that the symptoms of COVID-19 might mimic those of HELLP syndrome, viral hepatitis, or IHC. Therefore, the best diagnostic approach includes first ruling out these other causes. Compared to HELLP syndrome, AFLP is associated with higher degrees of liver enzyme derangement and coagulation abnormalities. In addition, it is known that COVID-19 is frequently associated with hepatic dysfunction [52]. These findings are supported by a case report by Morton *et al* [53] in which a pregnant woman with influenza hepatitis developed AFLP. In this study, the authors elucidated a possible mechanism linking the 2 diseases: impaired hepatic fatty acid oxidation mediated by Kupffer cell cytokine release, hepatic oxidative stress, and hepatocyte injury as a result of viral infection. Following this mechanism, it is conceivable that COVID-19 could trigger a similar response and contribute to the development of PE. So far, available data have shown that pregnant women with severe COVID-19 disease could develop PE-like syndrome [49]. Therefore, it is of great significance for healthcare providers to be aware of the existence of this syndrome and carefully monitor pregnant patients with suspected AFLP.

IHC in pregnancy

Due to its effect on the liver, COVID-19 is associated with higher aminotransferase levels, especially in pregnant patients with IHC [54]. Increased levels of serum BA are the most sensitive diagnostic marker of IHC, likely due in part to its impaired resorption as a result of increased estrogen. However, in the case of SARS-CoV-2 infection, there is doubt as to whether hepatic dysfunction is due to IHC, SARS-CoV-2, or both [55]. Liver injury may result from direct infection of hepatocytes or from a byproduct of hypoxic cellular injury. Rabiei *et al* [56] reported a case of a 38-year-old COVID-19 patient pregnant with triplets. The patient also exhibited IHC of pregnancy and was treated with ursodeoxycholic acid. Due to worsening of her condition, she had preterm delivery in the 29th GW with a good outcome for her and 1 of 3 infants. However, 2 of the infants died due to severe pulmonary insufficiency and sepsis [56]. It is reasonable to speculate that in pregnant women with concurrent IHC and COVID-19, the obstetric cholestasis and viral infection act synergistically to worsen hepatic function. Based on available data, it appears that the simultaneous presence of IHC and COVID-19 does not affect maternal and fetal outcomes more than in women with cholestasis alone. However, there is still a lack of evidence regarding whether increasing degrees of hepatic dysfunction are related to an increased risk of adverse pregnancy outcomes such as spontaneous and iatrogenic preterm delivery, meconium-stained amniotic fluid, neonatal respiratory distress syndrome, and stillbirth. Furthermore, it is unclear if established COVID-19 prognostic markers can be used in this cohort of patients.

HELLP, HELLP-like syndrome, and hepatic rupture

Because of the serious nature of the pandemic, the research community has focused on the complex pathogenesis of COVID-19 disease. Many studies have described the multifactorial nature of COVID-19, and have demonstrated thrombocytopenia, endothelial damage, impaired aggregation, impaired bone marrow function, and decreased megakaryocyte activity [57,58].

It is also known that many of the factors mentioned above, such as endothelial damage, platelet activation, and thrombosis, are also the hidden villains behind the physiopathology of HELLP syndrome and PE [59]. HELLP syndrome is a multisystemic disorder seen in 0.5%-0.9% of all pregnancies, mostly in the last trimester (70%), in multiparous women, and in advanced cases that are not diagnosed or treated early. HELLP syndrome has been associated with impaired renal function, intracranial hemorrhage, intrahepatic hemorrhage, coagulopathy, and disseminated intravascular coagulation [59]. Unfortunately, similar symptoms are often also present in pregnant COVID-19 patients, which makes the diagnosis challenging. Nevertheless, early recognition of the diagnosis could be life-saving, as mentioned in a study by Arslan *et al* [60]. The authors reported a case of a 30-year-old primigravida woman with COVID-19 and severe HELLP syndrome with a fatal outcome for mother and baby. Despite definitive evidence, given the sequence of events in this case, it is reasonable to speculate that COVID-19 may be a contributing factor in the development HELLP syndrome. Čivrná *et al* [61] reported another interesting case series describing the differences between HELLP and HELLP-like syndromes associated with COVID-19. In this study, 1 patient was noted to have elevated liver enzymes, elevated LDH, and a low ratio of angiogenic biomarkers, but did not have pregnancy complications. Laboratory findings in this patient normalized after recovering from SARS-CoV-2 infection. Hence, the authors diagnosed this patient with HELLP-like syndrome. In contrast, another patient in this case series did meet the criteria for HELLP syndrome, and her condition deteriorated resulting in respiratory failure and hepatic rupture. Proper early diagnosis of HELLP syndrome in severe COVID-19 in pregnancy could pose a diagnostic dilemma due to the similarity in presentations of these conditions [61].

Ronnje *et al* [62] reported a case of a 26-year-old woman with atypical HELLP syndrome and severe COVID-19, highlighting the similarities between the two conditions and the fact that prompt diagnosis may be delayed. This study also proposed that COVID-19 infection during pregnancy is linked to an increased risk of maternal thrombotic incidents, given that pregnancy itself induces a hypercoagulable state. In this case report, the conclusion that the severe COVID-19 infection caused the patient's liver injury and coagulation dysfunction was supported by detection of high D-dimer levels and elevated liver enzymes [62]. Misdiagnosis might lead to unnecessary intervention and iatrogenic prematurity or

underestimation of the severity of HELLP syndrome, causing delayed therapeutic intervention. As such, further investigation into this topic is of paramount importance to clarify the exact mechanisms, design an adequate therapeutic strategy, and avoid adverse outcomes.

As a late pregnancy-related liver disease, HELLP syndrome is a well-known culprit implicated in various complications. Among the most life-threatening of these is liver rupture with or without infarction[63]. Hepatic rupture has a low incidence rate (approximately 1 per 200000 pregnancies). It is primarily associated with AFLP or HELLP syndrome, and rarely occurs without associated liver disease. After excluding all non-pregnancy-related liver diseases, clinicians should consider 3 other possible causes of liver rupture in pregnancy: HELLP syndrome, severe PE, and rupture of hemangioma. Current reports assessing the pathogenetic mechanism of hepatic rupture in pregnant patients focus largely on HELLP syndrome. However, with the growing impact of COVID-19 and the millions of affected patients globally, among which are a significant percentage of pregnant women, the question arises whether SARS-CoV-2 could contribute to such a serious complication. One of the first to associate COVID-19 and hepatic rupture was a case of a 32-year-old pregnant patient reported by Ambrož *et al*[64]. This patient was found with SARS-CoV-2 infection in the third trimester; her condition deteriorated resulting in bilateral pneumonia and hemoperitoneum as a result of hepatic rupture. Vascular effects (*e.g.*, endotheliitis, procoagulation, or thrombosis) seem to be essential contributors to the worsening of hepatopathy during pregnancy, possibly through changes affecting the endothelium occurring during severe inflammatory response. These changes are thought to underlie liver rupture in the setting of pregnancy. In another study by Ahmed *et al*[65], a case of hemorrhage with intraabdominal hematoma was reported in a patient with severe COVID-19, PE, and HELLP syndrome.

Finally, high rates of infant and maternal mortality have been reported, 42% and 39%, respectively. These data underscore the need for close collaboration between the obstetrician and the surgeon[66,67]. As such, COVID-19 complications in pregnant patients including severe hepatopathy require further research.

PREGNANCY OUTCOMES AFTER LIVER INJURY

We reviewed available literature regarding COVID-19 in women with pregnancy-related hepatic injury. In total, 34 pregnant COVID-19 patients and 37 infants were included in our review[49,50,54,56,60-62,65,68]. We determined that the most common reported liver disease in pregnancy was IHC, followed by HELLP syndrome, and AFLP (61.7%, 32.3% and 2.9%, respectively). Most patients reported flu-like symptoms ($n = 27$), and 6 patients (17.65%) were diagnosed with pneumonia or acute respiratory distress syndrome (ARDS). Two pregnant women reported abdominal pain, and only one was diagnosed with intraabdominal hemorrhage. Only 1 patient presented with sepsis and multiorgan failure. A significant percentage (88.2%) of the women underwent C-section (Table 1).

With respect to maternal mortality rates, 2 (5.88%) pregnant women in the reviewed cases died; both cases were significant for HELLP syndrome (1 in week 22 and 1 in week 32 of gestation). Neonatal or fetal death were found in 4 cases (10.81%). Two babies were delivered at week 29 by mothers with IHC, while the other two were delivered at week by mothers with HELLP syndrome (Table 1). With respect to maternal medical history and treatment strategies employed, we cannot accurately report the data as they were not reported in the reviewed studies. Another limitation of our research was inability to assess the maternal age and gestational ages of fetuses with preterm delivery due to lack available data.

To our knowledge, this literature review is among the few that have addressed COVID-19 in pregnant patients with associated liver injury. However, despite review of the available data on the topic, there are still some missing points in etiopathogenetic mechanisms and the outcomes of COVID-19-related liver injury in pregnancy. The relevant available studies are summarized in Table 1.

Taken together, the results of available literature have shown that liver injury should be considered in pregnant patients with COVID-19. To this end, active follow-up and treatment of COVID-19 is mandatory. However, not a single laboratory or a clinical marker could be established as definitive for COVID-19-related liver injury. Usually, liver enzymes are elevated in these cases; however, this finding may be a consequence of pharmacotherapy (*e.g.*, systemic glucocorticoids or antiviral, anti-inflammatory, or anticoagulant drugs). Comorbidities such as established liver disease, diabetes, hypertension, and obesity frequently result in non-alcoholic hepatosteatosis and may also impact the onset and severity of liver injury caused by SARS-CoV-2 during pregnancy. Pregnancy itself is a risk factor for severe COVID-19; therefore, managing liver injury during pregnancy is a significant challenge and requires a multispecialty approach.

VACCINATION FOR PREGNANT WOMEN TO AVOID COMPLICATIONS

Similar to those with autoimmune diseases, pregnant women have generally been excluded from clinical trials of novel drugs and vaccinations due to worries regarding fetal consequences. This has also been true of COVID-19 vaccines thus far[69].

Table 1 Coronavirus disease 2019-related liver injuries in pregnant women

Ref.	Number of patients	Type of disease	Concomitant disease	Past disease	Age	Gestational week	Symptoms	Treatment	Outcome
Ronnje <i>et al</i> [62]	1	HELLP	HT; OO	Appendectomy; cholecystectomy	26	32	Flu-like (myalgia, arthralgia, cough); abdominal pain; fever	CS paracetamol; Morphine; dalteparin 7500 UI/d; betamethasone; cefotaxime	M + B: alive
Mendoza <i>et al</i> [49]	5	PE; HELLP	NR	NR	39.4 (34.2-44.5)	28.6 (22.3-32.4)	Severe pneumonia	1 CS, hypertensive therapy; 4 no delivery	M + B: alive
Rabiei <i>et al</i> [56]	1	IHCP	HT; GDM	Primary infertility	38	29 + 2	Flu-like (myalgia, arthralgia, cough)	UDCA; CS	M and 2 nd baby: alive; 1 st and 3 rd baby: death
Ahmed <i>et al</i> [65]	1	HELLP	NR	NR	26	NR	Confusion; intraabdominal hematoma	Surgery; CS	M + B: Alive
Čivrná <i>et al</i> [61]	2	HELLP; HR	NR	NR	NR	NR	1 st flu-like (myalgia, arthralgia, cough); 2 nd ARDS, HR	CS	1 st M + B: alive; 2 nd : NR
Choudhary <i>et al</i> [51]	1	PE; AFLP	NR	NR	27	35	Icteric fever; flu-like (myalgia, arthralgia, cough); renal failure	Labetalol 200 mg/d; Mg sulfate; CS	M + Both babies: alive
Arslan <i>et al</i> [60]	1	HELLP	NR	NR	30	32	Flu-like (myalgia, arthralgia, cough); fever; pneumonia; renal failure; sepsis	CS	M + B: death
D'Ambrosi <i>et al</i> [54]	20	IHCP	NR	NR	30.5 ± 5.7		Flu-like (myalgia, arthralgia, cough); fever	NR	M + B: alive
Futterman <i>et al</i> [68]	2	HELLP	NR	NR	NR	22; 29	NR	NR	1 st M + B: death; 2 nd M + B: alive

AFLP: Acute fatty liver of pregnancy; ARDS: Acute hypoxemic respiratory failure; B: Baby; CS: Corticosteroids; GDM: Gestational diabetes mellitus; GW: Gestational week; HELLP: Hemolysis, elevated liver enzymes and low platelets; HR: Hepatic rupture; HT: Hypothyroidism; IHCP: Intrahepatic cholestasis of pregnancy; M: Mother; M + B: Mother and baby; Mg: Magnesium; NR: Not reported, OO: Overweight and obese; PE: Preeclampsia; UDCA: Ursodeoxycholic acid.

Although there are limited data on the efficacy and safety in pregnant women, the Centers for Disease Control and Prevention, the American College of Obstetricians and Gynecologists, and the Society for Maternal-Fetal Medicine have each issued guidelines for the use of COVID-19 vaccines in pregnant women[70]. These guidelines are supported by data suggesting that vaccines reduce mortality and complications in SARS-CoV-2 infected people, especially those at high risk for severe disease.

LIMITATIONS

Our narrative review has been conducted by using a search strategy that is adequate to retrieve relevant studies. Although we presented a thorough review of available literature, we acknowledge some limitations. First, liver disease associated with SARS-CoV-2 infection during pregnancy is still understudied. This has resulted in a relatively small number of available case reports, original articles, reviews, and considerations of official societies. Second, despite all the collected data on the topic, there are still some missing points in etiopathogenetic mechanisms and the outcomes associated with COVID-19-related hepatic injury in pregnancy. Most authors did not report data on maternal medical history and treatment strategies utilized; therefore, we cannot present accurate information these topics. Another disadvantage we faced during review of the available literature was that maternal and gestational ages at the time of preterm delivery were also often not reported. Finally, the narrative

nature of our review did not allow us to make conclusions based on statistical analyses. However, we believe that these limitations are minor and represent opportunities to inform future research. Our aim to describe and summarize potential liver injuries in pregnant women with COVID-19 will hopefully be of tremendous help to consulting gynecologists and hepatologists who may encounter this scenario.

FUTURE DIRECTIONS

Many questions regarding how to promptly diagnose COVID-19-related liver injury in pregnant women remain. An algorithm that includes a diagnostic approach for these patients, including laboratory testing, clinical and imaging investigations, and most importantly, management (treatment and follow-up), is needed. Since pregnancy, underlying liver conditions, and others are risk factors for severe COVID-19 and adverse outcomes, liver injury is a highly unfavorable prognostic marker. More studies that include pregnant women with COVID-19 could help close the gap in knowledge and will improve the recommendations for clinical practice.

CONCLUSION

It is accepted that immunological reactions and cardiovascular changes brought on by pregnancy may accelerate the progression of COVID-19. However, little is known about the course of liver disease and associated outcomes in pregnant COVID-19 patients. Several factors, including severe hypoxemia due to acute respiratory failure, drug interactions, septic shock, and multiorgan dysfunction have been linked to acute liver damage in severe COVID-19 disease. Transient elevations in serum aminotransferases are common. Much of the research on COVID-19 and its effects on pregnant patients with hepatic injury is still ongoing. The management of liver injury during pregnancy is a significant challenge and requires a multispecialty approach that should utilize established classifications set forth by various professional obstetric organizations. Among the most common pregnancy- and liver-related complications are hyperemesis gravidarum, IHC, PE, HELLP syndrome, and AFLP. Finally, vaccination in pregnant women may reduce the risk of severe COVID-19 during pregnancy and help to avoid adverse delivery outcomes.

FOOTNOTES

Author contributions: Georgiev T and Sekulovski M contributed to the conceptualization; Georgiev T Sekulovski M, Bogdanova-Petrova S and Peshevska-Sekulovska M contributed to the resources and literature review; Georgiev T, Sekulovski M, Bogdanova-Petrova S and Peshevska-Sekulovska M contributed to the preparation of original draft; Georgiev T, Sekulovski M, Velikova T contributed to the review and editing; Georgiev T, and Velikova T contributed to the supervision; All authors revised and approved the final version of the manuscript.

Conflict-of-interest statement: The authors declare they have no conflicts of interest.

Open-Access: This article is an open-access article that was selected by an in-house editor and fully peer-reviewed by external reviewers. It is distributed in accordance with the Creative Commons Attribution NonCommercial (CC BY-NC 4.0) license, which permits others to distribute, remix, adapt, build upon this work non-commercially, and license their derivative works on different terms, provided the original work is properly cited and the use is non-commercial. See: <https://creativecommons.org/licenses/by-nc/4.0/>

Country/Territory of origin: Bulgaria

ORCID number: Metodija Sekulovski 0000-0001-8374-7756; Simona Bogdanova-Petrova 0000-0002-2601-2021; Monika Peshevska-Sekulovska 0000-0002-8468-0132; Tsvetelina Velikova 0000-0002-0593-1272; Tsvetoslav Georgiev 0000-0002-1652-4648.

S-Editor: Chang KL

L-Editor: Filipodia

P-Editor: Chang KL

REFERENCES

- 1 **World Health Organization.** Weekly epidemiological update on COVID-19 - 21 December 2022. [cited 4 January 2023]. Available from: <https://www.who.int/publications/m/item/covid-19-weekly-epidemiological-update---21-december-2022>

- 2 **Georgiev T**, Angelov AK. Complexities of diagnosis and management of COVID-19 in autoimmune diseases: Potential benefits and detriments of immunosuppression. *World J Clin Cases* 2020; **8**: 3669-3678 [PMID: [32953843](#) DOI: [10.12998/wjcc.v8.i17.3669](#)]
- 3 **Hoffmann M**, Kleine-Weber H, Schroeder S, Krüger N, Herrler T, Erichsen S, Schiergens TS, Herrler G, Wu NH, Nitsche A, Müller MA, Drosten C, Pöhlmann S. SARS-CoV-2 Cell Entry Depends on ACE2 and TMPRSS2 and Is Blocked by a Clinically Proven Protease Inhibitor. *Cell* 2020; **181**: 271-280.e8 [PMID: [32142651](#) DOI: [10.1016/j.cell.2020.02.052](#)]
- 4 **Velikova T**, Snegarova V, Kukov A, Batselova H, Mihova A, Nakov R. Gastrointestinal mucosal immunity and COVID-19. *World J Gastroenterol* 2021; **27**: 5047-5059 [PMID: [34497434](#) DOI: [10.3748/wjg.v27.i30.5047](#)]
- 5 **Chai X**, Hu L, Zhang Y, Han W, Lu Z, Ke A, Zhou J, Shi G, Fang N, Fan J, Cai J, Lan F. Specific ACE2 expression in cholangiocytes may cause liver damage after 2019-nCoV infection. 2020 Preprint. Available from: [bioRxiv:2020.02.03.931766](#) [DOI: [10.1101/2020.02.03.931766](#)]
- 6 **Li J**, Fan JG. Characteristics and Mechanism of Liver Injury in 2019 Coronavirus Disease. *J Clin Transl Hepatol* 2020; **8**: 13-17 [PMID: [32274341](#) DOI: [10.14218/JCTH.2020.00019](#)]
- 7 **Velikova TV**, Kotsev SV, Georgiev DS, Batselova HM. Immunological aspects of COVID-19: What do we know? *World J Biol Chem* 2020; **11**: 14-29 [PMID: [33024515](#) DOI: [10.4331/wjbc.v11.i2.14](#)]
- 8 **Mikolasevic I**, Filipec-Kanizaj T, Jakopcic I, Majurec I, Brncic-Fischer A, Sobocan N, Hratic I, Stimac T, Stimac D, Milic S. Liver Disease During Pregnancy: A Challenging Clinical Issue. *Med Sci Monit* 2018; **24**: 4080-4090 [PMID: [29905165](#) DOI: [10.12659/MSM.907723](#)]
- 9 **Jamieson DJ**, Rasmussen SA. An update on COVID-19 and pregnancy. *Am J Obstet Gynecol* 2022; **226**: 177-186 [PMID: [34534497](#) DOI: [10.1016/j.ajog.2021.08.054](#)]
- 10 **Gasparyan AY**, Ayvazyan L, Blackmore H, Kitaz GD. Writing a narrative biomedical review: considerations for authors, peer reviewers, and editors. *Rheumatol Int* 2011; **31**: 1409-1417 [PMID: [21800117](#) DOI: [10.1007/s00296-011-1999-3](#)]
- 11 **Shi H**, Han X, Jiang N, Cao Y, Alwalid O, Gu J, Fan Y, Zheng C. Radiological findings from 81 patients with COVID-19 pneumonia in Wuhan, China: a descriptive study. *Lancet Infect Dis* 2020; **20**: 425-434 [PMID: [32105637](#) DOI: [10.1016/S1473-3099\(20\)30086-4](#)]
- 12 **Zhang C**, Shi L, Wang FS. Liver injury in COVID-19: management and challenges. *Lancet Gastroenterol Hepatol* 2020; **5**: 428-430 [PMID: [32145190](#) DOI: [10.1016/S2468-1253\(20\)30057-1](#)]
- 13 **Georgakopoulou VE**, Bali T, Adamantou M, Asimakopoulou S, Makrodimitri S, Samara S, Triantafyllou M, Voutsinas PM, Eliadi I, Karamanakis G, Basoulis D, Chatzipanagiotou O, Adamopoulou E, Alevizou A, Athanasiadis M, Spandidos DA, Papalexis P, Tarantinos K, Sipsas NV, Samarkos M, Cholongitis E. Acute hepatitis and liver injury in hospitalized patients with COVID-19 infection. *Exp Ther Med* 2022; **24**: 691 [PMID: [36277149](#) DOI: [10.3892/etm.2022.11627](#)]
- 14 **Yao X**, Ye F, Zhang M, Cui C, Huang B, Niu P, Liu X, Zhao L, Dong E, Song C, Zhan S, Lu R, Li H, Tan W, Liu D. In Vitro Antiviral Activity and Projection of Optimized Dosing Design of Hydroxychloroquine for the Treatment of Severe Acute Respiratory Syndrome Coronavirus 2 (SARS-CoV-2). *Clin Infect Dis* 2020; **71**: 732-739 [PMID: [32150618](#) DOI: [10.1093/cid/ciaa237](#)]
- 15 **Taneva G**, Dimitrov D, Velikova T. Liver dysfunction as a cytokine storm manifestation and prognostic factor for severe COVID-19. *World J Hepatol* 2021; **13**: 2005-2012 [PMID: [35070004](#) DOI: [10.4254/wjh.v13.i12.2005](#)]
- 16 **Cooper KM**, Colletta A, Asirwatham AM, Moore Simas TA, Devuni D. COVID-19 associated liver injury: A general review with special consideration of pregnancy and obstetric outcomes. *World J Gastroenterol* 2022; **28**: 6017-6033 [PMID: [36405386](#) DOI: [10.3748/wjg.v28.i42.6017](#)]
- 17 **Mohammed SA**, Eid KM, Anyiam FE, Wadaaallah H, Muhamed MAM, Morsi MH, Dahman NBH. Liver injury with COVID-19: laboratory and histopathological outcome-systematic review and meta-analysis. *Egypt Liver J* 2022; **12**: 9 [PMID: [35096428](#) DOI: [10.1186/s43066-022-00171-6](#)]
- 18 **Yu D**, Du Q, Yan S, Guo XG, He Y, Zhu G, Zhao K, Ouyang S. Liver injury in COVID-19: clinical features and treatment management. *Virol J* 2021; **18**: 121 [PMID: [34108015](#) DOI: [10.1186/s12985-021-01593-1](#)]
- 19 **Zhao B**, Ni C, Gao R, Wang Y, Yang L, Wei J, Lv T, Liang J, Zhang Q, Xu W, Xie Y, Wang X, Yuan Z, Zhang R, Lin X. Recapitulation of SARS-CoV-2 infection and cholangiocyte damage with human liver ductal organoids. *Protein Cell* 2020; **11**: 771-775 [PMID: [32303993](#) DOI: [10.1007/s13238-020-00718-6](#)]
- 20 **Du M**, Cai G, Chen F, Christiani DC, Zhang Z, Wang M. Multiomics Evaluation of Gastrointestinal and Other Clinical Characteristics of COVID-19. *Gastroenterology* 2020; **158**: 2298-2301.e7 [PMID: [32234303](#) DOI: [10.1053/j.gastro.2020.03.045](#)]
- 21 **Yao XH**, Li TY, He ZC, Ping YF, Liu HW, Yu SC, Mou HM, Wang LH, Zhang HR, Fu WJ, Luo T, Liu F, Guo QN, Chen C, Xiao HL, Guo HT, Lin S, Xiang DF, Shi Y, Pan GQ, Li QR, Huang X, Cui Y, Liu XZ, Tang W, Pan PF, Huang XQ, Ding YQ, Bian XW. A pathological report of three COVID-19 cases by minimal invasive autopsies. *Zhonghua Bing Li Xue Za Zhi* 2020; **49**: 411-417 [PMID: [32172546](#) DOI: [10.3760/cma.j.cn112151-20200312-00193](#)]
- 22 **Karlafti E**, Paramythiotis D, Pantazi K, Georgakopoulou VE, Kaiafa G, Papalexis P, Protopapas AA, Ztriva E, Fyntanidou V, Savopoulos C. Drug-Induced Liver Injury in Hospitalized Patients during SARS-CoV-2 Infection. *Medicina (Kaunas)* 2022; **58** [PMID: [36557050](#) DOI: [10.3390/medicina58121848](#)]
- 23 **Mao R**, Qiu Y, He JS, Tan JY, Li XH, Liang J, Shen J, Zhu LR, Chen Y, Iacucci M, Ng SC, Ghosh S, Chen MH. Manifestations and prognosis of gastrointestinal and liver involvement in patients with COVID-19: a systematic review and meta-analysis. *Lancet Gastroenterol Hepatol* 2020; **5**: 667-678 [PMID: [32405603](#) DOI: [10.1016/S2468-1253\(20\)30126-6](#)]
- 24 **Wander P**, Epstein M, Bernstein D. COVID-19 Presenting as Acute Hepatitis. *Am J Gastroenterol* 2020; **115**: 941-942 [PMID: [32301760](#) DOI: [10.14309/ajg.0000000000000660](#)]
- 25 **Lazova S**, Alexandrova T, Gorelyova-Stefanova N, Atanasov K, Tzotcheva I, Velikova T. Liver Involvement in Children with COVID-19 and Multisystem Inflammatory Syndrome: A Single-Center Bulgarian Observational Study. *Microorganisms* 2021; **9** [PMID: [34576853](#) DOI: [10.3390/microorganisms9091958](#)]
- 26 **LaCourse SM**, Kachikis A, Blain M, Simmons LE, Mays JA, Pattison AD, Salerno CC, McCartney SA, Kretzer NM, Resnick R, Shay RL, Savitsky LM, Curtin AC, Huebner EM, Ma KK, Delaney S, Delgado C, Schippers A, Munson J, Pottinger PS, Cohen S, Neme S, Bourassa L, Bryan A, Greninger A, Jerome KR, Roxby AC, Lokken E, Cheng E, Adams

- Waldorf KM, Hitti J. Low Prevalence of Severe Acute Respiratory Syndrome Coronavirus 2 Among Pregnant and Postpartum Patients With Universal Screening in Seattle, Washington. *Clin Infect Dis* 2021; **72**: 869-872 [PMID: [32472688](#) DOI: [10.1093/cid/ciaa675](#)]
- 27 **Vintzileos WS**, Muscat J, Hoffmann E, John NS, Vertichio R, Vintzileos AM, Vo D. Screening all pregnant women admitted to labor and delivery for the virus responsible for coronavirus disease 2019. *Am J Obstet Gynecol* 2020; **223**: 284-286 [PMID: [32348743](#) DOI: [10.1016/j.ajog.2020.04.024](#)]
- 28 **Kelly JC**, Raghuraman N, Carter EB, Palanisamy A, Stout MJ. Preprocedural asymptomatic coronavirus disease 2019 cases in obstetrical and surgical units. *Am J Obstet Gynecol* 2021; **224**: 114-116 [PMID: [32971011](#) DOI: [10.1016/j.ajog.2020.09.023](#)]
- 29 **Zambrano LD**, Ellington S, Strid P, Galang RR, Oduyebo T, Tong VT, Woodworth KR, Nahabedian JF 3rd, Azziz-Baumgartner E, Gilboa SM, Meaney-Delman D; CDC COVID-19 Response Pregnancy and Infant Linked Outcomes Team. Update: Characteristics of Symptomatic Women of Reproductive Age with Laboratory-Confirmed SARS-CoV-2 Infection by Pregnancy Status - United States, January 22-October 3, 2020. *MMWR Morb Mortal Wkly Rep* 2020; **69**: 1641-1647 [PMID: [33151921](#) DOI: [10.15585/mmwr.mm6944e3](#)]
- 30 **Galang RR**, Newton SM, Woodworth KR, Griffin I, Oduyebo T, Sancken CL, Olsen EO, Aveni K, Wingate H, Shephard H, Fussman C, Alaali ZS, Silcox K, Siebman S, Halai UA, Lopez CD, Lush M, Sokale A, Barton J, Chaudhary I, Patrick PH, Schlosser L, Reynolds B, Gaarenstroom N, Chicchelly S, Read JS, de Wilde L, Mbotha D, Azziz-Baumgartner E, Hall AJ, Tong VT, Ellington S, Gilboa SM; Centers for Disease Control and Prevention COVID-19 Response Pregnancy and Infant Linked Outcomes Team. Risk Factors for Illness Severity Among Pregnant Women With Confirmed Severe Acute Respiratory Syndrome Coronavirus 2 Infection-Surveillance for Emerging Threats to Mothers and Babies Network, 22 State, Local, and Territorial Health Departments, 29 March 2020-5 March 2021. *Clin Infect Dis* 2021; **73**: S17-S23 [PMID: [34021332](#) DOI: [10.1093/cid/ciab432](#)]
- 31 **Metz TD**, Clifton RG, Hughes BL, Sandoval G, Saade GR, Grobman WA, Manuck TA, Miodovnik M, Sowles A, Clark K, Gyamfi-Bannerman C, Mendez-Figueroa H, Sehdev HM, Rouse DJ, Tita ATN, Bailit J, Costantine MM, Simhan HN, Macones GA; Eunice Kennedy Shriver National Institute of Child Health and Human Development (NICHD) Maternal-Fetal Medicine Units (MFMU) Network. Disease Severity and Perinatal Outcomes of Pregnant Patients With Coronavirus Disease 2019 (COVID-19). *Obstet Gynecol* 2021; **137**: 571-580 [PMID: [33560778](#) DOI: [10.1097/AOG.0000000000004339](#)]
- 32 **Longman RE**, Johnson TR. Viral respiratory disease in pregnancy. *Curr Opin Obstet Gynecol* 2007; **19**: 120-125 [PMID: [17353679](#) DOI: [10.1097/GCO.0b013e328028fde7](#)]
- 33 **Mazziotta C**, Pelliolo G, Tognon M, Martini F, Rotondo JC. Significantly Low Levels of IgG Antibodies Against Oncogenic Merkel Cell Polyomavirus in Sera From Females Affected by Spontaneous Abortion. *Front Microbiol* 2021; **12**: 789991 [PMID: [34970247](#) DOI: [10.3389/fmicb.2021.789991](#)]
- 34 **American College of Obstetricians and Gynecologists**. COVID-19 Vaccination Considerations for Obstetric-Gynecologic Care. [cited 20 September 2022]. Available from: <https://www.acog.org/clinical/clinical-guidance/practice-advisory/articles/2020/12/covid-19-vaccination-considerations-for-obstetric-gynecologic-care>
- 35 **Chmielewska B**, Barratt I, Townsend R, Kalafat E, van der Meulen J, Gurol-Urganci I, O'Brien P, Morris E, Draycott T, Thangaratnam S, Le Doare K, Ladhani S, von Dadelszen P, Magee L, Khalil A. Effects of the COVID-19 pandemic on maternal and perinatal outcomes: a systematic review and meta-analysis. *Lancet Glob Health* 2021; **9**: e759-e772 [PMID: [33811827](#) DOI: [10.1016/S2214-109X\(21\)00079-6](#)]
- 36 **Balachandren N**, Davies MC, Hall JA, Stephenson JM, David AL, Barrett G, O'Neill HC, Ploubidis GB, Yasmin E, Mavrelos D. SARS-CoV-2 infection in the first trimester and the risk of early miscarriage: a UK population-based prospective cohort study of 3041 pregnancies conceived during the pandemic. *Hum Reprod* 2022; **37**: 1126-1133 [PMID: [35389480](#) DOI: [10.1093/humrep/deac062](#)]
- 37 **Zu ZY**, Jiang MD, Xu PP, Chen W, Ni QQ, Lu GM, Zhang LJ. Coronavirus Disease 2019 (COVID-19): A Perspective from China. *Radiology* 2020; **296**: E15-E25 [PMID: [32083985](#) DOI: [10.1148/radiol.202000490](#)]
- 38 **Mao R**, Liang J, Shen J, Ghosh S, Zhu LR, Yang H, Wu KC, Chen MH; Chinese Society of IBD, Chinese Elite IBD Union; Chinese IBD Quality Care Evaluation Center Committee. Implications of COVID-19 for patients with pre-existing digestive diseases. *Lancet Gastroenterol Hepatol* 2020; **5**: 425-427 [PMID: [32171057](#) DOI: [10.1016/S2468-1253\(20\)30076-5](#)]
- 39 **Guan WJ**, Ni ZY, Hu Y, Liang WH, Ou CQ, He JX, Liu L, Shan H, Lei CL, Hui DSC, Du B, Li LJ, Zeng G, Yuen KY, Chen RC, Tang CL, Wang T, Chen PY, Xiang J, Li SY, Wang JL, Liang ZJ, Peng YX, Wei L, Liu Y, Hu YH, Peng P, Wang JM, Liu JY, Chen Z, Li G, Zheng ZJ, Qiu SQ, Luo J, Ye CJ, Zhu SY, Zhong NS; China Medical Treatment Expert Group for Covid-19. Clinical Characteristics of Coronavirus Disease 2019 in China. *N Engl J Med* 2020; **382**: 1708-1720 [PMID: [32109013](#) DOI: [10.1056/NEJMoa2002032](#)]
- 40 **Deng G**, Zeng F, Zhang L, Chen H, Chen X, Yin M. Characteristics of pregnant patients with COVID-19 and liver injury. *J Hepatol* 2020; **73**: 989-991 [PMID: [32569609](#) DOI: [10.1016/j.jhep.2020.06.022](#)]
- 41 **Anness A**, Siddiqui F. COVID-19 complicated by hepatic dysfunction in a 28-week pregnant woman. *BMJ Case Rep* 2020; **13** [PMID: [32878840](#) DOI: [10.1136/bcr-2020-237007](#)]
- 42 **Can E**, Oğlak SC, Ölmez F. Abnormal liver function tests in pregnant patients with COVID-19 - a retrospective cohort study in a tertiary center. *Ginekolo Pol* 2022 [PMID: [35072238](#) DOI: [10.5603/GP.a2021.0182](#)]
- 43 **Lamazou F**, Oger P, Dieli-Crimi R, Guerin A, Letouzey V, Octernaud S, Place V, Calès P, Descamps P, Delaroche L. COVID-19 infection in first trimester of pregnancy marked by a liver cytolysis in a woman previously treated by hydroxychloroquine for repeated implantation failure: a case report. *BMC Infect Dis* 2020; **20**: 845 [PMID: [33198681](#) DOI: [10.1186/s12879-020-05551-0](#)]
- 44 **Sharma AV**, John S. Liver Disease In Pregnancy. 2022 Jun 21. In: StatPearls [Internet]. Treasure Island (FL): StatPearls Publishing; 2022 Jan- [PMID: [29489187](#)]
- 45 **Chornock R**, Iqbal SN, Wang T, Kodama S, Kawakita T, Fries M. Incidence of Hypertensive Disorders of Pregnancy in Women with COVID-19. *Am J Perinatol* 2021; **38**: 766-772 [PMID: [33940651](#) DOI: [10.1055/s-0041-1727167](#)]

- 46 **Antoun L**, Taweel NE, Ahmed I, Patni S, Honest H. Maternal COVID-19 infection, clinical characteristics, pregnancy, and neonatal outcome: A prospective cohort study. *Eur J Obstet Gynecol Reprod Biol* 2020; **252**: 559-562 [PMID: [32732059](#) DOI: [10.1016/j.ejogrb.2020.07.008](#)]
- 47 **Li Y**, Zhou W, Yang L, You R. Physiological and pathological regulation of ACE2, the SARS-CoV-2 receptor. *Pharmacol Res* 2020; **157**: 104833 [PMID: [32302706](#) DOI: [10.1016/j.phrs.2020.104833](#)]
- 48 **Sathiyaraj R**, Rajendran J, Sumathi S. COVID-19 and Preeclampsia: Overlapping Features in Pregnancy. *Rambam Maimonides Med J* 2022; **13** [PMID: [35089126](#) DOI: [10.5041/RMMJ.10464](#)]
- 49 **Mendoza M**, Garcia-Ruiz I, Maiz N, Rodo C, Garcia-Manau P, Serrano B, Lopez-Martinez RM, Balcells J, Fernandez-Hidalgo N, Carreras E, Suy A. Pre-eclampsia-like syndrome induced by severe COVID-19: a prospective observational study. *BJOG* 2020; **127**: 1374-1380 [PMID: [32479682](#) DOI: [10.1111/1471-0528.16339](#)]
- 50 **Ch'ng CL**, Morgan M, Hainsworth I, Kingham JG. Prospective study of liver dysfunction in pregnancy in Southwest Wales. *Gut* 2002; **51**: 876-880 [PMID: [12427793](#) DOI: [10.1136/gut.51.6.876](#)]
- 51 **Choudhary A**, Singh V, Bharadwaj M, Barik A. Pregnancy With SARS-CoV-2 Infection Complicated by Preeclampsia and Acute Fatty Liver of Pregnancy. *Cureus* 2021; **13**: e15645 [PMID: [34306855](#) DOI: [10.7759/cureus.15645](#)]
- 52 **Cai Q**, Huang D, Yu H, Zhu Z, Xia Z, Su Y, Li Z, Zhou G, Gou J, Qu J, Sun Y, Liu Y, He Q, Chen J, Liu L, Xu L. COVID-19: Abnormal liver function tests. *J Hepatol* 2020; **73**: 566-574 [PMID: [32298767](#) DOI: [10.1016/j.jhep.2020.04.006](#)]
- 53 **Morton A**. Presumed acute fatty liver of pregnancy following influenza A hepatitis. *Obstet Med* 2017; **10**: 186-188 [PMID: [29225680](#) DOI: [10.1177/1753495X17695173](#)]
- 54 **D'Ambrosi F**, Di Maso M, Viscardi A, Ossola MW, Soldavini CM, Cetera GE, Erra R, Ferrazzi E. Serum hepatic biomarkers in women with obstetric cholestasis and a concurrent SARS-CoV-2 infection. *J Obstet Gynaecol Res* 2022; **48**: 2713-2720 [PMID: [35915565](#) DOI: [10.1111/jog.15383](#)]
- 55 **Geenes V**, Chappell LC, Seed PT, Steer PJ, Knight M, Williamson C. Association of severe intrahepatic cholestasis of pregnancy with adverse pregnancy outcomes: a prospective population-based case-control study. *Hepatology* 2014; **59**: 1482-1491 [PMID: [23857305](#) DOI: [10.1002/hep.26617](#)]
- 56 **Rabiei M**, Soori T, Abiri A, Farsi Z, Shizarpour A, Pirjani R. Maternal and fetal effects of COVID-19 virus on a complicated triplet pregnancy: a case report. *J Med Case Rep* 2021; **15**: 87 [PMID: [33602315](#) DOI: [10.1186/s13256-020-02643-y](#)]
- 57 **Lippi G**, Plebani M, Henry BM. Thrombocytopenia is associated with severe coronavirus disease 2019 (COVID-19) infections: A meta-analysis. *Clin Chim Acta* 2020; **506**: 145-148 [PMID: [32178975](#) DOI: [10.1016/j.cca.2020.03.022](#)]
- 58 **Zulfikar AA**, Lorenzo-Villalba N, Hassler P, Andr  s E. Immune Thrombocytopenic Purpura in a Patient with Covid-19. *N Engl J Med* 2020; **382**: e43 [PMID: [32294340](#) DOI: [10.1056/NEJMc2010472](#)]
- 59 **Mihu D**, Costin N, Mihu CM, Seicean A, Ciordea R. HELLP syndrome - a multisystemic disorder. *J Gastrointest Liver Dis* 2007; **16**: 419-424 [PMID: [18193124](#)]
- 60 **Arslan E**. COVID-19: A Cause of HELLP Syndrome? *Int J Womens Health* 2022; **14**: 617-623 [PMID: [35506047](#) DOI: [10.2147/IJWH.S362877](#)]
- 61 **  ivrn   Jana**, Skanderov   Daniela, Ehrmann Ji  r  , Pilka Radovan. HELLP syndrome and HELLP-like syndrome in pregnancies with covid-19 - case reports. *Ceska Gynekol* 2021; **86**: 236-241 [PMID: [34493047](#) DOI: [10.48095/cccg2021236](#)]
- 62 **Ronnje L**, L  nsberg JK, Vikhareva O, Hansson SR, Herbst A, Zaigham M. Complicated COVID-19 in pregnancy: a case report with severe liver and coagulation dysfunction promptly improved by delivery. *BMC Pregnancy Childbirth* 2020; **20**: 511 [PMID: [32887569](#) DOI: [10.1186/s12884-020-03172-8](#)]
- 63 **Westbrook RH**, Dusheiko G, Williamson C. Pregnancy and liver disease. *J Hepatol* 2016; **64**: 933-945 [PMID: [26658682](#) DOI: [10.1016/j.jhep.2015.11.030](#)]
- 64 **Ambro  z R**, Sta  sek M, Moln  r J,   pi  cka P, Klos D, Hamb  lek J, Skanderov   D. Spontaneous liver rupture following SARS-CoV-2 infection in late pregnancy: A case report. *World J Clin Cases* 2022; **10**: 5042-5050 [PMID: [35801049](#) DOI: [10.12998/wjcc.v10.i15.5042](#)]
- 65 **Ahmed I**, Eltaweel N, Antoun L, Rehal A. Severe pre-eclampsia complicated by acute fatty liver disease of pregnancy, HELLP syndrome and acute kidney injury following SARS-CoV-2 infection. *BMJ Case Rep* 2020; **13** [PMID: [32784239](#) DOI: [10.1136/bcr-2020-237521](#)]
- 66 **Marsh FA**, Kaufmann SJ, Bhabra K. Surviving hepatic rupture in pregnancy--a literature review with an illustrative case report. *J Obstet Gynaecol* 2003; **23**: 109-113 [PMID: [12745549](#) DOI: [10.1080/0144361031000074583](#)]
- 67 **Reck T**, Bussenius-Kammerer M, Ott R, M  ller V, Beinder E, Hohenberger W. Surgical treatment of HELLP syndrome-associated liver rupture -- an update. *Eur J Obstet Gynecol Reprod Biol* 2001; **99**: 57-65 [PMID: [11604187](#) DOI: [10.1016/s0301-2115\(01\)00358-x](#)]
- 68 **Futerman I**, Toaff M, Navi L, Clare CA. COVID-19 and HELLP: Overlapping Clinical Pictures in Two Gravid Patients. *AJP Rep* 2020; **10**: e179-e182 [PMID: [32566368](#) DOI: [10.1055/s-0040-1712978](#)]
- 69 **Velikova T**, Georgiev T. SARS-CoV-2 vaccines and autoimmune diseases amidst the COVID-19 crisis. *Rheumatol Int* 2021; **41**: 509-518 [PMID: [33515320](#) DOI: [10.1007/s00296-021-04792-9](#)]
- 70 **Rasmussen SA**, Kelley CF, Horton JP, Jamieson DJ. Coronavirus Disease 2019 (COVID-19) Vaccines and Pregnancy: What Obstetricians Need to Know. *Obstet Gynecol* 2021; **137**: 408-414 [PMID: [33370015](#) DOI: [10.1097/AOG.0000000000004290](#)]



Published by **Baishideng Publishing Group Inc**
7041 Koll Center Parkway, Suite 160, Pleasanton, CA 94566, USA

Telephone: +1-925-3991568

E-mail: bpgoffice@wjgnet.com

Help Desk: <https://www.f6publishing.com/helpdesk>

<https://www.wjgnet.com>

