

World Journal of *Clinical Cases*

World J Clin Cases 2023 March 26; 11(9): 1888-2122



Contents

Thrice Monthly Volume 11 Number 9 March 26, 2023

REVIEW

- 1888 Endoscopic transluminal drainage and necrosectomy for infected necrotizing pancreatitis: Progress and challenges

Zeng Y, Yang J, Zhang JW

MINIREVIEWS

- 1903 Functional role of frontal electroencephalogram alpha asymmetry in the resting state in patients with depression: A review

Xie YH, Zhang YM, Fan FF, Song XY, Liu L

- 1918 COVID-19 related liver injuries in pregnancy

Sekulovski M, Bogdanova-Petrova S, Peshevska-Sekulovska M, Velikova T, Georgiev T

- 1930 Examined lymph node count for gastric cancer patients after curative surgery

Zeng Y, Chen LC, Ye ZS, Deng JY

- 1939 Laparoscopic common bile duct exploration to treat choledocholithiasis in situs inversus patients: A technical review

Chiu BY, Chuang SH, Chuang SC, Kuo KK

- 1951 Airway ultrasound for patients anticipated to have a difficult airway: Perspective for personalized medicine

Nakazawa H, Uzawa K, Tokumine J, Lefor AK, Motoyasu A, Yorozu T

ORIGINAL ARTICLE

Observational Study

- 1963 Clinicopathological features and expression of regulatory mechanism of the Wnt signaling pathway in colorectal sessile serrated adenomas/polyps with different syndrome types

Qiao D, Liu XY, Zheng L, Zhang YL, Que RY, Ge BJ, Cao HY, Dai YC

Randomized Controlled Trial

- 1974 Effects of individual shock wave therapy vs celecoxib on hip pain caused by femoral head necrosis

Zhu JY, Yan J, Xiao J, Jia HG, Liang HJ, Xing GY

CASE REPORT

- 1985 Very low calorie ketogenic diet and common rheumatic disorders: A case report

Rondanelli M, Patelli Z, Gasparri C, Mansueto F, Ferraris C, Nichetti M, Alalwan TA, Sajoux I, Maugeri R, Perna S

- 1992 Delayed versus immediate intervention of ruptured brain arteriovenous malformations: A case report

Bintang AK, Bahar A, Akbar M, Soraya GV, Gunawan A, Hammado N, Rachman ME, Ulhaq ZS

- 2002** Children with infectious pneumonia caused by *Ralstonia insidiosa*: A case report
Lin SZ, Qian MJ, Wang YW, Chen QD, Wang WQ, Li JY, Yang RT, Wang XY, Mu CY, Jiang K
- 2009** Transient ischemic attack induced by pulmonary arteriovenous fistula in a child: A case report
Zheng J, Wu QY, Zeng X, Zhang DF
- 2015** Motor cortex transcranial magnetic stimulation to reduce intractable postherpetic neuralgia with poor response to other therapies: Report of two cases
Wang H, Hu YZ, Che XW, Yu L
- 2021** Small bowel adenocarcinoma in neoterminal ileum in setting of stricturing Crohn's disease: A case report and review of literature
Karthikeyan S, Shen J, Keyashian K, Gubatan J
- 2029** Novel combined endoscopic and laparoscopic surgery for advanced T2 gastric cancer: Two case reports
Dai JH, Qian F, Chen L, Xu SL, Feng XF, Wu HB, Chen Y, Peng ZH, Yu PW, Peng GY
- 2036** Acromicric dysplasia caused by a mutation of fibrillin 1 in a family: A case report
Shen R, Feng JH, Yang SP
- 2043** Ultrasound-guided intra-articular corticosteroid injection in a patient with manubriosternal joint involvement of ankylosing spondylitis: A case report
Choi MH, Yoon IY, Kim WJ
- 2051** Granulomatous prostatitis after bacille Calmette-Guérin instillation resembles prostate carcinoma: A case report and review of the literature
Yao Y, Ji JJ, Wang HY, Sun LJ, Zhang GM
- 2060** Unusual capitate fracture with dorsal shearing pattern and concomitant carpometacarpal dislocation with a 6-year follow-up: A case report
Lai CC, Fang HW, Chang CH, Pao JL, Chang CC, Chen YJ
- 2067** Live births from *in vitro* fertilization-embryo transfer following the administration of gonadotropin-releasing hormone agonist without gonadotropins: Two case reports
Li M, Su P, Zhou LM
- 2074** Spontaneous conus infarction with "snake-eye appearance" on magnetic resonance imaging: A case report and literature review
Zhang QY, Xu LY, Wang ML, Cao H, Ji XF
- 2084** Transseptal approach for catheter ablation of left-sided accessory pathways in children with Marfan syndrome: A case report
Dong ZY, Shao W, Yuan Y, Lin L, Yu X, Cui L, Zhen Z, Gao L
- 2091** Occipital artery bypass importance in unsuitable superficial temporal artery: Two case reports
Hong JH, Jung SC, Ryu HS, Kim TS, Joo SP

- 2098** Anesthetic management of a patient with preoperative R-on-T phenomenon undergoing laparoscopic-assisted sigmoid colon resection: A case report
Li XX, Yao YF, Tan HY
- 2104** Pembrolizumab combined with axitinib in the treatment of skin metastasis of renal clear cell carcinoma to nasal ala: A case report
Dong S, Xu YC, Zhang YC, Xia JX, Mou Y
- 2110** Successful treatment of a rare subcutaneous emphysema after a blow-out fracture surgery using needle aspiration: A case report
Nam HJ, Wee SY

LETTER TO THE EDITOR

- 2116** Are biopsies during endoscopic ultrasonography necessary for a suspected esophageal leiomyoma? Is laparoscopy always feasible?
Beji H, Chtourou MF, Zribi S, Kallel Y, Bouassida M, Touinsi H
- 2119** Vaginal microbes confounders and implications on women's health
Nori W, H-Hameed B

ABOUT COVER

Editorial Board Member of *World Journal of Clinical Cases*, Marilia Carabotti, MD, PhD, Academic Research, Medical-Surgical Department of Clinical Sciences and Translational Medicine, University Sapienza Rome, Rome 00189, Italy. mariliacarabotti@gmail.com

AIMS AND SCOPE

The primary aim of *World Journal of Clinical Cases* (WJCC, *World J Clin Cases*) is to provide scholars and readers from various fields of clinical medicine with a platform to publish high-quality clinical research articles and communicate their research findings online.

WJCC mainly publishes articles reporting research results and findings obtained in the field of clinical medicine and covering a wide range of topics, including case control studies, retrospective cohort studies, retrospective studies, clinical trials studies, observational studies, prospective studies, randomized controlled trials, randomized clinical trials, systematic reviews, meta-analysis, and case reports.

INDEXING/ABSTRACTING

The WJCC is now abstracted and indexed in Science Citation Index Expanded (SCIE, also known as SciSearch®), Journal Citation Reports/Science Edition, Current Contents®/Clinical Medicine, PubMed, PubMed Central, Scopus, Reference Citation Analysis, China National Knowledge Infrastructure, China Science and Technology Journal Database, and Superstar Journals Database. The 2022 Edition of Journal Citation Reports® cites the 2021 impact factor (IF) for WJCC as 1.534; IF without journal self cites: 1.491; 5-year IF: 1.599; Journal Citation Indicator: 0.28; Ranking: 135 among 172 journals in medicine, general and internal; and Quartile category: Q4. The WJCC's CiteScore for 2021 is 1.2 and Scopus CiteScore rank 2021: General Medicine is 443/826.

RESPONSIBLE EDITORS FOR THIS ISSUE

Production Editor: *Ying-Yi Yuan*; Production Department Director: *Xiang Li*; Editorial Office Director: *Jin-Lei Wang*.

NAME OF JOURNAL

World Journal of Clinical Cases

ISSN

ISSN 2307-8960 (online)

LAUNCH DATE

April 16, 2013

FREQUENCY

Thrice Monthly

EDITORS-IN-CHIEF

Bao-Gan Peng, Jerzy Tadeusz Chudek, George Kontogeorgos, Maurizio Serati, Ja Hyeon Ku

EDITORIAL BOARD MEMBERS

<https://www.wjnet.com/2307-8960/editorialboard.htm>

PUBLICATION DATE

March 26, 2023

COPYRIGHT

© 2023 Baishideng Publishing Group Inc

INSTRUCTIONS TO AUTHORS

<https://www.wjnet.com/bpg/gerinfo/204>

GUIDELINES FOR ETHICS DOCUMENTS

<https://www.wjnet.com/bpg/GerInfo/287>

GUIDELINES FOR NON-NATIVE SPEAKERS OF ENGLISH

<https://www.wjnet.com/bpg/gerinfo/240>

PUBLICATION ETHICS

<https://www.wjnet.com/bpg/GerInfo/288>

PUBLICATION MISCONDUCT

<https://www.wjnet.com/bpg/gerinfo/208>

ARTICLE PROCESSING CHARGE

<https://www.wjnet.com/bpg/gerinfo/242>

STEPS FOR SUBMITTING MANUSCRIPTS

<https://www.wjnet.com/bpg/GerInfo/239>

ONLINE SUBMISSION

<https://www.f6publishing.com>



Randomized Controlled Trial

Effects of individual shock wave therapy vs celecoxib on hip pain caused by femoral head necrosis

Jun-Yu Zhu, Jun Yan, Jian Xiao, Hai-Guang Jia, Hao-Jun Liang, Geng-Yan Xing

Specialty type: Orthopedics

Provenance and peer review:

Unsolicited article; Externally peer reviewed.

Peer-review model: Single blind

Peer-review report's scientific quality classification

Grade A (Excellent): 0
Grade B (Very good): 0
Grade C (Good): C, C
Grade D (Fair): 0
Grade E (Poor): 0

P-Reviewer: Bianchi J, United States; Verlaan JJ, Netherlands

Received: November 19, 2022

Peer-review started: November 19, 2022

First decision: January 30, 2023

Revised: February 7, 2023

Accepted: March 3, 2023

Article in press: March 3, 2023

Published online: March 26, 2023



Jun-Yu Zhu, Geng-Yan Xing, Orthopedic Department, The Third Medical Center of Chinese People's Liberation Army General Hospital, The Armed Police Clinical College, Anhui Medical University, Hefei 230022, Anhui Province, China

Jun-Yu Zhu, Jun Yan, Jian Xiao, Hai-Guang Jia, Hao-Jun Liang, Orthopedic Department, The Third Medical Center of Chinese People's Liberation Army General Hospital, Beijing 100039, China

Corresponding author: Geng-Yan Xing, PhD, Additional Professor, Orthopedic Department, The Third Medical Center of Chinese People's Liberation Army General Hospital, The Armed Police Clinical College, Anhui Medical University, No. 81 Meishan Road, Hefei 230022, Anhui Province, China. jyzhu@ihep.ac.cn

Abstract

BACKGROUND

Celecoxib has been used to treat hip discomfort and functional difficulties associated with osteonecrosis of the femoral head (ONFH), although significant adverse reactions often follow long-term use. Extracorporeal shock wave therapy (ESWT) can delay the progression of ONFH, alleviate the pain and functional limitations it causes, and avoid the adverse effects of celecoxib.

AIM

To investigate the effects of individual ESWT, a treatment alternative to the use of celecoxib, in alleviating pain and dysfunction caused by ONFH.

METHODS

This was a randomized, controlled, double-blinded, non-inferiority trial. We examined 80 patients for eligibility in this study; 8 patients were excluded based on inclusion and exclusion criteria. A total of 72 subjects with ONFH were randomly assigned to group A ($n = 36$; celecoxib + alendronate + sham-placebo shock wave) or group B ($n = 36$; individual focused shock wave [ESWT based on magnetic resonance imaging three-dimensional (MRI-3D) reconstruction] + alendronate). The outcomes were assessed at baseline, at the end of treatment, and at an 8-wk follow-up. The primary outcome measure was treatment efficiency after 2 wk of intervention using the Harris hip score (HHS) (improvement of 10 points or more from the baseline was deemed sufficient). Secondary outcome measures were post-treatment HHS, visual analog scale (VAS), and Western Ontario and McMaster Universities Osteoarthritis Index (WOMAC) scores.

RESULTS

After treatment, the pain treatment efficiency of group B was greater than that of group A (69% *vs* 51%; 95% CI: 4.56% to 40.56%), with non-inferiority thresholds of -4.56% and -10%, respectively. Furthermore, the HHS, WOMAC, and VAS scores in group B dramatically improved during the follow-up period as compared to those in group A ($P < 0.001$). After therapy, the VAS and WOMAC in group A were significantly improved from the 2nd to 8th wk ($P < 0.001$), although HHS was only significantly altered at the 2 wk point ($P < 0.001$). On the 1st d and 2nd wk after treatment, HHS and VAS scores were different between groups, with the difference in HHS lasting until week 4. Neither group had severe complications such as skin ulcer infection or lower limb motor-sensory disturbance.

CONCLUSION

Individual shock wave therapy (ESWT) based on MRI-3D reconstruction was not inferior to celecoxib in managing hip pain and restrictions associated with ONFH.

Key Words: Extracorporeal shockwave therapy; Osteonecrosis of femoral head; Pain; Magnetic resonance imaging three-dimensional reconstruction; Celecoxib

©The Author(s) 2023. Published by Baishideng Publishing Group Inc. All rights reserved.

Core Tip: This is a randomized, controlled, and non-inferiority trial. To the best of our knowledge, the present study is the first to investigate the short-term effectiveness of extracorporeal shock wave therapy (ESWT) in the management of osteonecrosis of the femoral head (ONFH). Traditional ESWT was innovated by magnetic resonance imaging three-dimensional (MRI-3D) reconstruction technology. The final results demonstrate that ESWT based on MRI-3D reconstruction is not inferior to celecoxib in treating hip discomfort and restrictions associated with ONFH.

Citation: Zhu JY, Yan J, Xiao J, Jia HG, Liang HJ, Xing GY. Effects of individual shock wave therapy *vs* celecoxib on hip pain caused by femoral head necrosis. *World J Clin Cases* 2023; 11(9): 1974-1984

URL: <https://www.wjgnet.com/2307-8960/full/v11/i9/1974.htm>

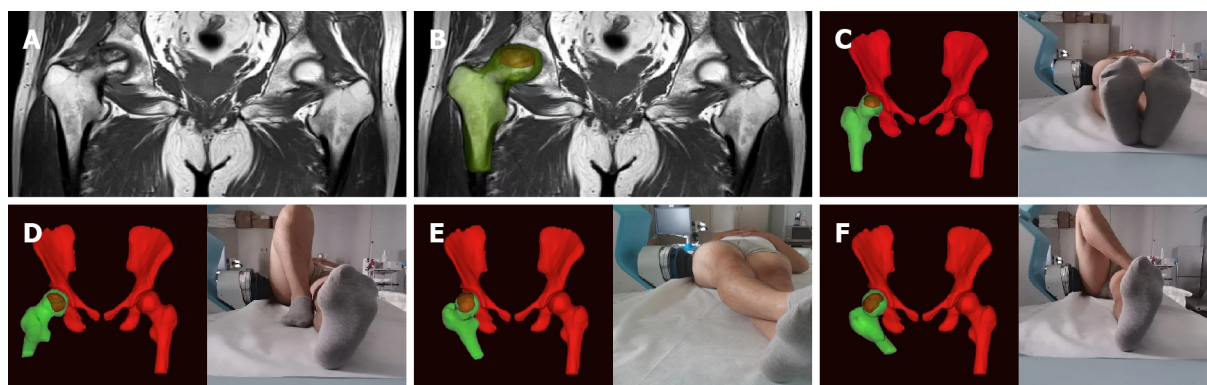
DOI: <https://dx.doi.org/10.12998/wjcc.v11.i9.1974>

INTRODUCTION

Osteonecrosis of the femoral head (ONFH) is a prevalent condition in orthopedic clinics, characterized by the gradual loss of bone cellularity and structure. Ischemia, necrosis, and collapse are characteristic pathological processes associated with ONFH[1,2]. The hip is one of the most important weight-bearing joints in the human body[3], and structural and pathological changes of this joint often lead to pain, dysfunction, and even disability[4]. Those suffering from ONFH are mostly young or middle-aged[5]. In the United States, more than 20000 individuals are afflicted by ONFH annually, and the prevalence continues to rise[6,7]. In China, it is estimated that more than 8 million individuals have suffered from ONFH[2].

Currently, the treatment of ONFH mainly includes the following: (1) Surgical treatment (artificial hip arthroplasty and drilling decompression); (2) Drug therapy [nonsteroidal anti-inflammatory drugs (NSAIDs) and alendronate]; (3) Physical therapies [extracorporeal shock wave therapy (ESWT) or high-pressure oxygen therapy]; and (4) Lifestyle changes (weight control and reduction of weight-bearing activities)[2,8,9]. Because of the limited life of the artificial joint in hip arthroplasty, the difficulties of secondary revision, the inadequate impact of hip preservation surgery, and considerable trauma, most patients prefer oral pharmacotherapy to alleviate symptoms[10]. The main goal of pharmacotherapy is to relieve hip pain and improve joint function. It has achieved some success in the management of ONFH, but long-term use of certain drugs is often accompanied by severe side effects[11-13]. Therefore, exploring a noninvasive treatment that can reduce side effects and replace traditional drug therapy is urgently needed. In treating ONFH, the biological effects of ESWT include analgesia, improvement of microcirculation, and promotion of osteocyte proliferation and differentiation[14-16]. A clinical study by Wang *et al*[17] in 2008 demonstrated that ESWT delays the progression of necrosis, alleviates hip joint pain, and promotes recovery of hip joint function.

In terms of analgesia and improving activity, ESWT avoids the side effects of drugs and dramatically decreases the trauma and economic burden associated with surgery[18,19]. However, the effects of ESWT often cannot be maximized due to acetabular obstruction during the transmission of shock wave



DOI: 10.12998/wjcc.v11.i9.1974 Copyright ©The Author(s) 2023.

Figure 1 Personalized extracorporeal shock wave therapy based on magnetic resonance imaging three-dimensional reconstruction. A: Magnetic resonance imaging (MRI) image; B: Three-dimensional (3D) reconstructed MRI images; C-F: Personalized posture + MRI-3D image + extracorporeal shock wave = personalized extracorporeal shock wave therapy.

energy and its attenuation in bone conduction[20-22]. Magnetic resonance imaging three-dimensional (MRI-3D) reconstruction to strengthen extracorporeal shock wave (ESW) targeting may be a reasonable solution for this issue[23]. Thus, the primary aim of this prospective, randomized study was to determine whether ESWT based on MRI-3D reconstruction was as effective as NSAIDs in improving pain and dysfunction associated with ONFH.

MATERIALS AND METHODS

Design and patients

This study was a prospective, double-blinded, non-inferiority randomized controlled trial designed per the principles of the Declaration of Helsinki. It was approved by the Ethics Committee of The Third Medical Center of Chinese People's Liberation Army General Hospital (ID: 001-R1) and registered on the Chinese Clinical Trial Registry (ChiCTR2100047844).

The study was conducted at the outpatient rehabilitation medicine department of The Third Medical Center of Chinese People's Liberation Army General Hospital. All consecutive subjects affected by ONFH associated with hip pain and dysfunction referred to the hospital from June 2021 to October 2021 were screened for inclusion in an outpatient rehabilitative setting. The recruitment procedure was performed by 2 specialists and included clinical examination of the affected hip, an MRI of the pelvis, an X-ray of the pelvis, and assessment of patient disease history and general condition.

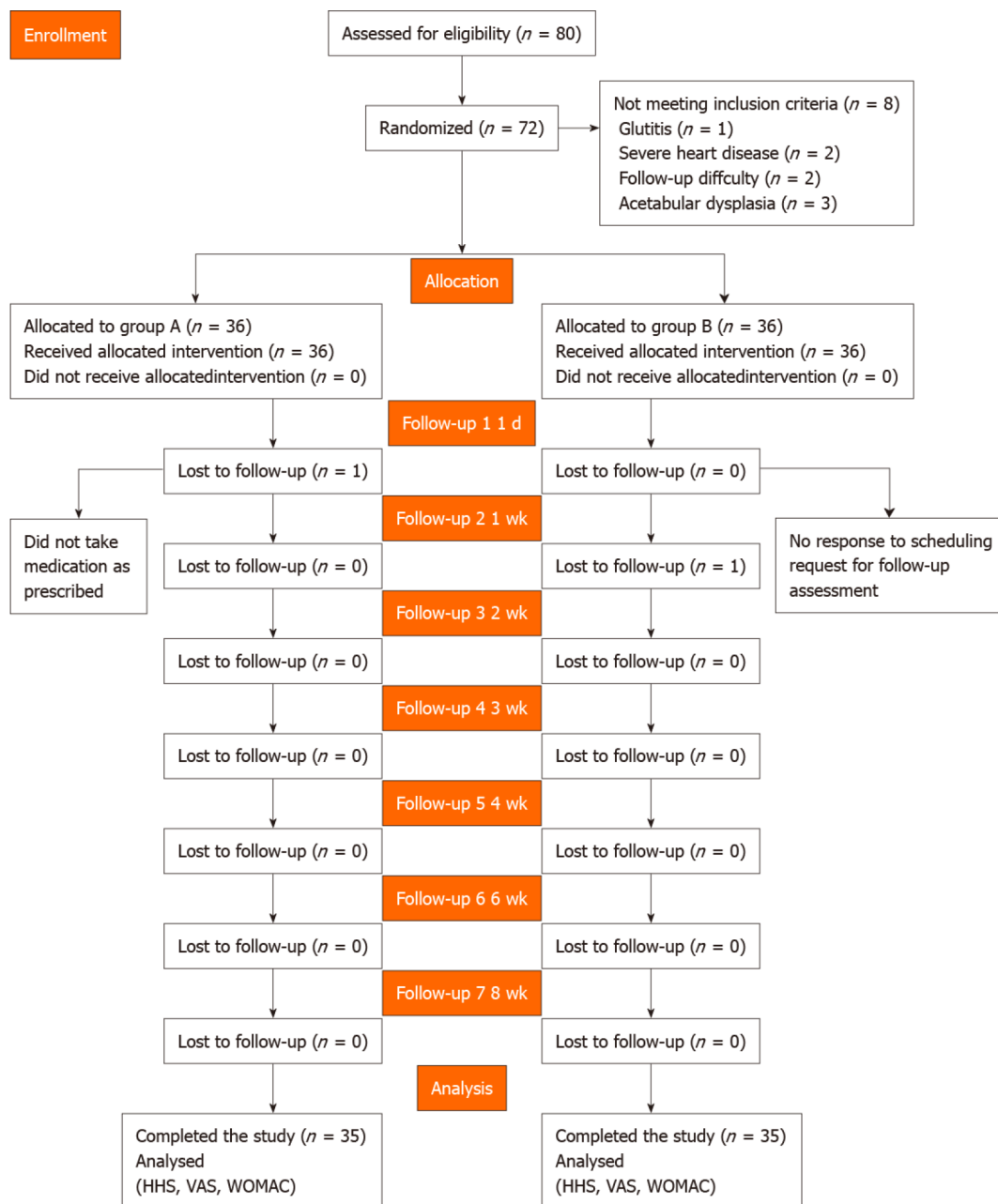
Eligibility criteria were as follows: (1) Adult age (18-75 years); (2) Diagnosed as ONFH and Association Research Circulation Osseous staging I-IV, confirmed with plain radiograph and MRI; (3) Patient unwillingness to accept surgical treatment and agreement not to use any other non-study treatment for hip pain during the study period; and (4) Voluntary participation in the clinical trial, compliance with the requirements of the trial, and signing of an informed consent form.

General contraindications to shock wave therapy were considered, including use of a pacemaker, pregnancy, bleeding disorder, anticoagulant drug use, or cancer in the focal area, and use of immunosuppressive agents. Patients with any of these contraindications were excluded.

Seventy-two patients were recruited and randomly divided into two groups. All participants provided written informed consent after a detailed understanding of the objectives and procedures of the study. The randomization was performed using the IWRS central random system (<https://iwrs.ymedical.net/#/projects/157/dashboard>), generating group A and group B. A flow diagram of the trial profile is shown in Figure 1.

Interventions

In group A, 200 mg celecoxib was used once daily for 9 consecutive days. Using sham focused ESWT, the protocol was the same as that used in group B, except that the energy level was a single grade (0.07 mJ/mm²) and no coupling gel was used on the treatment site. Instead, thick gauze was placed between the skin and the transmitter, with no energy applied. In group B, using personalized focused extracorporeal shockwave therapy (fESWT), the shock wave was generated by a focused shock wave generator (HK.SWT-007; Huikan AG, China) with a penetration depth between 0 and 70 mm and a focus diameter of 7.5 mm. All ESWT procedures were performed without general or regional anesthesia. First, raw MRI data from imaging of both hip joints (Digital Imaging and Communication in Medicine coronal T1-weighted MRI) were imported to the interactive medical imaging control system software (Mimics; Materialise Company, Leuven, Belgium). A three-dimensional (3D) view of the femoral head and its



DOI: 10.12998/wjcc.v11.i9.1974 Copyright ©The Author(s) 2023.

Figure 2 Study flow diagram. HHS: Harris hip score; VAS: Visual analog scale; WOMAC: Western Ontario and McMaster Universities Osteoarthritis Index.

necrotic area was obtained by image segmentation, visualization, registration, and other functions. The size and spatial location of the necrotic area were determined using the 3D perspective of the reconstructed necrotic area. The junctional zone between normal and necrotic bone within the femoral head was delineated under MRI-3D image guidance. Within the junctional zone, 2 or 3 points approximately 1.0 cm apart were chosen under MRI-3D imaging guidance and the corresponding locations were marked on the skin in the groin area. Next, physicians adjusted the treatment points according to personalized posture with the subjects in different lying positions. Furthermore, they placed the treatment head at the surface of the hip corresponding to the necrotic area (with avoidance of keep essential blood vessels and nerves) (Figure 2). Next, the water sac was adjusted to the appropriate position, and the proper amount of medical coupling agent was applied to the surface of the water in contact with the human body. Finally, when using 5-10 grade energy therapy (energy flow density: 0.20-0.6 mJ/mm²), the energy was increased from low to high according to the subject's sensitivity to pain. Simultaneously, to ensure exact targeting, the position was monitored throughout treatment, and the drift of the treatment point was adjusted in real-time.

The clinicians administering ESWT had extensive experience using this treatment to treat various musculoskeletal disorders. Each treatment cycle included 5 sessions with 1000 impulses per point, each administered at a frequency of 60 times per minute, at 48-72 h intervals.

During the trial, all the subjects were treated with basic treatment (70 mg oral alendronate sodium once per wk).

Outcome measurements

The primary outcome measure was treatment efficacy after the 2nd wk of treatment. Harris hip score (HHS) improved by 10 points after therapy, which was deemed sufficient. The secondary outcome measures [HHS, visual analog scale (VAS), and Western Ontario and McMaster Universities Osteoarthritis Index (WOMAC) scores] were improved on the 1st d and the 2nd, 4th, and 8th wk after treatment as compared to baseline. After completing therapy, pain recurrence was evaluated if the subject's VAS pain score was equal to or higher than baseline during the follow-up period. Each subject was instructed to record his or her VAS score at the following timepoints following therapy: day 1, week 1, week 2, week 3, week 4, week 6, and week 8.

Sample size

A sample size of 64 patients was computed given an alpha error of 5% (two-sided) and a power of 80%, assuming that the pain improvement rate of group A and group B was 65% and 85%, respectively, with a non-inferiority limit of -10%. Thus, non-inferiority would be demonstrated if the lower boundary of the 95%CI for the difference was higher than -10%. After considering the potential for patient dropout (estimated at 10%), the final sample was 72 patients (36 per group).

Randomization and blinding

Patients were randomized to group A or group B after providing written informed consent. Randomization was performed by a person not involved in the study, and a computer-generated list of random numbers was used. Patients and investigators were blinded to allocation. After intervention, results were recorded by a specialized physician. To maintain blinding, statistical analyses were conducted by independent statisticians, and results were not shared with the patients or other participants before the end of the study.

Statistical analysis

This experiment was a non-inferiority test. Statistical analysis was performed using Graphpad5.0 software (La Jolla, CA, United States). All statistical tests were bilateral, and $P < 0.05$ was considered statistically significant. Quantitative data were normally distributed by mean \pm SD, and the skewed distribution was described by median or interquartile range. A paired sample *t*-test was used to compare the mean change of each evaluation indicator between the pre-treatment and scheduled follow-up time points. Two-sample independent *t*-test or Wilcoxon rank-sum test was used to compare the groups. The classified data distribution was described by rate or composition ratio. The main curative effect used the normal approximation method, and the 95%CI of the rate difference between the two groups was compared with the non-inferiority boundary value of -10%.

Data availability

The datasets are available from the corresponding author upon reasonable request.

RESULTS

We examined 80 patients for study eligibility and 8 patients were excluded per inclusion and exclusion criteria. Seventy-two patients were randomized into two groups, which received treatment predefined for each group. All patients completed the designated interventions, which was monitored and reported at the end of the treatment period by physiotherapists. Two participants were lost to follow-up. All others were analyzed at each of the assessment points (Figure 1). There were no differences in age, sex, height, weight, BMI, or symptom duration between the groups ($P > 0.05$) (Table 1).

The findings of the Harris, VAS, and WOMAC score analyses were documented over the follow-up period (Table 2). The analysis found no statistical significance in the baseline data of the two groups of patients. With respect to the continuous changes in VAS, the downward trend in group B was faster than in group A (Figure 3).

The treatment efficacy observed in group A (18/35) and group B (24/35) were 51% and 69%, respectively (95%CI: -4.56% to 40.56%). The non-inferiority thresholds according to the primary outcome measure for group A and group B were -4.56% and -10%, respectively. In addition, the Harris, WOMAC, and VAS scores in group B were significantly improved at day 1, week 2, week 4, and week 8 following treatment (Table 2). In group A, the VAS and WOMAC scores were significantly improved at day 1, week 2, week 4, and week 8 following treatment ($P < 0.001$), while changes in HHS significant only at week 2 following treatment ($P < 0.001$). On day 1 and week 2 following treatment, HHS and VAS scores were significantly different between groups, with the difference in HHS lasting until week 4 (Table 2).

Table 1 Patient characteristics, mean \pm SD

Characteristic	Group A	Group B	P value
Patients, <i>n</i>	35	35	
Sex, male/female	26/10	18/17	
Age in yr	40.06 \pm 13.48	43.72 \pm 13.69	0.256 ¹
Weight in kg	71.82 \pm 11.02	67.79 \pm 10.93	0.124 ¹
Height in cm	171.6 \pm 7.71	168.4 \pm 8.22	0.099 ¹
BMI in kg/m ²	24.4 \pm 3.59	23.8 \pm 2.85	0.424 ¹
Pain duration in mo	14.8 \pm 7.99	13.7 \pm 7.89	0.564 ¹

¹Paired-samples *t*-test data are expressed as mean \pm SD or *n* (%).
Data were analyzed using unpaired *t*-test. BMI: Body mass index.

Table 2 Outcome assessment before and after treatment

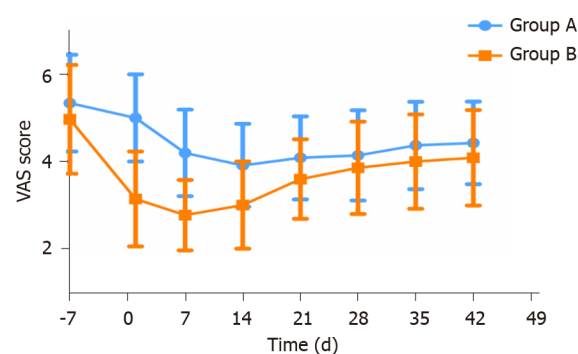
Parameter	Baseline	1 d	2 wk	4 wk	8 wk
Group A					
Patients, <i>n</i>	35	35	35	35	35
HHS range 0-100, mean \pm SD	51.8 \pm 11.8	51.8 \pm 11.6	57.9 \pm 12.5	52.9 \pm 11.5	52.7 \pm 11.2
Difference <i>vs</i> baseline		0.962 ¹	< 0.001 ¹	0.218 ¹	0.315 ¹
Difference <i>vs</i> group B		< 0.001 ²	0.004 ²	0.047 ²	0.147 ²
VAS (0-10), mean \pm SD	5.3 \pm 1.1	5.0 \pm 1.0	3.9 \pm 1.0	4.1 \pm 1.0	4.4 \pm 1.0
Difference <i>vs</i> baseline		0.003 ¹	< 0.001 ¹	< 0.001 ¹	< 0.001 ¹
Difference <i>vs</i> group B		< 0.001 ²	< 0.001 ²	0.257 ²	0.166 ²
WOMAC range 0-240, mean \pm SD	93.7 \pm 32.4	92.3 \pm 31.8	87.6 \pm 31.5	89.3 \pm 31.4	90.2 \pm 31.2
Difference <i>vs</i> baseline		0.022 ¹	< 0.001 ¹	< 0.001 ¹	< 0.001 ¹
Difference <i>vs</i> group B		0.196 ²	0.447 ²	0.596 ²	0.651 ²
Group B					
Patients, <i>n</i>	35	35	35	35	35
HHS range 0-100, mean \pm SD	53.9 \pm 13.3	62.4 \pm 11.6	62.9 \pm 12.1	58.5 \pm 12.0	56.9 \pm 12.9
Difference <i>vs</i> baseline		< 0.001 ¹	< 0.001 ¹	< 0.001 ¹	< 0.001 ¹
VAS range 0-10, mean \pm SD	5.0 \pm 1.2	3.1 \pm 1.1	3.0 \pm 1.0	3.9 \pm 1.1	4.1 \pm 1.1
Difference <i>vs</i> baseline		< 0.001 ¹	< 0.001 ¹	< 0.001 ¹	< 0.001 ¹
WOMAC range 0-240, mean \pm SD	91.0 \pm 25.1	83.5 \pm 23.9	82.5 \pm 24.0	86.0 \pm 24.3	87.1 \pm 24.7
Difference <i>vs</i> baseline		< 0.001 ¹	< 0.001 ¹	< 0.001 ¹	< 0.001 ¹

¹Paired-sample *t*-test.

²Two-sample independent *t*-test statistical significance at *P* < 0.05.

HHS: Harris hip score; VAS: Visual analog scale; WOMAC: Western Ontario and McMaster Universities Osteoarthritis Index.

Short-term side effects such as discomfort, edema, and bruising were similar in both groups. Heart rate, blood pressure, body temperature, and routine blood tests were unaffected by treatment. Patients from either group experienced no serious complication such as skin ulceration infection or lower extremity motor-sensory impairment.



DOI: 10.12998/wjcc.v11.i9.1974 Copyright ©The Author(s) 2023.

Figure 3 Changing trend of the visual analog scale in groups A and B. VAS: Visual analog scale.

DISCUSSION

This study demonstrated that fESWT can effectively and safely treat hip pain and functional restrictions associated with ONFH. The treatment efficacy observed in group B was significantly higher than that of group A. Moreover, most secondary outcomes, including composite scores and response criteria, showed improvements favoring the use of fESWT.

ONFH causes the collapse of the femoral head with severe pain and limited mobility[24]. Hip pain and functional limitations are the typical clinical manifestations of this condition[25]. Therefore, symptom alleviation and recovery of hip joint function are essential in determining the effectiveness of short-term treatment[†]. In this study, we proposed that individualized fESWT could be used for short-term symptomatic treatment of ONFH and it is as effective as NSAIDs (*e.g.*, celecoxib) with respect to analgesia and improvement of joint function[26]. After an 8-wk follow-up, we found that individualized fESWT was effective in alleviating hip joint pain and promoting recovery of hip joint function during short-term applications. The therapeutic effect peaked 1 wk after the intervention and was superior to celecoxib in both therapeutic and analgesic efficacy.

ONFH is more likely to occur in young and active patients as compared to osteoarthritis[4,27]. Therefore, most patients choose non-surgical treatments. In the short term, many non-operative treatments for ONFH are designed to relieve hip pain and improve joint function, while long-term treatments largely aim to prevent the progression of necrosis[28]. Recent studies recommend the use of osteoclast inhibitors and NSAIDs for symptomatic treatment[2,29]. In 2009, a nationwide cohort study conducted in Denmark showed that NSAIDs were associated with increased relative risks of cardiovascular events and death, even in the low-risk population[30]. At the same time, Singh *et al*[31] showed that NSAIDs had severe gastrointestinal toxicity, highlighting the significant adverse reactions associated with pharmacotherapy.

ESWT represents mechanical stimulation of the joint and has great potential in treating ONFH as it avoids the adverse effects of drug therapy. In 2 clinical studies, Wang *et al*[32] and Vulpiani *et al*[33] separately explored the long-term dose effects of ESWT in the treatment of ONFH. These studies demonstrated that ESWT could stimulate the growth of new bone at the site of necrosis and delay the progression of ONFH with long-term application[33]. Other studies have also indicated that ESWT might relieve pain by suppressing the release of inflammatory factors and downregulating the expression of pain-related, calcitonin gene-related peptides in dorsal root ganglion[34,35]. Additionally, it can directly act on peripheral sensory nerve endings, improving the pain threshold and preventing the production and propagation of pain signals[36]. These data suggest that ESWT may be useful as short-term, symptomatic supportive treatment in the management of ONFH.

To the best of our knowledge, this is the first investigation of the efficacy of ESWT in the short-term management of ONFH. Our results showed that the Harris, WOMAC, and VAS scores of group B improved significantly at day 1, week 2, week 4, and week 8 following treatment ($P < 0.001$). In group A, the VAS and WOMAC scores were significantly improved at week 2, week 4, and week 8 following treatment ($P < 0.001$), while Harris scores differed significantly only at week 2 ($P < 0.001$). These data suggest that both fESWT and celecoxib are effective in improving hip pain and promoting joint function in patients with ONFH. However, fESWT was superior to celecoxib in speed of onset and analgesic effect (a comparison of the two groups found significant differences in HHS and VAS at day 1 and week 2 following treatment, with the difference in HHS lasting until week 4). This finding suggests that, as compared to pharmacotherapy, ESWT avoids the lack of targeted treatment and limits bone marrow edema induced by early ONFH. During treatment, fESWT promotes blood circulation and reduces inflammation, thereby limiting pain associated with ONFH[14,37,38]. Treatment with traditional NSAIDs does not exhibit these features.

Additionally, based on our prior experience with ESWT, we noted that the acetabulum frequently blocks the incoming shock wave and reduces the therapeutic impact as a result of the uniqueness of hip joint anatomy. In a study of the energy decay of shock waves utilizing the femoral heads of pigs, ESW attenuated by 50% for every 10 mm of penetration into the femoral head[20]. Coupled with acetabular blocking, traditional ESWT often fails to maximize function[21]. Therefore, to reduce unnecessary energy attenuation in ESW transmission, our team designed an individual fESWT treatment for each patient according to MRI-3D reconstruction combined with posture adjustment (Figure 1). The 3D picture of the MRI, as opposed to the conventional X-ray localization, better reflected the spatial location and size of the necrotic area, increasing the accuracy of ESWT targeting and improving the curative impact. This supports the idea that MRI is the gold standard for diagnosing early stage ONFH, whereas X-ray and computed tomography less effective in diagnosing this condition[1,2,39].

Study limitations

Our study does have some limitations. Because the trial used a new treatment method (ESWT) based on MRI-3D reconstruction, we performed only a conservative non-inferiority test. Furthermore, due to ethical concerns and a lack of relevant pathology and other objective markers, the study could not investigate the exact causes of pain induced by ONFH. As a result, the lack of this objective evaluation may have led to bias in interpretation of the experimental results. Therefore, our goals in the next phase of study are optimization of the treatment regimen and exploration of the mechanism of ESWT to improve treatment of pain associated with ONFH. Finally, this study only included patients from a single medical center, and recruitment of subjects was somewhat limited.

CONCLUSION

Short-term ESWT based on MRI-3D reconstruction can relieve hip pain caused by ONFH, and is not inferior to celecoxib in terms of treatment efficacy and continuous analgesic effect. It also shows significant efficacy in improving the function of the hip joint, indicating that ESWT is a promising alternative for the short-term management of ONFH.

ARTICLE HIGHLIGHTS

Research background

Hip pain and functional joint limitations are the major symptoms associated with osteonecrosis of the femoral head (ONFH). The long-term use of nonsteroidal anti-inflammatory drugs (NSAIDs) such as celecoxib are often associated with severe adverse effects.

Research motivation

The motivation of this study was to explore a new treatment, extracorporeal shock wave therapy (ESWT) to replace pharmacotherapy in the treatment of ONFH.

Research objectives

This study investigated the efficacy of ESWT in improving pain and joint dysfunction associated with ONFH as compared to that of NSAID therapy.

Research methods

The eligible 72 ONFH patients were randomly assigned to two groups: the experiment group and the control group. All patients underwent clinical assessment and analysis during pre- and post-treatment periods.

Research results

The Harris hip score, Western Ontario and McMaster Universities Arthritis Index, and visual analog scale scores in both the experiment and control groups were significantly improved, but those of the experimental group improved to a greater degree.

Research conclusions

ESWT based on magnetic resonance imaging three-dimensional reconstruction was not inferior to celecoxib in controlling hip pain and function associated with ONFH.

Research perspectives

The findings of this study indicate that individual shock wave therapy represents an alternative to pharmacotherapy in effectively alleviating pain associated with ONFH.

ACKNOWLEDGEMENTS

We are grateful to the patients who participated in our study. We thank our research team, Geng-Yan Xing, Jun Yan, Hao-Jun Liang, Hai-Guan Jia, Li Tong, Jian Xiao, Fan Hu, Hao Li, and Fu-Jin Li, for their assistance with data collection and management, and the occupational therapists who provided the intervention.

FOOTNOTES

Author contributions: Xing GY designed this study; Yan J and Jia HG collected the data; Liang HJ analyzed the data; Zhu JY and Xiao J drafted the manuscript and gave final approval of the version to be published.

Institutional review board statement: The research protocol was approved by the Ethics Committee of The Third Medical Center of Chinese People's Liberation Army General Hospital (ID: 001-R1).

Clinical trial registration statement: This study was registered on the Chinese Clinical Trial Registry (ChiCTR2100047844).

Informed consent statement: Informed written consent was obtained from the patients to publish this report and any accompanying images.

Conflict-of-interest statement: The authors declare that they have no conflicts of interest.

Data sharing statement: The datasets used and/or analyzed in the current study are available from the corresponding author upon reasonable request.

CONSORT 2010 statement: The manuscript was prepared and revised according to the CONSORT 2010 statement.

Open-Access: This article is an open-access article that was selected by an in-house editor and fully peer-reviewed by external reviewers. It is distributed in accordance with the Creative Commons Attribution NonCommercial (CC BY-NC 4.0) license, which permits others to distribute, remix, adapt, build upon this work non-commercially, and license their derivative works on different terms, provided the original work is properly cited and the use is non-commercial. See: <https://creativecommons.org/licenses/by-nc/4.0/>

Country/Territory of origin: China

ORCID number: Jun-Yu Zhu 0000-0002-7826-2516; Hai-Guang Jia 0000-0003-4313-3586; Geng-Yan Xing 0000-0001-5412-9692.

S-Editor: Zhang H

L-Editor: Filipodia

P-Editor: Zhang H

REFERENCES

- 1 **Microsurgery Department of the Orthopedics Branch of the Chinese Medical Doctor Association;** Group from the Osteonecrosis and Bone Defect Branch of the Chinese Association of Reparative and Reconstructive Surgery; Microsurgery and Reconstructive Surgery Group of the Orthopedics Branch of the Chinese Medical Association. Chinese Guideline for the Diagnosis and Treatment of Osteonecrosis of the Femoral Head in Adults. *Orthop Surg* 2017; **9**: 3-12 [PMID: 28371498 DOI: 10.1111/os.12302]
- 2 **Zhao D,** Zhang F, Wang B, Liu B, Li L, Kim SY, Goodman SB, Hernigou P, Cui Q, Lineaweaver WC, Xu J, Drescher WR, Qin L. Guidelines for clinical diagnosis and treatment of osteonecrosis of the femoral head in adults (2019 version). *J Orthop Translat* 2020; **21**: 100-110 [PMID: 32309135 DOI: 10.1016/j.jot.2019.12.004]
- 3 **Li Z,** Zhuang Z, Hong Z, Chen L, He W, Wei Q. Avascular necrosis after femoral neck fracture in children and adolescents: poor prognosis and risk factors. *Int Orthop* 2021; **45**: 2899-2907 [PMID: 34549321 DOI: 10.1007/s00264-021-05210-2]
- 4 **Hauzeur JP,** Malaise M, de Maertelaer V. A prospective cohort study of the clinical presentation of non-traumatic osteonecrosis of the femoral head: spine and knee symptoms as clinical presentation of hip osteonecrosis. *Int Orthop* 2016; **40**: 1347-1351 [PMID: 26728612 DOI: 10.1007/s00264-015-3079-x]
- 5 **Yoon BH,** Jones LC, Chen CH, Cheng EY, Cui Q, Drescher W, Fukushima W, Gangji V, Goodman SB, Ha YC, Hernigou P, Hungerford M, Iorio R, Jo WL, Khanduja V, Kim H, Kim SY, Kim TY, Lee HY, Lee MS, Lee YK, Lee YJ, Mont MA, Sakai T, Sugano N, Takao M, Yamamoto T, Koo KH. Etiologic Classification Criteria of ARCO on Femoral Head Osteonecrosis Part 1: Glucocorticoid-Associated Osteonecrosis. *J Arthroplasty* 2019; **34**: 163-168.e1 [PMID: 30348552 DOI: 10.1016/j.arth.2018.09.005]
- 6 **Hungerford DS.** Osteonecrosis: avoiding total hip arthroplasty. *J Arthroplasty* 2002; **17**: 121-124 [PMID: 12068421 DOI: 10.1054/arth.2002.33300]

- 7 **Mont MA**, Salem HS, Piuze NS, Goodman SB, Jones LC. Nontraumatic Osteonecrosis of the Femoral Head: Where Do We Stand Today? *J Bone Joint Surg Am* 2020; **102**: 1084-1099 [PMID: [32282421](#) DOI: [10.2106/JBJS.19.01271](#)]
- 8 **Puljak L**, Marin A, Vrdoljak D, Markotic F, Utrobicic A, Tugwell P. Celecoxib for osteoarthritis. *Cochrane Database Syst Rev* 2017; **5**: CD009865 [PMID: [28530031](#) DOI: [10.1002/14651858.CD009865.pub2](#)]
- 9 **Lai KA**, Shen WJ, Yang CY, Shao CJ, Hsu JT, Lin RM. The use of alendronate to prevent early collapse of the femoral head in patients with nontraumatic osteonecrosis. A randomized clinical study. *J Bone Joint Surg Am* 2005; **87**: 2155-2159 [PMID: [16203877](#) DOI: [10.2106/JBJS.D.02959](#)]
- 10 **Tsukanaka M**, Halvorsen V, Nordsletten L, Engesaeter IØ, Engesaeter LB, Marie Fenstad A, Röhrli SM. Implant survival and radiographic outcome of total hip replacement in patients less than 20 years old. *Acta Orthop* 2016; **87**: 479-484 [PMID: [27435903](#) DOI: [10.1080/17453674.2016.1212180](#)]
- 11 **Dahlberg LE**, Holme I, Høye K, Ringertz B. A randomized, multicentre, double-blind, parallel-group study to assess the adverse event-related discontinuation rate with celecoxib and diclofenac in elderly patients with osteoarthritis. *Scand J Rheumatol* 2009; **38**: 133-143 [PMID: [19165648](#) DOI: [10.1080/03009740802419065](#)]
- 12 **Mallen SR**, Essex MN, Zhang R. Gastrointestinal tolerability of NSAIDs in elderly patients: a pooled analysis of 21 randomized clinical trials with celecoxib and nonselective NSAIDs. *Curr Med Res Opin* 2011; **27**: 1359-1366 [PMID: [21561397](#) DOI: [10.1185/03007995.2011.581274](#)]
- 13 **Moore RA**, Derry S, Makinson GT, McQuay HJ. Tolerability and adverse events in clinical trials of celecoxib in osteoarthritis and rheumatoid arthritis: systematic review and meta-analysis of information from company clinical trial reports. *Arthritis Res Ther* 2005; **7**: R644-R665 [PMID: [15899051](#) DOI: [10.1186/ar1704](#)]
- 14 **Sung PH**, Yin TC, Chai HT, Chiang JY, Chen CH, Huang CR, Yip HK. Extracorporeal Shock Wave Therapy Salvages Critical Limb Ischemia in B6 Mice through Upregulating Cell Proliferation Signaling and Angiogenesis. *Biomedicines* 2022; **10** [PMID: [35052796](#) DOI: [10.3390/biomedicines10010117](#)]
- 15 **Li B**, Wang R, Huang X, Ou Y, Jia Z, Lin S, Zhang Y, Xia H, Chen B. Extracorporeal Shock Wave Therapy Promotes Osteogenic Differentiation in a Rabbit Osteoporosis Model. *Front Endocrinol (Lausanne)* 2021; **12**: 627718 [PMID: [33841330](#) DOI: [10.3389/fendo.2021.627718](#)]
- 16 **Alshihri A**, Niu W, Kämmerer PW, Al-Askar M, Yamashita A, Kurisawa M, Spector M. The effects of shock wave stimulation of mesenchymal stem cells on proliferation, migration, and differentiation in an injectable gelatin matrix for osteogenic regeneration. *J Tissue Eng Regen Med* 2020; **14**: 1630-1640 [PMID: [32885906](#) DOI: [10.1002/term.3126](#)]
- 17 **Wang CJ**, Wang FS, Yang KD, Huang CC, Lee MS, Chan YS, Wang JW, Ko JY. Treatment of osteonecrosis of the hip: comparison of extracorporeal shockwave with shockwave and alendronate. *Arch Orthop Trauma Surg* 2008; **128**: 901-908 [PMID: [18060419](#) DOI: [10.1007/s00402-007-0530-5](#)]
- 18 **Wang CJ**, Huang CC, Wang JW, Wong T, Yang YJ. Long-term results of extracorporeal shockwave therapy and core decompression in osteonecrosis of the femoral head with eight- to nine-year follow-up. *Biomed J* 2012; **35**: 481-485 [PMID: [23442361](#) DOI: [10.4103/2319-4170.104413](#)]
- 19 **Ludwig J**, Lauber S, Lauber HJ, Dreisilker U, Raedel R, Hotzinger H. High-energy shock wave treatment of femoral head necrosis in adults. *Clin Orthop Relat Res* 2001; **388**: 119-126 [PMID: [11400872](#) DOI: [10.1097/00003086-200106000-00016](#)]
- 20 **Hausdorf J**, Lutz A, Mayer-Wagner S, Birkenmaier C, Jansson V, Maier M. Shock wave therapy for femoral head necrosis-Pressure measurements inside the femoral head. *J Biomech* 2010; **43**: 2065-2069 [PMID: [20451206](#) DOI: [10.1016/j.jbiomech.2010.04.009](#)]
- 21 **Tsutsumi M**, Nimura A, Akita K. New insight into the iliofemoral ligament based on the anatomical study of the hip joint capsule. *J Anat* 2020; **236**: 946-953 [PMID: [31867743](#) DOI: [10.1111/joa.13140](#)]
- 22 **Tsutsumi M**, Yamaguchi I, Nimura A, Utsunomiya H, Akita K, Kudo S. In vivo magnetic resonance imaging study of the hip joint capsule in the flexion abduction external rotation position. *Sci Rep* 2022; **12**: 6656 [PMID: [35459931](#) DOI: [10.1038/s41598-022-10718-7](#)]
- 23 **Derry S**, Moore RA. Single dose oral celecoxib for acute postoperative pain in adults. *Cochrane Database Syst Rev* 2013; **2013**: CD004233 [PMID: [24150982](#) DOI: [10.1002/14651858.CD004233.pub4](#)]
- 24 **Ikeuchi K**, Hasegawa Y, Seki T, Takegami Y, Amano T, Ishiguro N. Epidemiology of nontraumatic osteonecrosis of the femoral head in Japan. *Mod Rheumatol* 2015; **25**: 278-281 [PMID: [25036228](#) DOI: [10.3109/14397595.2014.932038](#)]
- 25 **Wang P**, Wang C, Meng H, Liu G, Li H, Gao J, Tian H, Peng J. The Role of Structural Deterioration and Biomechanical Changes of the Necrotic Lesion in Collapse Mechanism of Osteonecrosis of the Femoral Head. *Orthop Surg* 2022; **14**: 831-839 [PMID: [35445585](#) DOI: [10.1111/os.13277](#)]
- 26 **Luan S**, Wang S, Lin C, Fan S, Liu C, Ma C, Wu S. Comparisons of Ultrasound-Guided Platelet-Rich Plasma Intra-Articular Injection and Extracorporeal Shock Wave Therapy in Treating ARCO I-III Symptomatic Non-Traumatic Femoral Head Necrosis: A Randomized Controlled Clinical Trial. *J Pain Res* 2022; **15**: 341-354 [PMID: [35153512](#) DOI: [10.2147/JPR.S347961](#)]
- 27 **Seki T**, Hasegawa Y, Masui T, Yamaguchi J, Kanoh T, Ishiguro N, Kawabe K. Quality of life following femoral osteotomy and total hip arthroplasty for nontraumatic osteonecrosis of the femoral head. *J Orthop Sci* 2008; **13**: 116-121 [PMID: [18392915](#) DOI: [10.1007/s00776-007-1208-0](#)]
- 28 **Petek D**, Hannouche D, Suva D. Osteonecrosis of the femoral head: pathophysiology and current concepts of treatment. *EFORT Open Rev* 2019; **4**: 85-97 [PMID: [30993010](#) DOI: [10.1302/2058-5241.4.180036](#)]
- 29 **Luyten FP**, Geusens P, Malaise M, De Clerck L, Westhovens R, Raeman F, Vander Mijnsbrugge D, Mathy L, Hauzeur JP, De Keyser F, Van den Bosch F. A prospective randomised multicentre study comparing continuous and intermittent treatment with celecoxib in patients with osteoarthritis of the knee or hip. *Ann Rheum Dis* 2007; **66**: 99-106 [PMID: [16815864](#) DOI: [10.1136/ard.2006.052308](#)]
- 30 **Fosbol EL**, Gislason GH, Jacobsen S, Folke F, Hansen ML, Schramm TK, Sørensen R, Rasmussen JN, Andersen SS, Abildstrom SZ, Traerup J, Poulsen HE, Rasmussen S, Køber L, Torp-Pedersen C. Risk of myocardial infarction and death associated with the use of nonsteroidal anti-inflammatory drugs (NSAIDs) among healthy individuals: a nationwide cohort study. *Clin Pharmacol Ther* 2009; **85**: 190-197 [PMID: [18987620](#) DOI: [10.1038/clpt.2008.204](#)]
- 31 **Singh G**. Recent considerations in nonsteroidal anti-inflammatory drug gastropathy. *Am J Med* 1998; **105**: 31S-38S

- [PMID: 9715832 DOI: 10.1016/S0002-9343(98)00072-2]
- 32 **Wang CJ**, Huang CC, Yip HK, Yang YJ. Dosage effects of extracorporeal shockwave therapy in early hip necrosis. *Int J Surg* 2016; **35**: 179-186 [PMID: 27664561 DOI: 10.1016/j.ijssu.2016.09.013]
 - 33 **Vulpiani MC**, Vetrano M, Trischitta D, Scarcello L, Chizzi F, Argento G, Saraceni VM, Maffulli N, Ferretti A. Extracorporeal shock wave therapy in early osteonecrosis of the femoral head: prospective clinical study with long-term follow-up. *Arch Orthop Trauma Surg* 2012; **132**: 499-508 [PMID: 22228278 DOI: 10.1007/s00402-011-1444-9]
 - 34 **Murata R**, Nakagawa K, Ohtori S, Ochiai N, Arai M, Saisu T, Sasho T, Takahashi K, Moriya H. The effects of radial shock waves on gene transfer in rabbit chondrocytes in vitro. *Osteoarthritis Cartilage* 2007; **15**: 1275-1282 [PMID: 17537650 DOI: 10.1016/j.joca.2007.04.001]
 - 35 **Hausdorf J**, Lemmens MA, Kaplan S, Marangoz C, Milz S, Odaci E, Korr H, Schmitz C, Maier M. Extracorporeal shockwave application to the distal femur of rabbits diminishes the number of neurons immunoreactive for substance P in dorsal root ganglia L5. *Brain Res* 2008; **1207**: 96-101 [PMID: 18371941 DOI: 10.1016/j.brainres.2008.02.013]
 - 36 **Takahashi N**, Ohtori S, Saisu T, Moriya H, Wada Y. Second application of low-energy shock waves has a cumulative effect on free nerve endings. *Clin Orthop Relat Res* 2006; **443**: 315-319 [PMID: 16462457 DOI: 10.1097/01.blo.0000188064.56091.a7]
 - 37 **Zhao W**, Gao Y, Zhang S, Liu Z, He L, Zhang D, Li W, Meng Q. Extracorporeal shock wave therapy for bone marrow edema syndrome in patients with osteonecrosis of the femoral head: a retrospective cohort study. *J Orthop Surg Res* 2021; **16**: 21 [PMID: 33413520 DOI: 10.1186/s13018-020-02159-7]
 - 38 **Sukubo NG**, Tibalt E, Respizzi S, Locati M, d'Agostino MC. Effect of shock waves on macrophages: A possible role in tissue regeneration and remodeling. *Int J Surg* 2015; **24**: 124-130 [PMID: 26291028 DOI: 10.1016/j.ijssu.2015.07.719]
 - 39 **Hopkins C**, Genant HK. Editorial for Guidelines for clinical diagnosis and treatment of osteonecrosis of the femoral head in adults (2019 version). *J Orthop Translat* 2020; **21**: A1 [PMID: 32309141 DOI: 10.1016/j.jot.2020.01.009]



Published by **Baishideng Publishing Group Inc**
7041 Koll Center Parkway, Suite 160, Pleasanton, CA 94566, USA

Telephone: +1-925-3991568

E-mail: bpgoffice@wjgnet.com

Help Desk: <https://www.f6publishing.com/helpdesk>

<https://www.wjgnet.com>

