

World Journal of *Clinical Cases*

World J Clin Cases 2023 March 26; 11(9): 1888-2122



Contents

Thrice Monthly Volume 11 Number 9 March 26, 2023

REVIEW

- 1888 Endoscopic transluminal drainage and necrosectomy for infected necrotizing pancreatitis: Progress and challenges
Zeng Y, Yang J, Zhang JW

MINIREVIEWS

- 1903 Functional role of frontal electroencephalogram alpha asymmetry in the resting state in patients with depression: A review
Xie YH, Zhang YM, Fan FF, Song XY, Liu L
- 1918 COVID-19 related liver injuries in pregnancy
Sekulovski M, Bogdanova-Petrova S, Peshevska-Sekulovska M, Velikova T, Georgiev T
- 1930 Examined lymph node count for gastric cancer patients after curative surgery
Zeng Y, Chen LC, Ye ZS, Deng JY
- 1939 Laparoscopic common bile duct exploration to treat choledocholithiasis in situs inversus patients: A technical review
Chiu BY, Chuang SH, Chuang SC, Kuo KK
- 1951 Airway ultrasound for patients anticipated to have a difficult airway: Perspective for personalized medicine
Nakazawa H, Uzawa K, Tokumine J, Lefor AK, Motoyasu A, Yorozu T

ORIGINAL ARTICLE

Observational Study

- 1963 Clinicopathological features and expression of regulatory mechanism of the Wnt signaling pathway in colorectal sessile serrated adenomas/polyps with different syndrome types
Qiao D, Liu XY, Zheng L, Zhang YL, Que RY, Ge BJ, Cao HY, Dai YC

Randomized Controlled Trial

- 1974 Effects of individual shock wave therapy *vs* celecoxib on hip pain caused by femoral head necrosis
Zhu JY, Yan J, Xiao J, Jia HG, Liang HJ, Xing GY

CASE REPORT

- 1985 Very low calorie ketogenic diet and common rheumatic disorders: A case report
Rondanelli M, Patelli Z, Gasparri C, Mansueto F, Ferraris C, Nichetti M, Alalwan TA, Sajoux I, Maugeri R, Perna S
- 1992 Delayed versus immediate intervention of ruptured brain arteriovenous malformations: A case report
Bintang AK, Bahar A, Akbar M, Soraya GV, Gunawan A, Hammado N, Rachman ME, Ulhaq ZS

- 2002** Children with infectious pneumonia caused by *Ralstonia insidiosa*: A case report
Lin SZ, Qian MJ, Wang YW, Chen QD, Wang WQ, Li JY, Yang RT, Wang XY, Mu CY, Jiang K
- 2009** Transient ischemic attack induced by pulmonary arteriovenous fistula in a child: A case report
Zheng J, Wu QY, Zeng X, Zhang DF
- 2015** Motor cortex transcranial magnetic stimulation to reduce intractable postherpetic neuralgia with poor response to other therapies: Report of two cases
Wang H, Hu YZ, Che XW, Yu L
- 2021** Small bowel adenocarcinoma in neoterminal ileum in setting of stricturing Crohn's disease: A case report and review of literature
Karthikeyan S, Shen J, Keyashian K, Gubatan J
- 2029** Novel combined endoscopic and laparoscopic surgery for advanced T2 gastric cancer: Two case reports
Dai JH, Qian F, Chen L, Xu SL, Feng XF, Wu HB, Chen Y, Peng ZH, Yu PW, Peng GY
- 2036** Acromicric dysplasia caused by a mutation of fibrillin 1 in a family: A case report
Shen R, Feng JH, Yang SP
- 2043** Ultrasound-guided intra-articular corticosteroid injection in a patient with manubriosternal joint involvement of ankylosing spondylitis: A case report
Choi MH, Yoon IY, Kim WJ
- 2051** Granulomatous prostatitis after bacille Calmette-Guérin instillation resembles prostate carcinoma: A case report and review of the literature
Yao Y, Ji JJ, Wang HY, Sun LJ, Zhang GM
- 2060** Unusual capitate fracture with dorsal shearing pattern and concomitant carpometacarpal dislocation with a 6-year follow-up: A case report
Lai CC, Fang HW, Chang CH, Pao JL, Chang CC, Chen YJ
- 2067** Live births from *in vitro* fertilization-embryo transfer following the administration of gonadotropin-releasing hormone agonist without gonadotropins: Two case reports
Li M, Su P, Zhou LM
- 2074** Spontaneous conus infarction with "snake-eye appearance" on magnetic resonance imaging: A case report and literature review
Zhang QY, Xu LY, Wang ML, Cao H, Ji XF
- 2084** Transseptal approach for catheter ablation of left-sided accessory pathways in children with Marfan syndrome: A case report
Dong ZY, Shao W, Yuan Y, Lin L, Yu X, Cui L, Zhen Z, Gao L
- 2091** Occipital artery bypass importance in unsuitable superficial temporal artery: Two case reports
Hong JH, Jung SC, Ryu HS, Kim TS, Joo SP

- 2098** Anesthetic management of a patient with preoperative R-on-T phenomenon undergoing laparoscopic-assisted sigmoid colon resection: A case report
Li XX, Yao YF, Tan HY
- 2104** Pembrolizumab combined with axitinib in the treatment of skin metastasis of renal clear cell carcinoma to nasal ala: A case report
Dong S, Xu YC, Zhang YC, Xia JX, Mou Y
- 2110** Successful treatment of a rare subcutaneous emphysema after a blow-out fracture surgery using needle aspiration: A case report
Nam HJ, Wee SY

LETTER TO THE EDITOR

- 2116** Are biopsies during endoscopic ultrasonography necessary for a suspected esophageal leiomyoma? Is laparoscopy always feasible?
Beji H, Chtourou MF, Zribi S, Kallel Y, Bouassida M, Touinsi H
- 2119** Vaginal microbes confounders and implications on women's health
Nori W, H-Hameed B

ABOUT COVER

Editorial Board Member of *World Journal of Clinical Cases*, Marilia Carabotti, MD, PhD, Academic Research, Medical-Surgical Department of Clinical Sciences and Translational Medicine, University Sapienza Rome, Rome 00189, Italy. mariliacarabotti@gmail.com

AIMS AND SCOPE

The primary aim of *World Journal of Clinical Cases* (WJCC, *World J Clin Cases*) is to provide scholars and readers from various fields of clinical medicine with a platform to publish high-quality clinical research articles and communicate their research findings online.

WJCC mainly publishes articles reporting research results and findings obtained in the field of clinical medicine and covering a wide range of topics, including case control studies, retrospective cohort studies, retrospective studies, clinical trials studies, observational studies, prospective studies, randomized controlled trials, randomized clinical trials, systematic reviews, meta-analysis, and case reports.

INDEXING/ABSTRACTING

The WJCC is now abstracted and indexed in Science Citation Index Expanded (SCIE, also known as SciSearch®), Journal Citation Reports/Science Edition, Current Contents®/Clinical Medicine, PubMed, PubMed Central, Scopus, Reference Citation Analysis, China National Knowledge Infrastructure, China Science and Technology Journal Database, and Superstar Journals Database. The 2022 Edition of Journal Citation Reports® cites the 2021 impact factor (IF) for WJCC as 1.534; IF without journal self cites: 1.491; 5-year IF: 1.599; Journal Citation Indicator: 0.28; Ranking: 135 among 172 journals in medicine, general and internal; and Quartile category: Q4. The WJCC's CiteScore for 2021 is 1.2 and Scopus CiteScore rank 2021: General Medicine is 443/826.

RESPONSIBLE EDITORS FOR THIS ISSUE

Production Editor: *Ying-Yi Yuan*; Production Department Director: *Xiang Li*; Editorial Office Director: *Jin-Lei Wang*.

NAME OF JOURNAL

World Journal of Clinical Cases

ISSN

ISSN 2307-8960 (online)

LAUNCH DATE

April 16, 2013

FREQUENCY

Thrice Monthly

EDITORS-IN-CHIEF

Bao-Gan Peng, Jerzy Tadeusz Chudek, George Kontogeorgos, Maurizio Serati, Ja Hyeon Ku

EDITORIAL BOARD MEMBERS

<https://www.wjnet.com/2307-8960/editorialboard.htm>

PUBLICATION DATE

March 26, 2023

COPYRIGHT

© 2023 Baishideng Publishing Group Inc

INSTRUCTIONS TO AUTHORS

<https://www.wjnet.com/bpg/gerinfo/204>

GUIDELINES FOR ETHICS DOCUMENTS

<https://www.wjnet.com/bpg/GerInfo/287>

GUIDELINES FOR NON-NATIVE SPEAKERS OF ENGLISH

<https://www.wjnet.com/bpg/gerinfo/240>

PUBLICATION ETHICS

<https://www.wjnet.com/bpg/GerInfo/288>

PUBLICATION MISCONDUCT

<https://www.wjnet.com/bpg/gerinfo/208>

ARTICLE PROCESSING CHARGE

<https://www.wjnet.com/bpg/gerinfo/242>

STEPS FOR SUBMITTING MANUSCRIPTS

<https://www.wjnet.com/bpg/GerInfo/239>

ONLINE SUBMISSION

<https://www.f6publishing.com>



Children with infectious pneumonia caused by *Ralstonia insidiosa*: A case report

Shuang-Zhu Lin, Mei-Jia Qian, Yan-Wei Wang, Qian-Dui Chen, Wan-Qi Wang, Jia-Yi Li, Rui-Tong Yang, Xin-Yao Wang, Chun-Yu Mu, Kai Jiang

Specialty type: Medicine, research and experimental

Provenance and peer review:

Unsolicited article; Externally peer reviewed.

Peer-review model: Single blind

Peer-review report's scientific quality classification

Grade A (Excellent): 0
Grade B (Very good): 0
Grade C (Good): C
Grade D (Fair): 0
Grade E (Poor): E

P-Reviewer: Chiu H, Taiwan;
Karunanayake A, Sri Lanka

Received: November 8, 2022

Peer-review started: November 8, 2022

First decision: November 25, 2022

Revised: December 2, 2022

Accepted: February 21, 2023

Article in press: February 21, 2023

Published online: March 26, 2023



Shuang-Zhu Lin, Mei-Jia Qian, Kai Jiang, Diagnosis and Treatment Center for Children, Affiliated Hospital of Changchun University of Chinese Medicine, Changchun 130021, Jilin Province, China

Yan-Wei Wang, Department of Imaging, Affiliated Hospital of Changchun University of Chinese Medicine, Changchun 130021, Jilin Province, China

Qian-Dui Chen, Rui-Tong Yang, Xin-Yao Wang, College of Integrated Chinese and Western Medicine, Changchun University of Chinese Medicine, Changchun 130117, Jilin Province, China

Wan-Qi Wang, Jia-Yi Li, Chun-Yu Mu, College of Traditional Chinese Medicine, Changchun University of Chinese Medicine, Changchun 130117, Jilin Province, China

Corresponding author: Kai Jiang, MD, Chief Physician, Professor, Diagnosis and Treatment Center for Children, Affiliated Hospital of Changchun University of Chinese Medicine, No. 1478 Gongnong Road, Chaoyang District, Changchun 130021, Jilin Province, China. 2835221172@qq.com

Abstract

BACKGROUND

Ralstonia is a Gram-negative non-fermentative bacterium widespread in nature, and includes four species, *Ralstonia pickettii*, *Ralstonia solanacearum*, *Ralstonia mannitolilytica*, and *Ralstonia insidiosa*, which were proposed in 2003. *Ralstonia* is mainly found in the external water environment, including municipal and medical water purification systems. This bacterium has low toxicity and is a conditional pathogen. It has been reported in recent years that infections due to *Ralstonia* are increasing. Previous studies have shown that most cases of infection are caused by *Ralstonia pickettii*, a few by *Ralstonia mannitolilytica*, and infections caused by *Ralstonia insidiosa* are rare.

CASE SUMMARY

A 2-year-old Chinese child suffered from intermittent fever and cough for 20 d and was admitted to hospital with bronchial pneumonia. Bronchoscopy and alveolar lavage fluid culture confirmed *Ralstonia insidiosa* pneumonia. The infection was well controlled after treatment with meropenem and azithromycin.

CONCLUSION

Ralstonia infections are increasing, and we report a rare case of *Ralstonia insidiosa* infection in a child. Clinicians should be vigilant about *Ralstonia* infections.

Key Words: Children; Infections; *Ralstonia insidiosa*; Pneumonia; Treatment; Case report

©The Author(s) 2023. Published by Baishideng Publishing Group Inc. All rights reserved.

Core Tip: *Ralstonia* is a rare type of conditionally pathogenic bacterium found in nature, and its infection incidents have been increasing in recent years. We describe a 2-year-old male baby, who was diagnosed with *Ralstonia insidiosa* infection after culture of alveolar lavage fluid. The infection was controlled with a combination of two antibiotics. Our report adds to the case reports of rare *Ralstonia insidiosa* infections and warns doctors to be aware of this rare infection.

Citation: Lin SZ, Qian MJ, Wang YW, Chen QD, Wang WQ, Li JY, Yang RT, Wang XY, Mu CY, Jiang K. Children with infectious pneumonia caused by *Ralstonia insidiosa*: A case report. *World J Clin Cases* 2023; 11(9): 2002-2008

URL: <https://www.wjgnet.com/2307-8960/full/v11/i9/2002.htm>

DOI: <https://dx.doi.org/10.12998/wjcc.v11.i9.2002>

INTRODUCTION

Ralstonia is a non-fermentative species widespread in nature, it is a Gram-negative bacterium, which was first isolated in 1973 and incorporated into *Burkholderia* (*Burkholderia pickettii* and *Burkholderia solanacearum*). The genus *Ralstonia* was named separately in 1995 by Yabuuchi *et al*[1], and it includes *Ralstonia pickettii*, *Ralstonia solanacearum*, *Ralstonia mannitolilytica*, and *Ralstonia insidiosa*, which were newly introduced in 2003[2]. *Ralstonia* reproduces in wet conditions and can survive long-term in harsh environments, mainly in external water environments, including municipal water and medical water purification systems[3,4]. Previous reports indicated that the bacterium was less virulent and was an opportunistic pathogen. However, human infections with *Ralstonia* without exposure to a contaminated solution are rare, thus the bacterium was not considered a major pathogen[5].

However, the incidence of *Ralstonia* infection is increasing in recent years. Previous studies have shown that most cases of infection are caused by *Ralstonia pickettii*, and a few by *Ralstonia mannitolilytica*; these pathogens can cause bloodstream infections, pneumonia, prostatitis, and many other diseases[6]. *Ralstonia pickettii*, has been isolated from various clinical specimens, such as sputum, blood, infected wounds, urine, ears, nasal swabs, and cerebrospinal fluid[5].

Ralstonia insidiosa is a new species proposed in 2003[7], which is closest to *Ralstonia pickettii*, and it has been reported to be isolated from the respiratory tract of patients with cystic fibrosis. In addition, *Ralstonia insidiosa* has been detected in water distribution and laboratory-purified water systems[8]. However, due to the low incidence of this bacterium infection and insufficient clinical awareness, reports of *Ralstonia insidiosa* infection are infrequent.

CASE PRESENTATION

Chief complaints

A boy aged 2 years and 6 mo presented with intermittent fever and cough for 20 d and attended hospital on January 27, 2019.

History of present illness

The child had a fever without apparent cause which started 20 d previously. His fever was persistent, with yellow-colored sputum but no blood-stained sputum. The clinical diagnosis was bronchial pneumonia, and azithromycin, erythromycin and other drugs were administered for 19 d, and the effect was not satisfactory. On admission, the child still had a fever, and cough with sputum.

History of past illness

The child had previously been physically fit. Family members denied contact with contaminated water in the endemic area or history of surgery and invasive procedures.

Personal and family history

The child was gravida 1, para 1, delivered by cesarean section at term, and had no history of related infections, infectious diseases, or history of genetic diseases in the family.

Physical examination

The child's weight was 16 kg, height 91 cm, admission temperature 39.6 °C, pulse rate 120 bpm, and respiratory rate 28 breaths/min. He had good nutritional status, normal development, no rash on the skin or mucous membranes throughout the body, no pharyngeal hyperemia, and no enlargement and purulent discharge of tonsils, and superficial lymph nodes in the entire body were not palpable. Breath was regular and orderly, breath sounds in both lungs were rough, and crackles could be heard. The heart rhythm was aligned. Pericardial rub, additional heart sounds, and pathological murmur were not heard on auscultation. The abdominal examination was normal. The liver, gallbladder and spleen were not palpable, percussion pain in both kidney areas was negative, and neurological examination was normal.

Laboratory examinations

On January 27, 2019, routine blood tests showed white blood cell count (WBC) $7.15 \times 10^9/L$, neutrophil (NEU) 59.90%, lymphocyte (LYM) 31.20%, monocyte (MON) ratio 8.50%, red blood cell count (RBC) $4.37 \times 10^{12}/L$, platelet (PLT) count $159 \times 10^9/L$, abnormal LYM (YX) < 10%, and high-sensitivity C-reactive protein (hs-CRP) < 0.50 mg/L.

On January 28, 2019, procalcitonin was < 0.1 ng/mL, immunoglobulin A 0.693 g/L, and complement C3 0.720 g/L. No abnormalities were found in myocardial enzymes, liver and kidney function, and various viral antibody tests. Tuberculosis antibodies, antinuclear antibodies, rheumatoid factor detection and the anti-O test were normal.

On January 30, 2019, thyroid function tests showed T3 0.877 nmol/L, T4 52.92 nmol/L, free triiodothyronine 2.39 pmol/L, free thyroxine 9.43 pmol/L, A-thrombopoietin 96.34 IU/mL, and A-thyroglobulin 328.80 IU/mL.

On February 1, 2019, routine blood tests showed WBC $7.60 \times 10^9/L$, NEU 45.80%, LYM 36.70%, MON 8.30%, RBC $4.45 \times 10^{12}/L$, PLT $253 \times 10^9/L$, and hs-CRP 11 mg/L, and D-dimer 932 µg/L. Fungal-D glucan was higher than 162 pg/mL (normal values were < 100.5 pg/mL). No abnormalities in tuberculosis-infected T cells and respiratory virus antibodies were detected.

On February 2, 2019, a blood culture was tested on the next day after admission, and the result was negative on the 7th d.

On February 4, 2019, routine blood tests showed WBC $6.42 \times 10^9/L$, NEU 38.64%, LYM 51.44%, MON 6.24%, RBC $4.20 \times 10^{12}/L$, PLT $277 \times 10^9/L$, and hs-CRP < 0.50 mg/L.

On February 7, 2019, routine blood tests showed WBC $6.61 \times 10^9/L$, NEU 47.44%, LYM 39.34%, MON 8.04%, RBC $4.39 \times 10^{12}/L$, PLT $272 \times 10^9/L$, and hs-CRP < 0.50 mg/L.

According to the "National Clinical Laboratory Operating Procedures" compiled by the Department of Medical Administration, Ministry of Health, China, The usual WBC count range is $(4.0-10.0) \times 10^9$, the normal value for the percentage of NEUs is 50%-70%, the normal value for the LYM percentage is 20%-40%, the normal value of the percentage of monocytes is 3%-8%, the normal value of RBCs is $(3.5-5.5) \times 10^{12}/L$, the normal value of PLTs is $(100-300) \times 10^9/L$, the normal value for the hypersensitive CRP is 0-3 mg/L.

Imaging examinations

Computed tomography (CT) scanning of the lungs was performed, with the following findings.

On January 27, 2019, the texture of both lungs was enhanced, the bronchial vascular bundle was thickened and disordered, multiple fuzzy cord shadows were seen, and the lower lobe of the right lung showed patchy dense opacity, with smooth edges and an uneven internal density (Figure 1A).

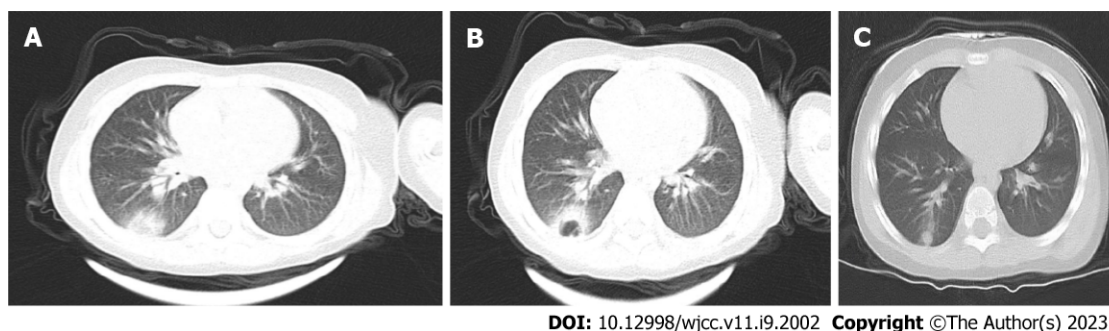
On January 31, 2019, compared with the previous CT images on January 27, 2019, the density of the lower lobe of the right lung had increased significantly, the edges were blurred, and an irregular cavity was seen inside. A small amount of fluid was noted in the right thorax (Figure 1B).

FINAL DIAGNOSIS

The patient was eventually diagnosed with *Ralstonia insidiosa* pneumonia.

TREATMENT

The patient was started on conventional empirical medication with amoxicillin sodium-clavulanate potassium 30 mg/kg 3 times daily and adenosine monophosphate 5 mg/kg once a day. On the third day of admission, the child had increased fever and was given meropenem 20 mg/kg 3 times daily and



DOI: 10.12998/wjcc.v11.i9.2002 Copyright ©The Author(s) 2023.

Figure 1 Computed tomography images. A: Computed tomography (CT) images of the lungs in the child on the 19th d of infection onset and the day of admission; B: CT scan of the lungs on day 4 after admission; C: CT scan of the lungs more than 1 mo after discharge.

immunoglobulin 1 g/kg once a day intravenously. Subsequently, meropenem 20 mg/kg was administered 3 times daily combined with azithromycin 10 mg/kg once a day. Based on the timeline of the onset of the infection, a chart of the child's fever trend (Figure 2) and WBC count (Figure 3) was prepared for comparison.

OUTCOME AND FOLLOW-UP

The child has been followed up, and no disease recurrence has been observed. A pulmonary CT performed 42 d after discharge on March 21, 2019, showed texture enhancement in both lungs. The lower lobe of the right lung showed patchy and cord-like high-density opacities with blurred edges (Figure 1C).

DISCUSSION

With regard to *Ralstonia* infections, a review of previous literature showed that the majority of cases were nosocomial infections, with evidence that *Ralstonia* enters the hospital environment primarily through a contaminated water supply system[9]. Infections are primarily caused by contaminated solutions, including blood products, sterile water, saline, respiratory therapeutic fluids[10-13], and that the most common infected items are blood collection tubes, dialysis machines, and nebulizers, which may eventually lead to different diseases such as bacteremia, sepsis, respiratory infections, and pneumonia[14], with human infections unrelated to contaminated solutions being rare. Infections occur predominantly in weak or immunosuppressed individuals, mainly in the elderly or neonates who are immunocompromised.

The child in the present report was admitted to hospital with intermittent fever and cough for 20 d, with no history of surgery or invasive procedures which excluded contact with medical devices such as ventilators and dialysis machines. The child had a long course of the disease and received antibiotics for 19 d before admission to the hospital (exact dose was unknown). After admission, we ruled out febrile illnesses such as tuberculosis, infectious mononucleosis, Kawasaki disease, rheumatic fever, and epidemic hemorrhagic fever. Physical and chemical examinations showed lower values of immunoglobulin A, complement C3, and serum T3 and T4, suggesting that the child was immunocompromised. On admission, CT showed a patchy dense shadow in the lower lobe of the right lung. A blood culture was tested on the next day after admission, and the result was negative on the 7th d. This also made the diagnosis difficult. The child was initially considered to have lobar pneumonia and was given amoxicillin sodium-clavulanate potassium, immunoglobulin, and meropenem as empirical treatment against infection. The child's condition did not improve, and a second CT scan showed a significant increase in the hyperdense shadow in the lower lobe of the right lung and a small amount of pleural effusion. The child was also tested for fungal-D glucan, which was higher than 162 mg/L. This also led us to consider the possibility of specific flora infectious pneumonia and fungal pneumonia at the time of diagnosis. As fungal pneumonia does not have characteristic imaging, bronchoalveolar lavage is used for diagnosis[15]. During follow-up, the child underwent bronchoscopy, and an alveolar lavage fluid culture was performed, which eventually confirmed the diagnosis of *Ralstonia insidiosa* infection based on the lavage fluid culture results.

Reliable therapeutic data on *Ralstonia insidiosa* infection are lacking. Studies related to drug resistance in *Ralstonia insidiosa* have shown that this bacterium is highly resistant to the aminoglycoside gentamicin and the β -lactam antibiotic aztreonam, with different drug resistance to ticarcillin-clavulanic acid mixtures[16]. Studies by Ryan and Adley[16] have shown that most *Ralstonia* strains are sensitive to

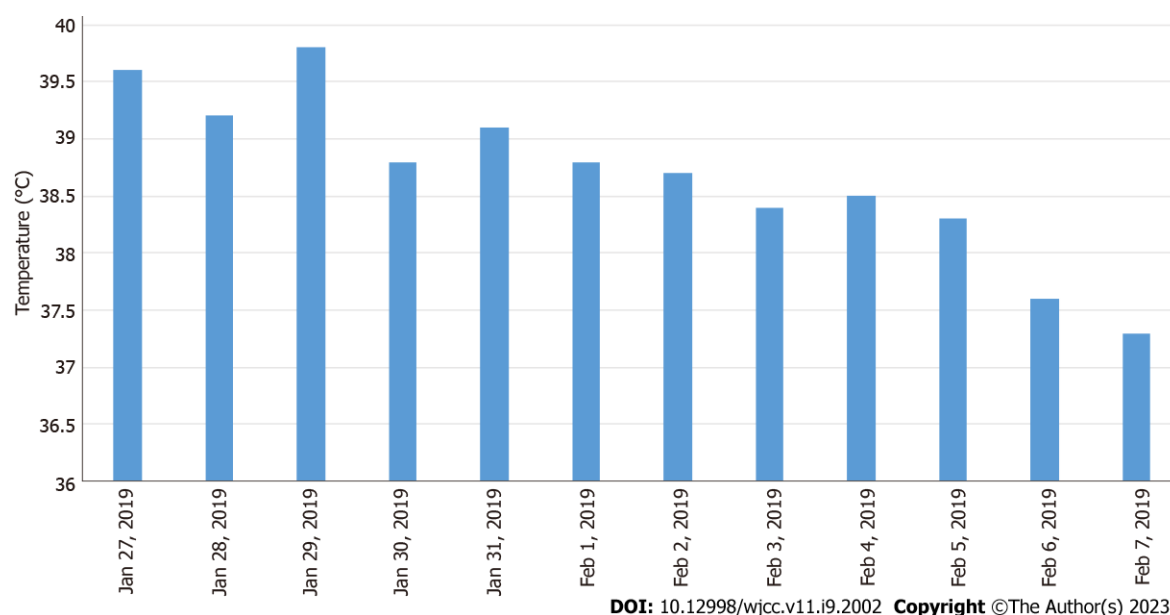


Figure 2 The body temperature in the figure is the highest daily body temperature of the child.

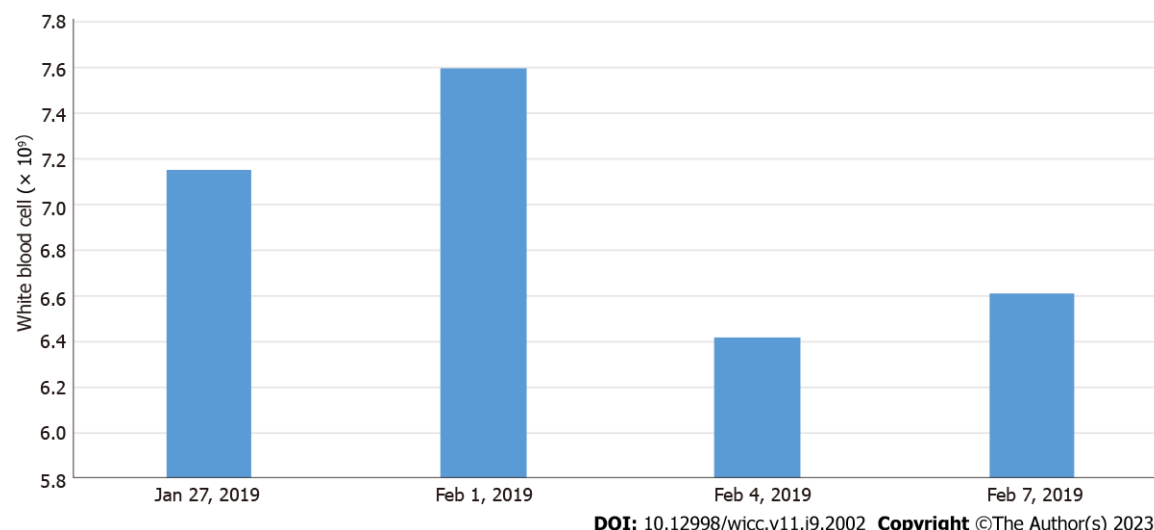


Figure 3 A chart of the child's fever trend and white blood cell count. The usual white blood cell count range is $(4.0-10.0) \times 10^9$ according to the "National Clinical Laboratory Operating Procedures" compiled by the Department of Medical Administration, Ministry of Health, China.

carbapenem antibiotics. All isolates were sensitive to quinolones (ciprofloxacin and ofloxacin), tetracyclines (tetracycline and minocycline), cephalosporins (cefotaxime and ceftazidime), folate pathway inhibitors (meperidine/sulfamethoxazole) and uropipexicillin broad-spectrum-lactam antibiotics (piperacillin)[17]. Our patient, after 3 d of anti-infective treatment with azithromycin 10 mg/kg once daily combined with meropenem 20 mg/kg three times daily prior to the diagnosis of *Ralstonia insidiosa* infection, showed a significant reduction in fever and a significant improvement in clinical signs. Therefore, this regimen was continued for 4 d after diagnosis and the infection eventually improved and was controlled.

CONCLUSION

Ralstonia infections are becoming increasingly common in clinical practice. The reasons for this may be associated with the massive clinical use and partial misuse of antibiotics, the insidious nature of the bacterium, which is easily overlooked in the early stages of infection, and its multi-drug resistance, which makes the infection difficult to control. Our report presents a rare case of childhood *Ralstonia insidiosa* pneumonia. Clinicians should be vigilant about *Ralstonia* infections, especially in immunocom-

promised patients and those with a history of invasive procedures such as ventilators and dialysis machines.

ACKNOWLEDGEMENTS

We would like to thank the patient and his family members for their contributions to this report.

FOOTNOTES

Author contributions: Lin SZ and Qian MJ are the attending doctors at the Diagnosis and Treatment Center for Children, Affiliated Hospital of Changchun University of Chinese Medicine, and provided this case; Wang YW and Chen QD reviewed the literature, and wrote and revised the manuscript; Wang WQ, Yang RT and Wang XY compiled the literature review, conducted the preliminary translation of the report and the subsequent submission; Jiang K provided guidance on the article; and all authors issued final approval for the version to be submitted.

Informed consent statement: We have obtained informed consent from the parents of the child.

Conflict-of-interest statement: All the authors report no relevant conflicts of interest for this article.

CARE Checklist (2016) statement: We have read and followed the CARE Checklist (2016) to prepare this report.

Open-Access: This article is an open-access article that was selected by an in-house editor and fully peer-reviewed by external reviewers. It is distributed in accordance with the Creative Commons Attribution NonCommercial (CC BY-NC 4.0) license, which permits others to distribute, remix, adapt, build upon this work non-commercially, and license their derivative works on different terms, provided the original work is properly cited and the use is non-commercial. See: <https://creativecommons.org/licenses/by-nc/4.0/>

Country/Territory of origin: China

ORCID number: Shuang-Zhu Lin 0000-0001-5333-2138; Mei-Jia Qian 0000-0002-3847-4194; Yan-Wei Wang 0000-0003-1606-4255; Qian-Dui Chen 0000-0002-8593-4077; Wan-Qi Wang 0000-0002-8247-7616; Jia-Yi Li 0000-0002-7729-4479; Rui-Tong Yang 0000-0003-0923-3444; Xin-Yao Wang 0000-0002-9066-5887; Chun-Yu Mu 0000-0002-5966-3322; Kai Jiang 0000-0002-0194-9934.

S-Editor: Wang JJ

L-Editor: A

P-Editor: Wang JJ

REFERENCES

- 1 **Yabuuchi E**, Kosako Y, Yano I, Hotta H, Nishiuchi Y. Transfer of two Burkholderia and an Alcaligenes species to Ralstonia gen. Nov.: Proposal of Ralstonia pickettii (Ralston, Palleroni and Doudoroff 1973) comb. Nov., Ralstonia solanacearum (Smith 1896) comb. Nov. and Ralstonia eutropha (Davis 1969) comb. Nov. *Microbiol Immunol* 1995; **39**: 897-904 [PMID: 8657018 DOI: 10.1111/j.1348-0421.1995.tb03275.x]
- 2 **Sharma D**, Sharma P, Soni P, Gupta B. Ralstonia picketti neonatal sepsis: a case report. *BMC Res Notes* 2017; **10**: 28 [PMID: 28061799 DOI: 10.1186/s13104-016-2347-1]
- 3 **Chen YY**, Huang WT, Chen CP, Sun SM, Kuo FM, Chan YJ, Kuo SC, Wang FD. An Outbreak of Ralstonia pickettii Bloodstream Infection Associated with an Intrinsically Contaminated Normal Saline Solution. *Infect Control Hosp Epidemiol* 2017; **38**: 444-448 [PMID: 28115025 DOI: 10.1017/ice.2016.327]
- 4 **Vincenti S**, Quaranta G, De Meo C, Bruno S, Ficarra MG, Carovillano S, Ricciardi W, Laurenti P. Non-fermentative gram-negative bacteria in hospital tap water and water used for haemodialysis and bronchoscope flushing: prevalence and distribution of antibiotic resistant strains. *Sci Total Environ* 2014; **499**: 47-54 [PMID: 25173861 DOI: 10.1016/j.scitotenv.2014.08.041]
- 5 **Pan W**, Zhao Z, Dong M. Lobar pneumonia caused by Ralstonia pickettii in a sixty-five-year-old Han Chinese man: a case report. *J Med Case Rep* 2011; **5**: 377 [PMID: 21843320 DOI: 10.1186/1752-1947-5-377]
- 6 **Fang Q**, Feng Y, Feng P, Wang X, Zong Z. Nosocomial bloodstream infection and the emerging carbapenem-resistant pathogen Ralstonia insidiosa. *BMC Infect Dis* 2019; **19**: 334 [PMID: 31014269 DOI: 10.1186/s12879-019-3985-4]
- 7 **Coenye T**, Goris J, De Vos P, Vandamme P, LiPuma JJ. Classification of Ralstonia pickettii-like isolates from the environment and clinical samples as Ralstonia insidiosa sp. nov. *Int J Syst Evol Microbiol* 2003; **53**: 1075-1080 [PMID: 12892129 DOI: 10.1099/ijs.0.02555-0]
- 8 **Ryan MP**, Pembroke JT, Adley CC. Genotypic and phenotypic diversity of Ralstonia pickettii and Ralstonia insidiosa isolates from clinical and environmental sources including High-purity Water. Diversity in Ralstonia pickettii. *BMC Microbiol* 2011; **11**: 194 [PMID: 21878094 DOI: 10.1186/1471-2180-11-194]

- 9 **Tayeb LA**, Lefevre M, Passet V, Diancourt L, Brisse S, Grimont PA. Comparative phylogenies of Burkholderia, Ralstonia, Comamonas, Brevundimonas and related organisms derived from rpoB, gyrB and rrs gene sequences. *Res Microbiol* 2008; **159**: 169-177 [PMID: [18280706](#) DOI: [10.1016/j.resmic.2007.12.005](#)]
- 10 **Moreira BM**, Leobons MB, Pellegrino FL, Santos M, Teixeira LM, de Andrade Marques E, Sampaio JL, Pessoa-Silva CL. Ralstonia pickettii and Burkholderia cepacia complex bloodstream infections related to infusion of contaminated water for injection. *J Hosp Infect* 2005; **60**: 51-55 [PMID: [15823657](#) DOI: [10.1016/j.jhin.2004.09.036](#)]
- 11 **Labarca JA**, Trick WE, Peterson CL, Carson LA, Holt SC, Arduino MJ, Meylan M, Mascola L, Jarvis WR. A multistate nosocomial outbreak of Ralstonia pickettii colonization associated with an intrinsically contaminated respiratory care solution. *Clin Infect Dis* 1999; **29**: 1281-1286 [PMID: [10524976](#) DOI: [10.1086/313458](#)]
- 12 **McNeil MM**, Solomon SL, Anderson RL, Davis BJ, Spengler RF, Reisberg BE, Thornsberry C, Martone WJ. Nosocomial Pseudomonas pickettii colonization associated with a contaminated respiratory therapy solution in a special care nursery. *J Clin Microbiol* 1985; **22**: 903-907 [PMID: [4066922](#) DOI: [10.1128/jcm.22.6.903-907.1985](#)]
- 13 **Yoneyama A**, Yano H, Hitomi S, Okuzumi K, Suzuki R, Kimura S. Ralstonia pickettii colonization of patients in an obstetric ward caused by a contaminated irrigation system. *J Hosp Infect* 2000; **46**: 79-80 [PMID: [11023730](#) DOI: [10.1053/jhin.2000.0791](#)]
- 14 **Ryan MP**, Pembroke JT, Adley CC. Ralstonia pickettii: a persistent gram-negative nosocomial infectious organism. *J Hosp Infect* 2006; **62**: 278-284 [PMID: [16337309](#) DOI: [10.1016/j.jhin.2005.08.015](#)]
- 15 **Fortún J**. Diagnostic and therapeutic approach to fungal pneumonia in the critically ill patient. *Rev Esp Quimioter* 2022; **35** Suppl 1: 97-103 [PMID: [35488836](#) DOI: [10.37201/req/s01.21.2022](#)]
- 16 **Ryan MP**, Adley CC. The antibiotic susceptibility of water-based bacteria Ralstonia pickettii and Ralstonia insidiosa. *J Med Microbiol* 2013; **62**: 1025-1031 [PMID: [23579396](#) DOI: [10.1099/jmm.0.054759-0](#)]
- 17 **Girlich D**, Naas T, Nordmann P. OXA-60, a chromosomal, inducible, and imipenem-hydrolyzing class D beta-lactamase from Ralstonia pickettii. *Antimicrob Agents Chemother* 2004; **48**: 4217-4225 [PMID: [15504844](#) DOI: [10.1128/AAC.48.11.4217-4225.2004](#)]



Published by **Baishideng Publishing Group Inc**
7041 Koll Center Parkway, Suite 160, Pleasanton, CA 94566, USA

Telephone: +1-925-3991568

E-mail: bpgoffice@wjgnet.com

Help Desk: <https://www.f6publishing.com/helpdesk>

<https://www.wjgnet.com>

