

# World Journal of *Clinical Cases*

*World J Clin Cases* 2023 March 26; 11(9): 1888-2122



## Contents

Thrice Monthly Volume 11 Number 9 March 26, 2023

## REVIEW

- 1888 Endoscopic transluminal drainage and necrosectomy for infected necrotizing pancreatitis: Progress and challenges

Zeng Y, Yang J, Zhang JW

## MINIREVIEWS

- 1903 Functional role of frontal electroencephalogram alpha asymmetry in the resting state in patients with depression: A review

Xie YH, Zhang YM, Fan FF, Song XY, Liu L

- 1918 COVID-19 related liver injuries in pregnancy

Sekulovski M, Bogdanova-Petrova S, Peshevska-Sekulovska M, Velikova T, Georgiev T

- 1930 Examined lymph node count for gastric cancer patients after curative surgery

Zeng Y, Chen LC, Ye ZS, Deng JY

- 1939 Laparoscopic common bile duct exploration to treat choledocholithiasis in situs inversus patients: A technical review

Chiu BY, Chuang SH, Chuang SC, Kuo KK

- 1951 Airway ultrasound for patients anticipated to have a difficult airway: Perspective for personalized medicine

Nakazawa H, Uzawa K, Tokumine J, Lefor AK, Motoyasu A, Yorozu T

## ORIGINAL ARTICLE

## Observational Study

- 1963 Clinicopathological features and expression of regulatory mechanism of the Wnt signaling pathway in colorectal sessile serrated adenomas/polyps with different syndrome types

Qiao D, Liu XY, Zheng L, Zhang YL, Que RY, Ge BJ, Cao HY, Dai YC

## Randomized Controlled Trial

- 1974 Effects of individual shock wave therapy vs celecoxib on hip pain caused by femoral head necrosis

Zhu JY, Yan J, Xiao J, Jia HG, Liang HJ, Xing GY

## CASE REPORT

- 1985 Very low calorie ketogenic diet and common rheumatic disorders: A case report

Rondanelli M, Patelli Z, Gasparri C, Mansueto F, Ferraris C, Nichetti M, Alalwan TA, Sajoux I, Maugeri R, Perna S

- 1992 Delayed versus immediate intervention of ruptured brain arteriovenous malformations: A case report

Bintang AK, Bahar A, Akbar M, Soraya GV, Gunawan A, Hammado N, Rachman ME, Ulhaq ZS

- 2002** Children with infectious pneumonia caused by *Ralstonia insidiosa*: A case report  
*Lin SZ, Qian MJ, Wang YW, Chen QD, Wang WQ, Li JY, Yang RT, Wang XY, Mu CY, Jiang K*
- 2009** Transient ischemic attack induced by pulmonary arteriovenous fistula in a child: A case report  
*Zheng J, Wu QY, Zeng X, Zhang DF*
- 2015** Motor cortex transcranial magnetic stimulation to reduce intractable postherpetic neuralgia with poor response to other therapies: Report of two cases  
*Wang H, Hu YZ, Che XW, Yu L*
- 2021** Small bowel adenocarcinoma in neoterminal ileum in setting of stricturing Crohn's disease: A case report and review of literature  
*Karthikeyan S, Shen J, Keyashian K, Gubatan J*
- 2029** Novel combined endoscopic and laparoscopic surgery for advanced T2 gastric cancer: Two case reports  
*Dai JH, Qian F, Chen L, Xu SL, Feng XF, Wu HB, Chen Y, Peng ZH, Yu PW, Peng GY*
- 2036** Acromicric dysplasia caused by a mutation of fibrillin 1 in a family: A case report  
*Shen R, Feng JH, Yang SP*
- 2043** Ultrasound-guided intra-articular corticosteroid injection in a patient with manubriosternal joint involvement of ankylosing spondylitis: A case report  
*Choi MH, Yoon IY, Kim WJ*
- 2051** Granulomatous prostatitis after bacille Calmette-Guérin instillation resembles prostate carcinoma: A case report and review of the literature  
*Yao Y, Ji JJ, Wang HY, Sun LJ, Zhang GM*
- 2060** Unusual capitate fracture with dorsal shearing pattern and concomitant carpometacarpal dislocation with a 6-year follow-up: A case report  
*Lai CC, Fang HW, Chang CH, Pao JL, Chang CC, Chen YJ*
- 2067** Live births from *in vitro* fertilization-embryo transfer following the administration of gonadotropin-releasing hormone agonist without gonadotropins: Two case reports  
*Li M, Su P, Zhou LM*
- 2074** Spontaneous conus infarction with "snake-eye appearance" on magnetic resonance imaging: A case report and literature review  
*Zhang QY, Xu LY, Wang ML, Cao H, Ji XF*
- 2084** Transseptal approach for catheter ablation of left-sided accessory pathways in children with Marfan syndrome: A case report  
*Dong ZY, Shao W, Yuan Y, Lin L, Yu X, Cui L, Zhen Z, Gao L*
- 2091** Occipital artery bypass importance in unsuitable superficial temporal artery: Two case reports  
*Hong JH, Jung SC, Ryu HS, Kim TS, Joo SP*

- 2098** Anesthetic management of a patient with preoperative R-on-T phenomenon undergoing laparoscopic-assisted sigmoid colon resection: A case report  
*Li XX, Yao YF, Tan HY*
- 2104** Pembrolizumab combined with axitinib in the treatment of skin metastasis of renal clear cell carcinoma to nasal ala: A case report  
*Dong S, Xu YC, Zhang YC, Xia JX, Mou Y*
- 2110** Successful treatment of a rare subcutaneous emphysema after a blow-out fracture surgery using needle aspiration: A case report  
*Nam HJ, Wee SY*

### LETTER TO THE EDITOR

- 2116** Are biopsies during endoscopic ultrasonography necessary for a suspected esophageal leiomyoma? Is laparoscopy always feasible?  
*Beji H, Chtourou MF, Zribi S, Kallel Y, Bouassida M, Touinsi H*
- 2119** Vaginal microbes confounders and implications on women's health  
*Nori W, H-Hameed B*

**ABOUT COVER**

Editorial Board Member of *World Journal of Clinical Cases*, Marilia Carabotti, MD, PhD, Academic Research, Medical-Surgical Department of Clinical Sciences and Translational Medicine, University Sapienza Rome, Rome 00189, Italy. mariliacarabotti@gmail.com

**AIMS AND SCOPE**

The primary aim of *World Journal of Clinical Cases* (WJCC, *World J Clin Cases*) is to provide scholars and readers from various fields of clinical medicine with a platform to publish high-quality clinical research articles and communicate their research findings online.

WJCC mainly publishes articles reporting research results and findings obtained in the field of clinical medicine and covering a wide range of topics, including case control studies, retrospective cohort studies, retrospective studies, clinical trials studies, observational studies, prospective studies, randomized controlled trials, randomized clinical trials, systematic reviews, meta-analysis, and case reports.

**INDEXING/ABSTRACTING**

The WJCC is now abstracted and indexed in Science Citation Index Expanded (SCIE, also known as SciSearch®), Journal Citation Reports/Science Edition, Current Contents®/Clinical Medicine, PubMed, PubMed Central, Scopus, Reference Citation Analysis, China National Knowledge Infrastructure, China Science and Technology Journal Database, and Superstar Journals Database. The 2022 Edition of Journal Citation Reports® cites the 2021 impact factor (IF) for WJCC as 1.534; IF without journal self cites: 1.491; 5-year IF: 1.599; Journal Citation Indicator: 0.28; Ranking: 135 among 172 journals in medicine, general and internal; and Quartile category: Q4. The WJCC's CiteScore for 2021 is 1.2 and Scopus CiteScore rank 2021: General Medicine is 443/826.

**RESPONSIBLE EDITORS FOR THIS ISSUE**

Production Editor: *Ying-Yi Yuan*; Production Department Director: *Xiang Li*; Editorial Office Director: *Jin-Lei Wang*.

**NAME OF JOURNAL**

*World Journal of Clinical Cases*

**ISSN**

ISSN 2307-8960 (online)

**LAUNCH DATE**

April 16, 2013

**FREQUENCY**

Thrice Monthly

**EDITORS-IN-CHIEF**

Bao-Gan Peng, Jerzy Tadeusz Chudek, George Kontogeorgos, Maurizio Serati, Ja Hyeon Ku

**EDITORIAL BOARD MEMBERS**

<https://www.wjnet.com/2307-8960/editorialboard.htm>

**PUBLICATION DATE**

March 26, 2023

**COPYRIGHT**

© 2023 Baishideng Publishing Group Inc

**INSTRUCTIONS TO AUTHORS**

<https://www.wjnet.com/bpg/gerinfo/204>

**GUIDELINES FOR ETHICS DOCUMENTS**

<https://www.wjnet.com/bpg/GerInfo/287>

**GUIDELINES FOR NON-NATIVE SPEAKERS OF ENGLISH**

<https://www.wjnet.com/bpg/gerinfo/240>

**PUBLICATION ETHICS**

<https://www.wjnet.com/bpg/GerInfo/288>

**PUBLICATION MISCONDUCT**

<https://www.wjnet.com/bpg/gerinfo/208>

**ARTICLE PROCESSING CHARGE**

<https://www.wjnet.com/bpg/gerinfo/242>

**STEPS FOR SUBMITTING MANUSCRIPTS**

<https://www.wjnet.com/bpg/GerInfo/239>

**ONLINE SUBMISSION**

<https://www.f6publishing.com>



## Acromicric dysplasia caused by a mutation of fibrillin 1 in a family: A case report

Ren Shen, Jian-Hua Feng, Shan-Pu Yang

**Specialty type:** Medicine, research and experimental

**Provenance and peer review:** Unsolicited article; Externally peer reviewed.

**Peer-review model:** Single blind

**Peer-review report's scientific quality classification**

Grade A (Excellent): 0  
Grade B (Very good): 0  
Grade C (Good): 0  
Grade D (Fair): 0  
Grade E (Poor): 0

**P-Reviewer:** Zhai JF, China

**Received:** November 29, 2022

**Peer-review started:** November 29, 2022

**First decision:** February 14, 2023

**Revised:** February 20, 2023

**Accepted:** March 3, 2023

**Article in press:** March 3, 2023

**Published online:** March 26, 2023



**Ren Shen, Shan-Pu Yang,** Department of Pediatrics, The People's Hospital of Yuhuan, Taizhou 317600, Zhejiang Province, China

**Jian-Hua Feng,** Department of Hematology, The First Affiliated Hospital of Wenzhou Medical University, Wenzhou 325000, Zhejiang Province, China

**Corresponding author:** Shan-Pu Yang, MBChB, Chief Physician, Department of Pediatrics, The People's Hospital of Yuhuan, No. 18 Changle Road, Yucheng Street, Taizhou 317600, Zhejiang Province, China. [ysp6005@qq.com](mailto:ysp6005@qq.com)

### Abstract

#### BACKGROUND

Acromicric dysplasia (AD) is a rare skeletal dysplasia. Its incidence is  $< 1/1000000$ , and only approximately 60 cases are reported worldwide. It is a disease characterized by severe short stature, short hands and feet, facial abnormalities, normal intelligence, and bone abnormalities. Unlike other skeletal dysplasia, AD has a mild clinical phenotype, mainly characterized by short stature. Extensive endocrine examination has not revealed a potential cause. The clinical effect of growth hormone therapy is still uncertain.

#### CASE SUMMARY

We report a clinical phenotype of AD associated with mutations in the fibrillin 1 (*FBN1*) (OMIM 102370) gene c.5183C>T (p. Ala1728Val) in three people from a Chinese family. A 4-year-old member of the family first visited the hospital because of slow growth and short stature for 2 years, but no abnormalities were found after a series of laboratory tests, echocardiography, pituitary magnetic resonance imaging, and ophthalmological examination. Recombinant human growth hormone (rhGH) was used to treat the patient for  $> 5$  years. The efficacy of rhGH was apparent in the first year of treatment; the height increased from -3.64 standard deviation score (SDS) to -2.88 SDS, while the efficacy weakened from the second year. However, long-term follow-up is required to clarify the efficacy of rhGH.

#### CONCLUSION

*FBN1*-related AD has genetic heterogeneity and/or clinical variability, which brings challenges to the evaluation of clinical treatment. rhGH is effective for treatment of AD, but long-term follow-up is needed to clarify the effect.

**Key Words:** *Fibrillin 1*; Gene; Acromicric dysplasia; Short stature; Recombinant human growth hormone; Case report

©The Author(s) 2023. Published by Baishideng Publishing Group Inc. All rights reserved.

**Core Tip:** Acromicric dysplasia (AD) is a rare skeletal dysplasia, and its incidence is < 1 in 1000000. Here, we report a clinical phenotype of AD associated with mutations in the *fibrillin 1* (OMIM 102370) gene c.5183C>T (p.Ala1728Val) in three people from a Chinese family. A 4-year-old boy was treated with recombinant human growth hormone (rhGH) for > 5 years. The efficacy of rhGH was clear in the first year of treatment; his height increased from -3.64 standard deviation score (SDS) to -2.88 SDS, while the efficacy weakened from the second year. However, long-term follow-up is required to clarify the efficacy of rhGH.

**Citation:** Shen R, Feng JH, Yang SP. Acromicric dysplasia caused by a mutation of fibrillin 1 in a family: A case report. *World J Clin Cases* 2023; 11(9): 2036-2042

**URL:** <https://www.wjgnet.com/2307-8960/full/v11/i9/2036.htm>

**DOI:** <https://dx.doi.org/10.12998/wjcc.v11.i9.2036>

## INTRODUCTION

Geleophysic dysplasia (GD), acromicric dysplasia (AD), and Weill-Marchesani syndrome (WMS) are all acrodysplasia syndromes caused by mutations in the fibrillin 1 (*FBN1*) gene. AD is a rare heterogeneous skeletal dysplasia characterized by short stature, short hands and feet, stiff joints, thickened skin, facial abnormalities, normal intelligence, and skeletal abnormalities, with a prevalence of < 1 in 1000000[1-3]. Although these diseases are similar in physical features, each disease has its own unique clinical phenotype. GD is characterized by happy facial features, progressive valvular heart disease, progressive hepatomegaly, tracheal stenosis, and tiptoe gait. Although AD shows similar characteristics as GD, AD usually does not manifest heart valve abnormalities, hepatomegaly, tracheal stenosis, or eye disease[4]. WMS is distinguished from AD by ocular abnormalities, including lens myopia, lens ectopia, glaucoma, and spherical lenses. In contrast to the genetic heterogeneity of GD and WMS, AD is caused only by mutations in *FBN1* and is an autosomal dominant disorder[5]. Here, we report the clinical phenotype and genetic characteristics of three cases of AD associated with a mutation in the *FBN1* (OMIM 102370) gene c.5183C>T (p. Ala1728Val) in a Chinese family, to enhance clinicians' understanding of the disease and to share the experience of a young patient receiving long-term recombinant human growth hormone (rhGH) therapy.

## CASE PRESENTATION

### Chief complaints

A 4-year-old boy presented with slow growth and short stature for 2 years.

### History of present illness

Two years ago, the patient was found to have short stature, normal mental capacity, liver enlargement, dyspnea, myopia, glaucoma, and other symptoms.

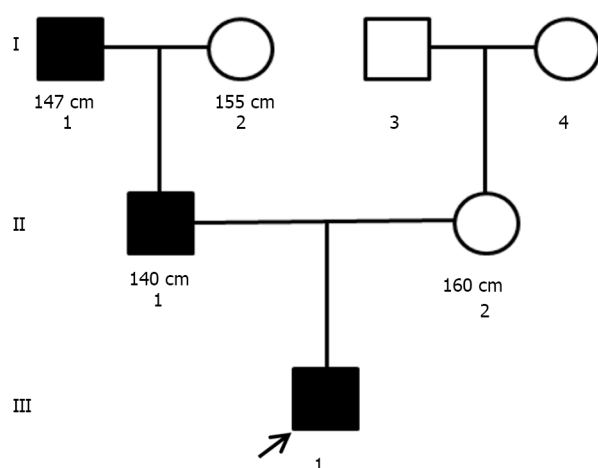
### History of past illness

The patient was healthy in the past and had no history of skin, heart, lung, liver, kidney or eye diseases.

### Personal and family history

The patient was born in Zhejiang Province of China, of Han nationality. The patient was the first birth of the second pregnancy, born by cesarean section at 40 wk' gestation, with a birth weight of 3500 g and length of 50 cm, and without a history of birth trauma asphyxia at birth. In the family, the height of the father was 140 cm [< -5 standard deviation score (SDS)][6] tall and the grandfather was 147 cm (< -4 SDS)[6] tall, the mother and grandmother were of normal height, and neither parents nor grandparents were consanguineous (Figure 1).





Patient (III.1), the paternal line is affected. The black means heterozygous, white means normal.

DOI: 10.12998/wjcc.v11.i9.2036 Copyright ©The Author(s) 2023.

Figure 1 Pedigree map of the family.

### Physical examination

The patient was short (90.5 cm, < -3 SDS)[6], with low weight (12.5 kg, < -2 SDS)[6], round face, stubby nose, forward-leaned nostrils, long eyelashes and thick lips (Figure 2).

### Laboratory examinations

There were no obvious abnormalities in sex hormones, insulin-like growth factor (IGF)-1, IGF binding protein-3, thyroid function, biochemistry, trace elements, routine blood tests, routine urine tests, growth hormone challenge tests, cardiac ultrasound, pituitary-enhanced magnetic resonance imaging or karyotyping (550 bands, G bands).

### Imaging examinations

Radiography showed delayed bone age (2.4 years) (Figure 3A). Plain pelvic radiography showed a beak-like femur head (Figure 3B), and the lumbar lateral radiograph showed lumbar lordosis (Figure 3C).

### Further diagnostic work-up

The patient, his father and grandfather all showed significant familial short stature. We suspected the possibility of hereditary short stature and recommended that the patient, his parents and his grandfather underwent whole-exome sequencing. On October 17, 2019, whole-exome sequencing of the patient, his father and grandfather showed a mutation of the *FBN1* gene (OMIM 102370) c.5183C>T (p. Ala1728Val), while whole-exome sequencing of the patient's mother showed no abnormalities. The pathogenicity criteria of the mutation according to the American College of Medical Genetics and Genomics, and the pathogenicity rating was likely pathogenic[7].

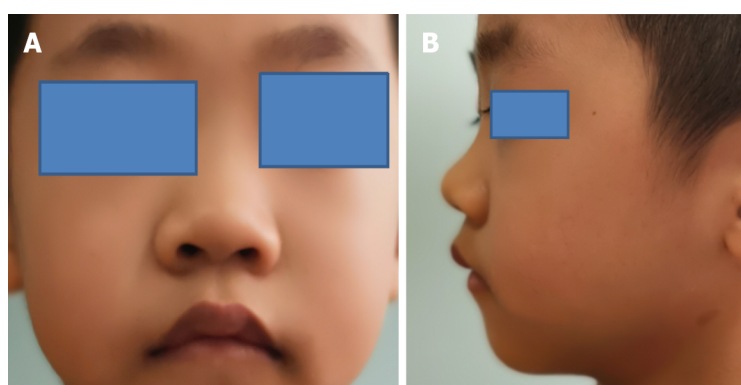
## FINAL DIAGNOSIS

Combined with the patient's medical history, physical examination and whole-exome sequencing, the final diagnosis was AD.

## TREATMENT

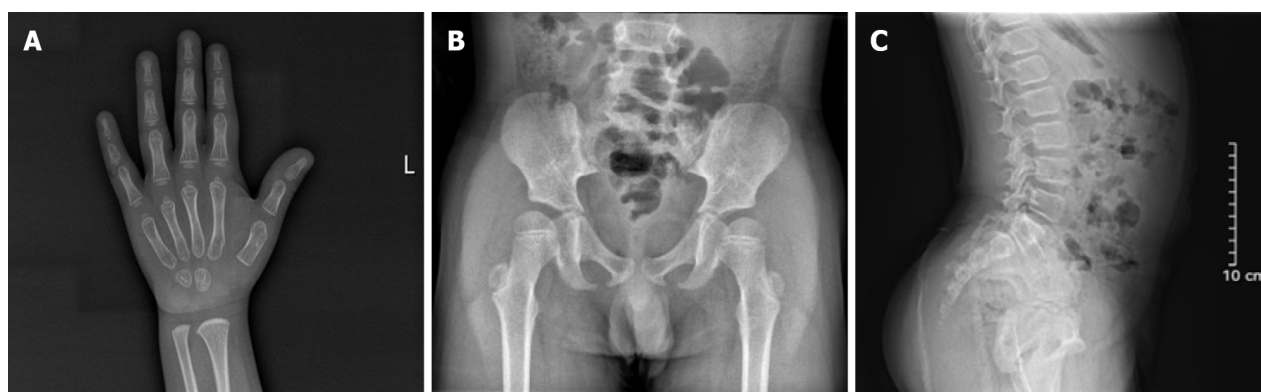Before whole-exome sequencing, the initial diagnosis was idiopathic short stature. From October 2016 to October 2019, rhGH at a dose of 0.12–0.15 IU/kg/d was used to treat the patient. After whole-exome sequencing, the final diagnosis was AD. Although the current case reports suggested that rhGH treatment had limited benefits on the final height of the children, the parents requested to continue rhGH treatment after informed consent was obtained. From October 2019 to present, rhGH at a dose of 0.15 IU/kg/d was used to treat the patient (it was suspended from July 2021 to February 2022) (Figure 4).





DOI: 10.12998/wjcc.v11.i9.2036 Copyright ©The Author(s) 2023.

**Figure 2 Distinctive facial features.** A: Round face, stubby nose, forward-leaned nostrils and thick lips; B: Long eyelashes.



DOI: 10.12998/wjcc.v11.i9.2036 Copyright ©The Author(s) 2023.

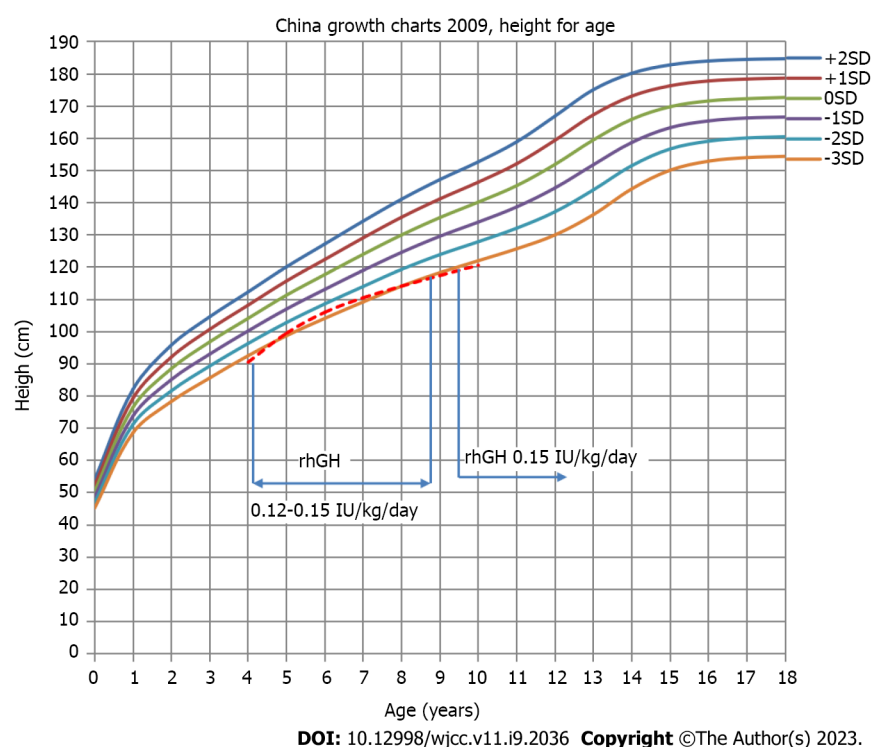
**Figure 3 Representative radiographic images.** A: Delayed bone age; B: Beak-like femur head; C: Lumbar lordosis.

## OUTCOME AND FOLLOW-UP

The height at the beginning of treatment was 90.5 cm (-3.64 SDS), and the height after treatment in the first year (October 2016 to September 2017) was 99.5 cm (-2.88 SDS). Thus, the annual growth rate during the first year was 9.0 cm/year. The height after treatment in the second year (October 2017 to September 2018) was 106 cm (-2.60 SDS); thus, the annual growth rate during the second year was 6.5 cm/year. The height after treatment in the third year (October 2018 to September 2019) was 110.5 cm (-2.80 SDS); thus, the annual growth rate during the third year was 4.5 cm/year. The height after treatment in the fourth year (October 2019 to September 2020) was 114.1 cm (-3.04 SDS); thus, the annual growth rate during the fourth year was 3.6 cm/year. The height after treatment in the fifth year (October 2020 to July 2021) was 117.1 cm (-3.09 SDS), yielding an annual growth rate during the fifth year of 3.0 cm/year. Considering the poor efficacy, it is recommended to stop rhGH treatment. After stopping rhGH for 7 mo, the height was 118.5 cm (-3.17 SDS) in February 2022; thus, the annual growth rate was 2.4 cm/year. The parents requested reuse of rhGH. Afterward, the height was 119.6 cm (-3.20 SDS) in June 2022 and 121.7 cm (-3.11 SDS) in October 2022, indicating an annual growth rate of 4.8 cm/year. To date, the patient has been treated and followed up for 6 years (Figure 4). The efficacy of rhGH treatment was clear in the first year, and the height increased from -3.64 SDS to -2.88 SDS. However, the efficacy of the treatment weakened from the second year. At the request of the parents, the patients would continue to be treated with rhGH and be followed up.

## DISCUSSION

In 1986, Maroteaux *et al*[8] first described a novel type of osteodysplasia in six children with short stature, short hands and feet, normal intelligence, mild facial deformities, and hand X-ray abnormalities. They called the disease AD and could not clarify the cause further because of the limitations of the genetic diagnostic technology at that time.



**Figure 4** Age and height curve. rhGH: Recombinant human growth hormone; SD: Standard deviation.

In 1991, Dietz *et al*[9] first identified the *FBN1* gene as the causative gene of Marfan syndrome (MS). In 2011, Le Goff *et al*[10] found that the *FBN1* gene was associated with GD and AD autosomal dominant inheritance, which showed the opposite phenotype of MS. Both AD and MS have *FBN1* gene mutations, so why do the two diseases have opposite phenotypes? Mutations in *FBN1* leading to MS exist throughout the entire length of the gene (mainly in exon regions 13, 15, 24–28, 32 and 43)[11], while *FBN1* mutations that result in AD are mainly limited to the hotspot regions of exons 41 and 42[5]. These findings indicated that the clinical phenotype could be related to the type and location of the gene variant.

In the 2015 revision of the classification of hereditary bone diseases, acral dysplasia included 10 diseases, among which the *FBN1* gene mutation causes AD, GD, and WMS, and specific mutations in the *FBN1* gene have been found in AD, GD and WMS patients[1,4,12]. The *FBN1* gene is located in the long arm of human chromosome 15 (15q15–q21.1) and contains 66 exons, encoding a 2871-aa (350 kDa) structural protein called fibrillin (FBN)1[13]. *FBN1* consists of 47 epidermal growth factor-like domains and seven transforming growth factor (TGF)- $\beta$ 1-binding-protein-like domains[14]. *FBN1* is the only gene associated with AD that is inherited in an autosomal dominant manner[5]. The *FBN1* gene can participate in the TGF- $\beta$  signaling pathway by regulating the bioavailability and local activity of TGF- $\beta$ , which is an important pathway for linear growth regulation. AD and GD2 (ADAMTSL2-negative) are caused by TGF- $\beta$ 5 region heterozygous missense mutations in the *FBN1* gene, and disruption of TGF- $\beta$  signaling is a common underlying mechanism in different types of patients with acrodysplasia[15].

In the present case, the patient's father and grandfather all had mutations in the *FBN1* gene c.5183C>T (p. Ala1728Val). This gene mutation was first found in a GD patient with severe short stature and cardiac involvement[10]. We reviewed three previously reported AD cases associated with mutation of *FBN1* (OMIM 102370) gene c.5183C>T (p. Ala1728Val). A Brazilian boy developed severe dwarfism at the age of 10 years and 2 mo (-3.9 SDS). He was born with normal birth length, his mother was short at 131cm (-5 SDS), while his father and brothers were normal in height. Physical examination found that fingers and palms were short. His nose bridge was wide, the middle part of his nose was prominent, his lips were thick, and he had obvious genu varus, but his gait was normal. No abnormality was found in endocrine examination. The patient was diagnosed as idiopathic short stature and began to receive rhGH treatment (50–66 mg/kg/d) according to experience, but the overall effect was poor [15]. An African-American girl born in the United States was 107.5 cm (-4 SDS) tall at the age of 7 years. She was born at 37 wk of gestation, with a birth length of only 43 cm (-2.3 SDS) and a birth weight of 2580 g (-0.9 SDS). The height of both parents was normal. The physical examination found that the bridge of the nose was broad, and she had slight osteoporosis, thick lips, small hands and feet, but no other abnormalities. Endocrine examination was normal, and bone age was delayed by about 2 years. At the age of 8 years and 9 mo, recombinant IGF-1 was administered according to experience, and reached a maximum dose of 90 mg/kg/d. The growth rate increased significantly. However, this growth acceleration was confused with early puberty development at the age of 9 years and 1 mo. After the start

of leuporelin treatment, the growth rate decreased to 4–5 cm/year before treatment. Treatment with recombinant IGF-1 was stopped at the age of 9 years and 4 mo[15]. A 5 years and 7 month old Chinese boy was 100.3 cm tall (< -3 SDS). The birth length was 49 cm. His father was 148 cm tall (< -4 SDS). His mother was 160 cm tall. Physical examination showed that the hands were wide and short, but there was no joint stiffness, and there were no abnormality in cardiovascular, abdominal or endocrine examination. The X-ray examination showed that the tubular bone of the hands were shortened and the femoral head was beaked[13]. Although these cases had the same gene mutation site, the clinical phenotypes varied. This site variant might be associated with the autosomal dominant AD (OMIM: 102370), GD (OMIM: 614185) and WMS (OMIM: 608328)[1]. In our case, the three patients showed severe short stature as the main manifestation, and none of them had hepatomegaly, heart valve disease, joint stiffness or eye disease. Meanwhile, the disease condition was milder compared with GD or WMS, neither the quality of the study or quality of life was affected, and the adults are doing well in their professions; thus, all the clinical conditions support the diagnosis of AD. The same mutation at the *FBN1* gene locus could lead to a variety of different clinical phenotypes, and the discovery of multiple phenotypes could help to conduct further research on the pathogenesis of the diseases.

GH therapy has not been widely used in patients with skeletal dysplasia because of genetic heterogeneity and/or clinical variability, which pose challenges in assessing treatment effectiveness. The efficacy of GH in the treatment of AD is still unclear. Faivre *et al*[16] reported one case of AD given rhGH treatment, but there was no significant effect on final height. Jin *et al*[17] found that a patient with AD received rhGH treatment of 0.1 IU/kg/d for 3.5 years, and during treatment, his growth rate remained at 5 cm/year, and his height was -2.23 SDS after 3.5 years. However, long-term follow-up is needed to verify the effect of rhGH treatment. The effects of GH treatment in our present case were similar to those in the patient just described. In our case, the patient's height increased by 9.0 cm in the first year of rhGH treatment, 6.5 cm in the second year, 4.5 cm in the third year, 3.6 cm in the fourth year, and 3 cm in the fifth year. In the first year of treatment, the annual growth rate was 9.0 cm/year, and the height increased from -3.64 SDS to -2.88 SDS, an increase of 0.76 SDS, suggesting that rhGH therapy was effective[18]. In the patient's family, the height of the father was 140 cm (< -5 SDS) tall and the grandfather was 147 cm (< -4 SDS) tall. In the first 5 years of treatment, the growth rate of the patient remained at 5.3 cm/year, and the height increased from -3.64 SDS to -3.09 SDS. It seems that the treatment had some effect, and the first year was the most significant. However, whether it would have a positive effect on the final height remains unclear, and long-term follow-up observation is needed.

## CONCLUSION

AD is a rare skeletal dysplasia and an autosomal dominant disease. *FBN1* is the only gene related to AD. *FBN1*-related acral dysplasia has genetic heterogeneity and/or clinical variability, which brings challenges to the evaluation of clinical treatment. rhGH therapy appears to have some effect on growth, but long-term follow-up is needed to clarify the effect.

## FOOTNOTES

**Author contributions:** Yang SP and Shen R were responsible for the diagnosis and treatment of the patient; Shen R prepared the manuscript; Yang SP and Feng JH participated in revision of the manuscript; All authors have read and approved the final manuscript.

**Informed consent statement:** Informed written consent was obtained from the patients for publication of this report and any accompanying images.

**Conflict-of-interest statement:** All the authors report no relevant conflicts of interest for this article.

**CARE Checklist (2016) statement:** The authors have read the CARE Checklist (2016), and the manuscript was prepared and revised according to the CARE Checklist (2016).

**Open-Access:** This article is an open-access article that was selected by an in-house editor and fully peer-reviewed by external reviewers. It is distributed in accordance with the Creative Commons Attribution NonCommercial (CC BY-NC 4.0) license, which permits others to distribute, remix, adapt, build upon this work non-commercially, and license their derivative works on different terms, provided the original work is properly cited and the use is non-commercial. See: <https://creativecommons.org/licenses/by-nc/4.0/>

**Country/Territory of origin:** China

**ORCID number:** Ren Shen 0000-0001-7369-6692; Jian-Hua Feng 0000-0003-1570-7626; Shan-Pu Yang 0000-0003-3135-5165.

**S-Editor:** Fan JR

L-Editor: A

P-Editor: Fan JR

## REFERENCES

- 1 **Bonafe L**, Cormier-Daire V, Hall C, Lachman R, Mortier G, Mundlos S, Nishimura G, Sangiorgi L, Savarirayan R, Sillence D, Spranger J, Superti-Furga A, Warman M, Unger S. Nosology and classification of genetic skeletal disorders: 2015 revision. *Am J Med Genet A* 2015; **167A**: 2869-2892 [PMID: [26394607](#) DOI: [10.1002/ajmg.a.37365](#)]
- 2 **Globa E**, Zelinska N, Dauber A. The Clinical Cases of Geleophysic Dysplasia: One Gene, Different Phenotypes. *Case Rep Endocrinol* 2018; **2018**: 8212417 [PMID: [30057829](#) DOI: [10.1155/2018/8212417](#)]
- 3 **Quitter F**, Flury M, Waldmueller S, Schubert T, Koehler K, Huebner A. Acromicric dysplasia due to a novel missense mutation in the fibrillin 1 gene in a three-generation family. *J Pediatr Endocrinol Metab* 2022; **35**: 1443-1447 [PMID: [35942587](#) DOI: [10.1515/jpem-2022-0287](#)]
- 4 **Wang Y**, Zhang H, Ye J, Han L, Gu X. Three novel mutations of the FBN1 gene in Chinese children with acromelic dysplasia. *J Hum Genet* 2014; **59**: 563-567 [PMID: [25142510](#) DOI: [10.1038/jhg.2014.73](#)]
- 5 **Sakai LY**, Keene DR, Renard M, De Backer J. FBN1: The disease-causing gene for Marfan syndrome and other genetic disorders. *Gene* 2016; **591**: 279-291 [PMID: [27437668](#) DOI: [10.1016/j.gene.2016.07.033](#)]
- 6 **Li H**, Ji CY, Zong XN, Zhang YQ. [Height and weight standardized growth charts for Chinese children and adolescents aged 0 to 18 years]. *Zhonghua Er Ke Za Zhi* 2009; **47**: 487-492 [PMID: [19951507](#)]
- 7 **Richards S**, Aziz N, Bale S, Bick D, Das S, Gastier-Foster J, Grody WW, Hegde M, Lyon E, Spector E, Voelkerding K, Rehm HL; ACMG Laboratory Quality Assurance Committee. Standards and guidelines for the interpretation of sequence variants: a joint consensus recommendation of the American College of Medical Genetics and Genomics and the Association for Molecular Pathology. *Genet Med* 2015; **17**: 405-424 [PMID: [25741868](#) DOI: [10.1038/gim.2015.30](#)]
- 8 **Maroteaux P**, Stanescu R, Stanescu V, Rappaport R. Acromicric dysplasia. *Am J Med Genet* 1986; **24**: 447-459 [PMID: [3728563](#) DOI: [10.1002/ajmg.1320240307](#)]
- 9 **Dietz HC**, Cutting GR, Pyeritz RE, Maslen CL, Sakai LY, Corson GM, Puffenberger EG, Hamosh A, Nanthakumar EJ, Currstin SM. Marfan syndrome caused by a recurrent de novo missense mutation in the fibrillin gene. *Nature* 1991; **352**: 337-339 [PMID: [1852208](#) DOI: [10.1038/352337a0](#)]
- 10 **Le Goff C**, Mahaut C, Wang LW, Allali S, Abhyankar A, Jensen S, Zylberberg L, Collod-Beroud G, Bonnet D, Alanay Y, Brady AF, Cordier MP, Devriendt K, Genevieve D, Kiper PÖ, Kitoh H, Krakow D, Lynch SA, Le Merrer M, Mégarbane A, Mortier G, Odent S, Polak M, Rohrbach M, Sillence D, Stolte-Dijkstra I, Superti-Furga A, Rimoin DL, Topouchian V, Unger S, Zabel B, Bole-Feysot C, Nitschke P, Handford P, Casanova JL, Boileau C, Apte SS, Munnich A, Cormier-Daire V. Mutations in the TGFβ binding-protein-like domain 5 of FBN1 are responsible for acromicric and geleophysic dysplasias. *Am J Hum Genet* 2011; **89**: 7-14 [PMID: [21683322](#) DOI: [10.1016/j.ajhg.2011.05.012](#)]
- 11 **Collod-Bérout G**, Le Bourdelles S, Ades L, Ala-Kokko L, Booms P, Boxer M, Child A, Comeglio P, De Paepe A, Hyland JC, Holman K, Kaitila I, Loeys B, Matyas G, Nuytink L, Peltonen L, Rantamaki T, Robinson P, Steinmann B, Junien C, Bérout C, Boileau C. Update of the UMD-FBN1 mutation database and creation of an FBN1 polymorphism database. *Hum Mutat* 2003; **22**: 199-208 [PMID: [12938084](#) DOI: [10.1002/humu.10249](#)]
- 12 **Le Goff C**, Cormier-Daire V. From tall to short: the role of TGFβ signaling in growth and its disorders. *Am J Med Genet C Semin Med Genet* 2012; **160C**: 145-153 [PMID: [22791552](#) DOI: [10.1002/ajmg.c.31337](#)]
- 13 **Shan YC**, Yang ZC, Ma L, Ran N, Feng XY, Liu XM, Fu P, Yi MJ. A Review of Three Chinese Cases of Acromicric/Geleophysic Dysplasia with FBN1 Mutations. *Int J Gen Med* 2021; **14**: 1873-1880 [PMID: [34040419](#) DOI: [10.2147/IJGM.S306018](#)]
- 14 **Sakai LY**, Keene DR. Fibrillin protein pleiotropy: Acromelic dysplasias. *Matrix Biol* 2019; **80**: 6-13 [PMID: [30219651](#) DOI: [10.1016/j.matbio.2018.09.005](#)]
- 15 **de Bruin C**, Finlayson C, Funari MF, Vasques GA, Lucheze Freire B, Lerario AM, Andrew M, Hwa V, Dauber A, Jorge AA. Two Patients with Severe Short Stature due to a FBN1 Mutation (p.Ala1728Val) with a Mild Form of Acromicric Dysplasia. *Horm Res Paediatr* 2016; **86**: 342-348 [PMID: [27245183](#) DOI: [10.1159/000446476](#)]
- 16 **Faivre L**, Le Merrer M, Baumann C, Polak M, Chatelain P, Sulmont V, Cousin J, Bost M, Cordier MP, Zackai E, Russell K, Finidori G, Pouliquen JC, Munnich A, Maroteaux P, Cormier-Daire V. Acromicric dysplasia: long term outcome and evidence of autosomal dominant inheritance. *J Med Genet* 2001; **38**: 745-749 [PMID: [11694546](#) DOI: [10.1136/jmg.38.11.745](#)]
- 17 **Jin HS**, Song HY, Cho SY, Ki CS, Yang SH, Kim OH, Kim SJ. Acromicric Dysplasia Caused by a Novel Heterozygous Mutation of FBN1 and Effects of Growth Hormone Treatment. *Ann Lab Med* 2017; **37**: 92-94 [PMID: [27834076](#) DOI: [10.3343/alm.2017.37.1.92](#)]
- 18 **Cohen P**, Rogol AD, Deal CL, Saenger P, Reiter EO, Ross JL, Chernausek SD, Savage MO, Wit JM; 2007 ISS Consensus Workshop participants. Consensus statement on the diagnosis and treatment of children with idiopathic short stature: a summary of the Growth Hormone Research Society, the Lawson Wilkins Pediatric Endocrine Society, and the European Society for Paediatric Endocrinology Workshop. *J Clin Endocrinol Metab* 2008; **93**: 4210-4217 [PMID: [18782877](#) DOI: [10.1210/jc.2008-0509](#)]



Published by **Baishideng Publishing Group Inc**  
7041 Koll Center Parkway, Suite 160, Pleasanton, CA 94566, USA

**Telephone:** +1-925-3991568

**E-mail:** [bpgoffice@wjgnet.com](mailto:bpgoffice@wjgnet.com)

**Help Desk:** <https://www.f6publishing.com/helpdesk>

<https://www.wjgnet.com>

