

# World Journal of *Clinical Cases*

*World J Clin Cases* 2024 January 6; 12(1): 1-235



## Contents

Thrice Monthly Volume 12 Number 1 January 6, 2024

## OPINION REVIEW

- 1 Gut-targeted therapies for type 2 diabetes mellitus: A review  
*Xu TC, Liu Y, Yu Z, Xu B*

## MINIREVIEWS

- 9 Honeymoon phase in type 1 diabetes mellitus: A window of opportunity for diabetes reversal?  
*Mittal M, Porchezian P, Kapoor N*

## ORIGINAL ARTICLE

## Retrospective Cohort Study

- 15 Evaluating combined bevacizumab and XELOX in advanced colorectal cancer: Serum markers carcinoembryonic antigen, carbohydrate antigen 125, carbohydrate antigen 199 analysis  
*Zhou DB, Cheng J, Zhang XH*
- 24 Clinical value of precise rehabilitation nursing in management of cerebral infarction  
*Xu YN, Wang XZ, Zhang XR*

## Retrospective Study

- 32 Marker Ki-67 is a potential biomarker for the diagnosis and prognosis of prostate cancer based on two cohorts  
*Song Z, Zhou Q, Zhang JL, Ouyang J, Zhang ZY*
- 42 Natural history of asymptomatic gallbladder stones in clinic without beds: A long-term prognosis over 10 years  
*Sakai Y, Tsuyuguchi T, Ohyama H, Kumagai J, Kaiho T, Ohtsuka M, Kato N, Sakai T*
- 51 Clinical nursing value of predictive nursing in reducing complications of pregnant women undergoing short-term massive blood transfusion during cesarean section  
*Cheng L, Li LP, Zhang YY, Deng F, Lan TT*
- 59 Effect of cardiac rehabilitation care after coronary intervention on cardiac function recovery and negative mood in patients with myocardial infarction  
*Yang M, Huang YT, Hu XW, Wu CL*
- 68 Efficacy and safety of Nafamostat mesylate in patients with end-stage renal failure  
*Liu K, Li ZH*
- 76 Nursing effect of narrative nursing intervention on postoperative patients with severe lung cancer  
*Wen B, Liu Y, Min XX, Wang AQ*

**Observational Study**

- 86 Interaction between adolescent sleep rhythms and gender in an obese population  
*Wu NN, Yan GL, Zhang HY, Sun L, Hou M, Xu GM*

**SYSTEMATIC REVIEWS**

- 95 Endoscopic submucosal dissection *vs* transanal endoscopic surgery for rectal tumors: A systematic review and meta-analysis  
*Huang LW, Zhong Y*
- 107 Impact of frailty on outcomes of elderly patients undergoing percutaneous coronary intervention: A systematic review and meta-analysis  
*Wang SS, Liu WH*
- 119 Nasogastric tube syndrome: A Meta-summary of case reports  
*Juneja D, Nasa P, Chanchalani G, Jain R*

**CASE REPORT**

- 130 Erythrodermic mycosis fungoides: A case report  
*Xu WB, Zhang YP, Zhou SP, Bai HY*
- 136 Azacitidine maintenance therapy for blastic plasmacytoid dendritic cell neoplasm allograft: A case report  
*Tao LL, Wen HT, Wang ZY, Cheng J, Zhao L*
- 142 Congestive ischemic colitis successfully treated with anti-inflammatory therapy: A case report  
*Lee GW, Park SB*
- 148 Subarachnoid hemorrhage misdiagnosed as acute coronary syndrome leading to catastrophic neurologic injury: A case report  
*Lin JM, Yuan XJ, Li G, Gan XR, Xu WH*
- 157 Successful management of severe hypoglycemia induced by total parenteral nutrition in patients with hepatocellular injury: Three cases reports  
*Fang LZ, Jin HX, Zhao N, Wu YP, Shi YQ*
- 163 Endophthalmitis in silicone oil-filled eye: A case report  
*Yan HC, Wang ZL, Yu WZ, Zhao MW, Liang JH, Yin H, Shi X, Miao H*
- 169 Lung imaging characteristics in a patient infected with *Elizabethkingia miricola* following cerebral hemorrhage surgery: A case report  
*Qi PQ, Zeng YJ, Peng W, Kuai J*
- 176 Gastric IgG4-related disease mimicking a gastrointestinal stromal tumor in a child: A case report  
*Lin HCA, Lee KF, Huang TH*
- 180 Labial inverse dilaceration of bilateral maxillary central incisors: A case report  
*Wang JM, Guo LF, Ma LQ, Zhang J*

- 188** Changes in macrophage infiltration and podocyte injury in lupus nephritis patients with repeated renal biopsy: Report of three cases  
*Liu SY, Chen H, He LJ, Huang CK, Wang P, Rui ZR, Wu J, Yuan Y, Zhang Y, Wang WJ, Wang XD*
- 196** Primary acinic cell carcinoma of the breast: A case report and review of literature  
*Ding JS, Zhang M, Zhou FF*
- 204** Acupuncture for cervical dystonia associated with anxiety and depression: A case report  
*Zhang YT, Zhang JJ, Zha BX, Fan YQ, Xu YB, Yang J, Zhang QP*
- 210** Intestinal malrotation complicated with gastric cancer: A case report  
*Jia XH, Kong S, Gao XX, Cong BC, Zheng CN*
- 217** Addison's disease caused by adrenal tuberculosis may lead to misdiagnosis of major depressive disorder: A case report  
*Zhang TX, Xu HY, Ma W, Zheng JB*
- 224** Pleural empyema with endobronchial mass due to *Rhodococcus equi* infection after renal transplantation: A case report and review of literature  
*Liang GF, Chao S, Sun Z, Zhu KJ, Chen Q, Jia L, Niu YL*

**LETTER TO THE EDITOR**

- 232** Chronic venous insufficiency, could it be one of the missing pieces in the puzzle of treating pain?  
*Chang MC*

**ABOUT COVER**

Editorial Board Member of *World Journal of Clinical Cases*, Woon-Man Kung, MD, Associate Professor, Surgeon, Department of Exercise and Health Promotion, College of Kinesiology and Health, Chinese Culture University, Taipei 11114, Taiwan. [nskungwm@yahoo.com.tw](mailto:nskungwm@yahoo.com.tw)

**AIMS AND SCOPE**

The primary aim of *World Journal of Clinical Cases* (WJCC, *World J Clin Cases*) is to provide scholars and readers from various fields of clinical medicine with a platform to publish high-quality clinical research articles and communicate their research findings online.

WJCC mainly publishes articles reporting research results and findings obtained in the field of clinical medicine and covering a wide range of topics, including case control studies, retrospective cohort studies, retrospective studies, clinical trials studies, observational studies, prospective studies, randomized controlled trials, randomized clinical trials, systematic reviews, meta-analysis, and case reports.

**INDEXING/ABSTRACTING**

The WJCC is now abstracted and indexed in Science Citation Index Expanded (SCIE, also known as SciSearch®), Journal Citation Reports/Science Edition, Current Contents®/Clinical Medicine, PubMed, PubMed Central, Reference Citation Analysis, China Science and Technology Journal Database, and Superstar Journals Database. The 2023 Edition of Journal Citation Reports® cites the 2022 impact factor (IF) for WJCC as 1.1; IF without journal self cites: 1.1; 5-year IF: 1.3; Journal Citation Indicator: 0.26; Ranking: 133 among 167 journals in medicine, general and internal; and Quartile category: Q4.

**RESPONSIBLE EDITORS FOR THIS ISSUE**

Production Editor: Si Zhao; Production Department Director: Xiang Li; Editorial Office Director: Jin-Lei Wang.

**NAME OF JOURNAL**

*World Journal of Clinical Cases*

**ISSN**

ISSN 2307-8960 (online)

**LAUNCH DATE**

April 16, 2013

**FREQUENCY**

Thrice Monthly

**EDITORS-IN-CHIEF**

Bao-Gan Peng, Salim Surani, Jerzy Tadeusz Chudek, George Kontogeorgos, Maurizio Serati

**EDITORIAL BOARD MEMBERS**

<https://www.wjgnet.com/2307-8960/editorialboard.htm>

**PUBLICATION DATE**

January 6, 2024

**COPYRIGHT**

© 2024 Baishideng Publishing Group Inc

**INSTRUCTIONS TO AUTHORS**

<https://www.wjgnet.com/bpg/gerinfo/204>

**GUIDELINES FOR ETHICS DOCUMENTS**

<https://www.wjgnet.com/bpg/GerInfo/287>

**GUIDELINES FOR NON-NATIVE SPEAKERS OF ENGLISH**

<https://www.wjgnet.com/bpg/gerinfo/240>

**PUBLICATION ETHICS**

<https://www.wjgnet.com/bpg/GerInfo/288>

**PUBLICATION MISCONDUCT**

<https://www.wjgnet.com/bpg/gerinfo/208>

**ARTICLE PROCESSING CHARGE**

<https://www.wjgnet.com/bpg/gerinfo/242>

**STEPS FOR SUBMITTING MANUSCRIPTS**

<https://www.wjgnet.com/bpg/GerInfo/239>

**ONLINE SUBMISSION**

<https://www.f6publishing.com>



## Nasogastric tube syndrome: A Meta-summary of case reports

Deven Juneja, Prashant Nasa, Gunjan Chanchalani, Ravi Jain

**Specialty type:** Medicine, research and experimental

**Provenance and peer review:** Invited article; Externally peer reviewed.

**Peer-review model:** Single blind

**Peer-review report's scientific quality classification**

Grade A (Excellent): 0  
Grade B (Very good): 0  
Grade C (Good): 0  
Grade D (Fair): 0  
Grade E (Poor): 0

**P-Reviewer:** Arakawa-Sugueno L, Brazil

**Received:** October 28, 2023

**Peer-review started:** October 28, 2023

**First decision:** December 5, 2023

**Revised:** December 7, 2023

**Accepted:** December 18, 2023

**Article in press:** December 18, 2023

**Published online:** January 6, 2024



**Deven Juneja**, Department of Critical Care Medicine, Max Super Speciality Hospital, New Delhi 110017, India

**Prashant Nasa**, Department of Critical Care Medicine, NMC Specialty Hospital, Dubai 7832, United Arab Emirates

**Gunjan Chanchalani**, Department of Critical Care Medicine, Karamshibhai Jethabhai Somaiya Hospital and Research Centre, Mumbai 400022, India

**Ravi Jain**, Department of Critical Care Medicine, Mahatma Gandhi Medical College and Hospital, Jaipur 302022, Rajasthan, India

**Corresponding author:** Deven Juneja, DNB, MBBS, Director, Department of Critical Care Medicine, Max Super Speciality Hospital, 1 Press Enclave Road, Saket, New Delhi 110017, India. [devenjuneja@gmail.com](mailto:devenjuneja@gmail.com)

### Abstract

#### BACKGROUND

Since its description in 1790 by Hunter, the nasogastric tube (NGT) is commonly used in any healthcare setting for alleviating gastrointestinal symptoms or enteral feeding. However, the risks associated with its placement are often underestimated. Upper airway obstruction with a NGT is an uncommon but potentially life-threatening complication. NGT syndrome is characterized by the presence of an NGT, throat pain and vocal cord (VC) paralysis, usually bilateral. It is potentially life-threatening, and early diagnosis is the key to the prevention of fatal upper airway obstruction. However, fewer cases may have been reported than might have occurred, primarily due to the clinicians' unawareness. The lack of specific signs and symptoms and the inability to prove temporal relation with NGT insertion has made diagnosing the syndrome quite challenging.

#### AIM

To review and collate the data from the published case reports and case series to understand the possible risk factors, early warning signs and symptoms for timely detection to prevent the manifestation of the complete syndrome with life-threatening airway obstruction.

#### METHODS

We conducted a systematic search for this meta-summary from the database of PubMed, EMBASE, Reference Citation Analysis (<https://www.referencecitation-analysis.com/>) and Google scholar, from all the past studies till August 2023. The search terms included major MESH terms "Nasogastric tube", "Intubation,

Gastrointestinal", "Vocal Cord Paralysis", and "Syndrome". All the case reports and case series were evaluated, and the data were extracted for patient demographics, clinical symptomatology, diagnostic and therapeutic interventions, clinical course and outcomes. A datasheet for evaluation was further prepared.

## RESULTS

Twenty-seven cases, from five case series and 13 case reports, of NGT syndrome were retrieved from our search. There was male predominance (17, 62.96%), and age at presentation ranged from 28 to 86 years. Ten patients had diabetes mellitus (37.04%), and nine were hypertensive (33.33%). Only three (11.11%) patients were reported to be immunocompromised. The median time for developing symptoms after NGT insertion was 14.5 d (interquartile range 6.25-33.75 d). The most commonly reported reason for NGT insertion was acute stroke (10, 37.01%) and the most commonly reported symptoms were stridor or wheezing 17 (62.96%). In 77.78% of cases, bilateral VC were affected. The only treatment instituted in most patients (77.78%) was removing the NG tube. Most patients (62.96%) required tracheostomy for airway protection. But 8 of the 23 survivors recovered within five weeks and could be decannulated. Three patients were reported to have died.

## CONCLUSION

NGT syndrome is an uncommon clinical complication of a very common clinical procedure. However, an under-reporting is possible because of misdiagnosis or lack of awareness among clinicians. Patients in early stages and with mild symptoms may be missed. Further, high variability in the presentation timing after NGT insertion makes diagnosis challenging. Early diagnosis and prompt removal of NGT may suffice in most patients, but a significant proportion of patients presenting with respiratory compromise may require tracheostomy for airway protection.

**Key Words:** Nasogastric tube; Nasogastric tube syndrome; Ryle's tube; Sofferman syndrome; Vocal cord paralysis

©The Author(s) 2024. Published by Baishideng Publishing Group Inc. All rights reserved.

**Core Tip:** Nasogastric tube (NGT) insertion is a commonly employed procedure in hospitalised patients. Although it is considered a minor and safe procedure, complications may occur due to its invasive nature. Immediate complications while NGT insertion may be easily recognised, but long-term complications may be missed and are rarely reported. Most of the complications are minor and can be rapidly detected, but rarely, life-threatening complications like NGT syndrome have also been reported. NGT syndrome has been described decades ago, but till now, very few adult cases have been reported in the literature. Timely recognition and a simple intervention of NGT removal may be life-saving, and most patients may show complete recovery. However, a significant proportion of these patients may require tracheostomy for airway protection until the vocal cord palsy recovers.

**Citation:** Juneja D, Nasa P, Chanchalani G, Jain R. Nasogastric tube syndrome: A Meta-summary of case reports. *World J Clin Cases* 2024; 12(1): 119-129

**URL:** <https://www.wjgnet.com/2307-8960/full/v12/i1/119.htm>

**DOI:** <https://dx.doi.org/10.12998/wjcc.v12.i1.119>

## INTRODUCTION

Nasogastric tube (NGT) insertion is a common procedure for hospitalised patients. Although NGT insertion is considered a simple procedure, it may lead to complications because of its invasive nature. Elderly, critically ill and those with underlying comorbidities may be prone to develop these complications, but these are the patients who may also benefit the most from NGT insertion. The commonly reported complications of NGT include malposition, knotting or coiling of the tube, and local trauma or bleeding[1,2]. Most of these complications occur during NGT insertion and are generally mild and easily recognised. Severe complications like oesophageal rupture have also been reported. In patients with long-standing NGT tubes, ulceration or necrosis of nasal alar, epistaxis, congestion, rhinosinusitis, and acute otitis media have also been reported[2-4]. Other complications associated with NGT include impaired lower oesophageal sphincter function, leading to increased gastroesophageal reflux (GER) and aspiration pneumonitis[2]. However, certain long-term complications associated with NGT, like the NGT syndrome, may be challenging to recognise and rarely reported (Tables 1 and 2)[5-22].

The NGT syndrome is a serious and potentially life-threatening complication of NGT insertion. Even though the first description of this syndrome was in a case series of 12 patients published by Iglaue and Molt[23] in 1939, the term NGT syndrome was coined by Sofferman *et al*[6] in 1990. They described NGT syndrome as the development of throat pain and abductor dysfunction of vocal cords (VC) secondary to the presence of the NGT. It is suspected to result from ulceration and necrosis of the posterior cricoid region, leading to VC abduction paralysis[6].

Table 1 Base-line parameters of patients developing “nasogastric tube syndrome”

Case number	Author	Year of publication	Country of origin	Number of cases	Age	Sex	Comorbidities	Immunocompromised	Indication for NGT insertion
1	Sofferman and Hubbell [5]	1981	United States	4	60	Female	Cecal cancer	None	Perioperative
2	Sofferman and Hubbell [5]	1981	United States	4	74	Male	None	None	CVA
3	Sofferman and Hubbell [5]	1981	United States	4	34	Male	None	None	Severe TBI
4	Sofferman and Hubbell [5]	1981	United States	4	75	Female	Osler-Weber-Rendu disease, Anemia	None	Post-operative
5	Sofferman <i>et al</i> [6]	1990	United States	4	28	Male	DM, HTN, CKD	Yes (post-renal transplantation)	Perioperative period
6	Sofferman <i>et al</i> [6]	1990	United States	4	42	Male	DM, HTN, CKD, CAD	Yes (post-renal transplantation)	Perioperative period
7	Sofferman <i>et al</i> [6]	1990	United States	4	36	Male	DM, CKD	No	AMS
8	Sofferman <i>et al</i> [6]	1990	United States	4	45	Female	DM, CKD	Yes (post-renal transplantation)	Acute pancreatitis
9	Apostolakis <i>et al</i> [7]	2001	United States	2	77	Male	None	No	Toxic megacolon
10	Apostolakis <i>et al</i> [7]	2001	United States	2	73	Male	DM, HTN, COPD	No	GI bleed
11	To <i>et al</i> [8]	2001	Hong Kong	1	63	Male	NA	NA	Perioperative period
12	Nehru <i>et al</i> [9]	2003	Kuwait	1	60	Male	DM, HTN	No	Acute stroke
13	Sanaka <i>et al</i> [10]	2004	Japan	1	85	Male	HTN	No	Gastrointestinal obstruction
14	Isozaki <i>et al</i> [11]	2005	Japan	2	73	Male	NA	NA	Dementia
15	Isozaki <i>et al</i> [11]	2005	Japan	2	77	Male	NA	NA	Acute stroke
16	Marcus <i>et al</i> [12]	2006	Israel	1	72	Male	None	No	Traumatic brain injury
17	Vielva del Campo <i>et al</i> [13]	2010	Spain	1	70	Female	DM, Parkinsonism	No	Acute stroke
18	Kim <i>et al</i> [14]	2015	Korea	1	86	Female	DM, HTN, Parkinsonism	NA	Severe pneumonia with septic shock
19	Sano <i>et al</i> [15]	2016	Japan	1	76	Male	No	No	GI obstruction
20	Perera [16]	2018	Sri Lanka	1	76	Female	NA	NA	Acute stroke
21	Kanbayashi <i>et al</i> [17]	2021	Japan	1	77	Male	HTN, AF	No	Acute stroke
22	Yildiz <i>et al</i> [18]	2021	Türkiye	1	73	Male	NA	NA	Perioperative
23	Taira <i>et al</i> [19]	2022	Japan	1	78	Male	No	NA	AMS
24	Cui <i>et al</i> [20]	2023	China	1	65	Female	HTN, Parkinsonism	No	Cervical cord injury
25	Nihira <i>et al</i> [21]	2023	Japan	1	86	Female	None	No	Acute stroke
26	Paul <i>et al</i> [22]	2023	Qatar	2	78	Female	DM, HTN	No	Perioperative



27	Paul <i>et al</i> [22]	2023	Qatar	2	79	Female	DM, CAD	No	AMS
----	------------------------	------	-------	---	----	--------	---------	----	-----

NGT: Nasogastric syndrome; DM: Diabetes mellitus; HTN: Hypertension; CKD: Chronic kidney disease; CAD: Coronary artery disease; AMS: Altered mental status; NA: Not available; COPD: Chronic obstructive pulmonary diseases; CVA: Cerebrovascular accident; TBI: Traumatic brain injury; GI: Gastrointestinal; AF: Atrial fibrillation.

The exact cause of NGT syndrome remains unknown. However, multiple mechanisms have been postulated, a combination of which may lead to the development of NGT syndrome. The first reason could be the dynamic and delicate larynx being constantly irritated by the semi-rigid NGT when the patient swallows or coughs. Secondly, the tonic contractile cricopharyngeus muscle continually presses the NGT against the posterior cricoid cartilage lamina, forming pressure ulcers. Thirdly, gravity pulls the larynx posteriorly in a supine patient, causing the NGT to be stuck between the rigid cricoid cartilage and the anterior cervical spine[5]. Finally, another proposed mechanism is the ischemia secondary to the compression of blood vessels supplying the posterior cricoarytenoid muscle by the NGT[11]. All these may lead to NGT causing persistent pressure, trauma and irritation on the posterior cricoid lamina, leading to ischemic necrosis, ulceration, and infection. This infection and necrosis of the posterior cricoid cartilage affect the function of the posterior cricoarytenoid muscles, which in turn affects the capacity of the larynx to abduct the VC, leading to respiratory compromise[5,11].

Diagnosis of NGT syndrome may be missed because of lack of awareness, non-specific symptomatology and delayed presentation after NGT insertion. Hence, only a few cases have been reported in the literature. Through this meta-summary, we intend to review and collate the available case reports and series data to understand the possible risk factors, signs and symptoms, and the clinical course of patients with NGT syndrome.

## MATERIALS AND METHODS

We conducted a systematic search for this meta-summary from the databases of PubMed, EMBASE, Reference Citation Analysis (<https://www.referencecitationanalysis.com/>) and Google scholar, from all the past studies till August 2023. The search terms included major MESH terms "Nasogastric tube", "Intubation, Gastrointestinal", "Vocal Cord Paralysis", and Syndrome. Further, it was filtered for the case reports published in the English language and on adult (> 18 years) humans. We manually screened all the search results and included the relevant literature for NGT syndrome. Duplicate articles from different search databases were excluded manually (Figure 1).

All the case reports and case series were evaluated, and the data were extracted for patient demographics, clinical symptomatology, diagnostic and therapeutic interventions, clinical course and outcomes. A datasheet for evaluation was further prepared.

### Data Analysis

We prepared and evaluated the datasheet with the help of Excel and Microsoft Office 2019. Categorical variables were presented as frequency and percentage. Mean (SD) or median [interquartile range (IQR)] was used for continuous variables as appropriate. We applied a non-parametric correlational statistical test to test the non-parametric statistical hypothesis, as found appropriate. A *P* value of < 0.05 was deemed significant. Unless otherwise indicated, all the statistical analyses were done using SPSS (version 25.0, IBM SPSS Inc., Chicago, IL, United States). Tabulation and final documentation were done using MS Office software (MS Office 2019, Microsoft Corp, WA, United States).

## RESULTS

Twenty-seven cases, from five case series and 13 case reports, of NGT syndrome were retrieved from our search, and published in literature till August 2023[6-22]. There was male predominance (17, 62.96%), and maximum number of cases were reported from the United States (10, 37.04%) and Japan (7, 25.93%). The age at presentation ranged from 28 to 86 years, with 22 (81.48%) aged 60 years or above. The median reported age was 73 years (IQR 61.5-77.0). Ten patients had diabetes mellitus (37.04%), and nine were hypertensive (33.33%). Other commonly reported comorbidities included chronic kidney disease (2, 7.4%), parkinsonism (2, 7.4%) and coronary artery disease (1, 3.7%). Only three (11.11%) patients were reported to be immunocompromised. The median time for developing symptoms after NGT insertion was 14.5 d (IQR 6.25-33.75 d).

The most commonly reported reason for NGT insertion was acute stroke (10, 37.01%), followed by peri-operative insertion (7, 25.93%) and altered mental status (3, 11.11%). The most commonly reported symptoms were stridor or wheezing 17 (62.96%), throat pain (7, 25.9%) and breathlessness (4, 14.8%). In 21, 77.78% of cases, bilateral VC were affected but in 3 patients (11.1%), only unilateral involvement was reported.

The only treatment instituted in most patients (21, 77.78%) was removing the NGT. However, few patients were also treated with systemic (7, 25.9%) or inhaled (4, 14.8%) steroids. Most patients (17, 62.96%) required tracheostomy for airway protection. But 8 of the 23 survivors recovered within five weeks and could be decannulated. Three patients (11.11%) were reported to have died (Table 3).

Table 2 Clinical course of patients with nasogastric syndrome

Case number	Presenting symptoms	Type of feed NGT	Days after which symptoms developed	Side of vocal cords involved	Laryngoscopy	Biopsy	Culture	Therapeutic interventions	Tracheostomy	Outcome	Sequelae
1	Voice change, throat pain	NG	3	B/L	Vocal cord edema, post cricoid abcess	None	None	NG removal, steroids, antibiotics	Yes	Alive	Recovered in 7 d and discharged
2	Sore throat, stridor	NG	8	B/L	Vocal cod edema, arytenoid edema, post cricoid ulceration	None	None	NG removal	Yes	Alive	Recovery in 14 d
3	Throat discomfort, aspiration,	NG	30	B/L	Vocal cord edema and paralysis, postcricoid edema	<sup>1</sup>	None	NG removal, gastrostomy placement	Yes	Alive	Gastrostomy support required even after 12 wk follow up
4	Stridor, troat pain	NG	9	B/L	Vocal cord paralyis and arytenoid edema	None	None	Removal of tube	Yes	Alive	Recovered completely 15 d after tube removal
5	Stridor, throat pain	NG	18	B/L	Vocal cord edema and post cricoid ulcer	NA	Coagulase positive staph aureus	NGT removal	Yes	Alive	One month after trach – VC mobile, but residual arytenoid edema
6	Throat pain, fever	NG	5		Vocal cord edema and post cricoid ulcer	NA	Streptococcus	NGT removal	No	Alive	
7	Stridor	NA	16		Vocal cord edema and post cricoid ulcer	NA	None		Yes	Died	
8	Stridor, fever	NG	NA	B/L	B/L vocal cord edema	NA	Candida albicans	NGT removal	Yes	Alive	54 d after – both VC recovered sufficient abductor mobility and decannulation done
9	Stridor	NG	2	B/L	Impaired vocal cord abduction bilaterally. With edema. Postcricoid necrotic ulcer was noted, 1.5 cm in width	No	Mixed bacterial growth	NGT removal	Yes	Alive	No recovery till 1 month
10	SOB	NG	2	B/L	Isolated and complete abductor dysfunction of his vocal cords. With edema. Postcricoid ulceration	No	Mixed bacterial growth	NGT removal, steroids	Yes	Alive	Decannulated after 5 wk
11	Cough, sore throat	NG	9	Left VC paralysis	Left arytenoid fold swollen	No	None	NGT removal	No	Alive	None
12	Incidental	NG	140	Lt	Left- inhibited abductor movement	Yes	None	NG removal	Yes	Alive	Persistent VC palsy
13	Stridor, SOB	Long intestinal	4	B/L	Mild arytenoid edema	No	None	Removal of tube	Yes	Alive	Decannulated after 3 wk

		tube									
14	Stridor	NG	730	B/L	B/L VC edema	No	None	NA	No	Died	
15	Stridor	NG	75	B/L	B/L VC edema	No	None	Frequent NG changes	No	Died	
16	Stridor, tachypnea, SOB	NG	30	B/L	Right VC paralysis, impaired left VC mobility, B/L edema	No	None	NGT removal, steroids	No	Alive	None
17	Stridor, SOB	NG	35	B/L	Bilateral arytenoid edema	No	None	NGT removal	Yes	Yes	Decannulated after 20 d
18	Stridor, desaturation, AMS	NG	15	B/L	Impaired abduction of the Vocal cords	No	None	NGT removal, steroids	No	Alive	None
19	Stridor, throat pain, desaturation	Long intestinal tube	6	B/L	B/L arytenoid edema	No	None	NGT removal	Yes	Alive	Decannulated after 4 wk
20	Stridor, throat pain, Respiratory distress	NG	14	B/L	Bilateral vocal cord palsy with severely compromised airway.	No	None	NGT removal, steroids	Yes	Alive	Improved after 4 wk
21	Stridor	NG	14	B/L	B/L VC palsy	No	None	NGT removal	No	Alive	None
22	Stridor, slurring of speech, sore throat, difficulty in swallowing, desaturation	NG	7	B/L	B/L vocal cord edema	No	None	NGT removal, steroids	Yes	Alive	A month to complete recovery
23	Wheezing, hoarseness	Nasointestinal ileus tube	3	B/L	Left arytenoid edema and erythema	No	None	Tube removal, steroids	No	Alive	None
24	Incidental	NG	15	B/L	Severe edema	No	None	Inhaled steroids	Yes	Alive	Decannulated after 5 wk
25	Stridor	NG	105	B/L	BL laryngeal edema	No	None	NGT removal	Yes	Alive	None
26	Desaturation	NG	180	Rt	Rt VC palsy	No	None	Neb steroids	NA	Alive	None
27	Stridor	NG	760	Rt	Rt VC palsy	No	None	Neb steroids	NA	Alive	None

<sup>1</sup>Proliferative interarytenoid granulation tissue and no abscess.

NG: Nasogastric; B/L: Bilateral; NA: Not available; SOB: Shortness of breath; VC: Vocal cords; NGT: Nasogastric tube.

## DISCUSSION

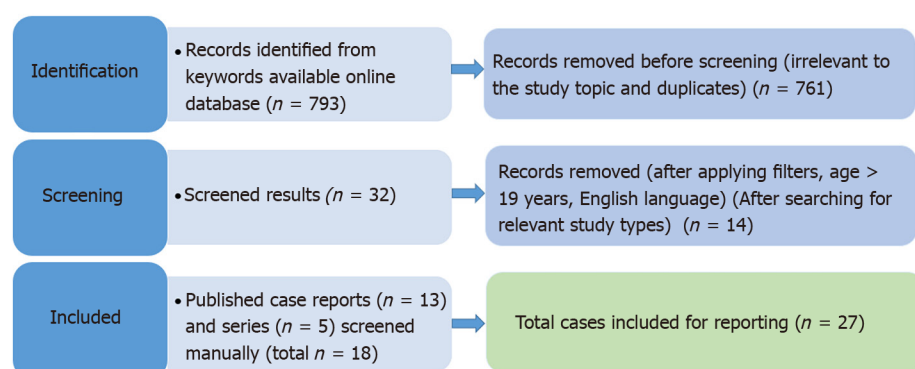
The present review included data from 27 reported cases with a diagnosis of NGT syndrome, published in last five decades. More than 80% of patients were aged 60 years and above and 37.04% were reported to be diabetics. There was a considerable heterogeneity in the timing of onset of symptoms from NGT insertion (ranging 2 d to 2 years). In most of the patients, the only intervention required was NGT removal. Even though 62.96% required tracheostomy for airway protection, most of them showed complete recovery, with 8 of 23 survivors getting tracheostomy decannulation within five weeks.

**Table 3 Clinical course of patients with nasogastric syndrome**

Indication for NGT	Number of patients, n (%)
Acute stroke	10 (37.04)
Peri-operative period	7 (25.93)
Altered mental status	4 (14.81)
Gastrointestinal obstruction	2 (7.41)
Traumatic brain or spinal cord injury	2 (7.41)
GI bleed	1 (3.7)
Acute pancreatitis	1 (3.7)
Severe pneumonia with septic shock	1 (3.7)
Toxic megacolon	1 (3.7)
Presenting symptoms	
Stridor	17 (62.96)
Sore throat/throat pain	7 (25.93)
Shortness of breath	4 (14.8)
Desaturation	3 (11.11)
Speech disturbance	4 (14.8)
Swallowing difficulty	3 (11.11)
Cough	1 (3.7)
Altered sensorium	1 (3.7)
Incidental	2 (7.41)
Type of feed NGT	
Nasogastric	23 (85.19)
Long intestinal tube	1 (3.7)
Naso-intestinal ileus tube	2 (7.41)
NA	1 (3.7)
Vocal cord involved	
Bilateral	21 (77.78)
Left	2 (7.41)
Right	2 (7.41)
Therapeutic interventions	
Tube removal	21 (77.78)
Systemic steroids	7 (25.93)
Inhalational steroids	4 (14.81)
Frequent change of nasogastric tube	1 (3.7)
Tracheostomy procedure	
Yes	17 (62.96)
No	8 (29.63)
NA	2 (7.41)
Final outcome	
Alive	23 (85.19)
Dead	3 (11.11)
NA	1 (3.7)

Reported sequelae of NGT syndrome	
Improved after 3 wk	4 (14.81)
Improved after 4 wk	2 (7.41)
Partial improvement after 4 wk	1 (3.7)
Improved after 5 wk	2 (7.41)
Improved after 8 wk	2 (7.41)
No recovery till 4 wk	1 (3.7)
Persistent vocal cord palsy	2 (7.41)
None reported	8 (29.63)

NG: Nasogastric; NGT: Nasogastric tube; NA: Not available; GI: Gastrointestinal.



DOI: 10.12998/wjcc.v12.i1.119 Copyright ©The Author(s) 2024.

**Figure 1** The preferred reporting items for systematic reviews and meta-analyses flow diagram of the selected literature.

NGT syndrome is a rare but potentially life-threatening complication of NGT insertion. It may be stipulated that the incidence of NGT syndrome may be much higher than reported and the diagnosis is largely missed, as many patients may have minor symptoms or are misdiagnosed. Further, many patients requiring NGT are too sick to report any symptoms and hence, the diagnosis largely depends on the suspicion of treating physicians. Wolff and Kessler[24], evaluated larynges of 149 patients by performing a post-mortem, who have had NGT in situ for more than 48 h and reported that 35% had post-cricoid ulcers present[24]. This may suggest, in critically ill patients requiring NGT for more than 48 h, the incidence may be much higher, warranting a high index of suspicion in such patients.

The non-specific symptoms related to NGT syndrome are frequently missed or attributed to other common diseases like asthma or infection. Throat pain has been described as an important and early presenting complaint and is a component of the classical triad defined by Sofferman *et al*[6]. However, critically ill patients or those with altered mental status may not be able to complain of pain and hence the diagnosis may be missed or delayed. In our review, throat pain was reported in only 7, 25.93% of patients, and stridor was the most commonly reported symptom, present in almost 17, 62.96% of patients. As most of these patients had neurological dysfunction or were critically ill, throat pain might not have been reported. Hence, the presence of stridor or wheeze in a patient with NGT should alert the treating physician towards the possibility of NGT syndrome. Symptoms like breathlessness, desaturation or respiratory distress develop late and are suggestive of advanced disease requiring prompt medical intervention. If early signs are missed, patients with NGT syndrome may present with life-threatening respiratory distress, which may require emergency tracheostomy to maintain the airway.

The presence of comorbidities may also affect the incidence of NGT syndrome. Diabetes Mellitus has been reported to increase the risk of developing NGT syndrome, which was also reported to be present in 10, 37.04% of cases in our review [6]. The other reported risk factors include the presence of GER leading to an acidic environment in the post-cricoid region and the presence of NGT at the level of the lower oesophageal sphincter which may reduce its function[25].

Classically NGT syndrome has been described to affect both the VC[6]. However, as the awareness regarding this syndrome increased over the years, multiple unilateral varieties of NGT syndrome have been described[8,9,22]. Three patients (11.11%) in our review had only unilateral VC involvement.

Symptoms of NGT syndrome have been shown to develop even two days after NGT insertion[2] but may be delayed up to two years[11]. This heterogeneity in presentation and lack of predictability makes the diagnosis more challenging.

Diagnosis of NGT syndrome requires direct visualisation of the VC and the post-cricoid area. Culture or biopsy may not be required for the diagnosis but may be helpful in ruling out any secondary infection and instituting appropriate antibiotics. As the diagnosis requires an invasive procedure, patients with minor symptoms like sore throat and

hoarseness of voice may not warrant such a procedure and hence may be missed.

The only treatment instituted in most of the patients (73.9%) was the removal of the NGT. Oral ingestion of food should be avoided as it may lead to aspiration due to VC palsy. Re-insertion of a softer NGT of a smaller size has also been shown to prevent the development of NGT syndrome[17]. Although NGT syndrome has been reported even with smaller size tubes, the effect of size remains unknown because most of the case reports on NGT syndrome did not mention the size of NGT used[22]. Although it seems prudent that the use of a smaller and softer NGT, if the patient's condition allows, may prevent the development of NGT syndrome.

Even though inhaled or intravenous steroids were used in some patients, its role remains debatable. However, it may be instrumental in reducing inflammation and may provide early symptomatic relief in patients with severe symptoms. But, the risk of secondary infections must be kept in mind while prescribing corticosteroids in critically ill patients. Hence, corticosteroids if used, should be for short duration and considering risk-benefit in patients with severe airway obstruction.

Complications of NGT syndrome include acute respiratory failure and the formation of retro-cricoid abscesses. Airway compromise secondary to VC palsy may necessitate tracheostomy for maintaining the airway. The presence of an endotracheal tube may prevent VC healing. Hence, tracheostomy may be preferred in such patients. The tracheostomy tube should be removed only after the resolution of VC palsy, which, in most of these cases, occur between few weeks to months. In our review, even though most of the patients required tracheostomy, they could be successfully decannulated over the next few weeks.

There are several strengths to our analysis. We have included all the published cases on NGT syndrome till date. As we selected only adult cases, the data collected is more homogenous and applicable to adult healthcare. This being a meta-summary of case series and case reports, it has some inherent limitations. The data was collected from case series and case reports, and thus, there was no control arm, studies were heterogeneous, and prone to high risk of bias and missing data. This may affect the generalisability of the results. The present study is a meta-summary of published case reports and series, and there are significant deficits of data in these papers, and data regarding any dysphagia assessment, probe usage, or assistance provided by rehabilitation teams was not present and scarcely reported. Hence, this could not be commented on in our study. However, as these are very important aspects of understanding the natural history and course of NGT syndrome, we also recommend including these data in future research or report papers.

## CONCLUSION

NGT syndrome is an uncommon clinical complication of a very common clinical procedure. However, an underreporting is possible because of misdiagnosis, or lack of awareness among clinicians. Patients in early stages and with mild symptoms may be missed. Further, high variability in the timing of presentation after NGT insertion makes diagnosis challenging. Hence, a high index of suspicion is warranted to make a diagnosis. Early diagnosis and prompt removal of NGT may suffice in most patients, but a significant proportion of patients presenting with respiratory compromise may require tracheostomy for airway protection. The long-term outcomes remain favourable with complete resolution of symptoms in most of the cases.

## ARTICLE HIGHLIGHTS

### Research background

The risks associated with nasogastric tube (NGT) placement are often underestimated. Upper airway obstruction with a NGT is an uncommon but potentially life-threatening complication.

### Research motivation

NGT syndrome is potentially life-threatening, and early diagnosis is the key to prevention of fatal upper airway obstruction. Lack of specific signs and symptoms and inability to prove temporal relation with NGT insertion, has made diagnosing the syndrome quite challenging.

### Research objectives

To review and collate the data from the published case reports and case series, to understand the possible risk factors, early warning signs and symptoms for timely detection to prevent the manifestation of the complete syndrome with life-threatening airway obstruction.

### Research methods

We conducted a systematic search, from the database of PubMed from all the past studies till August 2023. The search terms included major MESH terms "Nasogastric tube", "Intubation, Gastrointestinal", "Vocal Cord Paralysis", and "Syndrome". Further, it was filtered for the case reports published in the English language and on adult (> 18 years) humans.



## Research results

Twenty-seven cases, from five case series and 13 case reports, of NGT syndrome were retrieved. There was male predominance (62.96%), and the age at presentation ranged from 28 to 86 years. The median time taken for developing symptoms after NGT insertion was 14.5 d (interquartile range 6.25-33.75 d). The most commonly reported reason for NGT insertion was acute stroke (37.01%), and the most commonly reported symptoms were stridor or wheezing (62.96%). The only treatment instituted in most of patients (77.78%) was removing the NGT. The majority (62.96%) of patients required tracheostomy for airway protection, but only three deaths were reported.

## Research conclusions

NGT syndrome is an uncommon clinical complication of a very common clinical procedure. Early diagnosis and prompt removal of NGT may suffice in most patients, but a significant proportion of patients presenting with respiratory compromise may require tracheostomy for airway protection.

## Research perspectives

A high index of suspicion is required for diagnosis of NGT syndrome. Further studies may aid in identifying the risk factors and help in early diagnosis.

## FOOTNOTES

**Author contributions:** Juneja D and Nasa P conceptualized and designed the article; Juneja D, Nasa P, Chanchalani G, and Jain R performed acquisition of data, analysis and interpretation of data, and drafted the article; Chanchalani G and Jain R revised the article; All authors have read and approved the final manuscript.

**Conflict-of-interest statement:** All the authors report no relevant conflicts of interest for this article.

**PRISMA 2009 Checklist statement:** The authors have read the PRISMA 2009 Checklist, and the manuscript was prepared and revised according to the PRISMA 2009 Checklist.

**Open-Access:** This article is an open-access article that was selected by an in-house editor and fully peer-reviewed by external reviewers. It is distributed in accordance with the Creative Commons Attribution NonCommercial (CC BY-NC 4.0) license, which permits others to distribute, remix, adapt, build upon this work non-commercially, and license their derivative works on different terms, provided the original work is properly cited and the use is non-commercial. See: <https://creativecommons.org/licenses/by-nc/4.0/>

**Country/Territory of origin:** India

**ORCID number:** Deven Juneja 0000-0002-8841-5678; Prashant Nasa 0000-0003-1948-4060; Gunjan Chanchalani 0000-0001-8429-8526; Ravi Jain 0000-0001-9260-479X.

**S-Editor:** Li L

**L-Editor:** A

**P-Editor:** Li L

## REFERENCES

- 1 Agarwala S, Dave S, Gupta AK, Mitra DK. Duodeno-renal fistula due to a nasogastric tube in a neonate. *Pediatr Surg Int* 1998; **14**: 102-103 [PMID: 9880713 DOI: 10.1007/s003830050451]
- 2 Newton M, Burnham WR, Kamm MA. Morbidity, mortality, and risk factors for esophagitis in hospital inpatients. *J Clin Gastroenterol* 2000; **30**: 264-269 [PMID: 10777185 DOI: 10.1097/00004836-200004000-00012]
- 3 Lai PB, Pang PC, Chan SK, Lau WY. Necrosis of the nasal ala after improper taping of a nasogastric tube. *Int J Clin Pract* 2001; **55**: 145 [PMID: 11321856 DOI: 10.1111/j.1742-1241.2001.tb10997.x]
- 4 Stein M, Caplan ES. Nosocomial sinusitis: a unique subset of sinusitis. *Curr Opin Infect Dis* 2005; **18**: 147-150 [PMID: 15735419 DOI: 10.1097/01.qco.0000160904.56566.4a]
- 5 Sofferman RA, Hubbell RN. Laryngeal complications of nasogastric tubes. *Ann Otol Rhinol Laryngol* 1981; **90**: 465-468 [PMID: 7305201 DOI: 10.1177/000348948109000510]
- 6 Sofferman RA, Haisch CE, Kirchner JA, Hardin NJ. The nasogastric tube syndrome. *Laryngoscope* 1990; **100**: 962-968 [PMID: 2395406 DOI: 10.1288/00005537-199009000-00010]
- 7 Apostolakis LW, Funk GF, Urdaneta LF, McCulloch TM, Jeyapalan MM. The nasogastric tube syndrome: two case reports and review of the literature. *Head Neck* 2001; **23**: 59-63 [PMID: 11190859 DOI: 10.1002/1097-0347(200101)23:1<59::AID-HED9>3.0.CO;2-A]
- 8 To EW, Tsang WM, Pang PC, Cheng JH, Lai EC. Nasogastric-tube-induced unilateral vocal cord palsy. *Anaesthesia* 2001; **56**: 695-696 [PMID: 11437789 DOI: 10.1046/j.1365-2044.2001.02137-8.x]
- 9 Nehru VI, Al Shammari HJ, Jaffer AM. Nasogastric tube syndrome: the unilateral variant. *Med Princ Pract* 2003; **12**: 44-46 [PMID: 12566968 DOI: 10.1159/000068162]
- 10 Sanaka M, Kishida S, Yoritaka A, Sasamura Y, Yamamoto T, Kuyama Y. Acute upper airway obstruction induced by an indwelling long

- intestinal tube: attention to the nasogastric tube syndrome. *J Clin Gastroenterol* 2004; **38**: 913 [PMID: 15492616 DOI: 10.1097/00004836-200411000-00020]
- 11 **Isozaki E**, Tobisawa S, Naito R, Mizutani T, Hayashi H. A variant form of nasogastric tube syndrome. *Intern Med* 2005; **44**: 1286-1290 [PMID: 16415551 DOI: 10.2169/internalmedicine.44.1286]
  - 12 **Marcus EL**, Caine Y, Hamdan K, Gross M. Nasogastric tube syndrome: a life-threatening laryngeal obstruction in a 72-year-old patient. *Age Ageing* 2006; **35**: 538-539 [PMID: 16754698 DOI: 10.1093/ageing/afn042]
  - 13 **Vielva del Campo B**, Moráis Pérez D, Saldaña Garrido D. Nasogastric tube syndrome: a case report. *Acta Otorrinolaringol Esp* 2010; **61**: 85-86 [PMID: 20061208 DOI: 10.1016/j.otorri.2009.03.006]
  - 14 **Kim T**, Kim SM, Sohn SB, Lee YH, Lim SY, Sim JK. Nasogastric Tube Syndrome: Why Is It Important in the Intensive Care Unit? *Acute Crit Care* 2015; **30**: 231-233 [DOI: 10.4266/kjccm.2015.30.3.231]
  - 15 **Sano N**, Yamamoto M, Nagai K, Yamada K, Ohkohchi N. Nasogastric tube syndrome induced by an indwelling long intestinal tube. *World J Gastroenterol* 2016; **22**: 4057-4061 [PMID: 27099450 DOI: 10.3748/wjg.v22.i15.4057]
  - 16 **Perera HMM**. NG tube syndrome: a case report of a rare complication of NG tube. *Ceylon Med J* 2018; **63**: 192-193 [PMID: 30669705 DOI: 10.4038/cmj.v63i4.8773]
  - 17 **Kanbayashi T**, Tanaka S, Uchida Y, Hatanaka Y, Sonoo M. Nasogastric Tube Syndrome: The Size and Type of the Nasogastric Tube May Contribute to the Development of Nasogastric Tube Syndrome. *Intern Med* 2021; **60**: 1977-1979 [PMID: 33518566 DOI: 10.2169/internalmedicine.6258-20]
  - 18 **Yildiz E**, Öner Ö, Koçak Ö, Yildirim N. A case report: probably concurrent nasogastric tube syndrome and cerebrovascular disease in a postoperative patient. *BSJ Health Sci* 2021; **4**: 153-155 [DOI: 10.19127/bshealthscience.803290]
  - 19 **Taira K**, Koyama S, Morisaki T, Fukuhara T, Donishi R, Fujiwara K. Nasogastric Tube Syndrome: A Severe Complication of Nasointestinal Ileus Tube. *Case Rep Gastroenterol* 2022; **17**: 191-196 [PMID: 37261032 DOI: 10.1159/000526715]
  - 20 **Cui W**, Xiang J, Deng X, Qin Z. Difficult tracheostomy decannulation related to nasogastric tube syndrome: A case report. *Int J Surg Case Rep* 2023; **110**: 108734 [PMID: 37660494 DOI: 10.1016/j.ijscr.2023.108734]
  - 21 **Nihira T**, Fukaguchi K, Taguchi A, Fukui H, Sekine I, Yamamoto D, Moriya H, Yamagami H. Bilateral vocal cord palsy induced by long-term use of small-bore nasogastric tube. *Acute Med Surg* 2023; **10**: e872 [PMID: 37469376 DOI: 10.1002/ams2.872]
  - 22 **Paul T**, Shdid RKA, Khan SHU. Unilateral Variant of NGT Syndrome: An Uncommon Complication of a Very Common Intervention. *Gerontol Geriatr Med* 2023; **9**: 23337214231172626 [PMID: 37152208 DOI: 10.1177/23337214231172626]
  - 23 **Iglauer S**, Molt WF. LXXI Severe Injury to the Larynx Resulting from the Indwelling Duodenal Tube (Case Reports). *Ann Otol Rhinol Laryngol* 1939; **48**: 886-904 [DOI: 10.1177/000348943904800402]
  - 24 **Wolff AP**, Kessler S. Iatrogenic injury to the hypopharynx and cervical esophagus: an autopsy study. *Ann Otol Rhinol Laryngol* 1973; **82**: 778-783 [PMID: 4761038 DOI: 10.1177/000348947308200605]
  - 25 **Dotson RG**, Robinson RG, Pingleton SK. Gastroesophageal reflux with nasogastric tubes. Effect of nasogastric tube size. *Am J Respir Crit Care Med* 1994; **149**: 1659-1662 [PMID: 8004326 DOI: 10.1164/ajrccm.149.6.8004326]





Published by **Baishideng Publishing Group Inc**  
7041 Koll Center Parkway, Suite 160, Pleasanton, CA 94566, USA

**Telephone:** +1-925-3991568

**E-mail:** [bpgoffice@wjgnet.com](mailto:bpgoffice@wjgnet.com)

**Help Desk:** <https://www.f6publishing.com/helpdesk>

<https://www.wjgnet.com>

