

World Journal of *Clinical Cases*

World J Clin Cases 2024 January 26; 12(3): 466-670



Contents

Thrice Monthly Volume 12 Number 3 January 26, 2024

EDITORIAL

- 466 Is medical management useful in Moyamoya disease?
Muengtaweepongsa S, Panpattanakul V
- 474 Metabologenomics and network pharmacology to understand the molecular mechanism of cancer research
Tutar Y

ORIGINAL ARTICLE

Case Control Study

- 479 Significance of oxidative stress and antioxidant capacity tests as biomarkers of premature ovarian insufficiency: A case control study
Kakinuma K, Kakinuma T
- 488 Colorectal resections for malignancy: A pilot study comparing conventional *vs* freehand robot-assisted laparoscopic colectomy
Cawich SO, Plummer JM, Griffith S, Naraynsingh V

Retrospective Study

- 495 Ultrasound diagnosis of congenital Morgagni hernias: Ten years of experience at two Chinese centers
Shi HQ, Chen WJ, Yin Q, Zhang XH

Observational Study

- 503 Genetic investigation of the ubiquitin-protein ligase E3A gene as putative target in Angelman syndrome
Manoubi W, Mahdouani M, Hmida D, Kdissa A, Rouissi A, Turki I, Gueddiche N, Soyah N, Saad A, Bouwkamp C, Elgersma Y, Mougou-Zerelli S, Gribaa M

Prospective Study

- 517 Benefit in physical function and quality of life to nonsurgical treatment of varicose veins: Pilot study
Kim GM, Kim B, Jang M, Park JH, Bae M, Lee CW, Kim JW, Huh U

SYSTEMATIC REVIEWS

- 525 Emerging roles of microRNAs as diagnostics and potential therapeutic interest in type 2 diabetes mellitus
Shrivastav D, Singh DD

META-ANALYSIS

- 538 Impact of body mass index on adverse kidney events in diabetes mellitus patients: A systematic-review and meta-analysis
Wan JF, Chen Y, Yao TH, Wu YZ, Dai HZ

CASE REPORT

- 551** Epithelioid malignant peripheral nerve sheath tumor of the bladder and concomitant urothelial carcinoma: A case report
Ozden SB, Simsekoglu MF, Sertbudak I, Demirdag C, Gurses I
- 560** Simultaneous type III congenital esophageal atresia and patent ductus arteriosus in a low-weight patient: A case report
Ma YY, Chen JR, Yang SW, Wang SY, Cao X, Wu J
- 565** Marginal zone lymphoma with severe rashes: A case report
Bai SJ, Geng Y, Gao YN, Zhang CX, Mi Q, Zhang C, Yang JL, He SJ, Yan ZY, He JX
- 575** Inetetamab combined with pyrotinib and chemotherapy in the treatment of breast cancer brain metastasis: A case report
Dou QQ, Sun TT, Wang GQ, Tong WB
- 582** Adult rhabdomyosarcoma combined with acute myeloid leukemia: A case report
Zheng L, Zhang FJ
- 587** Special electromyographic features in a child with paramyotonia congenita: A case report and review of literature
Yi H, Liu CX, Ye SX, Liu YL
- 596** Removal of a guide-wire sliding into abdominal cavity *via* transgastric natural orifice transluminal endoscopic surgery: A case report
Chen SJ, Zhang DY, Lv YT, Bai FH
- 601** Polyneuropathy, organomegaly, endocrinopathy, M-protein, skin changes syndrome with dilated cardiomyopathy: A case report
Li JR, Feng LY, Li JW, Liao Y, Liu FQ
- 607** Ischemic colitis induced by a platelet-raising capsule: A case report
Wang CL, Si ZK, Liu GH, Chen C, Zhao H, Li L
- 616** Brain abscess from oral microbiota approached by metagenomic next-generation sequencing: A case report and review of literature
Zhu XM, Dong CX, Xie L, Liu HX, Hu HQ
- 623** Carrimycin in the treatment of acute promyelocytic leukemia combined with pulmonary tuberculosis: A case report
Yang FY, Shao L, Su J, Zhang ZM
- 630** Rare esophageal carcinoma-primary adenoid cystic carcinoma of the esophagus: A case report
Geng LD, Li J, Yuan L, Du XB
- 637** Early selective enteral feeding in treatment of acute pancreatitis: A case report
Kashintsev AA, Anisimov SV, Nadeeva A, Proutski V

- 643** Pathological diagnosis and immunohistochemical analysis of giant retrosternal goiter in the elderly: A case report
Meng YC, Wu LS, Li N, Li HW, Zhao J, Yan J, Li XQ, Li P, Wei JQ
- 650** Cerebral syphilitic gumma misdiagnosed as brain abscess: A case report
Mu LK, Cheng LF, Ye J, Zhao MY, Wang JL
- 657** Primary anaplastic lymphoma kinase-positive large B-cell lymphoma of the left bulbar conjunctiva: A case report
Guo XH, Li CB, Cao HH, Yang GY
- 665** Porocarcinoma in a palm reconstructed with a full thickness skin graft: A case report
Lim SB, Kwon KY, Kim H, Lim SY, Koh IC

ABOUT COVER

Peer Reviewer of *World Journal of Clinical Cases*, Kazuhiro Katada, MD, PhD, Assistant Professor, Molecular Gastroenterology and Hepatology, Graduate School of Medical Science, Kyoto Prefectural University of Medicine, Kyoto 6028566, Japan. katada@koto.kpu-m.ac.jp

AIMS AND SCOPE

The primary aim of *World Journal of Clinical Cases* (WJCC, *World J Clin Cases*) is to provide scholars and readers from various fields of clinical medicine with a platform to publish high-quality clinical research articles and communicate their research findings online.

WJCC mainly publishes articles reporting research results and findings obtained in the field of clinical medicine and covering a wide range of topics, including case control studies, retrospective cohort studies, retrospective studies, clinical trials studies, observational studies, prospective studies, randomized controlled trials, randomized clinical trials, systematic reviews, meta-analysis, and case reports.

INDEXING/ABSTRACTING

The WJCC is now abstracted and indexed in Science Citation Index Expanded (SCIE, also known as SciSearch®), Journal Citation Reports/Science Edition, Current Contents®/Clinical Medicine, PubMed, PubMed Central, Reference Citation Analysis, China Science and Technology Journal Database, and Superstar Journals Database. The 2023 Edition of Journal Citation Reports® cites the 2022 impact factor (IF) for WJCC as 1.1; IF without journal self cites: 1.1; 5-year IF: 1.3; Journal Citation Indicator: 0.26; Ranking: 133 among 167 journals in medicine, general and internal; and Quartile category: Q4.

RESPONSIBLE EDITORS FOR THIS ISSUE

Production Editor: Zi-Hang Xu, Production Department Director: Xiang Li, Editorial Office Director: Jin-Lei Wang.

NAME OF JOURNAL

World Journal of Clinical Cases

ISSN

ISSN 2307-8960 (online)

LAUNCH DATE

April 16, 2013

FREQUENCY

Thrice Monthly

EDITORS-IN-CHIEF

Bao-Gan Peng, Salim Surani, Jerzy Tadeusz Chudek, George Kontogeorgos, Maurizio Serati

EDITORIAL BOARD MEMBERS

<https://www.wjgnet.com/2307-8960/editorialboard.htm>

PUBLICATION DATE

January 26, 2024

COPYRIGHT

© 2024 Baishideng Publishing Group Inc

INSTRUCTIONS TO AUTHORS

<https://www.wjgnet.com/bpg/gerinfo/204>

GUIDELINES FOR ETHICS DOCUMENTS

<https://www.wjgnet.com/bpg/GerInfo/287>

GUIDELINES FOR NON-NATIVE SPEAKERS OF ENGLISH

<https://www.wjgnet.com/bpg/gerinfo/240>

PUBLICATION ETHICS

<https://www.wjgnet.com/bpg/GerInfo/288>

PUBLICATION MISCONDUCT

<https://www.wjgnet.com/bpg/gerinfo/208>

ARTICLE PROCESSING CHARGE

<https://www.wjgnet.com/bpg/gerinfo/242>

STEPS FOR SUBMITTING MANUSCRIPTS

<https://www.wjgnet.com/bpg/GerInfo/239>

ONLINE SUBMISSION

<https://www.f6publishing.com>



Adult rhabdomyosarcoma combined with acute myeloid leukemia: A case report

Lu Zheng, Fen-Juan Zhang

Specialty type: Medicine, research and experimental

Provenance and peer review: Unsolicited article; Externally peer reviewed.

Peer-review model: Single blind

Peer-review report's scientific quality classification

Grade A (Excellent): 0
Grade B (Very good): 0
Grade C (Good): C
Grade D (Fair): 0
Grade E (Poor): 0

P-Reviewer: Sultana N, Bangladesh

Received: September 19, 2023

Peer-review started: September 19, 2023

First decision: December 5, 2023

Revised: December 17, 2023

Accepted: January 4, 2024

Article in press: January 4, 2024

Published online: January 26, 2024



Lu Zheng, Fen-Juan Zhang, Department of Hematology, Lishui Municipal Central Hospital, Lishui 323000, Zhejiang Province, China

Corresponding author: Fen-Juan Zhang, MD, Nurse, Department of Hematology, Lishui Municipal Central Hospital, No. 289 Kuocang Road, Lishui 323000, Zhejiang Province, China. zhangfenjuan84@163.com

Abstract

BACKGROUND

Rhabdomyosarcoma is a tumor of mesenchymal origin. Secondary leukemia is a complication of previous transformation to other hematologic disorders or is a treatment-related acute myeloid leukemia secondary to cytotoxic chemotherapy or radiation therapy for other malignancies.

CASE SUMMARY

We present the case of a 36-year-old female patient who was diagnosed with rhabdomyosarcoma and acute myeloid leukemia. Further disease progression was observed after multiline chemotherapy. Eventually, the patient suffered cerebral hemorrhage, which resulted in death.

CONCLUSION

The incidence of rhabdomyosarcoma in adults is extremely low, and secondary leukemia caused by rhabdomyosarcoma is even rarer. Secondary leukemia has a very poor prognosis and a low overall survival rate.

Key Words: Rhabdomyosarcoma; Secondary acute myeloid leukocytes; Chemotherapeutics; Secondary leukemia; Case report

©The Author(s) 2024. Published by Baishideng Publishing Group Inc. All rights reserved.

Core Tip: This article reports on a patient with rhabdomyosarcoma who developed acute myeloid leukemia (AML-M5a) after 11 chemotherapy sessions. Eventually, the patient suffered cerebral hemorrhage, which resulted in death. The incidence of rhabdomyosarcoma in adults is extremely low, and secondary leukemia caused by rhabdomyosarcoma is even rarer. Secondary leukemia has a very poor prognosis and a low overall survival rate.

Citation: Zheng L, Zhang FJ. Adult rhabdomyosarcoma combined with acute myeloid leukemia: A case report. *World J Clin Cases* 2024; 12(3): 582-586

URL: <https://www.wjgnet.com/2307-8960/full/v12/i3/582.htm>

DOI: <https://dx.doi.org/10.12998/wjcc.v12.i3.582>

INTRODUCTION

Rhabdomyosarcoma is a tumor of mesenchymal origin. It occurs most frequently in children and adolescents and has a very low incidence in adults[1]. The main treatments for rhabdomyosarcoma are surgery, chemotherapy and radiotherapy. Secondary leukemia is a complication of previous transformation to other hematologic disorders or treatment-related acute myeloid leukemia secondary to cytotoxic chemotherapy or radiation therapy for other malignancies[2,3]. With technological advances in chemotherapy and radiotherapy, the survival of oncology patients has increased, as has the probability of developing secondary leukemias. This article reports on a patient with rhabdomyosarcoma who developed acute myeloid leukemia (AML-M2) after 11 chemotherapy sessions.

CASE PRESENTATION

Chief complaints

A 36-year-old female patient visited our hospital on October 30, 2019, due to right cheek swelling for 1 month.

History of present illness

The patient was admitted with a mass on the left cheek. Physical examination revealed a mass approximately 3.4 cm in size on the right cheek. The peripheral blood and biochemical parameters (liver and renal function and serum lactate dehydrogenase level) were within normal limits. Pathology of the right buccal mass puncture showed spindle cell rhabdomyosarcoma. Immunohistochemistry (Figure 1) showed the following: ALK IA4 (portion+), Caldesmon (-), Desmin (+), H3K27ME3 (excalation), MyoD1 (+), Myogenin (+), S-100 (portion+), and SMA (-). She was diagnosed with spindle cell rhabdomyosarcoma. After the diagnosis, the patient underwent surgical treatment. The postoperative pathologic diagnosis was consistent with spindle cell rhabdomyosarcoma. The patient was subsequently given a 12-cycle VAC/IA regimen (VAC; Vinorelbine, 38 mg; cyclophosphamide, 1.4 mg; Epirus; IA: isocyclophosphamide 2.5 g 1-5 d, etoposide 0.1 g 1-5 d). Her disease went into remission after treatment. On April 28, 2021, the patient's repeat blood test showed a white blood cell count of $115.4 \times 10^9/L$, a hemoglobin level of 112 g/L, a blood platelet count of $144 \times 10^9/L$, and a primary cell count of 49%.

History of past illness

The patient had no family history or specific social history.

Personal and family history

No personal or family history was available.

Physical examination

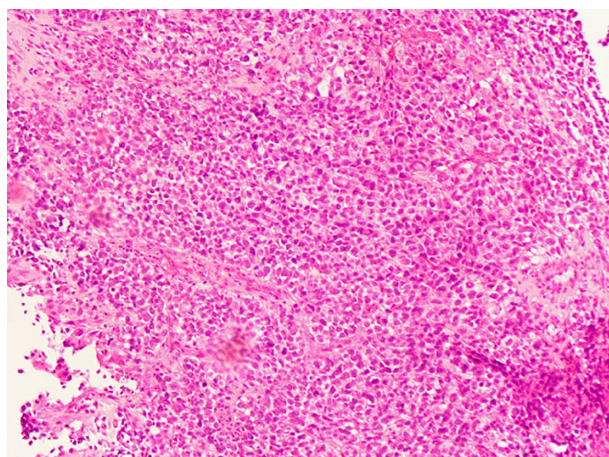
Physical examination revealed no palpable lymph nodes, organomegaly, or cutaneous lesions.

Laboratory examinations

Her bone marrow morphology showed active cell hyperplasia, accounting for 77%. For these types of cells, the cytoplasm was 12-25 μm in size, the shape was round, oval or irregular, and the cytoplasmic volume was rich and colored dark blue. Part of the cell cytoplasm could be seen as tiny purplish-red particles, and the cytosolic nuclei were round and oval. The nuclear chromatin was meticulously granular, with 1 to several nucleoli that were not clear and seemed to be monophyletic. POX (+), butyric acid (+) and NaF (inhibition). The bone marrow picture was consistent with acute nonlymphocytic leukemia, with cytomorphology resembling M5. Immunohistochemistry revealed the following results: 87.57% of the primary cells predominantly expressed CD33, CD38, CD13, HLA-DR, CD11b, CD36, and CD64, while CD34, CD117, CD14, and cMPO were not expressed. The karyotype was 45, XX, -7. The leukemia genetic testing reported that the mutated genes are NRAS, CUX1, LIG4, MYH1, KMT2A, CTC1, ANKRD26, BCOR, KAT6A, GFI1 and MLLT3.

Imaging examinations

The patient did not have an imaging examination.



DOI: 10.12998/wjcc.v12.i3.582 Copyright ©The Author(s) 2024.

Figure 1 Pathology of the right buccal mass puncture showed spindle cell rhabdomyosarcoma.

FINAL DIAGNOSIS

Based on the above findings, the final diagnosis was acute myeloid leukemia (AML-M5a).

TREATMENT

On May 5, 2021, the patient was treated with a VA program (venetoclax 400 mg for 28 d and azacitidine for 7 d). Repeat bone marrow cytology suggested a state of disease remission. On June 25, 2021, the patient relapsed with acute myeloid leukemia. Multiple but ineffective platelet transfusions were performed.

OUTCOME AND FOLLOW-UP

On July 10, 2021, the patient suffered cerebral hemorrhage, which resulted in death.

DISCUSSION

In 1992, fusiform rhabdomyosarcoma was first discovered by Cavazzana *et al*[4]. Rhabdomyosarcoma is a malignant tumor arising from embryonic mesenchymal tissue that occurs most commonly in children and adolescents and rarely in adults and accounts for 2%-5% of all tumors. When it is present in the head and neck, the prognosis is often poor, and the clinical manifestations are more malignant[5]. According to the WHO classification, rhabdomyosarcoma is divided into embryonal rhabdomyosarcoma, acinar rhabdomyosarcoma, polymorphic rhabdomyosarcoma and spindle cell/sclerosing rhabdomyosarcoma. Rhabdomyosarcoma has a very low incidence in adults, accounting for less than 1% of all adult malignancies and 3% of adult soft tissue sarcomas[6]. Rhabdomyosarcoma generally has a soft morphology, and its gross appearance is mainly a cauliflower-like or polypoid mass that can invade surrounding tissues, cause tissue adhesion, and subsequently invade bone[7]. Microscopically, the tumors were diverse and mainly composed of small round cells. After HE staining, the rhabdomyosarcoma cells showed small, elongated nuclei with frequent mitotic activity, a reddish cytoplasm, and a clear stroma. Immunohistochemistry revealed SMA (+), MyoD1 (+), myogenin (+), CD99 (+), and vimentin (+), with MyoD1 and vimentin being specific markers of striated muscle.

The immunophenotype of the patient in this case was MyoD1 (+) and Myogenin(+), which was consistent with the findings of other reports[8]. The optimal treatment method for rhabdomyosarcoma has not yet been determined, and there is no standardized systematic treatment method. Currently, local extensive resection combined with postoperative chemotherapy is the main treatment method.

The causes of secondary leukemia include chemotherapy, radiotherapy, genetics, and other factors, and secondary leukemia caused by chemotherapy drugs ranks first. The main chemical drugs that can cause secondary leukemia are alkylating agents (such as cyclophosphamide, mefalam, nitrogen mustard, *etc.*), topoisomerase II inhibitors (etoposide, doxorubicin, mitoxantrone, *etc.*), dioxypyrazine drugs, *etc.* The disease progression of leukemia caused by alkylating agents is gradual and is usually accompanied by myelodysplastic syndrome, with a median latency of 5 yr (range 1-14 yr) [9]. The median latency of leukemia caused by topoisomerase II inhibitors was 1.5 yr[9]. The patient in this case had a history of rhabdomyosarcoma and was cured after multiple rounds of chemotherapy. Multiple chemotherapy cycles may also cause secondary leukemia, and the duration from chemotherapy to secondary leukemia was 1.5 yr. Studies have

shown that the incidence of secondary leukemia increases 7-fold when etoposide and/or cyclophosphamide are used[10].

Compared with those of primary leukemia, secondary leukemia often has worse clinical outcomes, including a significantly worse complete remission (CR) rate, relapse-free survival rate and overall survival rate[11]. This may be related to the older age and worse organ function of patients with secondary leukemia. In addition, these patients may have persistent malignant disease or experience recurrence of primary malignancies. Previous chemotherapy or radiotherapy leads to hematopoietic failure and prolongs bone marrow suppression after treatment for acute myeloid leukemia, which can easily cause more serious treatment-related complications.

The median survival time of patients with secondary leukemia is 6-12 mo, and the main cause of death is the tumor itself[12]. Molecular mutations and cytogenetic abnormalities, such as TP53 mutations, may be more common in patients with secondary leukemia and are associated with resistance to conventional chemotherapy[13]. The median survival time of patients with secondary leukemia is 6-12 mo, and the main cause of death is the tumor itself[12]. However, molecular mutations and cytogenetic abnormalities, such as TP53 mutations, which are associated with resistance to conventional chemotherapy[13], may be more common in patients with secondary leukemia.

With the progress of medical technology, there have been obvious breakthroughs in understanding the etiology and pathogenesis of secondary leukemia and in its treatment. At present, the best method for treating secondary leukemia is still unclear, and intensive chemical treatment is still one of the main methods for treating secondary leukemia. Godley *et al*[12] conducted a study on 32 patients with secondary leukemia. After treatment with high-dose cytarabine + mitoxantrone, the complete response rate was 66%, the partial response rate was 16%, and the overall response rate was 82%. The mortality rate after treatment on the 30th day was 9%. At present, a variety of small molecule inhibitors targeting Bcl-2 have been marketed, among which venetoclax has been widely used. Venetoclax is an oral, potent, selective Bcl-2 inhibitor. Several studies have reported clinical trials of venetoclax in elderly AML patients who cannot tolerate chemotherapy. The results showed that the median CR rate was 62%, the median response time was 1 mo, the median survival time was 18.4 mo, and the 1-yr OS was 70.4%[14]. Venetoclax in combination with the hypomethylating agents azacitidine and decitabine is a new treatment for refractory relapsed leukemia. At present, venetoclax is mainly used in elderly patients with acute leukemia and recurrent/refractory acute leukemia, and it is still rarely used for the treatment of primary drug-related secondary leukemia.

In this case, the patient had received multiple rounds of chemotherapy for the treatment of spindle rhabdomyosarcoma and was physiologically resistant to chemotherapy. Therefore, she first received 100 mg azacitidine on days 1 to 7 and 400 mg venetoclax once daily for 28 d. She achieved CR, but the remission time was not long. Finally, the complications of cerebral hemorrhage led to death. It was also suggested that the prognosis of secondary leukemia patients was very poor, which was basically consistent with reports in the literature. In this case, the patient had received multiple rounds of chemotherapy for the treatment of spindle rhabdomyosarcoma and was physiologically resistant to chemotherapy. Therefore, she first received 100 mg azacitidine for days 1 to 7 and 400 mg venetoclax once daily for days. She achieved CR, but the remission time was not long. Ultimately, cerebral hemorrhage complications led to death. These findings also suggest that the prognosis of secondary leukemia patients is extremely poor, which is basically consistent with reports in the literature.

CONCLUSION

In summary, the incidence of rhabdomyosarcoma in adults is extremely low, and secondary leukemia caused by rhabdomyosarcoma is even rarer. Secondary leukemia has a very poor prognosis and a low overall survival rate. Despite the development of various new treatment technologies in recent years, we still need to continue to explore treatment options.

FOOTNOTES

Author contributions: Zheng L designed the report and wrote the paper; Zhang FJ revised the paper; all the authors have read and approved the final version of this manuscript.

Informed consent statement: All study participants, or their legal guardian, provided informed written consent prior to study enrollment.

Conflict-of-interest statement: The authors declare that they have no conflicts of interest.

CARE Checklist (2016) statement: The authors have read the CARE Checklist (2016), and the manuscript was prepared and revised according to the CARE Checklist (2016).

Open-Access: This article is an open-access article that was selected by an in-house editor and fully peer-reviewed by external reviewers. It is distributed in accordance with the Creative Commons Attribution NonCommercial (CC BY-NC 4.0) license, which permits others to distribute, remix, adapt, build upon this work non-commercially, and license their derivative works on different terms, provided the original work is properly cited and the use is non-commercial. See: <https://creativecommons.org/licenses/by-nc/4.0/>

Country/Territory of origin: China

ORCID number: Lu Zheng 0009-0002-2949-2056; Fen-Juan Zhang 0009-0004-2434-119X.

S-Editor: Gao CC

L-Editor: A

P-Editor: Zheng XM

REFERENCES

- 1 Akki AS, Harrell DK, Weaver KD, Esnakula AK, Shenoy A. Rare case of spindle cell/sclerosing rhabdomyosarcoma in adult liver. *Pathology* 2019; **51**: 745-747 [PMID: 31668403 DOI: 10.1016/j.pathol.2019.07.010]
- 2 Cheung E, Perissinotti AJ, Bixby DL, Burke PW, Pettit KM, Benitez LL, Brown J, Scappaticci GB, Marini BL. The leukemia strikes back: a review of pathogenesis and treatment of secondary AML. *Ann Hematol* 2019; **98**: 541-559 [PMID: 30666431 DOI: 10.1007/s00277-019-03606-0]
- 3 Micallef IN, Lillington DM, Apostolidis J, Amess JA, Neat M, Matthews J, Clark T, Foran JM, Salam A, Lister TA, Rohatiner AZ. Therapy-related myelodysplasia and secondary acute myelogenous leukemia after high-dose therapy with autologous hematopoietic progenitor-cell support for lymphoid malignancies. *J Clin Oncol* 2000; **18**: 947-955 [PMID: 10694543 DOI: 10.1200/jco.2000.18.5.947]
- 4 Cavazzana AO, Schmidt D, Ninfo V, Harms D, Tollot M, Carli M, Treuner J, Betto R, Salviati G. Spindle cell rhabdomyosarcoma. A prognostically favorable variant of rhabdomyosarcoma. *Am J Surg Pathol* 1992; **16**: 229-235 [PMID: 1599014 DOI: 10.1097/0000478-199203000-00002]
- 5 Owosho AA, Ch D, Huang SC, Chen S, Mbbs, Kashikar S, Dds, Estilo CL, Dmd, Wolden SL, Md, Wexler LH, Md, Huryn JM, Dds, Antonescu CR, Md. A clinicopathologic study of head and neck rhabdomyosarcomas showing FOXO1 fusion-positive alveolar and MYOD1-mutant sclerosing are associated with unfavorable outcome. *Oral Oncol* 2016; **61**: 89-97 [PMID: 27688110 DOI: 10.1016/j.oraloncology.2016.08.017]
- 6 Kayser S, Döhner K, Krauter J, Köhne CH, Horst HA, Held G, von Lilienfeld-Toal M, Wilhelm S, Kündgen A, Götze K, Rummel M, Nachbaur D, Schlegelberger B, Göhring G, Späth D, Morlok C, Zucknick M, Ganser A, Döhner H, Schlenk RF; German-Austrian AMLSG. The impact of therapy-related acute myeloid leukemia (AML) on outcome in 2853 adult patients with newly diagnosed AML. *Blood* 2011; **117**: 2137-2145 [PMID: 21127174 DOI: 10.1182/blood-2010-08-301713]
- 7 Ciammella P, Galeandro M, D'Abbiero N, Palmieri T, Donini E, Iotti C. Prostate embryonal rhabdomyosarcoma in adults: Case report and review of literature. *Rep Pract Oncol Radiother* 2013; **18**: 310-315 [PMID: 24416569 DOI: 10.1016/j.rpor.2013.03.007]
- 8 Yasui N, Yoshida A, Kawamoto H, Yonemori K, Hosono A, Kawai A. Clinicopathologic analysis of spindle cell/sclerosing rhabdomyosarcoma. *Pediatr Blood Cancer* 2015; **62**: 1011-1016 [PMID: 25557260 DOI: 10.1002/pbc.25367]
- 9 Mauritzson N, Albin M, Rylander L, Billström R, Ahlgren T, Mikoczy Z, Björk J, Strömberg U, Nilsson PG, Mitelman F, Hagmar L, Johansson B. Pooled analysis of clinical and cytogenetic features in treatment-related and de novo adult acute myeloid leukemia and myelodysplastic syndromes based on a consecutive series of 761 patients analyzed 1976-1993 and on 5098 unselected cases reported in the literature 1974-2001. *Leukemia* 2002; **16**: 2366-2378 [PMID: 12454741 DOI: 10.1038/sj.leu.2402713]
- 10 Heyn R, Khan F, Ensign LG, Donaldson SS, Ruymann F, Smith MA, Vietti T, Maurer HM. Acute myeloid leukemia in patients treated for rhabdomyosarcoma with cyclophosphamide and low-dose etoposide on Intergroup Rhabdomyosarcoma Study III: an interim report. *Med Pediatr Oncol* 1994; **23**: 99-106 [PMID: 8202048 DOI: 10.1002/mpo.2950230206]
- 11 Borthakur G, Lin E, Jain N, Estey EE, Cortes JE, O'Brien S, Faderl S, Ravandi F, Pierce S, Kantarjian H. Survival is poorer in patients with secondary core-binding factor acute myelogenous leukemia compared with de novo core-binding factor leukemia. *Cancer* 2009; **115**: 3217-3221 [PMID: 19441109 DOI: 10.1002/cncr.24367]
- 12 Godley LA, Njiaju UO, Green M, Weiner H, Lin S, Odenike O, Rich ES, Artz A, Van Besien K, Daugherty CK, Zhang Y, Le Beau MM, Stock W, Larson RA. Treatment of therapy-related myeloid neoplasms with high-dose cytarabine/mitoxantrone followed by hematopoietic stem cell transplant. *Leuk Lymphoma* 2010; **51**: 995-1006 [PMID: 20536346 DOI: 10.3109/10428191003763468]
- 13 Yang D, Fu X, Zhang X, Li W, Zhang M. Therapy-related acute myeloid leukemia in patients with lymphoma: A report of four cases and review of the literature. *Oncol Lett* 2015; **10**: 3261-3265 [PMID: 26722322 DOI: 10.3892/ol.2015.3703]
- 14 Bedikian AY, Garbe C, Conry R, Lebbe C, Grob JJ; Genasense Melanoma Study Group. Dacarbazine with or without oblimersen (a Bcl-2 antisense oligonucleotide) in chemotherapy-naïve patients with advanced melanoma and low-normal serum lactate dehydrogenase: 'The AGENDA trial'. *Melanoma Res* 2014; **24**: 237-243 [PMID: 24667300 DOI: 10.1097/CMR.0000000000000056]



Published by **Baishideng Publishing Group Inc**
7041 Koll Center Parkway, Suite 160, Pleasanton, CA 94566, USA

Telephone: +1-925-3991568

E-mail: office@baishideng.com

Help Desk: <https://www.f6publishing.com/helpdesk>

<https://www.wjgnet.com>

