

World Journal of *Clinical Cases*

World J Clin Cases 2024 January 26; 12(3): 466-670



Contents

Thrice Monthly Volume 12 Number 3 January 26, 2024

EDITORIAL

- 466 Is medical management useful in Moyamoya disease?
Muengtaweepongsa S, Panpattanakul V
- 474 Metabologenomics and network pharmacology to understand the molecular mechanism of cancer research
Tutar Y

ORIGINAL ARTICLE

Case Control Study

- 479 Significance of oxidative stress and antioxidant capacity tests as biomarkers of premature ovarian insufficiency: A case control study
Kakinuma K, Kakinuma T
- 488 Colorectal resections for malignancy: A pilot study comparing conventional *vs* freehand robot-assisted laparoscopic colectomy
Cawich SO, Plummer JM, Griffith S, Naraynsingh V

Retrospective Study

- 495 Ultrasound diagnosis of congenital Morgagni hernias: Ten years of experience at two Chinese centers
Shi HQ, Chen WJ, Yin Q, Zhang XH

Observational Study

- 503 Genetic investigation of the ubiquitin-protein ligase E3A gene as putative target in Angelman syndrome
Manoubi W, Mahdouani M, Hmida D, Kdissa A, Rouissi A, Turki I, Gueddiche N, Soyah N, Saad A, Bouwkamp C, Elgersma Y, Mougou-Zerelli S, Gribaa M

Prospective Study

- 517 Benefit in physical function and quality of life to nonsurgical treatment of varicose veins: Pilot study
Kim GM, Kim B, Jang M, Park JH, Bae M, Lee CW, Kim JW, Huh U

SYSTEMATIC REVIEWS

- 525 Emerging roles of microRNAs as diagnostics and potential therapeutic interest in type 2 diabetes mellitus
Shrivastav D, Singh DD

META-ANALYSIS

- 538 Impact of body mass index on adverse kidney events in diabetes mellitus patients: A systematic-review and meta-analysis
Wan JF, Chen Y, Yao TH, Wu YZ, Dai HZ

CASE REPORT

- 551 Epithelioid malignant peripheral nerve sheath tumor of the bladder and concomitant urothelial carcinoma: A case report
Ozden SB, Simsekoglu MF, Sertbudak I, Demirdag C, Gurses I
- 560 Simultaneous type III congenital esophageal atresia and patent ductus arteriosus in a low-weight patient: A case report
Ma YY, Chen JR, Yang SW, Wang SY, Cao X, Wu J
- 565 Marginal zone lymphoma with severe rashes: A case report
Bai SJ, Geng Y, Gao YN, Zhang CX, Mi Q, Zhang C, Yang JL, He SJ, Yan ZY, He JX
- 575 Inetetamab combined with pyrotinib and chemotherapy in the treatment of breast cancer brain metastasis: A case report
Dou QQ, Sun TT, Wang GQ, Tong WB
- 582 Adult rhabdomyosarcoma combined with acute myeloid leukemia: A case report
Zheng L, Zhang FJ
- 587 Special electromyographic features in a child with paramyotonia congenita: A case report and review of literature
Yi H, Liu CX, Ye SX, Liu YL
- 596 Removal of a guide-wire sliding into abdominal cavity *via* transgastric natural orifice transluminal endoscopic surgery: A case report
Chen SJ, Zhang DY, Lv YT, Bai FH
- 601 Polyneuropathy, organomegaly, endocrinopathy, M-protein, skin changes syndrome with dilated cardiomyopathy: A case report
Li JR, Feng LY, Li JW, Liao Y, Liu FQ
- 607 Ischemic colitis induced by a platelet-raising capsule: A case report
Wang CL, Si ZK, Liu GH, Chen C, Zhao H, Li L
- 616 Brain abscess from oral microbiota approached by metagenomic next-generation sequencing: A case report and review of literature
Zhu XM, Dong CX, Xie L, Liu HX, Hu HQ
- 623 Carrimycin in the treatment of acute promyelocytic leukemia combined with pulmonary tuberculosis: A case report
Yang FY, Shao L, Su J, Zhang ZM
- 630 Rare esophageal carcinoma-primary adenoid cystic carcinoma of the esophagus: A case report
Geng LD, Li J, Yuan L, Du XB
- 637 Early selective enteral feeding in treatment of acute pancreatitis: A case report
Kashintsev AA, Anisimov SV, Nadeeva A, Proutski V

- 643** Pathological diagnosis and immunohistochemical analysis of giant retrosternal goiter in the elderly: A case report
Meng YC, Wu LS, Li N, Li HW, Zhao J, Yan J, Li XQ, Li P, Wei JQ
- 650** Cerebral syphilitic gumma misdiagnosed as brain abscess: A case report
Mu LK, Cheng LF, Ye J, Zhao MY, Wang JL
- 657** Primary anaplastic lymphoma kinase-positive large B-cell lymphoma of the left bulbar conjunctiva: A case report
Guo XH, Li CB, Cao HH, Yang GY
- 665** Porocarcinoma in a palm reconstructed with a full thickness skin graft: A case report
Lim SB, Kwon KY, Kim H, Lim SY, Koh IC

ABOUT COVER

Peer Reviewer of *World Journal of Clinical Cases*, Kazuhiro Katada, MD, PhD, Assistant Professor, Molecular Gastroenterology and Hepatology, Graduate School of Medical Science, Kyoto Prefectural University of Medicine, Kyoto 6028566, Japan. katada@koto.kpu-m.ac.jp

AIMS AND SCOPE

The primary aim of *World Journal of Clinical Cases* (WJCC, *World J Clin Cases*) is to provide scholars and readers from various fields of clinical medicine with a platform to publish high-quality clinical research articles and communicate their research findings online.

WJCC mainly publishes articles reporting research results and findings obtained in the field of clinical medicine and covering a wide range of topics, including case control studies, retrospective cohort studies, retrospective studies, clinical trials studies, observational studies, prospective studies, randomized controlled trials, randomized clinical trials, systematic reviews, meta-analysis, and case reports.

INDEXING/ABSTRACTING

The WJCC is now abstracted and indexed in Science Citation Index Expanded (SCIE, also known as SciSearch®), Journal Citation Reports/Science Edition, Current Contents®/Clinical Medicine, PubMed, PubMed Central, Reference Citation Analysis, China Science and Technology Journal Database, and Superstar Journals Database. The 2023 Edition of Journal Citation Reports® cites the 2022 impact factor (IF) for WJCC as 1.1; IF without journal self cites: 1.1; 5-year IF: 1.3; Journal Citation Indicator: 0.26; Ranking: 133 among 167 journals in medicine, general and internal; and Quartile category: Q4.

RESPONSIBLE EDITORS FOR THIS ISSUE

Production Editor: Zi-Hang Xu, Production Department Director: Xiang Li, Editorial Office Director: Jin-Lei Wang.

NAME OF JOURNAL

World Journal of Clinical Cases

ISSN

ISSN 2307-8960 (online)

LAUNCH DATE

April 16, 2013

FREQUENCY

Thrice Monthly

EDITORS-IN-CHIEF

Bao-Gan Peng, Salim Surani, Jerzy Tadeusz Chudek, George Kontogeorgos, Maurizio Serati

EDITORIAL BOARD MEMBERS

<https://www.wjgnet.com/2307-8960/editorialboard.htm>

PUBLICATION DATE

January 26, 2024

COPYRIGHT

© 2024 Baishideng Publishing Group Inc

INSTRUCTIONS TO AUTHORS

<https://www.wjgnet.com/bpg/gerinfo/204>

GUIDELINES FOR ETHICS DOCUMENTS

<https://www.wjgnet.com/bpg/GerInfo/287>

GUIDELINES FOR NON-NATIVE SPEAKERS OF ENGLISH

<https://www.wjgnet.com/bpg/gerinfo/240>

PUBLICATION ETHICS

<https://www.wjgnet.com/bpg/GerInfo/288>

PUBLICATION MISCONDUCT

<https://www.wjgnet.com/bpg/gerinfo/208>

ARTICLE PROCESSING CHARGE

<https://www.wjgnet.com/bpg/gerinfo/242>

STEPS FOR SUBMITTING MANUSCRIPTS

<https://www.wjgnet.com/bpg/GerInfo/239>

ONLINE SUBMISSION

<https://www.f6publishing.com>



Special electromyographic features in a child with paramyotonia congenita: A case report and review of literature

Hui Yi, Chen-Xiang Liu, Shu-Xin Ye, Yu-Lin Liu

Specialty type: Medicine, research and experimental

Provenance and peer review: Unsolicited article; Externally peer reviewed.

Peer-review model: Single blind

Peer-review report's scientific quality classification

Grade A (Excellent): 0
Grade B (Very good): B
Grade C (Good): 0
Grade D (Fair): 0
Grade E (Poor): 0

P-Reviewer: Dauey K, Kazakhstan

Received: September 21, 2023

Peer-review started: September 21, 2023

First decision: November 20, 2023

Revised: December 4, 2023

Accepted: January 4, 2024

Article in press: January 4, 2024

Published online: January 26, 2024



Hui Yi, Shu-Xin Ye, Yu-Lin Liu, Department of Neuroelectrophysiology, Qilu Children's Hospital of Shandong University, Jinan 250000, Shandong Province, China

Chen-Xiang Liu, Department of Neuroelectrophysiology, University of Health and Rehabilitation Sciences (Qingdao Municipal Hospital), Qingdao 266000, Shandong Province, China

Corresponding author: Yu-Lin Liu, MA, Deputy Director, Department of Neuroelectrophysiology, Qilu Children's Hospital of Shandong University, No. 23976 Jingshi Road, Jinan 250000, Shandong Province, China. liuyulin1122@126.com

Abstract

BACKGROUND

Paramyotonia congenita (PMC) stands as a rare sodium channelopathy of skeletal muscle, initially identified by Eulenburg. The identification of PMC often relies on electromyography (EMG), a diagnostic technique. The child's needle EMG unveiled trains of myotonic discharges with notably giant amplitudes, alongside irregular wave trains of myotonic discharges. This distinctive observation had not surfaced in earlier studies.

CASE SUMMARY

We report the case of a 3-year-old female child with PMC, who exhibited laryngeal stridor, muffled speech, myotonia from birth. Cold, exposure to cool water, crying, and physical activity exacerbated the myotonia, which was relieved in warmth, yet never normalized. Percussion myotonia was observable in bilateral biceps. Myotonia symptoms remained unchanged after potassium-rich food consumption like bananas. Hyperkalemic periodic paralysis was excluded. Cranial magnetic resonance imaging yielded normal results. Blood potassium remained within normal range, while creatine kinase showed slight elevation. Exome-wide genetic testing pinpointed a heterozygous mutation on chromosome SCN4A: c.3917G>A (p.G1306E). After a six-month mexiletine regimen, symptoms alleviated.

CONCLUSION

In this case revealed the two types of myotonic discharges, and had not been documented in other studies. We underscore two distinctive features: Giant-amplitude potentials and irregular waves.

Key Words: Paramyotonia congenita; Channelopathy; Electromyography; Child; Case report

©The Author(s) 2024. Published by Baishideng Publishing Group Inc. All rights reserved.

Core Tip: Paramyotonia congenita (PMC) is a rare sodium channelopathy of skeletal muscle, first identified by Eulenburg. The distinguishing feature of PMC is paradoxical myotonia, where myotonia worsens with cold and exercise. In instances where genetic testing is unavailable, electromyography (EMG) is a swift, cost-effective diagnostic and differential diagnostic method for PMC. This article elaborates on the EMG characteristics of a recently diagnosed PMC case at our hospital. In this particular case revealed the two types of myotonic discharges, and had not been documented in other studies. We underscore two distinctive features: Giant-amplitude potentials and irregular waves.

Citation: Yi H, Liu CX, Ye SX, Liu YL. Special electromyographic features in a child with paramyotonia congenita: A case report and review of literature. *World J Clin Cases* 2024; 12(3): 587-595

URL: <https://www.wjgnet.com/2307-8960/full/v12/i3/587.htm>

DOI: <https://dx.doi.org/10.12998/wjcc.v12.i3.587>

INTRODUCTION

Paramyotonia congenita (PMC) is a rare sodium channelopathy of skeletal muscle[1,2], first identified by Eulenburg[3]. This autosomal dominant condition stems from mutations in the SCN4A gene, which encodes the α -subunit of Nav1.4[4]. These mutations cause the sodium channel to stay open, leading to sustained muscle contractions and resulting in myotonia[5]. PMC becomes evident in individuals displaying cold-and exercise-triggered myotonia, alongside muscle weakness[6,7]. In children, additional symptoms like neonatal stridor, dysphagia, and respiratory compromise can arise [8]. The distinguishing feature of PMC is paradoxical myotonia, where myotonia worsens with cold and exercise. The global prevalence of PMC is approximately 1 in 200000[9]. Around 50 distinct mutation sites in the SCN4A gene have been documented, with the majority being missense mutations[10]. Diagnosis relies on patient history, examination, character of electromyography (EMG), and genetic verification. In instances where genetic testing is unavailable, certain studies[11,12] have proposed that EMG is a swift, cost-effective diagnostic and differential diagnostic method for PMC [13]. This article elaborates on the EMG characteristics of a recently diagnosed PMC case at our hospital. The case exhibited distinctive manifestations of various types of myotonia discharges, a feature previously unreported. By sharing this novel finding, this article aims to enhance the understanding of neurophysiologists, neurologists, and pediatricians regarding the EMG of PMC. This will ultimately enhance the diagnostic accuracy for patients with this condition, leading to improved treatment and relief of symptoms and quality of life.

CASE PRESENTATION

Chief complaints

A 3-year-old child presented to the rehabilitation department, Qilu Children's Hospital of Shandong University with a complaint of inflexible physical activity for 3 years on July 16, 2022.

History of present illness

A 3-year-old child exhibited laryngeal stridor, muffled speech, and sporadic stridor from birth, a condition unaffected by positioning. This manifestation occurred after feeding and crying, leading to issues with water consumption, mild breathlessness, and occasional breath-holding. Severe cases brought about breathlessness, apnea, lip and facial cyanosis, and myotonia. Cold, exposure to cool water, crying, and physical activity exacerbated the myotonia, which was relieved in warmth, yet never normalized. At 6 mo, restricted upper limb movement was observed. The child managed independent standing and walking by 1 year and 3 mo, but upper limb inflexibility persisted. At 2 years and 8 mo, calf spasms, walking stiffness, knee-flexed lower limb posture abnormalities, and occasional limb rigidity after trips were noted. Instances of ptosis, difficulty in eye opening, and eyeball movement restriction following face washing were present. Myotonia symptoms remained unchanged after potassium-rich food consumption like bananas.

History of past illness

The patient underwent inguinal hernia repair (bilateral) in 2021 at Qilu Children's Hospital of Shandong University.

Personal and family history

Non-consanguineous parents and no family history of similar neurological disorders.

Physical examination

Physical traits encompassed a short neck, hunched back, limited bilateral eye abduction, motor skill delays, and firm muscles with evident muscle bulges. Percussion myotonia was observable in bilateral biceps.

Laboratory examinations

Blood potassium remained within normal range (4.1-4.8 mmol/L), while creatine kinase showed slight elevation (279-771 U/L). Liver function, renal function, thyroid function and inorganic ions were normal.

Imaging examinations

Cranial magnetic resonance imaging yielded normal results.

EMG

Low-frequency (2 Hz, 3 Hz, 5 Hz) and high-frequency (10 Hz, 20 Hz, 30 Hz) repetitive frequency electrical stimulation exhibited normal outcomes. EMG indicated challenging motor unit action discharge (MUP) differentiation, with abundant myotonic discharges detected in muscles examined. Facial nerve motor conduction and blink reflex testing were unremarkable.

A notable quantity of myotonic discharges was documented in all muscles subjected to the needle EMG investigation. Particularly noteworthy were the discernment of trains of positive waves in the myotonic discharges, accompanied by a sound reminiscent of a motorcycle. This phenomenon is evident in [Figure 1A-C](#). Each of these diagrams conveyed a specific muscle's single discharge pattern. [Figure 1A](#) captured the complete progression of a train of positive waves within myotonic discharges, featuring gradual fluctuations in amplitude and frequency, spanning a frequency range of 70-150 Hz and an amplitude range of 0.5-3 mV. [Figure 1B](#) highlighted a section of the train of positive waves depicted in [Figure 1A](#), revealing an oscillating pattern in both amplitude and frequency. This pattern exhibited an abrupt surge followed by a gradual decline. [Figure 1C](#) showcased a compact portion of the positive wave train featured in [Figure 1B](#). This illustration elucidated the structure of a single positive wave, which originated as a positive wave and transitioned into a negative wave characterized by a prolonged duration. The negative wave exhibited the fusion of multiple negative wave forms, each distinguished by varying frequencies and morphologies (as indicated by the arrows in [Figure 1C](#)).

As depicted in [Figure 2A and B](#), the child's muscle needle EMG displayed abrupt and sudden trains of giant-amplitude within myotonic discharges (a: Frequency range: 100-150 Hz, amplitude range: 3-15 mV, span: 300-600 ms). These discharges exhibited a waxing-waning pattern in both amplitude and frequency, with a sudden onset and cessation. Subsequently, there was a gradual reduction in amplitude and frequency. This was succeeded by the appearance of the second form of discharge (b): A train of positive waves within myotonic discharge. This pattern initiated with a positive wave, followed by a negative wave, characterized by a frequency of 100-150 Hz, amplitude of 0.5-3 mV, and a duration of approximately 6-10 s. Over time, frequency and amplitude diminished. The third type of myotonic discharge (c) materialized: A train of irregular waves within myotonic discharge. The irregularities in frequency and waveforms were apparent, with an amplitude range of 0.2-2 mV. During periods of desynchronization, estimating the frequency proved challenging. The auditory accompaniment for all these myotonic discharges resembled that of a dive bomber aircraft or a motorcycle. It is important to note that these three forms of myotonic discharges might coexist within a single myotonic discharge, rather than manifesting in isolation.

The most prevalent type observed within the needle EMG is the trains of irregular waves within myotonic discharge ([Figure 3](#)). This pattern comprises multiple biphasic spike myotonic discharges and positive wave myotonic discharges. Distinguishing irregular waves within myotonic discharge with varying shapes, frequencies, and amplitudes presents difficulties. Amplitude ranges from 50-1000 μ V, while the presence of multiple irregular waves complicates frequency assessment. The extensive myotonic discharges rendered the analysis of MUPs during voluntary contractions challenging.

The measurements for her sensory conduction velocity (SCV), sensory nerve action potential (SNAP), motor nerve conduction velocity (MCV), and compound muscle action potential (CMAP) yielded normal results, illustrated in [Figure 4A and B](#). Her F-wave occurrences and latency rates exhibited normal values, as depicted in [Figure 5A](#), while the H-reflex showcased normal amplitude and latency, as displayed in [Figure 5B](#).

Regarding the facial nerve, both CMAP and MCV measurements were within the normal range, as shown in [Figure 6A](#). Additionally, blink reflexes were elicited with standard latency and amplitude, presented in [Figure 6B](#). Repetitive frequency electrical stimulation results indicated normalcy for various muscles, including bilateral orbicularis oculi, left trapezius, abductor hallucis, right abductor digitorum minimi low frequency (2 Hz, 3 Hz, 5 Hz), and right abductor digitorum minimi high frequency (30 Hz), left abductor hallucis high frequency (10 Hz, 20 Hz), as depicted in [Figure 6C](#).

FINAL DIAGNOSIS

The diagnosis aligned with PMC, grounded in clinical features, lab tests, neurophysiology, and genetic evaluations[3,11-14,16]. Neither parent carried mutations in the gene, and familial history was absent, suggesting sporadic occurrence.

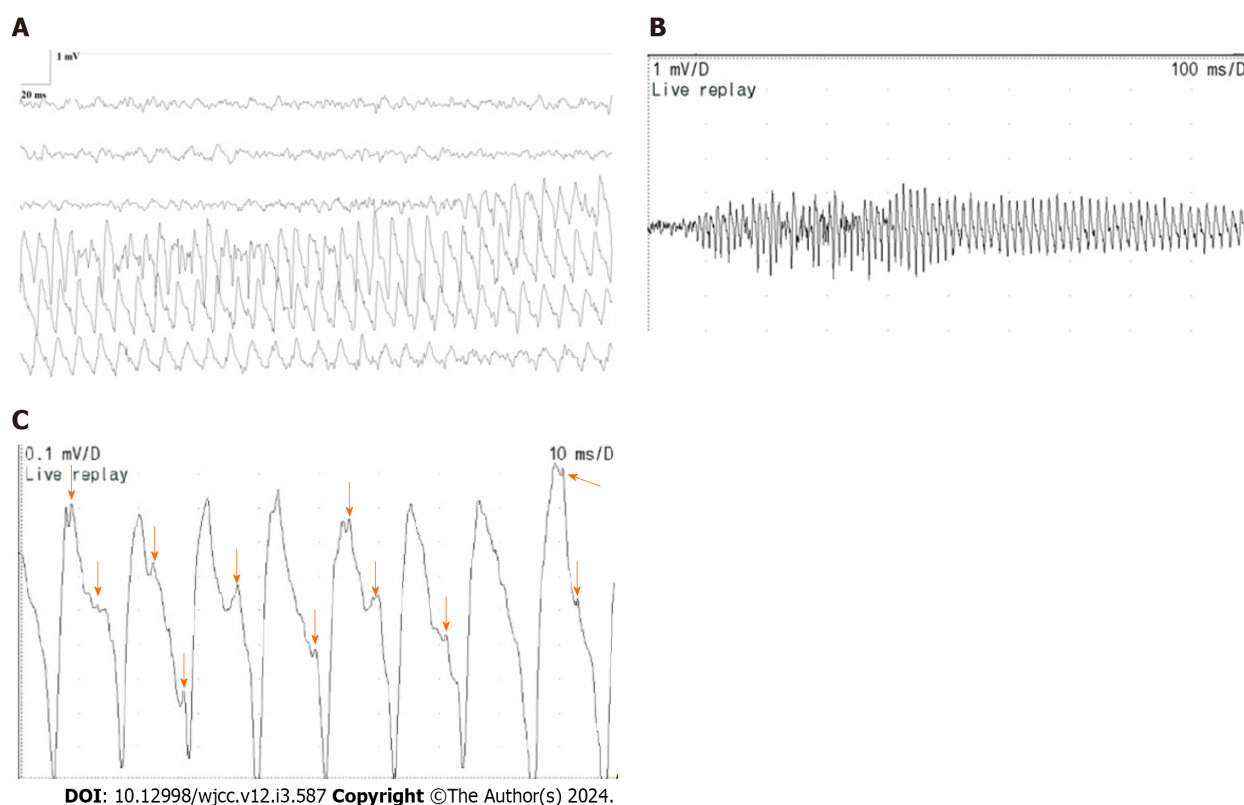


Figure 1 Right rectus femoris (horizontal bar 20 ms/D, vertical bar 1 mV/D; horizontal bar 100 ms/D, vertical bar 1 mV/D; and horizontal bar 10 ms/D, vertical bar 0.1 mV/D). A: Right rectus femoris (horizontal bar 20 ms/D, vertical bar 1 mV/D). The train of positive waves in myotonic discharges, displaying fluctuations in frequency and amplitude, with a frequency range of 70-150 Hz and an amplitude range of 0.5-3 mV, is depicted; B: Right rectus femoris (horizontal bar 100 ms/D, vertical bar 1 mV/D). A section of the train of positive waves in myotonic discharges showcases an oscillating pattern in amplitude and frequency, characterized by a rapid surge followed by a gradual decline; C: Right rectus femoris (horizontal bar 10 ms/D, vertical bar 0.1 mV/D). This represents a small section of the train of positive waves within myotonic discharge depicted in Figure 1B. A complete positive wave is visible, and the arrows denote the presence of negative phase waves, each exhibiting varying frequencies and shapes.

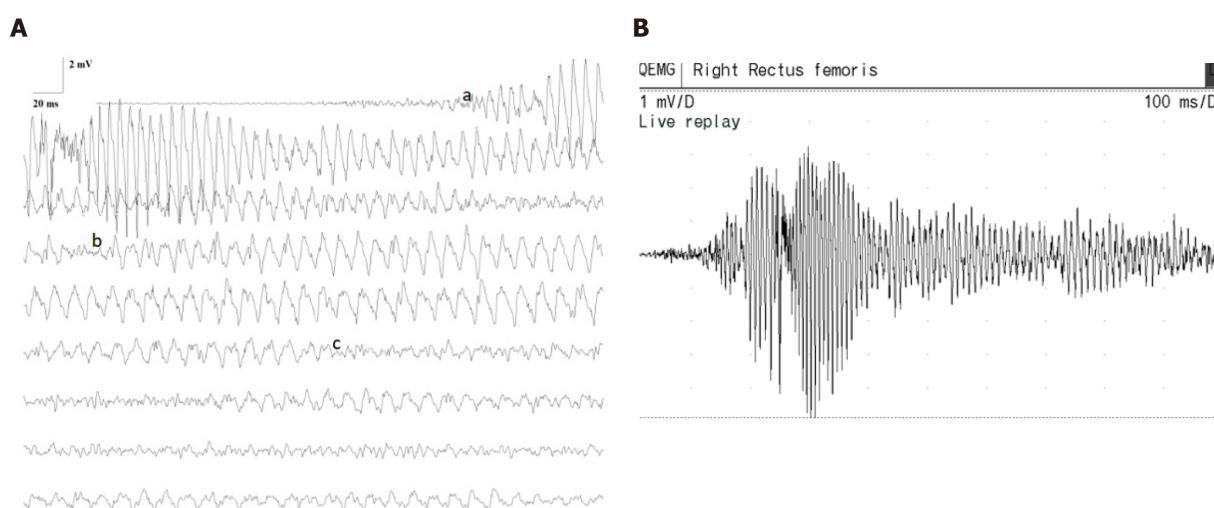


Figure 2 Right rectus femoris (horizontal bar 20 ms/D, vertical bar 2 mV/D; horizontal bar 100 ms/D, vertical bar 1 mV/D). A: Right rectus femoris (horizontal bar 20 ms/D, vertical bar 2 mV/D). a: Train of giant-amplitude of myotonic discharge displaying waxing-waning patterns in frequency (100-150 Hz) and amplitude (3-15 mV); b: Train of positive waves within myotonic discharge, with frequency (100-150 Hz) and amplitude (0.5-3 mV); c: Train of irregular waves within myotonic discharge, characterized by irregular frequency and waveform, with amplitude (0.2-2 mV), and challenging frequency estimation; B: Right rectus femoris (horizontal bar 100 ms/D, vertical bar 1 mV/D). Sequence of giant-amplitude myotonic discharge with sudden initiation and cessation.

TREATMENT

The child received mexiletine at an initial dose of 50 mg three times a day. The dose was increased to 75 mg three times a day after 2 wk, and to 100 mg three times a day after a month. In addition, the patients also participated in physical exercises for rehabilitation.

OUTCOME AND FOLLOW-UP

The frequency and severity after an eight-month mexiletine regimen, which affirmed the therapeutic effect.

DISCUSSION

In the context of PMC, the identification of myotonia is frequently more accurately achieved through needle EMG than neurological examination. In instances where genetic testing is unavailable, EMG can serve as a diagnostic and distinguishing tool for PMC[13]. Previous investigations have delineated two primary variants of myotonic discharge[15]: (1) Biphasic spike potentials, resembling fibrillation potentials, with a duration of less than 5 ms; and (2) Positive waves, akin to positive sharp waves, possessing a duration of 5-20 ms. A singular myotonic potential might visually and audibly resemble either a fibrillation potential or a positive sharp wave. The distinctive attribute of myotonic discharge lies in its waxing-waning pattern. Beyond the positive wave-like myotonic discharge, this particular case revealed the trains of giant-amplitude within myotonic discharges and the trains of irregular wave within myotonic discharges. Interestingly, these two types of myotonic discharges had not been documented in other studies.

In the child under consideration, spontaneous discharges manifested in all the examined muscle EMGs. The forms of myotonic discharge exhibited morphological resemblance or even identical traits across the non-endplate regions of over three muscles, coupled with a distinct auditory signature reminiscent of a dive bomber aircraft or a motorcycle[15].

All examined muscles subjected to needle EMG displayed trains of high-amplitude within myotonic discharges characterized by frequencies ranging from 70 to 150 Hz and amplitudes between 3 to 15 mV. These discharges were accompanied by an audible resemblance to a dive bomber aircraft. Existing literature has documented myotonic discharge frequencies of 20-150 Hz and amplitudes spanning 10-1000 μ V, which produces a distinctive auditory feature often referred to as a dive bomber aircraft[13,16-18]. In this specific case, the amplitude of myotonic discharge waves exceeded typical levels, even surpassing 10 mV - an amplitude magnitude greater than tenfold of previously reported values. Typically, myotonic discharges result from the spontaneous firing of an individual muscle fiber. However, a single concentric needle electrode can capture discharges from multiple muscle fibers[19]. In this instance, the presence of trains of irregular waves within myotonic discharge comprised diverse waves exhibiting different frequencies and shapes. This observation suggests that high-amplitude potentials emerge through ephaptic transmission between numerous closely positioned muscle fibers[20]. Consequently, multiple muscle fibers participate in myotonic discharge, operating in synchronization[21]. Wave amplitudes accumulate over time, yielding "giant-amplitude potentials". On the other hand, PMC arises due to a mutation in the sodium channel gene (SCN4A), impairing rapid sodium channel inactivation during repolarization. The influx of numerous Na⁺ ions through Nav1.4 elevates the equilibrium potential of Na⁺ and the magnitude of myocyte action potential depolarization[22,23]. Consequently, potential amplitudes rise, with these dual mechanisms synergistically generating giant-amplitude potentials. Distinguishing trains of giant-amplitude within myotonic discharges from neurological myotonia is imperative. Neurogenic myotonic discharge patterns entail synchronous contraction discharges across all muscle fibers within a motor unit. These discharges possess frequencies ranging from 100 to 300 Hz, protracted durations, gradual frequency and amplitude reduction spanning several minutes, yet lack the distinct "motorcycle start-up-like sound"[15].

The child also exhibited myotonic discharges resembling positive waves. Earlier investigations have typically noted that positive sharp wave-like myotonic discharges are generally characterized by amplitudes below 1 mV and durations spanning 5-20 ms[13,15,24]. However, a distinctive feature of the positive wave-like myotonic discharges identified in this particular case is their higher amplitude, ranging from 0.5-3 mV. Moreover, within these positive wave myotonic discharges, simultaneous occurrence of one or more negative-phase waves was observed. This occurrence contributed to the non-smooth morphology of the positive wave-like myotonic discharges, yielding a resemblance to a spike-like fusion. This particular discharge pattern also resulted from the synchronized discharge of a few closely spaced muscle fibers, which aggregated to produce high-amplitude positive-wave myotonic discharges. Meanwhile, the sluggish inactivation of sodium ion channels further amplifies the amplitude. Additionally, other muscle fibers produce negative-phase wave discharges characterized by diverse frequencies, which spatially combine to produce fused myotonic discharges. Notably, the asynchronous nature of this subset of muscle fiber discharges does not impact the positive wave-dominated myotonic discharge, preserving the morphological similarity to positive waves.

Prevalent in this child was the occurrence of trains of irregular waves within myotonic discharges. These waves exhibit an irregular shape and frequency, possessing amplitudes below 1 mV and frequencies challenging to estimate. Within these irregular waves, distinguishing positive waves and biphasic spike potentials proves complex. This observation strongly suggests the involvement of multiple muscle fibers in generating these waves, each contributing with distinct frequencies and morphologies. This phenomenon rules out the dominance of any single form of myotonic discharge characterized by synchronized discharges of several muscle fibers. Instead, the irregular waves generated by these diverse muscle fibers fuse both temporally and spatially in accordance with their individual firing frequencies. This

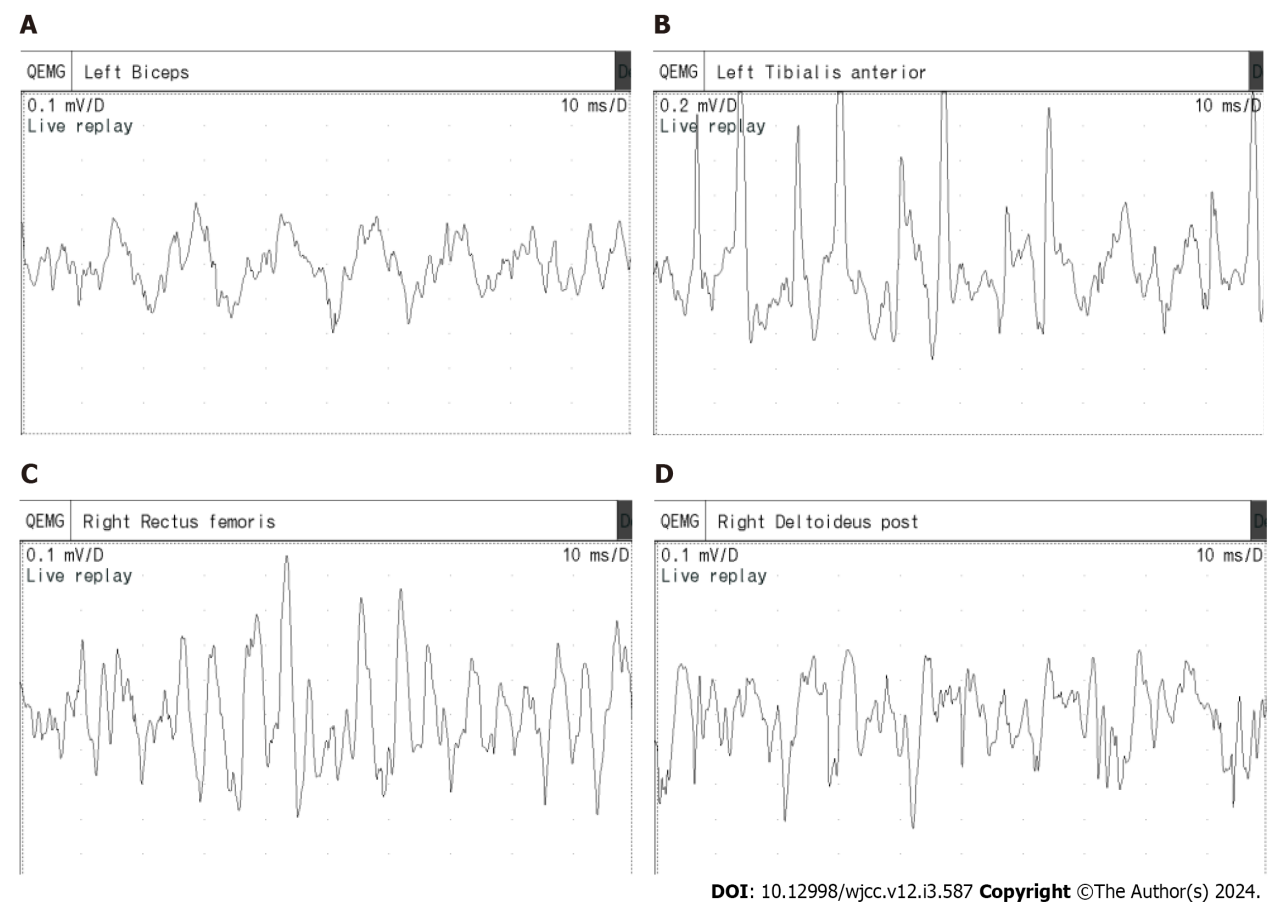


Figure 3 Trains of irregular waves within myotonic discharge across different muscles. A: Left biceps; B: Left tibialis anterior; C: Right rectus femoris; D: Right deltoideus post.

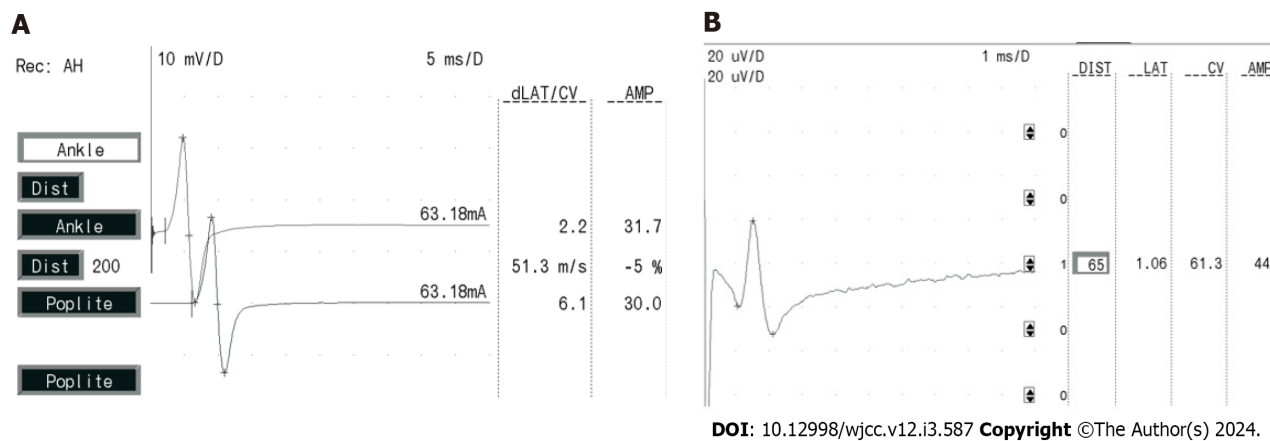


Figure 4 Right tibial nerve and left median nerve. A: Motor nerve conduction velocity and compound muscle action potential of the right tibial nerve; B: Sensory conduction velocity and sensory nerve action potential of the left median nerve.

fusion process results in an amalgamation of waves, losing the original attributes of fibrillation potentials and positive sharp waves.

In summary, a distinctive myotonic discharge profile was observed in this child, characterized by a train of giant-amplitude within myotonic discharges and trains of irregular waves within myotonic discharges, featuring multiple fused myotonic potentials. This attribute arises from the compromised inactivation of sodium channels, leading to increased sodium ion influx and augmented wave amplitude during depolarization. Simultaneously, multiple muscle fibers participate in generating myotonic potentials. When these fibers synchronize at a common frequency, a giant-amplitude potential emerges. As the involvement of synchronized muscle fibers diminishes, certain fibers engage in synchronized discharge while others exhibit distinct frequencies, resulting in the generation of positive wave myotonic discharges. This pattern is dominated by positive wave myotonic discharges while encompassing additional frequencies

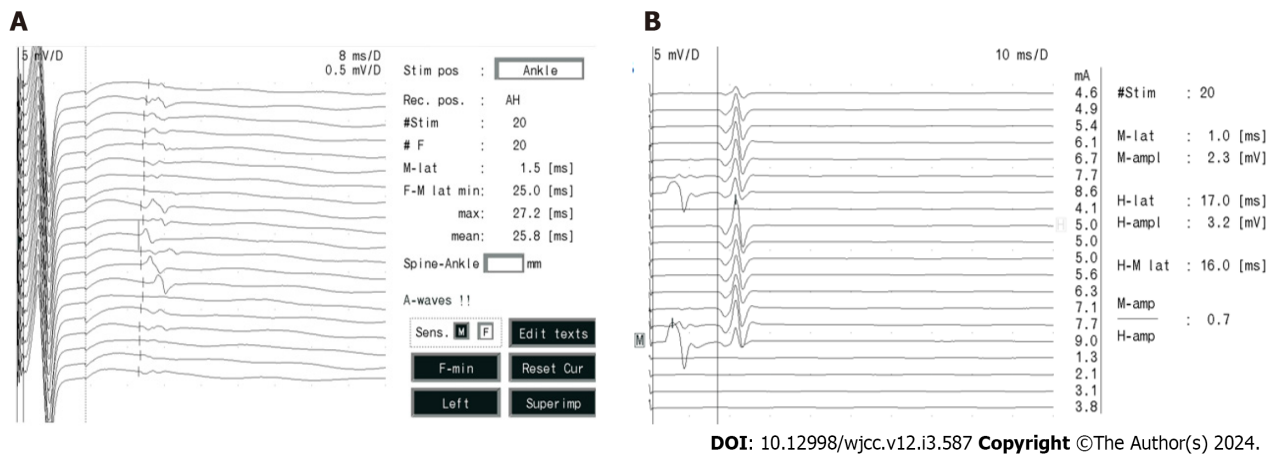


Figure 5 F-wave and H-reflex of the right tibial nerve. A: F-wave of the right tibial nerve; B: H-reflex of the right tibial nerve.




Figure 6 Facial nerve and left abductor hallucis digitorum. A: Compound muscle action potential and motor nerve conduction velocity of the facial nerve; B: Blink reflex (at sedation); C: Repetitive frequency electrical stimulation results of the left abductor hallucis digitorum [low-frequency (2 Hz, 3 Hz, 5 Hz) and high-frequency (10 Hz, 20 Hz) were normal].

of myotonic discharges. In cases where all muscle fibers discharge at varying frequencies, an indistinguishable irregular wave emerges, constituting a fusion of biphasic spike potentials and positive wave myotonic discharges of varying frequencies.

The child's facial nerve motor conduction, nerve conduction studies, and repetitive nerve stimulation (RNS) yielded normal results. It's worth noting that PMC, as a form of sodium channelopathy affecting skeletal muscles, generally

spares peripheral nerves and the neuromuscular junction[4]. Since RNS is primarily employed for detecting neuromuscular junction abnormalities[25], the unremarkable nerve conduction studies and RNS findings are consistent with the lack of involvement of these elements in PMC.

PMC is a sodium channelopathy of skeletal muscle caused by mutations in the SCN4A gene. EMG can confirm the presence, severity and distribution of myotonic discharge, which can support the diagnosis of PMC, and determine whether or not a patient has myopathy. Paradoxical myotonia is the typical feature of PMC. Nearly all patients' EMG showing myotonic potentials in previous studies[26-28]. CMAP decreased following exposure to cold or cold water tests in some patients[29-31]. Additionally, some people may also show a decrease in CMAP after a short period of exercise [27]. According to a report in China, one patient with PMC had delayed nerve conduction velocity and low F-wave appearance in both lower limbs[32]. If patients with PMC has not yet experienced clinical symptoms, their EMG were normal[33]. According to the studies, EMG in some patients with PMC exhibited both myotonic and myopathic potentials [32,34]. In presenting this case of PMC with unique potentials identified *via* needle EMG, we underscore two distinctive features: High-amplitude potentials and irregular waves. These features are linked to the synchronous activation of multiple muscle fibers and the impairment of sodium channel inactivation. By sharing this case, our intent is to assist clinicians in distinguishing this type of myotonic discharge from neurological myotonia.

CONCLUSION

The special case revealed two types of myotonic discharges, which had never been documented until now. We underscore two distinctive features: Giant-amplitude potentials and irregular waves. These features are linked to the synchronous activation of multiple muscle fibers and the impairment of sodium channel inactivation. By sharing this case, our intent is to assist clinicians in distinguishing this type of myotonic discharge from neurological myotonia and widens the known the special feature of EMG in PMC.

FOOTNOTES

Author contributions: Yi H wrote the article and reviewed the relevant literature; Liu CX was involved in the translation of the paper; Ye SX presented a new theoretical perspective on this case of electromyography; and all authors reviewed and edited the article and approved the final version of the article.

Informed consent statement: Written informed consent of this paper was obtained from the patient's legal guardian.

Conflict-of-interest statement: All the authors report no relevant conflicts of interest for this article.

CARE Checklist (2016) statement: The authors have read the CARE Checklist (2016), and the manuscript was prepared and revised according to the CARE Checklist (2016).

Open-Access: This article is an open-access article that was selected by an in-house editor and fully peer-reviewed by external reviewers. It is distributed in accordance with the Creative Commons Attribution NonCommercial (CC BY-NC 4.0) license, which permits others to distribute, remix, adapt, build upon this work non-commercially, and license their derivative works on different terms, provided the original work is properly cited and the use is non-commercial. See: <https://creativecommons.org/licenses/by-nc/4.0/>

Country/Territory of origin: China

ORCID number: Hui Yi 0009-0009-2203-5451; Chen-Xiang Liu 0009-0007-3756-9507; Shu-Xin Ye 0000-0002-6342-3348; Yu-Lin Liu 0009-0001-9136-0022.

S-Editor: Wang JJ

L-Editor: A

P-Editor: Zhao YQ

REFERENCES

- 1 Jarecki BW, Pickar AD, Jackson JO 2nd, Cummins TR. Human voltage-gated sodium channel mutations that cause inherited neuronal and muscle channelopathies increase resurgent sodium currents. *J Clin Invest* 2010; **120**: 369-378 [PMID: 20038812 DOI: 10.1172/JCI40801]
- 2 Yoshinaga H, Sakoda S, Good JM, Takahashi MP, Kubota T, Arikawa-Hirasawa E, Nakata T, Ohno K, Kitamura T, Kobayashi K, Ohtsuka Y. A novel mutation in SCN4A causes severe myotonia and school-age-onset paralytic episodes. *J Neurol Sci* 2012; **315**: 15-19 [PMID: 22257501 DOI: 10.1016/j.jns.2011.12.015]
- 3 Eulenburg A, Landois L. On nerve regeneration with the application of the suture. 1865. *J Mol Med (Berl)* 2001; **79**: 4-5 [PMID: 11327102 DOI: 10.1007/s001090100207]
- 4 Russell SH, Hirsch NP. Anaesthesia and myotonia. *Br J Anaesth* 1994; **72**: 210-216 [PMID: 8110575 DOI: 10.1093/bja/72.2.210]
- 5 Bouhours M, Luce S, Sternberg D, Willer JC, Fontaine B, Tabti N. A1152D mutation of the Na⁺ channel causes paramyotonia congenita and

- emphasizes the role of DIII/S4-S5 linker in fast inactivation. *J Physiol* 2005; **565**: 415-427 [PMID: [15790667](#) DOI: [10.1113/jphysiol.2004.081018](#)]
- 6 **Palma C**, Prior C, Gómez-González C, Rodríguez-Antolín C, Martínez-Montero P, Pérez de Ayala L, Pascual SI, Molano Mateos J. A SCN4A mutation causing paramyotonia congenita. *Neuromuscul Disord* 2017; **27**: 1123-1125 [PMID: [29111379](#) DOI: [10.1016/j.nmd.2017.09.008](#)]
 - 7 **Matthews E**, Tan SV, Fialho D, Sweeney MG, Sud R, Haworth A, Stanley E, Cea G, Davis MB, Hanna MG. What causes paramyotonia in the United Kingdom? Common and new SCN4A mutations revealed. *Neurology* 2008; **70**: 50-53 [PMID: [18166706](#) DOI: [10.1212/01.wnl.00000287069.21162.94](#)]
 - 8 **Matthews E**, Manzur AY, Sud R, Muntoni F, Hanna MG. Stridor as a neonatal presentation of skeletal muscle sodium channelopathy. *Arch Neurol* 2011; **68**: 127-129 [PMID: [21220685](#) DOI: [10.1001/archneurol.2010.347](#)]
 - 9 **Lehmann-Horn F**, Rüdel R. Channelopathies: the nondystrophic myotonias and periodic paralyses. *Semin Pediatr Neurol* 1996; **3**: 122-139 [PMID: [8795846](#) DOI: [10.1016/s1071-9091\(96\)80041-6](#)]
 - 10 **Stenson PD**, Mort M, Ball EV, Evans K, Hayden M, Heywood S, Hussain M, Phillips AD, Cooper DN. The Human Gene Mutation Database: towards a comprehensive repository of inherited mutation data for medical research, genetic diagnosis and next-generation sequencing studies. *Hum Genet* 2017; **136**: 665-677 [PMID: [28349240](#) DOI: [10.1007/s00439-017-1779-6](#)]
 - 11 **Feng Y**, Zhang Y, Liu ZL, Zhang CD. Exercise test on the patients with normokalaemic periodic paralysis from a Chinese family with a mutation in the SCN4A gene. *Chin Med J (Engl)* 2008; **121**: 1915-1919 [PMID: [19080124](#) DOI: [10.1097/00029330-200810010-00012](#)]
 - 12 **Cannon SC**. Sodium Channelopathies of Skeletal Muscle. *Handb Exp Pharmacol* 2018; **246**: 309-330 [PMID: [28939973](#) DOI: [10.1007/164_2017_52](#)]
 - 13 **van den Bersselaar LR**, Heytens L, Silva HCA, Reimann J, Tasca G, Díaz-Cambronero Ó, Løkken N, Hellblom A, Hopkins PM, Rueffert H, Bastian B, Vilchez JJ, Gillies R, Johannsen S, Veyckemans F, Muenster T, Klein A, Litman R, Jungbluth H, Riazzi S, Voermans NC, Snoeck MMJ. European Neuromuscular Centre consensus statement on anaesthesia in patients with neuromuscular disorders. *Eur J Neurol* 2022; **29**: 3486-3507 [PMID: [35971866](#) DOI: [10.1111/ene.15526](#)]
 - 14 **Becker PE**. Genetic approaches to the nosology of muscular disease: myotonias and similar diseases. *Birth Defects Orig Artic Ser* 1971; **7**: 52-62 [PMID: [5293617](#) DOI: [10.1002/bdra.20096](#)]
 - 15 **Miller TM**. Differential diagnosis of myotonic disorders. *Muscle Nerve* 2008; **37**: 293-299 [PMID: [18067134](#) DOI: [10.1002/mus.20923](#)]
 - 16 **Electromyography and Neuromuscular Disorders: Clinical-Electrodiagnostic-Ultrasound Correlations, Fourth Edition.** *J Clin Neurophysiol* 2021; **38**: e19 [PMID: [34210936](#) DOI: [10.1097/WNP.0000000000000842](#)]
 - 17 **Sawlati K**, Katirji B. Peripheral Nerve Hyperexcitability Syndromes. *Continuum (Minneapolis)* 2017; **23**: 1437-1450 [PMID: [28968370](#) DOI: [10.1212/CON.0000000000000520](#)]
 - 18 **Aminoff MJ**. Electrodiagnosis in clinical neurology. 4th ed. New York: Churchill Livingstone, 1999: 257-263
 - 19 **Nandedkar SD**, Sanders DB, Stålberg EV. Selectivity of electromyographic recording techniques: a simulation study. *Med Biol Eng Comput* 1985; **23**: 536-540 [PMID: [4079483](#) DOI: [10.1007/BF02455307](#)]
 - 20 **Trontelj J**, Stålberg E. Bizarre repetitive discharges recorded with single fibre EMG. *J Neurol Neurosurg Psychiatry* 1983; **46**: 310-316 [PMID: [6842243](#) DOI: [10.1136/jnnp.46.4.310](#)]
 - 21 **Torbergesen T**, Hødnebo A, Brautaset NJ, Løseth S, Stålberg E. A rare form of painful nondystrophic myotonia. *Clin Neurophysiol* 2003; **114**: 2347-2354 [PMID: [14652094](#) DOI: [10.1016/s1388-2457\(03\)00275-x](#)]
 - 22 **Heckman JD**. Electrodiagnosis in diseases of nerve and muscle. *Orthopedics* 1984; **7**: 601-604 [PMID: [24822552](#) DOI: [10.3928/0147-7447-19840401-07](#)]
 - 23 **Huang CW**, Lai HJ, Lin PC, Lee MJ. Changes of Resurgent Na(+) Currents in the Na(v)1.4 Channel Resulting from an SCN4A Mutation Contributing to Sodium Channel Myotonia. *Int J Mol Sci* 2020; **21** [PMID: [32276507](#) DOI: [10.3390/ijms21072593](#)]
 - 24 **Hehir MK**, Logigian EL. Electrodiagnosis of myotonic disorders. *Phys Med Rehabil Clin N Am* 2013; **24**: 209-220 [PMID: [23177040](#) DOI: [10.1016/j.pmr.2012.08.015](#)]
 - 25 **Osborne MT**. Repetitive stimulation of muscle. *Nature* 1958; **181**: 1798 [PMID: [13566145](#) DOI: [10.1038/1811798a0](#)]
 - 26 **Park JH**, Lee YW, Park SA, Lee TK, Rho HJ, Sung KB. A case of paramyotonia congenita without periodic paralysis: electrophysiological and molecular genetic studies. *Neurologist* 2010; **16**: 203-205 [PMID: [20445432](#) DOI: [10.1097/NRL.0b013e3181a3cb6c](#)]
 - 27 **Hahn C**, Salajegheh MK. Myotonic disorders: A review article. *Iran J Neurol* 2016; **15**: 46-53 [PMID: [27141276](#)]
 - 28 **Brooks EK**, Schweitzer D, Robinson HL. A case of paramyotonia congenita in pregnancy. *Obstet Med* 2020; **13**: 192-194 [PMID: [33343696](#) DOI: [10.1177/1753495X18816171](#)]
 - 29 **Huang S**, Zhang W, Chang X, Guo J. Overlap of periodic paralysis and paramyotonia congenita caused by SCN4A gene mutations two family reports and literature review. *Channels (Austin)* 2019; **13**: 110-119 [PMID: [30931713](#) DOI: [10.1080/19336950.2019.1600967](#)]
 - 30 **van Osch T**, Stunnenberg BC, Sternberg D, Kerklaan BJ. Prolonged attacks of weakness with hypokalemia in SCN4A-related paramyotonia congenita. *Muscle Nerve* 2018; **58**: E27-E28 [PMID: [30028520](#) DOI: [10.1002/mus.26190](#)]
 - 31 **Taminato T**, Mori-Yoshimura M, Miki J, Sasaki R, Sato N, Oya Y, Nishino I, Takahashi Y. Paramyotonia Congenita with Persistent Distal and Facial Muscle Weakness: A Case Report with Literature Review. *J Neuromuscul Dis* 2020; **7**: 193-201 [PMID: [32083589](#) DOI: [10.3233/JND-190440](#)]
 - 32 **Zhang S**, Wu SW. [Clinical and genetic study of a family with paramyotonia congenita]. *Chin J Neuromed* 2017; **630**-632 [DOI: [10.3760/cma.j.issn.1671-8925.2017.06.018](#)]
 - 33 **Koul R**, Alfutaisi A, Hira M. Paramyotonia congenita in 22 members of an Arab (Omani) kindred. *J Child Neurol* 2010; **25**: 212-215 [PMID: [19168830](#) DOI: [10.1177/0883073808330185](#)]
 - 34 **Song J**, Zhang JW, Fu J, Pang M, Li G, Ma MM. [Clinical, myopathological and genetic features of two Chinese families with paramyotonia congenita]. *Zhonghua Nei Ke Za Zhi* 2020; **59**: 535-539 [PMID: [32594687](#) DOI: [10.3760/cma.j.cn112138-20191014-00690](#)]



Published by **Baishideng Publishing Group Inc**
7041 Koll Center Parkway, Suite 160, Pleasanton, CA 94566, USA

Telephone: +1-925-3991568

E-mail: office@baishideng.com

Help Desk: <https://www.f6publishing.com/helpdesk>

<https://www.wjgnet.com>

