

# World Journal of *Clinical Cases*

*World J Clin Cases* 2024 January 26; 12(3): 466-670



## Contents

Thrice Monthly Volume 12 Number 3 January 26, 2024

## EDITORIAL

- 466 Is medical management useful in Moyamoya disease?  
*Muengtaweepongsa S, Panpattanakul V*
- 474 Metabologenomics and network pharmacology to understand the molecular mechanism of cancer research  
*Tutar Y*

## ORIGINAL ARTICLE

## Case Control Study

- 479 Significance of oxidative stress and antioxidant capacity tests as biomarkers of premature ovarian insufficiency: A case control study  
*Kakinuma K, Kakinuma T*
- 488 Colorectal resections for malignancy: A pilot study comparing conventional *vs* freehand robot-assisted laparoscopic colectomy  
*Cawich SO, Plummer JM, Griffith S, Naraynsingh V*

## Retrospective Study

- 495 Ultrasound diagnosis of congenital Morgagni hernias: Ten years of experience at two Chinese centers  
*Shi HQ, Chen WJ, Yin Q, Zhang XH*

## Observational Study

- 503 Genetic investigation of the ubiquitin-protein ligase E3A gene as putative target in Angelman syndrome  
*Manoubi W, Mahdouani M, Hmida D, Kdissa A, Rouissi A, Turki I, Gueddiche N, Soyah N, Saad A, Bouwkamp C, Elgersma Y, Mougou-Zerelli S, Gribaa M*

## Prospective Study

- 517 Benefit in physical function and quality of life to nonsurgical treatment of varicose veins: Pilot study  
*Kim GM, Kim B, Jang M, Park JH, Bae M, Lee CW, Kim JW, Huh U*

## SYSTEMATIC REVIEWS

- 525 Emerging roles of microRNAs as diagnostics and potential therapeutic interest in type 2 diabetes mellitus  
*Shrivastav D, Singh DD*

## META-ANALYSIS

- 538 Impact of body mass index on adverse kidney events in diabetes mellitus patients: A systematic-review and meta-analysis  
*Wan JF, Chen Y, Yao TH, Wu YZ, Dai HZ*

## CASE REPORT

- 551 Epithelioid malignant peripheral nerve sheath tumor of the bladder and concomitant urothelial carcinoma: A case report  
*Ozden SB, Simsekoglu MF, Sertbudak I, Demirdag C, Gurses I*
- 560 Simultaneous type III congenital esophageal atresia and patent ductus arteriosus in a low-weight patient: A case report  
*Ma YY, Chen JR, Yang SW, Wang SY, Cao X, Wu J*
- 565 Marginal zone lymphoma with severe rashes: A case report  
*Bai SJ, Geng Y, Gao YN, Zhang CX, Mi Q, Zhang C, Yang JL, He SJ, Yan ZY, He JX*
- 575 Inetetamab combined with pyrotinib and chemotherapy in the treatment of breast cancer brain metastasis: A case report  
*Dou QQ, Sun TT, Wang GQ, Tong WB*
- 582 Adult rhabdomyosarcoma combined with acute myeloid leukemia: A case report  
*Zheng L, Zhang FJ*
- 587 Special electromyographic features in a child with paramyotonia congenita: A case report and review of literature  
*Yi H, Liu CX, Ye SX, Liu YL*
- 596 Removal of a guide-wire sliding into abdominal cavity *via* transgastric natural orifice transluminal endoscopic surgery: A case report  
*Chen SJ, Zhang DY, Lv YT, Bai FH*
- 601 Polyneuropathy, organomegaly, endocrinopathy, M-protein, skin changes syndrome with dilated cardiomyopathy: A case report  
*Li JR, Feng LY, Li JW, Liao Y, Liu FQ*
- 607 Ischemic colitis induced by a platelet-raising capsule: A case report  
*Wang CL, Si ZK, Liu GH, Chen C, Zhao H, Li L*
- 616 Brain abscess from oral microbiota approached by metagenomic next-generation sequencing: A case report and review of literature  
*Zhu XM, Dong CX, Xie L, Liu HX, Hu HQ*
- 623 Carrimycin in the treatment of acute promyelocytic leukemia combined with pulmonary tuberculosis: A case report  
*Yang FY, Shao L, Su J, Zhang ZM*
- 630 Rare esophageal carcinoma-primary adenoid cystic carcinoma of the esophagus: A case report  
*Geng LD, Li J, Yuan L, Du XB*
- 637 Early selective enteral feeding in treatment of acute pancreatitis: A case report  
*Kashintsev AA, Anisimov SV, Nadeeva A, Proutski V*

- 643** Pathological diagnosis and immunohistochemical analysis of giant retrosternal goiter in the elderly: A case report  
*Meng YC, Wu LS, Li N, Li HW, Zhao J, Yan J, Li XQ, Li P, Wei JQ*
- 650** Cerebral syphilitic gumma misdiagnosed as brain abscess: A case report  
*Mu LK, Cheng LF, Ye J, Zhao MY, Wang JL*
- 657** Primary anaplastic lymphoma kinase-positive large B-cell lymphoma of the left bulbar conjunctiva: A case report  
*Guo XH, Li CB, Cao HH, Yang GY*
- 665** Porocarcinoma in a palm reconstructed with a full thickness skin graft: A case report  
*Lim SB, Kwon KY, Kim H, Lim SY, Koh IC*



**ABOUT COVER**

Peer Reviewer of *World Journal of Clinical Cases*, Kazuhiro Katada, MD, PhD, Assistant Professor, Molecular Gastroenterology and Hepatology, Graduate School of Medical Science, Kyoto Prefectural University of Medicine, Kyoto 6028566, Japan. katada@koto.kpu-m.ac.jp

**AIMS AND SCOPE**

The primary aim of *World Journal of Clinical Cases* (WJCC, *World J Clin Cases*) is to provide scholars and readers from various fields of clinical medicine with a platform to publish high-quality clinical research articles and communicate their research findings online.

WJCC mainly publishes articles reporting research results and findings obtained in the field of clinical medicine and covering a wide range of topics, including case control studies, retrospective cohort studies, retrospective studies, clinical trials studies, observational studies, prospective studies, randomized controlled trials, randomized clinical trials, systematic reviews, meta-analysis, and case reports.

**INDEXING/ABSTRACTING**

The WJCC is now abstracted and indexed in Science Citation Index Expanded (SCIE, also known as SciSearch®), Journal Citation Reports/Science Edition, Current Contents®/Clinical Medicine, PubMed, PubMed Central, Reference Citation Analysis, China Science and Technology Journal Database, and Superstar Journals Database. The 2023 Edition of Journal Citation Reports® cites the 2022 impact factor (IF) for WJCC as 1.1; IF without journal self cites: 1.1; 5-year IF: 1.3; Journal Citation Indicator: 0.26; Ranking: 133 among 167 journals in medicine, general and internal; and Quartile category: Q4.

**RESPONSIBLE EDITORS FOR THIS ISSUE**

Production Editor: Zi-Hang Xu, Production Department Director: Xiang Li, Editorial Office Director: Jin-Lei Wang.

**NAME OF JOURNAL**

*World Journal of Clinical Cases*

**ISSN**

ISSN 2307-8960 (online)

**LAUNCH DATE**

April 16, 2013

**FREQUENCY**

Thrice Monthly

**EDITORS-IN-CHIEF**

Bao-Gan Peng, Salim Surani, Jerzy Tadeusz Chudek, George Kontogeorgos, Maurizio Serati

**EDITORIAL BOARD MEMBERS**

<https://www.wjgnet.com/2307-8960/editorialboard.htm>

**PUBLICATION DATE**

January 26, 2024

**COPYRIGHT**

© 2024 Baishideng Publishing Group Inc

**INSTRUCTIONS TO AUTHORS**

<https://www.wjgnet.com/bpg/gerinfo/204>

**GUIDELINES FOR ETHICS DOCUMENTS**

<https://www.wjgnet.com/bpg/GerInfo/287>

**GUIDELINES FOR NON-NATIVE SPEAKERS OF ENGLISH**

<https://www.wjgnet.com/bpg/gerinfo/240>

**PUBLICATION ETHICS**

<https://www.wjgnet.com/bpg/GerInfo/288>

**PUBLICATION MISCONDUCT**

<https://www.wjgnet.com/bpg/gerinfo/208>

**ARTICLE PROCESSING CHARGE**

<https://www.wjgnet.com/bpg/gerinfo/242>

**STEPS FOR SUBMITTING MANUSCRIPTS**

<https://www.wjgnet.com/bpg/GerInfo/239>

**ONLINE SUBMISSION**

<https://www.f6publishing.com>



## Carrimycin in the treatment of acute promyelocytic leukemia combined with pulmonary tuberculosis: A case report

Fu-Yu Yang, Lei Shao, Jie Su, Zhen-Meng Zhang

**Specialty type:** Respiratory system

**Provenance and peer review:**

Unsolicited article; Externally peer reviewed.

**Peer-review model:** Single blind

**Peer-review report's scientific quality classification**

Grade A (Excellent): 0

Grade B (Very good): 0

Grade C (Good): 0

Grade D (Fair): 0

Grade E (Poor): 0

**P-Reviewer:** de Jong D,  
Netherlands

**Received:** November 22, 2023

**Peer-review started:** November 22, 2023

**First decision:** December 8, 2023

**Revised:** December 17, 2023

**Accepted:** January 4, 2024

**Article in press:** January 4, 2024

**Published online:** January 26, 2024



**Fu-Yu Yang, Lei Shao, Jie Su, Zhen-Meng Zhang,** Department of Infectious Diseases, The Affiliated Central Hospital of Shandong First Medical University, Jinan 250013, Shandong Province, China

**Corresponding author:** Lei Shao, MD, PhD, Chief Physician, Doctor, Department of Infectious Diseases, The Affiliated Central Hospital of Shandong First Medical University, No. 105 Jiefang Road, Lixia District, Jinan 250013, Shandong Province, China. [shaolei0328@163.com](mailto:shaolei0328@163.com)

### Abstract

#### BACKGROUND

Pulmonary tuberculosis (PTB) is prevalent in immunocompromised populations, including patients with hematologic malignancies, human immunodeficiency virus infections, and chronic diseases. Effective treatment for acute promyelocytic leukemia (APL) combined with PTB is lacking. These patients show an extremely poor prognosis. Therefore, studies should establish efficient treatment options to improve patient survival and prognosis.

#### CASE SUMMARY

A 60-year-old male with pain in the right side of his chest and a fever for 4 d visited the outpatient department of our hospital. Peripheral blood smear revealed 54% blasts. Following bone marrow examinations, variant APL with TNRC18-RARA fusion gene was diagnosed. Chest computed tomography scan showed bilateral pneumonitis with bilateral pleural effusions, partial atelectasis in the lower lobes of both lungs, and the bronchoalveolar lavage fluid gene X-Pert test was positive, indicative of PTB. Carrimycin, ethambutol (EMB), and isoniazid (INH) were administered since he could not receive chemotherapy as the WBC count decreased continuously. After one week of treatment with carrimycin, the patient recovered from fever and received chemotherapy. Chemotherapy was very effective and his white blood cells counts got back to normal. After being given five months with rifampin, EMB and INH and chemotherapy, the patient showed complete remission from pneumonia and APL.

#### CONCLUSION

We report a case of PTB treated successfully with carrimycin with APL that requires chemotherapy.

**Key Words:** Carrimycin; Hematologic disease; Acute myeloid leukemia; Acute promyelocytic leukemia; Pulmonary tuberculosis; Case report

**Core Tip:** Here, we report a case of a patient with acute promyelocytic leukemia (APL) combined with pulmonary tuberculosis (PTB). Addition of carrimycin in a patient with tuberculosis in remission thus enabling chemotherapy for leukemia. He could not tolerate the side effects of routine anti-tuberculosis drugs because of a low white blood cell count, so carrimycin was used for treatment for PTB. He achieved complete remission of APL and PTB after six months treatment. Further research is necessary to determine whether carrimycin is therapeutically useful in PTB.

**Citation:** Yang FY, Shao L, Su J, Zhang ZM. Carrimycin in the treatment of acute promyelocytic leukemia combined with pulmonary tuberculosis: A case report. *World J Clin Cases* 2024; 12(3): 623-629

**URL:** <https://www.wjgnet.com/2307-8960/full/v12/i3/623.htm>

**DOI:** <https://dx.doi.org/10.12998/wjcc.v12.i3.623>

## INTRODUCTION

A subtype of acute myeloid leukemia (AML) is acute promyelocytic leukemia (APL). A heterogeneous disease of hematological malignancies known as AML is characterized by aberrant clonal proliferation, poor differentiation, and inhibition of myeloid hematopoietic stem cell apoptosis[1]. Patients with AML have qualitative and quantitative deficits in granulocytes that predispose them to bacterial and fungal infections. Chemotherapeutic regimens often complicate these deficits, resulting in prolonged periods of severe neutropenia and disruption of mucosal barriers, further elevating the risk of infection[2]. Patients with hematological malignancies have a higher risk of developing PTB[3]. However, anti-tuberculosis chemotherapy is limited by adverse side effects and limited drug options. Few studies have investigated the treatment options for APL in combination with PTB. Here, we report a case of PTB in a patient with APL who achieved considerable relief from after carrimycin treatment. This case report provides evidence for the use of carrimycin as a therapeutic approach for PTB with APL and offers a clinical direction for treating PTB.

## CASE PRESENTATION

### Chief complaints

A 60-year-old male presented with pain in his right chest and a fever for the last 4 d.

### History of present illness

The patient presented with dull pain in the right chest aggravated by deep breathing and activity. His highest recorded temperature was 38.6°C, accompanied by generalized fatigue, muscle and joint pain, and occasional coughing with a small amount of white sputum. The patient was treated at home with self-administered antipyretic drugs after disease onset, with poor results. Before admission, the patient visited a local hospital where examinations revealed pancytopenia, pneumonia, and pleural effusion.

### History of past illness

The patient had a history of hypertension for more than 10 years, which was well controlled with valsartan and amlodipine.

### Personal and family history

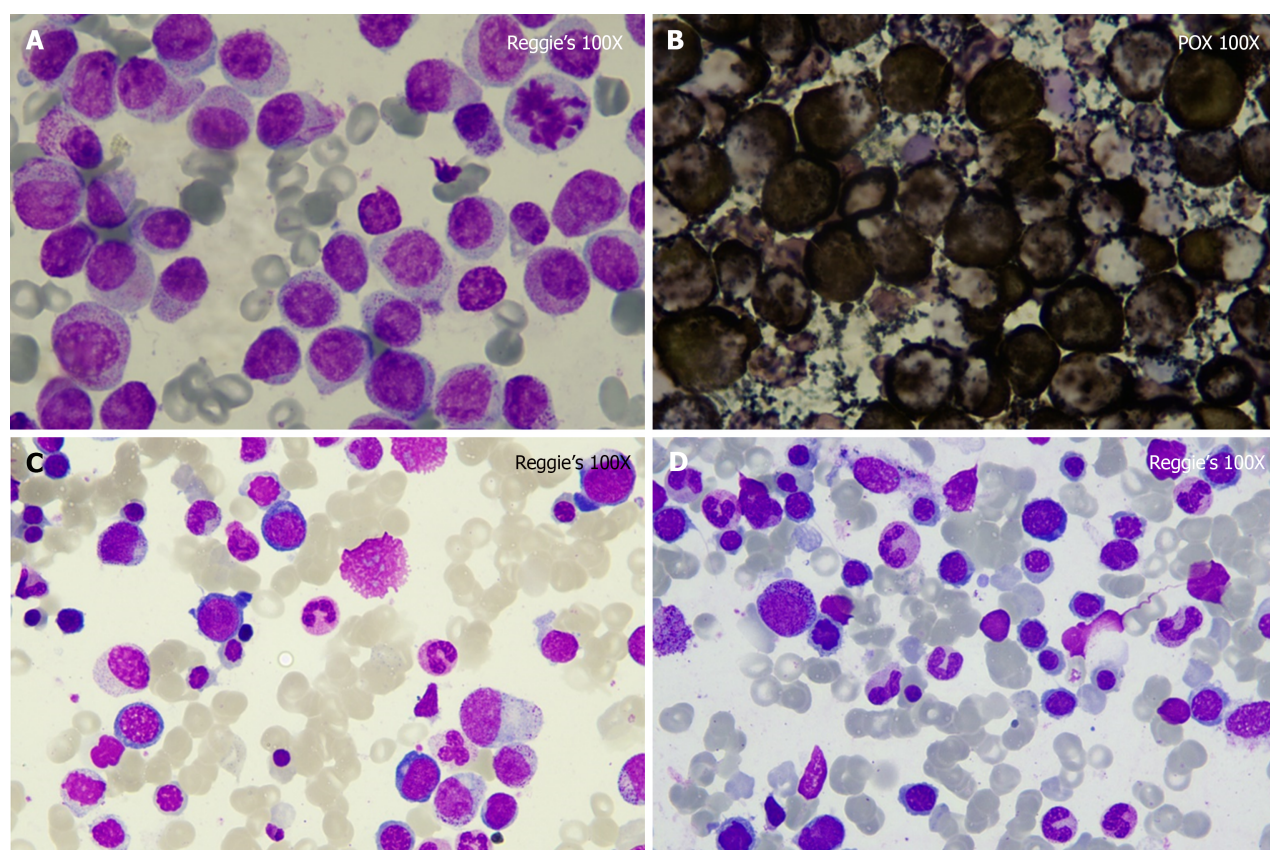
The patient had a history of smoking for more than 30 years (60 cigarettes per day) and drinking for more than 20 years (200 g of liquor per day). The patient's father had died of esophageal cancer.

### Physical examination

Physical symptoms were as follows: temperature, 36.8 °C; blood pressure, 132/75 mmHg; heart rate, 78 beats per min, and respiratory rate, 19 breaths per min. Physical examination revealed no palpable enlargement of the superficial lymph nodes throughout the body, no moist rales in either lungs, or hepatosplenomegaly.

### Laboratory examinations

Pancytopenia (absolute monocyte count:  $3.55 \times 10^9/L$ ; percentage monocyte: 53.30%; absolute neutrophil count:  $1.85 \times 10^9/L$ ; hemoglobin: 76 g/L; platelet:  $101 \times 10^9/L$ ) was identified during the initial examination. Peripheral blood smear revealed 54% blasts. C-reactive protein (190.39 mg/L), and D-dimer (29.64 mg/L) levels were increased. Bone marrow smear suggested a high probability of APL. Reggie's stain showed promyelocyte accounted for about 55% and Peroxidase stain was positivity (Figure 1A and B). A bone marrow biopsy was subsequently performed which revealed a small



DOI: 10.12998/wjcc.v12.i3.623 Copyright ©The Author(s) 2024.

**Figure 1** The patient's bone marrow smear at high magnification. A: Reggie's stain showed promyelocyte accounted for about 55%; B: Peroxidase stain was positivity; C and D: Reggie's stain twice showed that the patient achieved clinical complete response after chemotherapy.

number of cells with moderately enlarged cytosomes, deviated nuclei, fine chromatin, and inconspicuous nucleoli, requiring clinical and other tests to exclude AML. Flow cytometry of the specimens was consistent with the immunophenotype of APL. Leukemia-associated 45 fusion genes were not detected. Chromosomal karyotype analysis revealed the presence of 46, XY, i(7)(q10), inc(4)/46, XY(6). Fluorescence in situ hybridization confirmed the rearrangement of RARA. Hematology-associated fusion genes were identified, and the TNRC18-RARA fusion gene was detected. The patient underwent repeated bronchoscopies and the final bronchoalveolar lavage fluid (BALF) gene X-Pert test was positive.

### Imaging examinations

Chest computed tomography scans revealed bilateral pneumonitis with pleural effusion, partial atelectasis in the lower lobes of both lungs (Figure 2A). The patient's lung inflammation gradually deteriorated (Figure 2B). Multiple bronchoscopies were performed, and the BALF gene X-Pert test was positive.

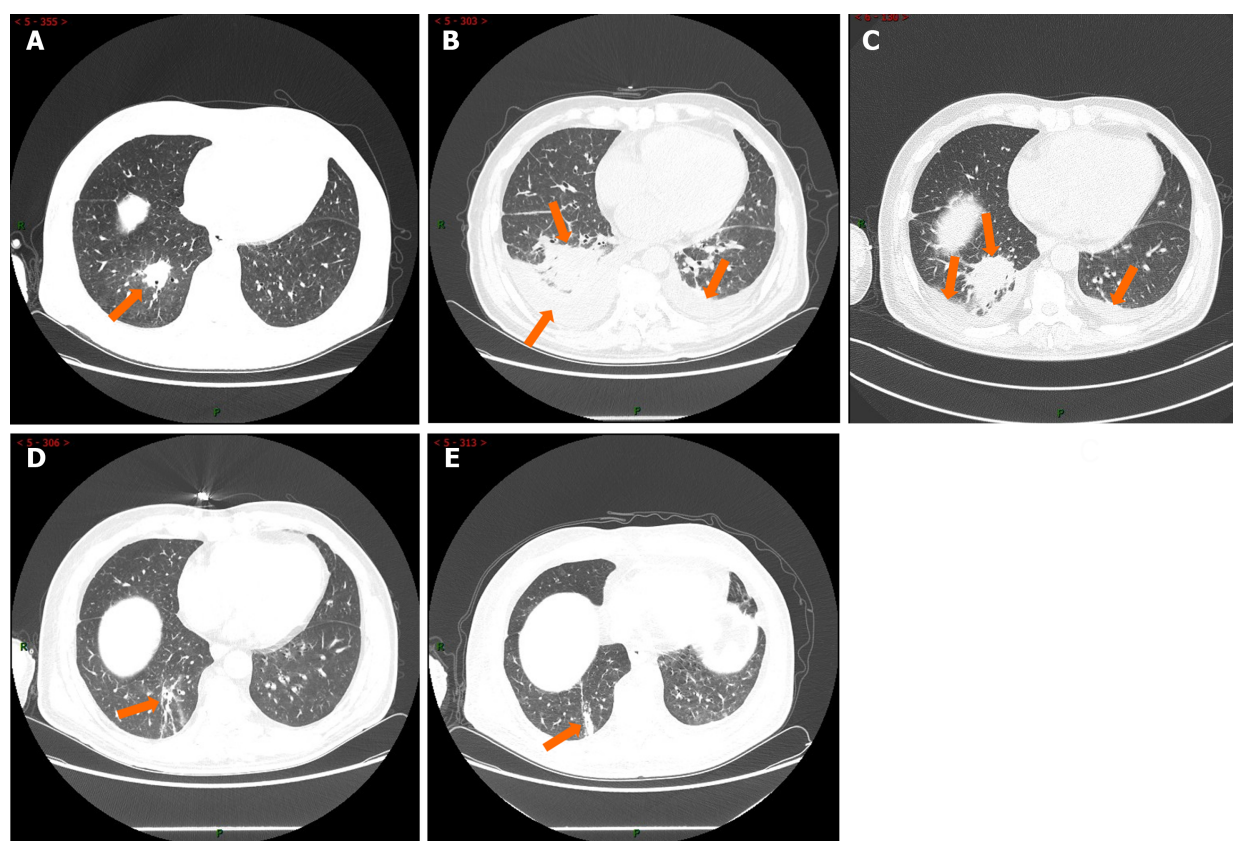
## FINAL DIAGNOSIS

The patient was finally diagnosed with APL combined with PTB.

## TREATMENT

Initially, the patient received treatment with ceftriaxone sodium, piperacillin-tazobactam, cefoperazone sodium, sulbactam sodium, meropenem, voriconazole, posaconazole, linezolid (LZD), caspofungin, and amphotericin B cholesteryl sulfate complex, which was ineffective, and he continued to experience fever recurrently (Figure 2A-C). During this period, the patient received three courses of chemotherapy for APL. After PTB diagnosis, he was administered rifampicin (0.45 g, qd), isoniazid (INH; 0.3 g, qd) and ethambutol (EMB; 0.75 g, qd) as anti-tuberculosis chemotherapy. Unfortunately, the patient's WBC count continued to decrease, making it impossible for the patient to continue anti-tuberculosis chemotherapy. Chemotherapy could not be administered for leukemia because PTB was not controlled, leading to recurrent fever. Therefore, carrimycin (0.4 g, qd) was administered to the patient for 24 d. His lung infection improved significantly. Rifampicin (0.45 g, qd), INH (0.3 g, qd) and EMB (0.75 g, qd) were administered as anti-





DOI: 10.12998/wjcc.v12.i3.623 Copyright ©The Author(s) 2024.

**Figure 2** The patient's chest computed tomography scan. A: computed tomography (CT) scan (March 21, 2022) showed consolidation of lung tissue in the right lower lobe (orange arrows) that may be inflammatory in origin; B: CT scan (April 8, 2022) showed the extent of lung consolidation increased in the right lower lobe with bilateral pleural effusion (orange arrows); C: CT scan (April 21, 2022) showed increased lung consolidation in the right lower lobe with decreased bilateral pleural effusion (orange arrows) after routine therapy with antibiotics; D: CT scan (July 20, 2022) showed pneumonitis in the right lower lobe was obvious to get an improvement (arrows) and the pleural effusion disappeared after carrimycin and anti-tuberculous treatment; E: CT scan (November 28, 2022) showed pneumonitis in the right lower lobe had been cured leaving scars (arrows).

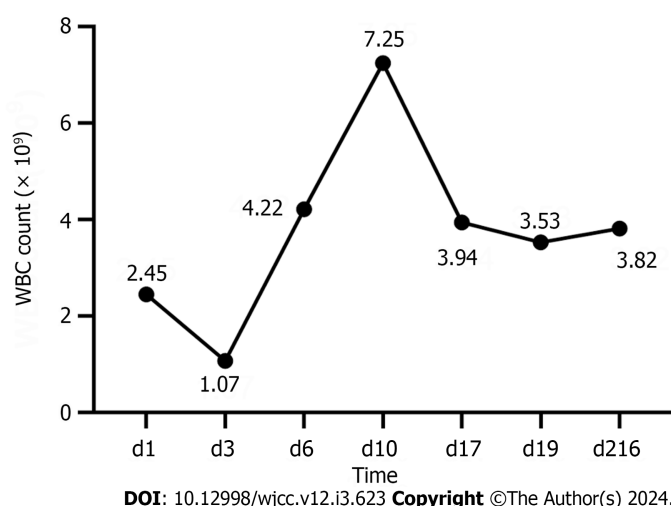
tuberculosis treatment for six months. The fourth cycle of venetoclax (200 mg on days 1–4, 400 mg on days 5–14) and azacitidine (100 mg on days 1–7) combination treatment for leukemia was initiated when the patient's white blood cell (WBC) count returned to the normal range. Reggie's stain twice showed that the patient achieved clinical complete response after chemotherapy (Figure 1C and D). PTB and APL showed complete remission after six months of treatment (Figure 2D and E). The changes of the patient's WBC count during treatment are shown in Figure 3.

## OUTCOME AND FOLLOW-UP

Carrimycin (0.4 g, qd) was administered for 24 d, and the lung infection improved dramatically. Chemotherapy for leukemia can be administered normally. The patient achieved complete remission after six months of treatment.

## DISCUSSION

APL is a highly heterogeneous disease caused by the aberrant differentiation of myeloid lineage cells in the hematopoietic system[4]. Patients with APL have reduced autoimmune function and are susceptible to co-infections. The risk of developing tuberculosis is higher in patients with hematological malignancies. A direct result of immunosuppression brought on by the malignancy, a side effect of treatment, or a combination of both can increase susceptibility to PTB[5]. Herein, we report a case of APL combined with PTB. X-Pert is a rapid nucleic acid amplification test used to tuberculosis [6]. The patient's BALF gene X-Pert test result was positive, confirming the diagnosis of tuberculosis. After a definitive diagnosis, the patient received both anti-tuberculosis and leukemia chemotherapy. However, anti-tuberculosis chemotherapy resulted in a persistent decrease in WBC count and was subsequently discontinued, causing recurrent fever, which made it impossible to properly administer leukemia chemotherapy. The patient was treated with carrimycin, INH, and EMB to control the lung infections so that leukemia chemotherapy could be administered. Surprisingly, the patient had no fever on the day carrimycin was added. The patient's WBC count normalized after five days of treatment,



**Figure 3** The change of patient's white blood cells during treatment. The patient's antibiotics uses: d1: Isoniazid 0.3 qd + rifampin 0.45 qd + ethambutol 0.75 qd; d3-d29: Carrimycin 0.4 qd (d10: chemotherapy); d29-d216: He got acute promyelocytic leukemia clinical complete response after chemotherapy and took isoniazid 0.3 qd + rifampin 0.45 qd + ethambutol 0.75 qd.

and the fourth cycle of leukemia chemotherapy with venetoclax combined with azacytidine was subsequently initiated. The patient achieved complete remission after six months of treatment.

APL and PTB have seldom been documented. Abdullah *et al*[7] described a case of APL combined with tuberculosis in a patient receiving the PETHEMA protocol consisting of ATRA plus Idarubicin and anti-TB treatment. Due to the interaction of several anti-tuberculosis drugs with chemotherapy, treating tuberculosis in patients with acute leukemia can be challenging. Susan Realegeno *et al*[8] reported a case of a patient with APL developing disseminated tuberculosis while undergoing APL therapy. The patient was treated with rifampin (RIF), pyrazinamide (PZA), moxifloxacin (MXF), and EMB, INH, levofloxacin, amikacin and LZD as anti-tuberculosis therapy. Conventional chemotherapy regimens for leukemia are myelosuppressive, making them ineffective for active PTB control[5]. Recurrent fever due to uncontrolled tuberculosis can limit the use of chemotherapeutic regimens for leukemia. RIF, INH, PZA, and EMB are well-known first-line medications. The selection of anti-tuberculosis drugs is limited owing to factors such as multidrug resistance and adverse effects of the drugs[9]. In our patient, carrimycin was added because of a persistent decrease in WBC count after the application of conventional anti-tuberculosis chemotherapy, which showed promising results for anti-tuberculosis treatment. Azacitidine has the potential to cause reactivation of tuberculosis[5].

Carrimycin is a new national class I drug that has been approved by the CFDA for treating acute tracheal bronchitis caused by *Haemophilus influenzae* and *Streptococcus pneumoniae* and acute sinusitis caused by *Streptococcus pneumoniae*, *Haemophilus influenzae*, *Streptococcus pyogenes*, *Moraxella catarrhalis*, and *Staphylococcus*[10]. Carrimycin exerts an inhibitory effect on inflammation[11]. Carrimycin considerably decreases interleukin (IL)-4 levels in the lungs and kidneys, especially in the liver and spleen. Furthermore, carrimycin significantly decreases IL-1 $\beta$  levels in the spleen, liver, and kidneys, especially in the small intestine and the lungs, showing an excellent anti-inflammatory effect[11]. Second, carrimycin is a novel macrolide antibiotic with excellent antibacterial effects that can inhibit bacterial protein synthesis by blocking the activity of peptidyl transferase in the 50s ribosome subunit to develop antibacterial effects[11]. Carrimycin has significant efficacy against multidrug-resistant bacteria that do not respond to conventional anti-infective treatment [12]. Carrimycin is a dual-acting immunoantibiotic with antibacterial and immunomodulatory properties. In terms of intrinsic immunity, carrimycin promotes neutrophil migration to the sites of inflammation and enhances phagocytosis by macrophages. In terms of adaptive immunity, carrimycin significantly increased the total T-cell population (CD3-positive cells), along with an increase in both CD4- and CD8-positive cells. Overall, carrimycin can kill pathogens directly while enhancing the host's immune response and indirectly killing bacteria. The normal WBC count was achieved in the patient after the application of carrimycin, and we speculate that carrimycin has a WBC count-increasing effect, which enhances host immunity by flipping the host's immune switch, thus eradicating pathogens. Thus, carrimycin is a novel therapeutic option for patients with APL and TB. Carrimycin also shows broad-spectrum antiviral efficacy against human coronaviruses (HCoVs) by targeting the post-entry replication event and inhibiting HCoV RNA synthesis[10]. Moreover, it has potential antitumor activity through the inhibition of protein synthesis to regulate cell physiology, proliferation, and immunity[13]. Cui *et al*[14] found that the main component of carrimycin, isovalerylspiramycin I, suppresses tumorigenesis and metastasis. It is effective in the treatment of non-small cell lung cancer, head and neck tumors, and hepatocellular carcinoma[15]. Therefore, we speculated that carrimycin also exerts an inhibitory effect on hematological tumors.

## CONCLUSION

Herein, we report a case of APL combined with PTB. Given that the patient's WBC count continued to decrease, we added carrimycin to the PTB treatment and achieved excellent therapeutic outcomes. This study provides a reference for

the treatment of patients with APL and TB. The therapeutic efficacy of carrimycin in APL accompanied by PTB requires further investigation.

## FOOTNOTES

**Author contributions:** Yang FY and Shao L contributed to manuscript writing; Su J contributed to data curation and review; Shao L and Zhang ZM contributed to manuscript and figure editing; All authors have read and approved the final manuscript.

**Informed consent statement:** Written informed consent was obtained from the patient to publish this paper.

**Conflict-of-interest statement:** The authors declare having no conflicts of interest.

**CARE Checklist (2016) statement:** The authors have read the CARE Checklist (2016), and the manuscript was prepared and revised according to the CARE Checklist (2016).

**Open-Access:** This article is an open-access article that was selected by an in-house editor and fully peer-reviewed by external reviewers. It is distributed in accordance with the Creative Commons Attribution NonCommercial (CC BY-NC 4.0) license, which permits others to distribute, remix, adapt, build upon this work non-commercially, and license their derivative works on different terms, provided the original work is properly cited and the use is non-commercial. See: <https://creativecommons.org/licenses/by-nc/4.0/>

**Country/Territory of origin:** China

**ORCID number:** Lei Shao 0009-0000-3574-5465.

**S-Editor:** Zhang H

**L-Editor:** A

**P-Editor:** Cai YX

## REFERENCES

- Ji L, Yang W, Xu XF, Xu YQ. A case report of complete remission of acute myeloid leukemia combined with DNMT3A, FLT3-TKD, and IDH2 gene mutations and active pulmonary tuberculosis treated with homeharringtonine + venetoclax + azacitidine. *Front Med (Lausanne)* 2023; **10**: 1180757 [PMID: 37384044 DOI: 10.3389/fmed.2023.1180757]
- Logan C, Koura D, Taplitz R. Updates in infection risk and management in acute leukemia. *Hematology Am Soc Hematol Educ Program* 2020; **2020**: 135-139 [PMID: 33275701 DOI: 10.1182/hematology.2020000098]
- Parker VR, Bennet JA, Sanne IM. An incidental finding of chronic lymphocytic leukaemia in a patient with pulmonary tuberculosis. *S Afr J Infect Dis* 2020; **35**: 218 [PMID: 34485482 DOI: 10.4102/sajid.v35i1.218]
- Cao Z, Shu Y, Wang J, Wang C, Feng T, Yang L, Shao J, Zou L. Super enhancers: Pathogenic roles and potential therapeutic targets for acute myeloid leukemia (AML). *Genes Dis* 2022; **9**: 1466-1477 [PMID: 36157504 DOI: 10.1016/j.gendis.2022.01.006]
- Pescatore J, Cohen A, Moturi K, Hernandez-Acosta R. Reactivation of Pulmonary Tuberculosis During Treatment of Chronic Myelomonocytic Leukemia. *Cureus* 2021; **13**: e15491 [PMID: 34268023 DOI: 10.7759/cureus.15491]
- Pillay S, Steingart KR, Davies GR, Chaplin M, De Vos M, Schumacher SG, Warren R, Theron G. Xpert MTB/XDR for detection of pulmonary tuberculosis and resistance to isoniazid, fluoroquinolones, ethionamide, and amikacin. *Cochrane Database Syst Rev* 2022; **5**: CD014841 [PMID: 35583175 DOI: 10.1002/14651858.CD014841.pub2]
- Abdullah AS, Adel AM, Hussein RM, Abdullah MA, Yousaf A, Mudawi D, Mohamed SF, Nashwan AJ, Soliman D, Ibrahim F, Yassin MA. Hypercalcemia and acute pancreatitis in a male patient with acute promyelocytic leukemia and pulmonary tuberculosis. *Acta Biomed* 2018; **89**: 23-27 [PMID: 29633729 DOI: 10.23750/abm.v89i3-S.7216]
- Realegeno S, Adeyiga O, Winston DJ, Beaird OE, Garner OB, Yang S. Utilization of whole genome sequencing for resolution of discrepant Mycobacterium tuberculosis drug susceptibility results: A case report. *IDCases* 2021; **26**: e01308 [PMID: 34745885 DOI: 10.1016/j.idcr.2021.e01308]
- Lan Z, Ahmad N, Baghaei P, Barkane L, Benedetti A, Brode SK, Brust JCM, Campbell JR, Chang VWL, Falzon D, Guglielmetti L, Isaakidis P, Kempker RR, Kipiani M, Kuksa L, Lange C, Laniado-Laborin R, Nahid P, Rodrigues D, Singla R, Udawadia ZF, Menzies D; Collaborative Group for the Meta-Analysis of Individual Patient Data in MDR-TB treatment 2017. Drug-associated adverse events in the treatment of multidrug-resistant tuberculosis: an individual patient data meta-analysis. *Lancet Respir Med* 2020; **8**: 383-394 [PMID: 32192585 DOI: 10.1016/S2213-2600(20)30047-3]
- Yan H, Sun J, Wang K, Wang H, Wu S, Bao L, He W, Wang D, Zhu A, Zhang T, Gao R, Dong B, Li J, Yang L, Zhong M, Lv Q, Qin F, Zhuang Z, Huang X, Yang X, Li Y, Che Y, Jiang J. Repurposing carrimycin as an antiviral agent against human coronaviruses, including the currently pandemic SARS-CoV-2. *Acta Pharm Sin B* 2021; **11**: 2850-2858 [PMID: 33723501 DOI: 10.1016/j.apsb.2021.02.024]
- Li XY, Luo YT, Wang YH, Yang ZX, Shang YZ, Guan QX. Anti-inflammatory effect and antihepatoma mechanism of carrimycin. *World J Gastroenterol* 2023; **29**: 2134-2152 [PMID: 37122599 DOI: 10.3748/wjg.v29.i14.2134]
- Zhu W, Tian Y, Xiang L, Cao L, He L. A Case of Multidrug-Resistant Klebsiella pneumoniae Treated with Carrimycin. *Infect Drug Resist* 2023; **16**: 2365-2369 [PMID: 37113529 DOI: 10.2147/IDR.S407076]
- Liang SY, Zhao TC, Zhou ZH, Ju WT, Liu Y, Tan YR, Zhu DW, Zhang ZY, Zhong LP. Anti-tumor effect of carrimycin on oral squamous cell carcinoma cells in vitro and in vivo. *Transl Oncol* 2021; **14**: 101074 [PMID: 33744726 DOI: 10.1016/j.tranon.2021.101074]
- Cui J, Zhou J, He W, Ye J, Westlake T, Medina R, Wang H, Thakur BL, Liu J, Xia M, He Z, Indig FE, Li A, Li Y, Weil RJ, Aladjem MI,

- Zhong L, Gilbert MR, Zhuang Z. Targeting selenoprotein H in the nucleolus suppresses tumors and metastases by Isovalerylspiramycin I. *J Exp Clin Cancer Res* 2022; **41**: 126 [PMID: [35387667](#) DOI: [10.1186/s13046-022-02350-0](#)]
- 15 Liu Z, Huang M, Hong Y, Wang S, Xu Y, Zhong C, Zhang J, Zhuang Z, Shan S, Ren T. Isovalerylspiramycin I suppresses non-small cell lung carcinoma growth through ROS-mediated inhibition of PI3K/AKT signaling pathway. *Int J Biol Sci* 2022; **18**: 3714-3730 [PMID: [35813464](#) DOI: [10.7150/ijbs.69989](#)]





Published by **Baishideng Publishing Group Inc**  
7041 Koll Center Parkway, Suite 160, Pleasanton, CA 94566, USA

**Telephone:** +1-925-3991568

**E-mail:** [office@baishideng.com](mailto:office@baishideng.com)

**Help Desk:** <https://www.f6publishing.com/helpdesk>

<https://www.wjgnet.com>

