

World Journal of *Clinical Cases*

World J Clin Cases 2024 March 16; 12(8): 1382-1548



Contents

Thrice Monthly Volume 12 Number 8 March 16, 2024

EDITORIAL

- 1382 Latest updates on structure and recommendations of cardiac rehabilitation programs in chronic heart failure
Kourek C, Briasoulis A, Magouliotis DE, Skoularigis J, Xanthopoulos A
- 1388 Immunoglobulin A glomerulonephropathy: A review
El Labban M, Surani S

ORIGINAL ARTICLE

Retrospective Study

- 1395 Serum proteins differentially expressed in gestational diabetes mellitus assessed using isobaric tag for relative and absolute quantitation proteomics
Cao WL, Yu CP, Zhang LL

Observational Study

- 1406 Effect of comprehensive nursing on the quality of life and swallowing function in individuals diagnosed with ischemic stroke
Hu HF, Sang YF, Xiao YQ

META-ANALYSIS

- 1416 Safety and effectiveness of butorphanol in epidural labor analgesia: A protocol for a systematic review and meta-analysis
Tang GC, He M, Huang ZZ, Cheng Y

CASE REPORT

- 1422 Left lower lobe sleeve resection for the clear cell variant of pulmonary mucoepidermoid carcinoma: A case report
Yu XH, Wang WX, Yang DS, Gong LH
- 1430 Lower extremity peripherally inserted central catheter placement ectopic to the ascending lumbar vein: A case report
Zhu XJ, Zhao L, Peng N, Luo JM, Liu SX
- 1437 Effect of foot reflexology on an infant with sensorineural hearing loss: A case report
Lee YJ, Chen MQ, Dong J
- 1442 Development of immature ovarian teratoma after mature teratoma in a girl with familial ovarian teratoma: A case report
Ju UC, Kang WD, Kim SM

- 1448** Metastatic clear cell sarcoma of the pancreas: A rare case report
Liu YJ, Zou C, Wu YY
- 1454** 3M syndrome patient with a novel mutation: A case report
Luo MR, Dai SM, Li Y, Wang Q, Liu H, Gao P, Liu JY, Chen J, Zhao SJ, Yin GY
- 1461** Appendiceal intussusception complicated by adenocarcinoma of the cecum: A case report
Long Y, Xiang YN, Huang F, Xu L, Li XY, Zhen YH
- 1467** Malignant triton tumor in the abdominal wall: A case report
Yang HJ, Kim D, Lee WS, Oh SH
- 1474** Multilocular thymic cysts can be easily misdiagnosed as malignant tumor on computer tomography: A case report
Sun J, Yang QN, Guo Y, Zeng P, Ma LY, Kong LW, Zhao BY, Li CM
- 1481** Diagnosis of poorly differentiated adenocarcinoma of the stomach by confocal laser endomicroscopy: A case report
Lou JX, Wu Y, Huhe M, Zhang JJ, Jia DW, Jiang ZY
- 1487** High-grade pancreatic intraepithelial neoplasia diagnosed based on changes in magnetic resonance cholangiopancreatography findings: A case report
Furuya N, Yamaguchi A, Kato N, Sugata S, Hamada T, Mizumoto T, Tamaru Y, Kusunoki R, Kuwai T, Kouno H, Kuraoka K, Shibata Y, Tazuma S, Sudo T, Kohno H, Oka S
- 1497** Chronic infectious unilateral giant thyroid cyst related to diabetes mellitus: A case report
Liu JB, Zhang SL, Jiang WL, Sun HK, Yang HC
- 1504** Multiple thoracic and abdominal foregut duplication cysts: A case report
Alsinan TA, Altokhais TI
- 1510** Advanced cervix cancer patient with chemotherapy-induced grade IV myelosuppression achieved complete remission with cadonilimab: A case report
Zhu R, Chen TZ, Sun MT, Zhu CR
- 1517** Detection of 4p16.3 deletion and 11p15.5p15.4 gain in a boy by comparative genomic hybridization array: A case report
Kaya I
- 1523** Eccrine porocarcinoma in the temple of an elderly woman: A case report
Wu ZW, Zhu WJ, Huang S, Tan Q, You C, Hu DG, Li LN
- 1530** Analysis and monitoring of drug therapy in a patient with peptic ulcer complicated by infection: A case report
Gou YP, Huang Y, Chen L, Zheng W, Zheng YH
- 1536** Primary gastroduodenal tuberculosis presenting as gastric outlet obstruction: A case report and review of literature
Ali AM, Mohamed YG, Mohamud AA, Mohamed AN, Ahmed MR, Abdullahi IM, Saydam T

- 1544** Clinical manifestations and the prenatal diagnosis of trisomy 7 mosaicism: Two case reports

Hou F, Li Y, Jin H

ABOUT COVER

Peer Reviewer of *World Journal of Clinical Cases*, Makram Koubaa, MD, Assistant Professor, Department of Infectious Diseases, Hedi Chaker University Hospital, Sfax 3029, Tunisia. makram.koubaa@gmail.com

AIMS AND SCOPE

The primary aim of *World Journal of Clinical Cases* (WJCC, *World J Clin Cases*) is to provide scholars and readers from various fields of clinical medicine with a platform to publish high-quality clinical research articles and communicate their research findings online.

WJCC mainly publishes articles reporting research results and findings obtained in the field of clinical medicine and covering a wide range of topics, including case control studies, retrospective cohort studies, retrospective studies, clinical trials studies, observational studies, prospective studies, randomized controlled trials, randomized clinical trials, systematic reviews, meta-analysis, and case reports.

INDEXING/ABSTRACTING

The WJCC is now abstracted and indexed in Science Citation Index Expanded (SCIE, also known as SciSearch®), Journal Citation Reports/Science Edition, Current Contents®/Clinical Medicine, PubMed, PubMed Central, Reference Citation Analysis, China Science and Technology Journal Database, and Superstar Journals Database. The 2023 Edition of Journal Citation Reports® cites the 2022 impact factor (IF) for WJCC as 1.1; IF without journal self cites: 1.1; 5-year IF: 1.3; Journal Citation Indicator: 0.26; Ranking: 133 among 167 journals in medicine, general and internal; and Quartile category: Q4.

RESPONSIBLE EDITORS FOR THIS ISSUE

Production Editor: Hua-Ge Yin, Production Department Director: Xu Guo, Editorial Office Director: Jin-Lei Wang.

NAME OF JOURNAL

World Journal of Clinical Cases

ISSN

ISSN 2307-8960 (online)

LAUNCH DATE

April 16, 2013

FREQUENCY

Thrice Monthly

EDITORS-IN-CHIEF

Bao-Gan Peng, Salim Surani, Jerzy Tadeusz Chudek, George Kontogeorgos, Maurizio Serati

EDITORIAL BOARD MEMBERS

<https://www.wjgnet.com/2307-8960/editorialboard.htm>

PUBLICATION DATE

March 16, 2024

COPYRIGHT

© 2024 Baishideng Publishing Group Inc

INSTRUCTIONS TO AUTHORS

<https://www.wjgnet.com/bpg/gerinfo/204>

GUIDELINES FOR ETHICS DOCUMENTS

<https://www.wjgnet.com/bpg/GerInfo/287>

GUIDELINES FOR NON-NATIVE SPEAKERS OF ENGLISH

<https://www.wjgnet.com/bpg/gerinfo/240>

PUBLICATION ETHICS

<https://www.wjgnet.com/bpg/GerInfo/288>

PUBLICATION MISCONDUCT

<https://www.wjgnet.com/bpg/gerinfo/208>

ARTICLE PROCESSING CHARGE

<https://www.wjgnet.com/bpg/gerinfo/242>

STEPS FOR SUBMITTING MANUSCRIPTS

<https://www.wjgnet.com/bpg/GerInfo/239>

ONLINE SUBMISSION

<https://www.f6publishing.com>



Diagnosis of poorly differentiated adenocarcinoma of the stomach by confocal laser endomicroscopy: A case report

Jia-Xin Lou, Yong Wu, Muren Huhe, Jing-Jie Zhang, Dong-Wu Jia, Zhen-Yu Jiang

Specialty type: Medicine, research and experimental

Provenance and peer review: Unsolicited article; Externally peer reviewed.

Peer-review model: Single blind

Peer-review report's scientific quality classification

Grade A (Excellent): 0
Grade B (Very good): 0
Grade C (Good): 0
Grade D (Fair): D
Grade E (Poor): 0

P-Reviewer: Limaïem F, Tunisia

Received: December 9, 2023

Peer-review started: December 9, 2023

First decision: January 5, 2024

Revised: January 20, 2024

Accepted: February 25, 2024

Article in press: February 25, 2024

Published online: March 16, 2024



Jia-Xin Lou, Yong Wu, Jing-Jie Zhang, Dong-Wu Jia, Zhen-Yu Jiang, Department of Gastroenterology, The Second Affiliated Hospital of Baotou Medical College, Inner Mongolia University of Science and Technology, Baotou 014030, Inner Mongolia Autonomous Region, China

Muren Huhe, Medical Innovation Center, The Fourth Military Medical University, Xi'an 710000, Shaanxi Province, China

Corresponding author: Zhen-Yu Jiang, PhD, Doctor, Department of Gastroenterology, The Second Affiliated Hospital of Baotou Medical College, Inner Mongolia University of Science and Technology, No. 30 Hude Mulin Street, Qingshan District, Baotou 014000, Inner Mongolia Autonomous Region, China. jzhy1981@foxmail.com

Abstract

BACKGROUND

In recent years, confocal laser endomicroscopy (CLE) has become a new endoscopic imaging technology at the microscopic level, which is extensively performed for real-time *in vivo* histological examination. CLE can be performed to distinguish benign from malignant lesions. In this study, we diagnosed using CLE an asymptomatic patient with poorly differentiated gastric adenocarcinoma.

CASE SUMMARY

A 63-year-old woman was diagnosed with gastric mucosal lesions, which may be gastric cancer, in the small curvature of the stomach by gastroscopy. She consented to undergo CLE for morphological observation of the gastric mucosa. Through the combination of CLE diagnosis and postoperative pathology, the intraoperative CLE diagnosis was considered to be reliable. According to our experience, CLE can be performed as the first choice for the diagnosis of gastric cancer.

CONCLUSION

CLE has several advantages over pathological diagnosis. We believe that CLE has great potential in the diagnosis of benign and malignant gastric lesions.

Key Words: Confocal laser endomicroscopy; Poorly differentiated gastric adenocarcinoma; Diagnosis; Early stage; Case report

©The Author(s) 2024. Published by Baishideng Publishing Group Inc. All rights reserved.

Core Tip: Confocal laser microscopic endoscope (CLE) is a relatively new endoscopic imaging technology. It provides a real-time microscopic vision of mucosal epithelium physiology and pathology in natural state. Gastric cancer is a common disease in clinic. Early symptoms are hidden, and patients do not pay enough attention to them. In this case, a woman was diagnosed gastric poorly differentiated adenocarcinoma by CLE in the small curvature by gastroscopy. Through the combination of CLE and pathology, the intraoperative CLE diagnosis was considered to be reliable. According to our experience, CLE can be used as the first choice for the diagnosis of gastric cancer.

Citation: Lou JX, Wu Y, Huhe M, Zhang JJ, Jia DW, Jiang ZY. Diagnosis of poorly differentiated adenocarcinoma of the stomach by confocal laser endomicroscopy: A case report. *World J Clin Cases* 2024; 12(8): 1481-1486

URL: <https://www.wjgnet.com/2307-8960/full/v12/i8/1481.htm>

DOI: <https://dx.doi.org/10.12998/wjcc.v12.i8.1481>

INTRODUCTION

Confocal laser endomicroscopy (CLE) is a relatively new endoscopic imaging technology. It is a supplement to histopathology and also provides real-time microscopic visualization of mucosal epithelium physiology and pathology in the natural state. The magnification can reach 500 times or more. Because of its real-time detection and virtual tissue imaging, it can be performed for the endoscopic study of living cells. For these reasons, CLE is usually called "optical biopsy."

Gastric cancer is a common disease worldwide. Early symptoms are hidden, and patients do not pay enough attention to them. Many cases are in the middle and late stages when found by gastroscopy. To improve the diagnosis rate of early gastric cancer, pathological biopsy is often performed for gastric mucosal lesions > 1 cm. Although the gold standard for the diagnosis of gastric cancer is still pathological biopsy, obtaining an effective pathological diagnosis depends on the accuracy of the sampling site and the experience of pathologists. Human factors have a great influence, so there are still opportunities for enhancement in the diagnosis of early gastric cancer.

CLE based on a probe can diagnose gastric cancer through the working channel of the gastroscopy. Therefore, we performed CLE combined with pathological biopsy to obtain the diagnosis of gastric cancer, with the risk of gastric malignant tumor, which provides a clinical basis for subsequent treatment.

CASE PRESENTATION

Chief complaints

On November 6, 2023, a 63-year-old woman presented to The Second Affiliated Hospital of Baotou Medical College (Baotou, China). The patient had intermittent epigastric discomfort without obvious inducement six months ago, had taken omeprazole and other drugs, and the effect was not good.

History of present illness

The patient has not lost weight since the onset of the disease. She did not complain of abdominal pain.

History of past illness

The patient has denied the history of heart disease, hypertension and diabetes.

Personal and family history

The patient's father has cardiac cancer.

Physical examination

During gastroscopy, the patient temperature was 36.6 °C, heart rate 78 bpm, respiratory rate 18 breaths/min, blood pressure 134/75 mmHg, and oxygen saturation in room air 99%.

Laboratory examinations

The Gastric function examination: Pepsinogen I 296.19 g/L, Pepsinogen II 17.41 g/L, Gastrin 17 49.10 pg/mL; There were no abnormalities in electrocardiogram, blood routine examination and infection test.

Imaging examinations

No relevant imaging examination was done.

FINAL DIAGNOSIS

The patient was diagnosed with poorly differentiated adenocarcinoma of the stomach.

TREATMENT

The patient, a 63-year-old woman, had been experiencing intermittent abdominal distension with hiccups for more than 0.5 years, which was aggravated for more than 1 month. The patient underwent a gastroscopy in the Digestive Endoscopy Center of the Second Affiliated Hospital of Baotou Medical College on November 6, 2023. White-light gastroscopy revealed that in the gastric antrum, the mucosa was red and white, mainly red, with peristalsis, and the mucosa was rough on the front wall of small curvature. In the stomach body, the shape and peristalsis of the folds were normal, the flaky mucosa was red, the center was depressed, and a small ulcer had formed on the small curvature (Figure 1A). Narrow band imaging magnification indicated that the flaky mucosa was brown with clear boundaries between surrounding tissues, glands were missing from the center, blood vessels were twisted and climbing, and the mucosa was brittle (Figure 1B). It was highly suggested that the small curvature of the stomach had a high probability of becoming cancerous.

To further determine the characteristics of the lesion, after acquiring the consent of the family members, a CLE was performed. Because intravenous fluorescein sodium stain in CLE examination is required, to avoid serious allergic reactions in the patient, a sodium fluorescein allergy test was performed. After a negative result was obtained, a CLE examination was performed at the mucosal depression on the small curvature of the stomach, suggesting that the normal gastric pit structure disappeared, the glandular duct structure disappeared, and the cell polarity was abnormal (Figure 2). Biopsy with forceps in the positive part of the CLE examination revealed poor tissue quality, poor elasticity, and easy bleeding. Pathology suggested adenocarcinoma (moderately poorly differentiated, intramucosal, hand-held type) (Figure 3). CLE and pathological results indicated that the patient had a poorly differentiated adenocarcinoma of the small curvature of the stomach.

OUTCOME AND FOLLOW-UP

Upon active communication with the patient and her family about the severity of the disease and the follow-up treatment plan, the patient agreed to undergo elective surgical treatment.

DISCUSSION

The gold standard for diagnosis of most gastrointestinal disorders is endoscopic tissue sampling with histopathology. The differentiation between malignant and benign lesions is crucial for further management. However, random biopsies involve flaws that may be incurred, such as sampling errors[1,2]. CLE is a new type of microscope that integrates optical microscopy technology, laser scanning technology, and computer image processing software, and it is the only endoscopic imaging technology that can pathologically diagnose living tissues in real time. CLE is known as optical biopsy, magnifying the cross-sectional gray-scale image 500 times to observe the digestive tract mucosa at the subcellular level. CLE has only been put into clinical application for more than 10 years, which has extraordinary application value in many gastrointestinal diseases, especially in early tumor screening and precancerous lesion monitoring, and has ushered in a new era for endoscopic diagnosis of gastrointestinal diseases. Studies have revealed that the sensitivity and specificity of CLE in distinguishing gastric mucosal tumors from nontumor lesions can reach 90.2% and 98.5%, respectively[3]. The sensitivity, specificity, and accuracy of CLE in the diagnosis of early gastric cancer reached 88.9%, 99.3%, and 98.9%, respectively[4]. The prospective study of Bok *et al*[5] found that the accuracy of CLE in diagnosing gastric cancer was higher than that of general endoscopy (90.7% *vs* 85.2%), and the accuracy of combined diagnosis of CLE and histopathology could reach 98.1%. It is difficult to distinguish superficial gastric microcarcinomas from noncancerous lesions under conventional white-light endoscopy, which further increases the number of unnecessary biopsies. CLE has changed this situation because it can directly provide histological observation *in vivo*, and it may be extensively performed in the diagnosis and treatment of digestive tract tumors as a new technology to replace histopathological biopsy in the future. Furthermore, CLE is easy to be controlled by doctors. With only a short learning curve, doctors can achieve a reliable CLE diagnostic level through training. In this regard, pathological biopsy diagnosis is not easily comparable[6].

Gastric cancer has a high incidence in China and is one of the most common malignant digestive tract tumors worldwide. The mortality of gastric cancer accounts for more than 20% of the total tumor mortality[7]. Because the early symptoms are hidden or patients do not pay enough attention to them, many patients are in the middle and late stages when they are diagnosed by gastroscopy, and most patients still have recurrence and metastasis after comprehensive treatment, with high mortality. In gastric cancer, poorly differentiated adenocarcinoma is a type with a relatively high degree of malignancy. The clinical manifestations are dull pain in the upper abdomen, fullness, and discomfort, and some patients may experience no discomfort. When cases are found, they are usually in the middle and late stages, with rapid onset and poor prognosis[8]. Therefore, the treatment of poorly differentiated gastric adenocarcinoma is relatively

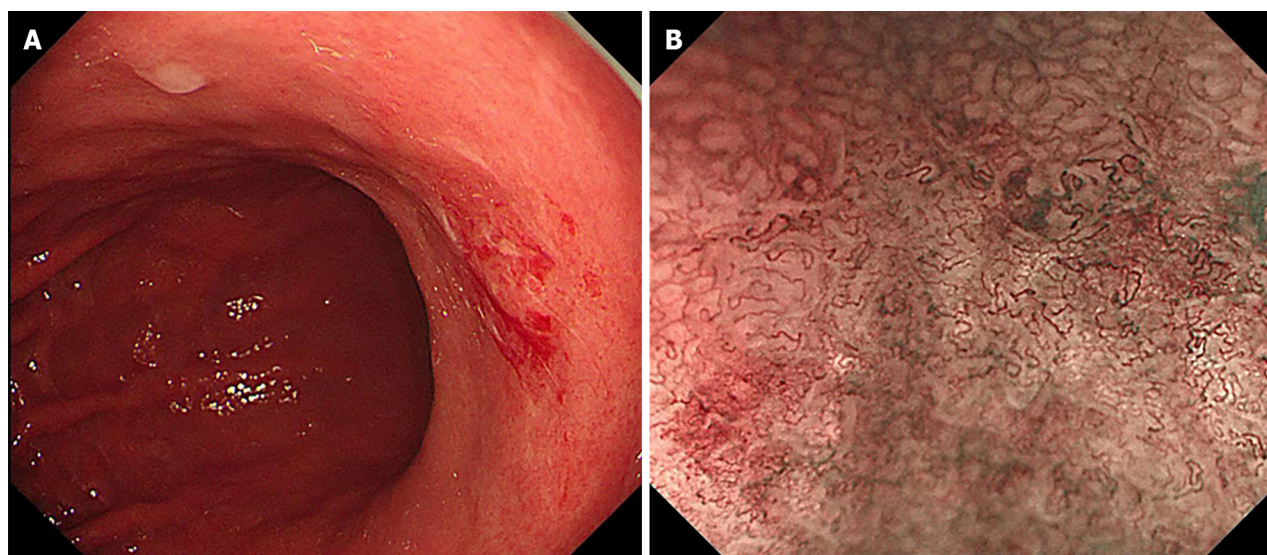


Figure 1 Gastroscopy features. A: Endoscopy observation of the small curvature of the stomach; B: Magnified Narrow band imaging examination of the gastric mucosa. NBI: Narrow band imaging.

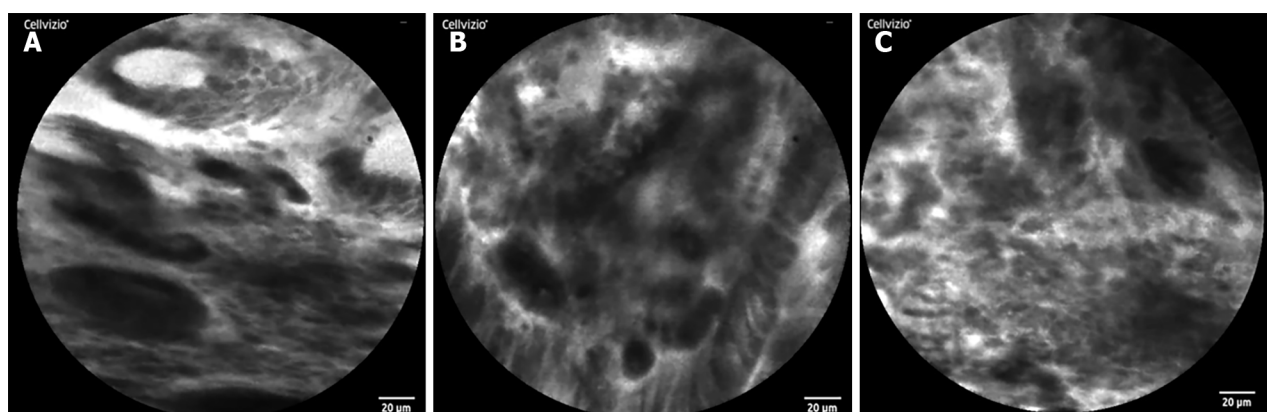


Figure 2 Confocal endomicroscopy features. A and B: Differentiated adenocarcinoma displaying a disorganized epithelium with dark and irregular glands; C: Undifferentiated adenocarcinoma characterized by dark and irregular cells with no identifiable glandular structures.

difficult, and the treatment of early poorly differentiated gastric adenocarcinoma is still mainly surgical resection[9]. Early detection and intervention are the most effective and economical therapeutic strategies.

Through CLE, our patient was diagnosed early, which provided good conditions for subsequent surgical treatment. According to a literature review, many genes play a regulatory role in the occurrence and development of gastric cancer, such as increased expression of notch homolog 1, recombinant hairy and enhancer of split 1, and calcium activated neutral proteinase 1, which regulate the invasion ability of gastric cancer cells by participating in cell adhesion and epithelial-mesenchymal transition[10]. To date, the pathogenesis of poorly differentiated gastric adenocarcinoma remains to be elucidated, and the prognosis of surgical treatment and postoperative comprehensive treatment is poor. Therapeutic large scale clinical trials showed that public health drive to reduce the prevalence of *Helicobacter pylori* as a strategy to reduce the incidence of gastric cancer in the population[7]. At present, the relationship between poorly differentiated gastric adenocarcinoma and *Helicobacter pylori* infection has not been supported by clear research evidence. Therefore, the primary goal is to improve the diagnosis rate of early gastric cancer through endoscopy to improve the prognosis of early gastric cancer. We believe that CLE can be performed as an examination tool for the diagnosis of early gastric cancer and can be broadly popularized in this field.

CONCLUSION

Based on our experience, CLE technology should be performed as the first choice for the diagnosis of early gastric cancer. We believe that CLE has great potential in this field.

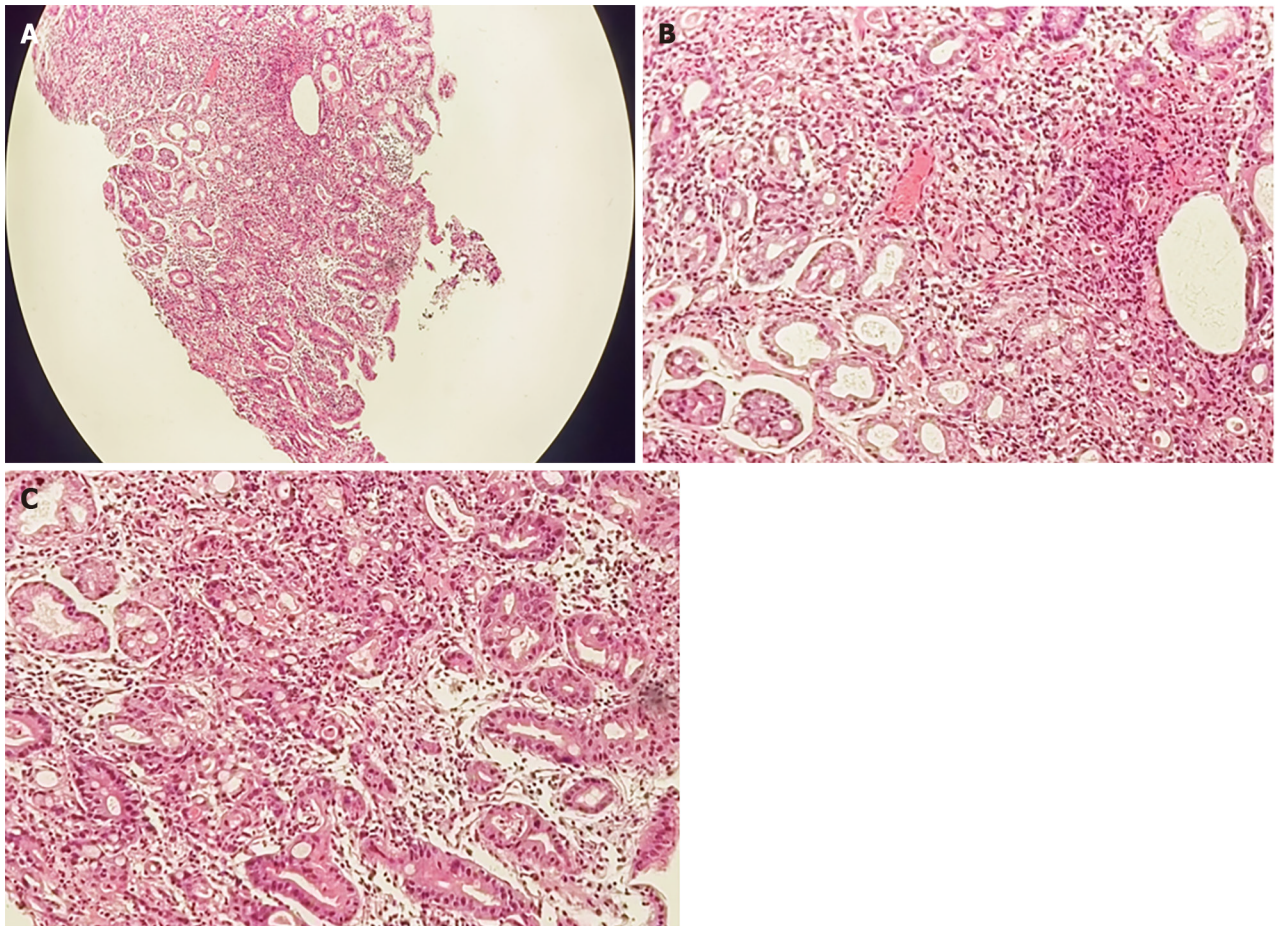


Figure 3 Histological examinations of the gastric mucosa by Hematoxylin-eosin staining revealed the pathology. A: Under 40 × magnification; B and C: Under 200 × magnification.

ACKNOWLEDGEMENTS

We are grateful for the understanding and cooperation of the patient.

FOOTNOTES

Author contributions: Lou JX and Jiang ZY designed the research study; Wu Y, Huhe M, Zhang JJ and Jia DW performed the research and collected the case information; Lou JX analyzed the data and wrote the manuscript. All authors have read and approve the final manuscript.

Supported by The Health Science and Technology Foundation of Inner Mongolia, No. 202201436; Science and Technology Innovation Foundation of Inner Mongolia, No. CXYD2022BT01.

Informed consent statement: All study participants, or their legal guardian, provided informed written consent prior to study enrollment.

Conflict-of-interest statement: Lou JX has received research funding from the Health Science and Technology Foundation of Inner Mongolia (202201436). Jiang ZY has received research funding from the Science and Technology Innovation Foundation of Inner Mongolia (CXYD2022BT01).

CARE Checklist (2016) statement: The authors have read the CARE Checklist (2016), and the manuscript was prepared and revised according to the CARE Checklist (2016).

Open-Access: This article is an open-access article that was selected by an in-house editor and fully peer-reviewed by external reviewers. It is distributed in accordance with the Creative Commons Attribution NonCommercial (CC BY-NC 4.0) license, which permits others to distribute, remix, adapt, build upon this work non-commercially, and license their derivative works on different terms, provided the original work is properly cited and the use is non-commercial. See: <https://creativecommons.org/licenses/by-nc/4.0/>

Country/Territory of origin: China

ORCID number: Jia-Xin Lou 0000-0002-2606-9132; Zhen-Yu Jiang 0000-0001-6789-3841.

S-Editor: Liu H

L-Editor: A

P-Editor: Yu HG

REFERENCES

- 1 **Huang B**, Tian S, Zhan N, Ma J, Huang Z, Zhang C, Zhang H, Ming F, Liao F, Ji M, Zhang J, Liu Y, He P, Deng B, Hu J, Dong W. Accurate diagnosis and prognosis prediction of gastric cancer using deep learning on digital pathological images: A retrospective multicentre study. *EBioMedicine* 2021; **73**: 103631 [PMID: 34678610 DOI: 10.1016/j.ebiom.2021.103631]
- 2 **Iwamuro M**, Kondo E, Takata K, Yoshino T, Okada H. Diagnosis of follicular lymphoma of the gastrointestinal tract: A better initial diagnostic workup. *World J Gastroenterol* 2016; **22**: 1674-1683 [PMID: 26819532 DOI: 10.3748/wjg.v22.i4.1674]
- 3 **Yao K**. How is the VS (vessel plus surface) classification system applicable to magnifying narrow-band imaging examinations of gastric neoplasias initially diagnosed as low-grade adenomas? *Gastric Cancer* 2012; **15**: 118-120 [PMID: 22407063 DOI: 10.1007/s10120-011-0132-3]
- 4 **Li WB**, Zuo XL, Li CQ, Zuo F, Gu XM, Yu T, Chu CL, Zhang TG, Li YQ. Diagnostic value of confocal laser endomicroscopy for gastric superficial cancerous lesions. *Gut* 2011; **60**: 299-306 [PMID: 21193460 DOI: 10.1136/gut.2010.223586]
- 5 **Bok GH**, Jeon SR, Cho JY, Cho JH, Lee WC, Jin SY, Choi IH, Kim HG, Lee TH, Park EJ. The accuracy of probe-based confocal endomicroscopy versus conventional endoscopic biopsies for the diagnosis of superficial gastric neoplasia (with videos). *Gastrointest Endosc* 2013; **77**: 899-908 [PMID: 23473002 DOI: 10.1016/j.gie.2013.01.018]
- 6 **East JE**, Vleugels JL, Roelandt P, Bhandari P, Bisschops R, Dekker E, Hassan C, Horgan G, Kiesslich R, Longcroft-Wheaton G, Wilson A, Dumonceau JM. Advanced endoscopic imaging: European Society of Gastrointestinal Endoscopy (ESGE) Technology Review. *Endoscopy* 2016; **48**: 1029-1045 [PMID: 27711949 DOI: 10.1055/s-0042-118087]
- 7 **Chen YC**, Malfertheiner P, Yu HT, Kuo CL, Chang YY, Meng FT, Wu YX, Hsiao JL, Chen MJ, Lin KP, Wu CY, Lin JT, O'Morain C, Megraud F, Lee WC, El-Omar EM, Wu MS, Liou JM. Global Prevalence of Helicobacter pylori Infection and Incidence of Gastric Cancer Between 1980 and 2022. *Gastroenterology* 2024 [PMID: 38176660 DOI: 10.1053/j.gastro.2023.12.022]
- 8 **Hibdon ES**, Razumilava N, Keeley TM, Wong G, Solanki S, Shah YM, Samuelson LC. Notch and mTOR Signaling Pathways Promote Human Gastric Cancer Cell Proliferation. *Neoplasia* 2019; **21**: 702-712 [PMID: 31129492 DOI: 10.1016/j.neo.2019.05.002]
- 9 **ASGE standards of practice committee**, Forbes N, Elhanafi SE, Al-Haddad MA, Thosani NC, Draganov PV, Othman MO, Ceppa EP, Kaul V, Feely MM, Sahin I, Buxbaum JL, Calderwood AH, Chalhoub JM, Coelho-Prabhu N, Desai M, Fujii-Lau LL, Kohli DR, Kwon RS, Machicado JD, Marya NB, Pawa S, Ruan W, Sheth SG, Storm AC, Thiruvengadam NR, Qumseya BJ; (ASGE Standards of Practice Committee Chair). American Society for Gastrointestinal Endoscopy guideline on endoscopic submucosal dissection for the management of early esophageal and gastric cancers: summary and recommendations. *Gastrointest Endosc* 2023; **98**: 271-284 [PMID: 37498266 DOI: 10.1016/j.gie.2023.03.015]
- 10 **Du X**, Cheng Z, Wang YH, Guo ZH, Zhang SQ, Hu JK, Zhou ZG. Role of Notch signaling pathway in gastric cancer: a meta-analysis of the literature. *World J Gastroenterol* 2014; **20**: 9191-9199 [PMID: 25083094 DOI: 10.3748/wjg.v20.i27.9191]



Published by **Baishideng Publishing Group Inc**
7041 Koll Center Parkway, Suite 160, Pleasanton, CA 94566, USA

Telephone: +1-925-3991568

E-mail: office@baishideng.com

Help Desk: <https://www.f6publishing.com/helpdesk>

<https://www.wjgnet.com>

