

Intracerebroventricular opiate infusion for refractory head and facial pain

Darrin J Lee, Gene G Gurkoff, Amir Goodarzi, J Paul Muizelaar, James E Boggan, Kiarash Shahlaie

Darrin J Lee, Gene G Gurkoff, Amir Goodarzi, J Paul Muizelaar, James E Boggan, Kiarash Shahlaie, Department of Neurological Surgery, School of Medicine, University of California, Davis, CA 95817, United States

Author contributions: Lee DJ, Muizelaar JP, Boggan JE and Shahlaie K contributed to substantial contributions to concept/design, acquisition of data, analysis of data, drafting/revising article, approval of final version; Gurkoff GG and Goodarzi A contributed to substantial contributions to analysis of data, drafting/revising article, approval of final version.

Correspondence to: Kiarash Shahlaie, MD, PhD, Assistant Professor, Department of Neurological Surgery, School of Medicine, University of California, 4860 Y Street, Suite 3740 Sacramento, Davis, CA 95817,

United States. kiarash.shahlaie@ucdmc.ucdavis.edu

Telephone: +1-916-7346342 Fax: +1-916-7345006

Received: December 17, 2013 Revised: June 6, 2014

Accepted: June 27, 2014

Published online: August 16, 2014

Abstract

AIM: To study the risks and benefits of intracerebroventricular (ICV) opiate pumps for the management of benign head and face pain.

METHODS: Six patients with refractory trigeminal neuralgia and/or cluster headaches were evaluated for implantation of an ICV opiate infusion pump using either ICV injections through an Ommaya reservoir or external ventricular drain. Four patients received morphine ICV pumps and two patients received a hydromorphone pump. Of the four patients with morphine ICV pumps, one patient had the medication changed to hydromorphone. Preoperative and post-operative visual analog scores (VAS) were obtained. Patients were evaluated post-operatively for a minimum of 3 mo and the pump dosage was adjusted at each outpatient clinic visit according to the patient's pain level.

RESULTS: All 6 patients had an intracerebroventricular

opiate injection trial period, using either an Ommaya reservoir or an external ventricular drain. There was an average VAS improvement of 75.8%. During the trial period, no complications were observed. Pump implantation was performed an average of 3.7 wk (range 1-7) after the trial injections. After implantation, an average of 20.7 ± 8.3 dose adjustments were made over 3-56 mo after surgery to achieve maximal pain relief. At the most recent follow-up (26.2 mo, range 3-56), VAS scores significantly improved from an average of 7.8 ± 0.5 (range 6-10) to 2.8 ± 0.7 (range 0-5) at the final dose (mean improvement 5.0 ± 1.0 , $P < 0.001$). All patients required a stepwise increase in opiate infusion rates to achieve maximal benefit. The most common complications were nausea and drowsiness, both of which resolved with pump adjustments. On average, infusion pumps were replaced every 4-5 years.

CONCLUSION: These results suggest that ICV delivery of opiates may potentially be a viable treatment option for patients with intractable pain from trigeminal neuralgia or cluster headache.

© 2014 Baishideng Publishing Group Inc. All rights reserved.

Key words: Intracerebroventricular; Opiate; Trigeminal neuralgia; Cluster headache; Pain

Core tip: Chronic head and face pain remains a debilitating condition, and patients may often be refractory to traditional medical therapies or surgical intervention (*i.e.*, stereotactic radiosurgery or microvascular decompression). Alternatively, the use of intracerebroventricular (ICV) pain pumps has been used for refractory nociceptive pain from head and neck cancer; however, its use in non-cancer head and face pain has not been well described. Here, we report the potential risks and benefits of ICV opiate pain pumps for cluster headaches and trigeminal neuralgia refractory to medical and surgical treatment.

Lee DJ, Gurkoff GG, Goodarzi A, Muizelaar JP, Boggan JE, Shahlaie K. Intracerebroventricular opiate infusion for refractory head and facial pain. *World J Clin Cases* 2014; 2(8): 351-356 Available from: URL: <http://www.wjgnet.com/2307-8960/full/v2/i8/351.htm> DOI: <http://dx.doi.org/10.12998/wjcc.v2.i8.351>

INTRODUCTION

Chronic head and face pain is a debilitating condition that affects over 3%-5% of people worldwide^[1], dramatically impacting emotional, psychological, and economic well-being. Two common etiologies of severe head and face pain are cluster headache and trigeminal neuralgia, which affect 300000 and 100000 people in the United States, respectively. Cluster headache is typically managed with medical therapies or botox injections^[2,3], and most cases of trigeminal neuralgia are successfully treated with oral medications, stereotactic radiosurgery, or microvascular decompression^[4]. However, 5% of patients with cluster headache^[5] and 11%-25% of patients with trigeminal neuralgia^[6-10] do not achieve adequate pain relief with these therapies and may require other treatment options.

Neurosurgical treatment options for pain syndromes have generally focused on modulation of specific pain pathways by lesioning, electrical stimulation, or spinal intrathecal delivery of pharmacological agents^[11,12]. Targets for electrical neuromodulation include the dorsal columns of the spinal cord, the sensory nuclei of the thalamus, the precentral motor cortex for neurogenic/neuropathic pain, and the periventricular/periaqueductal gray area for somatic or nociceptive pain^[13]. Chemical neuromodulation *via* central delivery of pharmacological agents is primarily accomplished *via* spinal intrathecal delivery strategies^[14].

Intracerebroventricular (ICV) administration of opioids represents a chemical, rather than electrical, neuromodulation treatment strategy. This allows for drug delivery directly at its anatomical site of action, achieving high tissue concentrations of drug that would not be achievable with systemic drug delivery. ICV delivery of opiate medications has been previously described for management of refractory nociceptive pain from head and neck cancer^[15-19]. This is typically accomplished *via* intermittent injection of opiates into an Ommaya reservoir^[17,20-22], although use of an implanted infusion pump has also been reported^[19,23]. In this study, we present our institutional experience treating six patients with ICV opiate pain pumps for treatment of severe, refractory head and face pain due to cluster headache and/or trigeminal neuralgia.

MATERIALS AND METHODS

Patient population

Six adult patients (4 women, 2 men) underwent implantation of an ICV opiate pump into the right lateral ventricle for treatment of severe, refractory head and/or face pain at the University of California, Davis Medical Center.

The average age of symptom onset was 44.3 years (range 17-75), the average duration of symptoms was 14.8 years (range 4-31), and the average age at ICV implantation was 59.0 years (range 35-79). Four patients had facial pain, 1 patient had cluster headaches, and 1 patient had cluster headache and atypical facial pain. Patients had tried an average of 4 (range 1-9) oral pain medications prior to ICV implantation; 2 patients tried opiate injection therapy, 2 patients had failed microvascular decompression for facial pain, and none of the patients in this series had undergone previous radiosurgery for pain (Table 1). The University of California, Davis Institutional Review Board approved this retrospective study.

Treatment protocol

Prior to ICV opiate pump implantation, all patients demonstrated significant clinical benefit with trial injection of opiates through an Ommaya reservoir ($n = 5$) or an external ventricular drain (EVD, $n = 1$). Trial injections were performed in the neurosurgical intensive care unit for close monitoring of known complications of ICV opiate delivery, including mental clouding, visual hallucinations, seizures, somnolence, respiratory depression, and coma^[24]. Initially, patients underwent a trial injection phase (3-15 d) at which time the dose of morphine or hydromorphone was titrated to determine an optimal dose for each individual. A Medtronic (Minnesota, United States) pain pump was implanted into a subcutaneous fat space in the abdomen within one month of the trial injections by one of two neurosurgeons (J.E.B, K.S.). In one patient (patient 6), intraoperative computed tomography was used to confirm placement of the intraventricular catheter (Figure 1). Adjustment of dose rates and/or refilling of pumps occurred monthly.

Outcome assessment

Visual analogue scale (VAS) scores were obtained before and after intraventricular trial injections, and before and after the ICV opiate pump infusion began. VAS scores were collected on an intermittent basis during outpatient clinic visits, before and after infusion rate adjustments.

RESULTS

There were no complications associated with placement of an Ommaya reservoir or EVD to perform trial injections. During trial injection therapy, one patient experienced a transient side effect of nausea but there were no permanent complications. An average of 9.2 doses (range 2-27) was necessary during the trial phase to provide maximum VAS improvement with trial injections (average VAS improvement 75.8%, range 50%-100%).

Pump implantation was performed an average of 3.7 wk (range 1-7) after ICU trial injections had been completed, and patients required an average of 20.7 (range 2-51) outpatient adjustments to the dose. At the most recent follow-up (26.2 mo, range 2-56, one patient transferred care to a different institution), VAS pain scores significantly im-

Table 1 Patient characteristics and outcomes

Patient	Age (at pump placement, yr)	Gender	Primary diagnosis	Prior surgeries	Pre-implantation trial	ICV pump medication	Initial dose (mg/d)	Final dose (mg/d)	Pre-op VAS	Post-op day 1 VAS	Last VAS	Last post-op visit (mo)
1	67	Male	Trigeminal neuralgia (left)		Ommaya reservoir-morphine	Morphine then dilaudid	0.1 morphine	3.27 dilaudid	6	3.5	4	145
2	35	Female	Cluster headaches		Ommaya reservoir-morphine	Morphine	0.65 morphine	19.0 morphine	8	4	0	166
3	37	Female	Trigeminal neuralgia (right), Cluster headaches		Ommaya reservoir-morphine, dilaudid	Dilaudid	0.1 dilaudid	0.2 dilaudid	8	2.5	3	9
4	74	Male	Trigeminal neuralgia (left)	Rhizotomy, Microvascular decompression	Ommaya reservoir-morphine	Morphine	0.75 morphine	1.75 morphine	8	1	1	10
5	62	Female	Trigeminal neuralgia (right)	Microvascular decompression	Ommaya reservoir-morphine	Morphine	4 morphine	4.25 morphine	10	3	2	3
6	79	Female	Trigeminal neuralgia (left)	Meningioma resection (left), radiosurgery ×2	External ventricular drain-morphine, dilaudid	Dilaudid	0.01 dilaudid	0.085 dilaudid	8	2	2	15

VAS: Visual analogue scale; ICV: Intracerebroventricular.

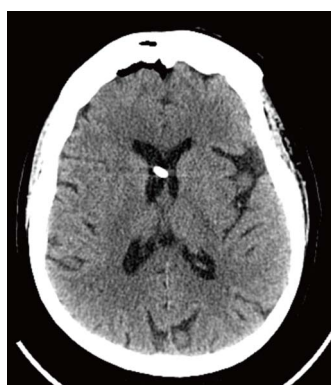

Figure 1 Intraoperative computed tomography of the head demonstrates intraventricular placement of the pump catheter (Patient 6).

proved from an average of 7.8 ± 0.5 (range 6-10) to 2.8 ± 0.7 (range 0-5) once reaching final dose (mean improvement 5.0 ± 1.0 , $P < 0.001$, Table 1, Figure 2).

All patients required stepwise increases in infusion rates to achieve maximal benefit. The average initial morphine dose was 1.4 mg/d (range 0.1-4.0 mg/d) and the average final dose was 11.7 mg/d (range 2-21.5, $n = 4$). The average initial hydromorphone dose was 0.08 mg/d (range 0.01-0.2 mg/d) and the average final dose was 1.2 mg/d (range 0.1-3.3). In one patient (Patient 1), the medication was changed from morphine to hydromorphone to achieve maximal benefit; in this patient, 12 morphine dosage adjustments were made prior to converting to hydromorphone 15 mo after implantation. The final morphine dosage was 21.5 mg/d and the

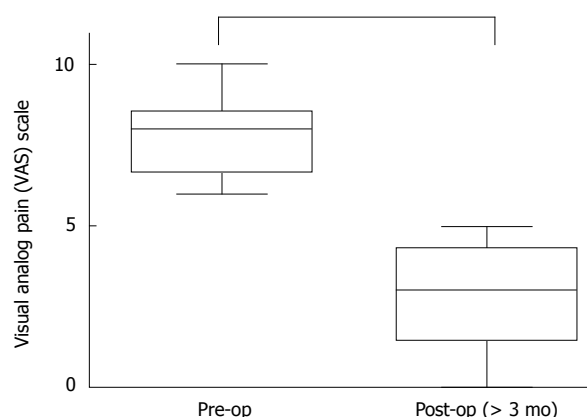


Figure 2 Preoperative visual analogue scale pain scores ranged from 6-10 out of 10 (average 7.8 ± 0.5). Post-operative visual analogue scale (VAS) scores at > 3 mo following opioid pain pump placement were significantly lower ($P < 0.001$ vs Post-op), ranging 0-5 out of 10 (average 2.7 ± 0.4).

initial hydromorphone dosage was 2.1 mg/d. Following medication adjustment, an additional 12 adjustments with hydromorphone were made. On average, infusion pumps were replaced every 4-5 years.

The most common complications in this series were nausea ($n = 2$) and drowsiness ($n = 2$), both of which resolved with adjustments in pump settings (Table 2). One patient experienced withdrawal symptoms due to pump failure, and underwent a distal catheter revision (to clear an obstruction) with subsequent resolution of her symptoms. One patient experienced psychiatric irritability after 10 years of good pain relief and had the ICV pain pump removed.

Table 2 Dose ranges and complications

Patient	Dose range (mg/d)	Complications
1	0.10-21.5 (morphine) 2.10-3.27 (dilaudid)	Nausea/Emesis (transient-decreased dosage) Changed medication due to inadequate pain control/nausea
2	0.65-19.0 (morphine)	Replacement of pump × 2 (q5 yr) Withdrawal symptoms (transient)
3	0.20 (dilaudid)	Psychiatric disturbances leading to removal of pain pump after 11 yr
4	0.75-2.0 (morphine)	Nausea/Emesis (transient-decreased dosage)
5	4.00-4.25 (morphine)	Lost to follow-up after 1 yr
6	0.01-0.10 (dilaudid)	

DISCUSSION

ICV opiate infusion using an implanted pump provides significant pain relief in patients with severe, refractory head and/or face pain that have failed other medical and surgical therapies. This study adds to the existing literature on successful use of ICV opiates for management of head and neck cancer pain^[25], and suggests that ICV opiate infusion may be a prudent treatment option for select patients with severe cluster headache or trigeminal neuralgia.

While the mechanism and site of action of opioids in the brain for head and neck pain is not completely understood, it is known that morphine and its derivatives bind to receptors that are found in the periventricular and periaqueductal gray regions, medulla spinalis, substantia gelatinosa, and the hypothalamus^[13,26-30]. Therefore, it is possible that ICV delivery of opioids selectively modulates activity in these brain regions, resulting in a level of analgesia that may be superior to that achieved with systemic therapies.

The efficacy of deep brain stimulation (DBS) of the periventricular/periaqueductal gray region for management of cluster headache and other central pain syndromes^[11,13,26] supports the hypothesis that targeted delivery is effective for refractory cases. Due to its proximity to pain pathways in the brainstem, hypothalamus, and thalamus, ICV delivery may potentially be more prudent than intraspinal intrathecal delivery for severe, refractory head and face pain syndromes. Prospective comparative studies are needed to further explore this possibility.

Because the pathophysiology of refractory trigeminal neuralgia and cluster headaches are poorly understood, ICV infusion therapy may be more effective than DBS since its effects are more regional and affect a larger volume of tissue. Different brain areas have been implicated in refractory cluster headache^[31,32], and the anatomical basis of trigeminal neuralgia that fails medical therapy and microvascular decompression is often elusive and has been attributed to demyelination or other unknown processes. Various lesioning therapies have been proposed for failed microvascular decompression, including therapies that target the facial nerve (chemical, mechanical decompression, radiosurgery, and nerve cutting) or its brainstem pathways (nucleus caudalis dorsal root entry zone lesioning). Since these procedures are irreversible

and can carry significant risks, ICV opioid infusion may be a preferable alternative since it allows for delivery of a regional targeted therapy that can be titrated to effect and, if necessary, discontinued.

It is important to note that cluster headache and trigeminal neuralgia are very different disorders with unique clinical and pathological characteristics. For example, cluster headaches are far more common in men (8:3 ratio)^[33] whereas trigeminal neuralgia affects more women than men (3:2 ratio)^[34]. Since morphine is generally more potent in men than women, it is possible that different opioid infusion strategies are needed to achieve adequate analgesia in these conditions. Such differences were not evident in the current series, but larger clinical studies are needed to determine if gender-specific and/or disease-specific opioid infusion strategies will yield better clinical outcomes.

The risks associated with ICV opiate infusion therapy include neurological injury from ventricular catheter placement, implant infection, and opioid toxicity (including allergy, intolerance or significant clinical side effects). We recommend a trial therapy in an ICU setting prior to pump implantation to confirm clinical efficacy and evaluate for any signs of opioid toxicity. After implantation, a slow, step-wise titration of opioid infusion is recommended to achieve maximum clinical efficacy with minimal side effects and complications. In this series, the average number of dose adjustments was 20.7 (range 2-51). The high number of adjustments demonstrates that opioid tolerance can develop over time. Special consideration should be given to the development of opioid tolerance and the risks associated with abrupt disruption or withdrawal of therapy (in the setting of pump failure, for example). There is some evidence that co-administration of drugs may enhance analgesia and reduce the likelihood of tolerance. For example, pre-clinical animal studies suggest that co-administration of drugs like calmodulin inhibitors^[35,36] or inhibitors of protein kinases^[37] may reduce or prevent morphine tolerance from developing. Also, there is evidence that certain non-opioid medications, such as the voltage-gated calcium channel blocker ziconotide, are extremely effective when delivered as an intrathecal infusion^[38,39] and may be appropriate alternatives to opioids or effective in a co-administration strategy.

In conclusion, severe head and facial pain syndromes that are refractory to conventional medical and surgical

therapies can be extremely debilitating and very difficult to manage. ICV opioid infusion has the potential to enhance analgesia through regional delivery of drug to brain centers that are directly responsible for processing pain signals. Using a careful clinical protocol to screen for efficacy and reduce risks, ICV opioid infusion therapy may be an effective treatment option for patients with severe head and facial pain due to cluster headache and trigeminal neuralgia.

COMMENTS

Background

Intracerebroventricular (ICV) opiate pumps are used for management of chronic pain due to head and neck cancers, but their use for neurological etiologies of benign head and face pain has not been well studied. This study aims to evaluate the risks and benefits of intracerebroventricular opiate pumps for management of benign head and face pain.

Research frontiers

Here, the authors describe the use of intracerebroventricular pain pumps for benign head and face pain refractory to medical and/or surgical treatment. While neurosurgical options for pain include lesioning, electrical stimulation, or spinal intrathecal delivery of pharmacological agents, the use of intracerebroventricular opiates has not been well described.

Innovations and breakthroughs

While intracerebroventricular pain pumps have been used for head and neck cancer pain, its use for benign head and face pain, such as trigeminal neuralgia or cluster headaches, has not been well described. This study suggests that ICV pain pumps may be a potential treatment option for patients suffering from benign head and face pain refractory to medical and/or surgical treatments.

Applications

This study suggests that intracerebroventricular pain pumps may be a viable option for patients with benign head and face pain that are refractory to previous medical or surgical treatments. Randomized controlled trials would need to be performed to further evaluate the efficacy and safety of this modality.

Terminology

Intracerebroventricular pain pump: Opiates can be administered into the ventricles directly via this modality. This can be distinguished from spinal catheter pain pumps. Visual analog score: 10-point pain scale used to evaluate severity of pain (0: no pain, 10 most severe pain).

Peer review

Interesting clinical article on intracerebroventricular opiate infusion for refractory head and facial pain. The authors report on a cohort of 6 patients with refractory trigeminal neuralgia and/or cluster headaches which underwent implantation of an intracerebroventricular opiate infusion pump as a means to control intractable pain. The article is well written, the patient population is presented in detail and the same applies to treatment protocol and outcome assessment. The results are equally presented with clarity and the discussion includes up to date references that correlate with the authors clinical results.

REFERENCES

- Gladstone J, Eross E, Dodick D. Chronic daily headache: a rational approach to a challenging problem. *Semin Neurol* 2003; **23**: 265-276 [PMID: 14722822 DOI: 10.1055/s-2003-814738]
- Beck E, Sieber WJ, Trejo R. Management of cluster headache. *Am Fam Physician* 2005; **71**: 717-724 [PMID: 15742909]
- Newman LC, Goadsby P, Lipton RB. Cluster and related headaches. *Med Clin North Am* 2001; **85**: 997-1016 [PMID: 11480270]
- Obermann M, Katsarava Z. Update on trigeminal neuralgia. *Expert Rev Neurother* 2009; **9**: 323-329 [PMID: 19271941 DOI: 10.1586/14737175.9.3.323]
- Irimia P, Palma JA, Fernandez-Torron R, Martinez-Vila E. Refractory migraine in a headache clinic population. *BMC Neurol* 2011; **11**: 94 [PMID: 21806790 DOI: 10.1186/1471-2377-11-94]
- Günther T, Gerganov VM, Stieglitz L, Ludemann W, Samii A, Samii M. Microvascular decompression for trigeminal neuralgia in the elderly: long-term treatment outcome and comparison with younger patients. *Neurosurgery* 2009; **65**: 477-482; discussion 482 [PMID: 19687692 DOI: 10.1227/01.NEU.0000350859.27751.90]
- Sanchez-Mejia RO, Limbo M, Cheng JS, Camara J, Ward MM, Barbaro NM. Recurrent or refractory trigeminal neuralgia after microvascular decompression, radiofrequency ablation, or radiosurgery. *Neurosurg Focus* 2005; **18**: e12 [PMID: 16419977]
- Barker FG, Jannetta PJ, Bissonette DJ, Larkins MV, Jho HD. The long-term outcome of microvascular decompression for trigeminal neuralgia. *N Engl J Med* 1996; **334**: 1077-1083 [PMID: 8598865 DOI: 10.1056/NEJM199604253341701]
- Bederson JB, Wilson CB. Evaluation of microvascular decompression and partial sensory rhizotomy in 252 cases of trigeminal neuralgia. *J Neurosurg* 1989; **71**: 359-367 [PMID: 2769387 DOI: 10.3171/jns.1989.71.3.0359]
- Burchiel KJ, Clarke H, Haglund M, Loeser JD. Long-term efficacy of microvascular decompression in trigeminal neuralgia. *J Neurosurg* 1988; **69**: 35-38 [PMID: 2454303 DOI: 10.3171/jns.1988.69.1.0035]
- Kumar K, Toth C, Nath RK. Deep brain stimulation for intractable pain: a 15-year experience. *Neurosurgery* 1997; **40**: 736-746; discussion 746-747 [PMID: 9092847]
- Cetas JS, Saedi T, Burchiel KJ. Destructive procedures for the treatment of nonmalignant pain: a structured literature review. *J Neurosurg* 2008; **109**: 389-404 [PMID: 18759567 DOI: 10.3171/JNS/2008/109/9/0389]
- Hosobuchi Y. Subcortical electrical stimulation for control of intractable pain in humans. Report of 122 cases (1970-1984). *J Neurosurg* 1986; **64**: 543-553 [PMID: 3485191 DOI: 10.3171/jns.1986.64.4.0543]
- Hayek SM, Deer TR, Pope JE, Panchal SJ, Patel VB. Intrathecal therapy for cancer and non-cancer pain. *Pain Physician* 2011; **14**: 219-248 [PMID: 21587327]
- Choi CR, Ha YS, Ahn MS, Lee JS, Song JU. Intraventricular or epidural injection of morphine for severe pain. *Neurochirurgia (Stuttg)* 1989; **32**: 180-183 [PMID: 2594133 DOI: 10.1055/s-2008-1054033]
- Cramond T, Stuart G. Intraventricular morphine for intractable pain of advanced cancer. *J Pain Symptom Manage* 1993; **8**: 465-473 [PMID: 7963773]
- Karavelis A, Foroglou G, Selviaridis P, Fountzilas G. Intraventricular administration of morphine for control of intractable cancer pain in 90 patients. *Neurosurgery* 1996; **39**: 57-61; discussion 61-62 [PMID: 8805140]
- Lazorthes YR, Sallerin BA, Verdié JC. Intracerebroventricular administration of morphine for control of irreducible cancer pain. *Neurosurgery* 1995; **37**: 422-428; discussion 422-428 [PMID: 7501106]
- Weigl K, Mundinger F, Chrusasik J. Continuous intraventricular morphine- or peptide-infusion for intractable cancer pain. *Acta Neurochir Suppl (Wien)* 1987; **39**: 163-165 [PMID: 3478979]
- Le MK, Shin HJ, Yang GY, Yoon YW, Han SK, Bae YC, Ahn DK. Intracisternal and intraperitoneal administration of morphine attenuates mechanical allodynia following compression of the trigeminal ganglion in rats. *J Orofac Pain* 2010; **24**: 113-121 [PMID: 20213037]
- Nurchi G. Use of intraventricular and intrathecal morphine in intractable pain associated with cancer. *Neurosurgery* 1984; **15**: 801-803 [PMID: 6549051]
- Reeve WG, Todd JG. Intraventricular diamorphine via an Ommaya shunt for intractable cancer pain. *Br J Anaesth* 1990; **65**: 544-547 [PMID: 2248824]
- Dennis GC, DeWitty RL. Long-term intraventricular infusion of morphine for intractable pain in cancer of the head

- and neck. *Neurosurgery* 1990; **26**: 404-407; discussion 404-407 [PMID: 2320208]
- 24 **Ballantyne JC**, Carwood CM. Comparative efficacy of epidural, subarachnoid, and intracerebroventricular opioids in patients with pain due to cancer. *Cochrane Database Syst Rev* 2005; **(1)**: CD005178 [PMID: 15654707 DOI: 10.1002/14651858.CD005178]
- 25 **Ballantyne JC**, Carr DB, Berkey CS, Chalmers TC, Mosteller F. Comparative efficacy of epidural, subarachnoid, and intracerebroventricular opioids in patients with pain due to cancer. *Reg Anesth* 1996; **21**: 542-556 [PMID: 8956391]
- 26 **Hosobuchi Y**, Adams JE, Linchitz R. Pain relief by electrical stimulation of the central gray matter in humans and its reversal by naloxone. *Science* 1977; **197**: 183-186 [PMID: 301658]
- 27 **Lipp J**. Possible mechanisms of morphine analgesia. *Clin Neuropharmacol* 1991; **14**: 131-147 [PMID: 1849794]
- 28 **Wall PD**. The role of substantia gelatinosa as a gate control. *Res Publ Assoc Res Nerv Ment Dis* 1980; **58**: 205-231 [PMID: 6245435]
- 29 **Markenson JA**. Mechanisms of chronic pain. *Am J Med* 1996; **101**: 6S-18S [PMID: 8764755]
- 30 **Grossman A**, Clement-Jones V. Opiate receptors: enkephalins and endorphins. *Clin Endocrinol Metab* 1983; **12**: 31-56 [PMID: 6303648]
- 31 **May A**, Bahra A, Büchel C, Frackowiak RS, Goadsby PJ. PET and MRA findings in cluster headache and MRA in experimental pain. *Neurology* 2000; **55**: 1328-1335 [PMID: 11087776]
- 32 **DaSilva AF**, Goadsby PJ, Borsook D. Cluster headache: a review of neuroimaging findings. *Curr Pain Headache Rep* 2007; **11**: 131-136 [PMID: 17367592]
- 33 **Rozen TD**, Fishman RS. Cluster headache in the United States of America: demographics, clinical characteristics, triggers, suicidality, and personal burden. *Headache* 2012; **52**: 99-113 [PMID: 22077141 DOI: 10.1111/j.1526-4610.2011.02028.x]
- 34 **Ji Y**, Murphy AZ, Traub RJ. Sex differences in morphine-induced analgesia of visceral pain are supraspinally and peripherally mediated. *Am J Physiol Regul Integr Comp Physiol* 2006; **291**: R307-R314 [PMID: 16556902 DOI: 10.1152/ajp-regu.00824.2005]
- 35 **Sepehri G**, Sheibani V, Azarang A, Shamsizadeh A, Afarinesh MR, Azizollahi S, Sepehri E. The intracerebroventricular (ICV) administration of W-7, a calmodulin inhibitor, attenuates the development of morphine tolerance in rats. *Pak J Pharm Sci* 2010; **23**: 170-174 [PMID: 20363694]
- 36 **Sánchez-Blázquez P**, Rodríguez-Muñoz M, Montero C, de la Torre-Madrid E, Garzón J. Calcium/calmodulin-dependent protein kinase II supports morphine antinociceptive tolerance by phosphorylation of glycosylated phospholipase C protein. *Neuropharmacology* 2008; **54**: 319-330 [PMID: 18006024 DOI: 10.1016/j.neuropharm.2007.10.002]
- 37 **Gabra BH**, Bailey CP, Kelly E, Smith FL, Henderson G, Dewey WL. Pre-treatment with a PKC or PKA inhibitor prevents the development of morphine tolerance but not physical dependence in mice. *Brain Res* 2008; **1217**: 70-77 [PMID: 18501877 DOI: 10.1016/j.brainres.2008.04.036]
- 38 **Michiels WB**, McGlithlen GL, Platt BJ, Grigsby EJ. Trigeminal neuralgia relief with intrathecal ziconotide. *Clin J Pain* 2011; **27**: 352-354 [PMID: 21494183 DOI: 10.1097/AJP.0b013e3181fb22f4]
- 39 **Lux EA**. Case report: successful treatment of a patient with trigeminal neuropathy using ziconotide. *Anesth Analg* 2010; **110**: 1195-1197 [PMID: 20142352 DOI: 10.1213/ANE.0b013e3181cfc307]

P- Reviewer: Rapidis AD S- Editor: Song XX L- Editor: A
E- Editor: Lu YJ





Published by **Baishideng Publishing Group Inc**

8226 Regency Drive, Pleasanton, CA 94588, USA

Telephone: +1-925-223-8242

Fax: +1-925-223-8243

E-mail: bpgoffice@wjgnet.com

Help Desk: <http://www.wjgnet.com/esps/helpdesk.aspx>

<http://www.wjgnet.com>

