

Combined surgical-orthodontic rehabilitation of cleidocranial dysplasia: 5 years follow-up

Emre Çimen, Ömür Dereci, Ayşegül Mine Tüzüner-Öncül, Duygu Yazıcıoğlu, Erhan Özdiler, Aslı Şenol, Nejat Bora Sayan

Emre Çimen, Private Practice, 34890 Istanbul, Turkey

Ömür Dereci, Department of Oral and Maxillofacial Surgery, Faculty of Dentistry, Eskişehir Osmangazi University, 26480 Eskişehir, Turkey

Ayşegül Mine Tüzüner-Öncül, Nejat Bora Sayan, Department of Oral and Maxillofacial Surgery, Faculty of Dentistry, Ankara University, 06500 Ankara, Turkey

Duygu Yazıcıoğlu, Private Practice, 06500 Ankara, Turkey

Erhan Özdiler, Aslı Şenol, Department of Orthodontics, Faculty of Dentistry, Ankara University, 06500 Ankara, Turkey

Author contributions: Çimen E, Tüzüner-Öncül AM, Özdiler E and Sayan NB designed the research; Çimen E, Tüzüner-Öncül AM, Yazıcıoğlu D and Sayan NB performed the surgery; Özdiler E and Şenol A performed orthodontic treatment; Çimen E, Dereci Ö, Özdiler E and Şenol A analyzed the data; Dereci Ö and Çimen E wrote the paper.

Institutional review board statement: The name of our institutional review board is 'Clinical Research Ethical Board of Eskişehir Osmangazi University, Faculty of Medicine.' This study is a case report with a long follow-up. Our Ethical board does not accept case reports due to there is no need for ethical approval for case reports. Therefore, we did not apply for institutional ethical board for approval.

Informed consent statement: Patient presented in this study gave his informed consent prior to study inclusion.

Conflict-of-interest statement: All authors declare that there is no conflict of interest.

Open-Access: This article is an open-access article which was selected by an in-house editor and fully peer-reviewed by external reviewers. It is distributed in accordance with the Creative Commons Attribution Non Commercial (CC BY-NC 4.0) license, which permits others to distribute, remix, adapt, build upon this work non-commercially, and license their derivative works on different terms, provided the original work is properly cited and the use is non-commercial. See: <http://creativecommons.org/licenses/by-nc/4.0/>

[licenses/by-nc/4.0/](http://creativecommons.org/licenses/by-nc/4.0/)

Correspondence to: Dr. Ömür Dereci, Assistant Professor, Department of Oral and Maxillofacial Surgery, Faculty of Dentistry, Eskişehir Osmangazi University, Meşelik Campus, 26480 Eskişehir, Turkey. omurdereci@hotmail.com
Telephone: +90-222-2391303
Fax: +90-222-2391273

Received: April 6, 2015

Peer-review started: April 8, 2015

First decision: April 27, 2015

Revised: June 3, 2015

Accepted: June 18, 2015

Article in press: July 15, 2015

Published online: August 16, 2015

Abstract

Cleidocranial dysplasia (CD) is an autosomal dominant syndrome which is characterized by several skeletal malformations such as non-closed fontanelles, skeletal abnormalities of the maxilla and mandible and absence of clavicles. Mid-facial hypoplasia and mandibular prognathism are mostly seen jaw abnormalities in CD. In this study, the combined orthodontic-surgical treatment of a patient with CD with class III malocclusion and multiple unerupted primary and deciduous teeth is presented.

Key words: Cleidocranial dysplasia; Marie-Sainton syndrome; Forced eruption; Prognathism; Orthodontic extrusion

© The Author(s) 2015. Published by Baishideng Publishing Group Inc. All rights reserved.

Core tip: Cleidocranial dysplasia is a syndromic disease with distinct craniofacial and maxillofacial manifestations. The satisfactory treatment of dental and

skeletal deformities in this disease can only be possible with combined orthodontic-surgical approach.

Çimen E, Dereci Ö, Tüzüner-Öncül AM, Yazıcıoğlu D, Özdiler E, Şenol A, Sayan NB. Combined surgical-orthodontic rehabilitation of cleidocranial dysplasia: 5 years follow-up. *World J Clin Cases* 2015; 3(8): 751-756 Available from: URL: <http://www.wjgnet.com/2307-8960/full/v3/i8/751.htm> DOI: <http://dx.doi.org/10.12998/wjcc.v3.i8.751>

INTRODUCTION

Cleidocranial dysplasia (CD) is a syndromic disease which is also known as cleidocranial dysostosis or Marie-Sainton disease^[1]. It is characterized by multiple or solitary supernumerary teeth, non-closed fontanelles, skeletal abnormalities of the maxilla and mandible, absence of clavicles, presence of open skull sutures, widening of pubic symphysis, multiple impacted permanent teeth and miscellaneous skeletal changes^[2,3]. Mutations of the transcription factor RUNX2 which is one of the major regulators of bone maturation, are responsible for the occurrence of CD^[2].

A multidisciplinary team approach is needed to overcome the dental abnormalities and facial deformities which are well-known complications that cause morbidity in CD patients. Combined treatment with orthognathic surgery and orthodontic therapy is the mostly-accepted treatment modality to correct mid-face hypoplasia and Class III malocclusion in the treatment of CD patients.

In this study, the combined orthodontic-surgical treatment of a CD patient with class III malocclusion and multiple impacted permanent teeth is presented.

CASE REPORT

Eighteen years old male with CD was referred to the department of orthodontics with complaints of ineffective chewing, biting and facial asymmetry (Figure 1). Orthopantomogram, lateral cephalometric radiograph and antero-posterior radiograph were obtained for examination of skeletal and dental abnormalities (Figures 2 and 3). A diagnosis of class III, division 1 malocclusion was made and cone beam computerized tomography (CBCT) was taken to decide the exact shapes and positions of impacted teeth (Figure 4). Multiple permanent and 3 supernumerary impacted teeth were detected in CBCT sections and after orthognathic and surgical consultation, it was decided to erupt the impacted teeth and perform bimaxillary surgery to correct skeletal deformity.

The teeth 42, 31, 32, 33, 13, 12, 11, 21, 22, 23 were surgically exposed and orthodontic buttons were bonded for orthodontic traction under general anesthesia. Three impacted supernumerary teeth were

extracted at the time of the exposure of permanent teeth. Missing teeth of the dentition were erupted in 10 mo (Figure 5). After eruption, orthodontic treatment was sustained and the alignment of dental arch was rendered at the end of 12 mo (Figures 6 and 7).

Bimaxillary orthognathic surgery was planned for correction of skeletal open-bite and class III malocclusion. Patient was operated in general anesthesia. Post-operative recovery was non-eventful. Clinical outcome after surgery was satisfying according to the clinical point of view. Patient was undertaken in follow-up period with 6-mo intervals. Facial profile and occlusal appearance were normal and unchanged in 5th year follow-up control (Figure 8).

DISCUSSION

CD is associated with several heterogenous mutations in RUNX2 which is an osteoblast-specific transcription factor and also takes role in the tooth development^[4]. The role of RUNX2 in tooth development partly accounts for dental abnormalities such as impacted permanent or supernumerary teeth^[1]. However, the abnormal impaction of permanent and supernumerary teeth could not be fully explained since 40% of the CD cases do not have any apparent genetic mutation^[2,5]. Most of CD patients are reported to have open sagittal sutures or fontanelles, multiple erupted or impacted supernumerary or primary teeth^[5]. These symptoms are considered pathognomonic in the diagnosis of CD^[2].

The treatment of CD varies due to the skeletal or dental abnormalities and the condition of impacted normal or supernumerary teeth. Daskalogiannakis *et al*^[6] suggested that appropriate treatment of CD should be planned with careful consideration of age of the patient, expected duration of the treatment and patient expectation from the treatment. Dental management in CD is challenging in most cases and aims to achieve functional and esthetic results. Dental prosthesis is frequently used method for the functional rehabilitation of CD patients. With increasing attention to craniofacial anomalies in syndromic patients lately, collaborative orthodontic-surgical treatment of dental and skeletal anomalies of the jaws is suggested^[6,7]. Several combined treatment regimens were proposed according to the timing and manner of approach to the impacted permanent teeth^[8-12]. In our study, a technique similar to the Belfast-Hamburg^[10,12] approach is applied to facilitate the eruption of impacted permanent teeth.

The traction of impacted teeth with elastics is a common method that is used in contemporary orthodontics, especially in syndromic cases such as CD. After surgical exposure of impacted or partially impacted tooth, a button or bracket is bonded and elastics are applied between impacted and opposing permanent erupted teeth^[10,11]. If there are no opposing teeth or permanent erupted teeth are not suitable for traction, titanium screws may be used as anchorage

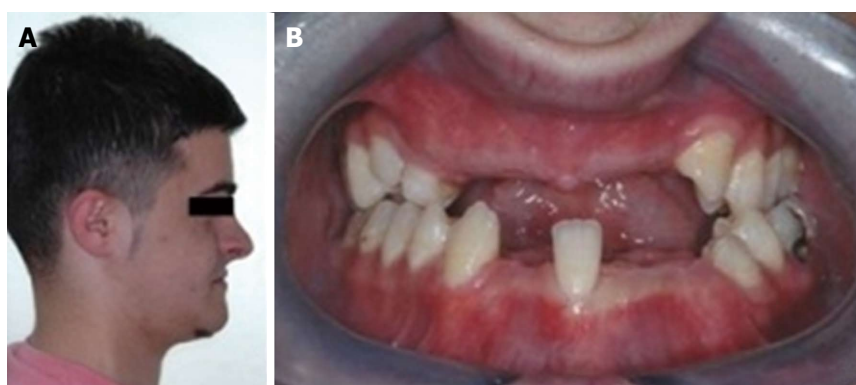


Figure 1 Clinical appearance before orthodontic treatment. A: Profile photo of the patient before orthodontic treatment; B: There were several missing teeth in the upper and lower dental arches.

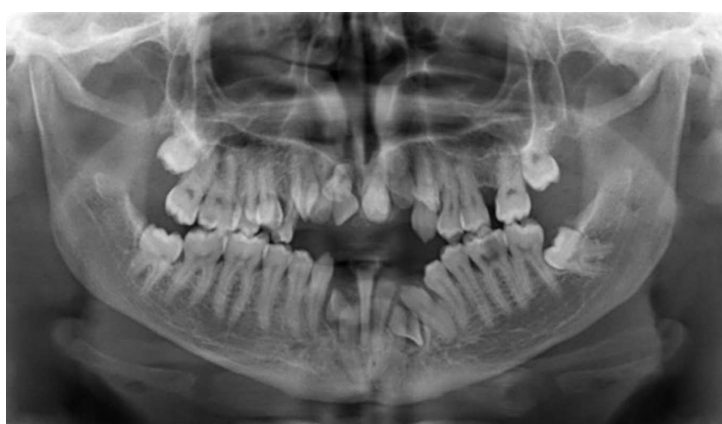

Figure 2 Pre-orthodontic panoramic radiography reveals multiple impacted permanent teeth with impacted supernumerary teeth and retained deciduous teeth. Ten permanent teeth were impacted. There were 2 supernumerary impacted teeth in the mandible and 1 supernumerary impacted tooth in the maxilla.

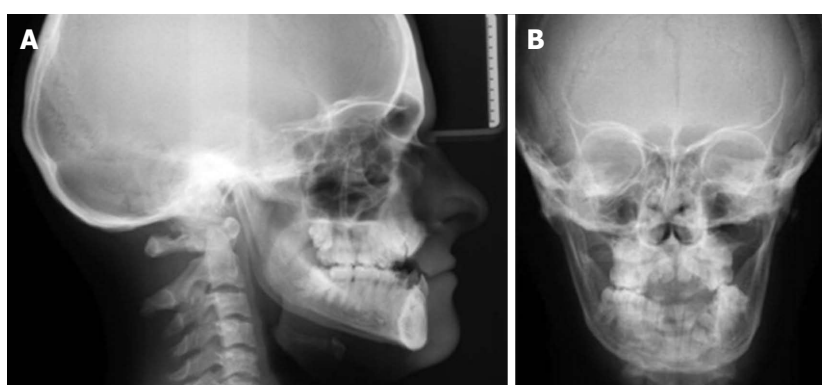


Figure 3 Cephalometric (A) and postero-anterior radiographies (B) of the patient before orthodontic treatment.

for the application of traction elastics^[13]. Rocha *et al.*^[14] suggested the use of a removable partial prosthesis to apply traction forces. In the current case, elastics were applied between lower and upper surgically exposed unerupted incisors and canines. The impacted teeth behaved as self-anchorage systems and full eruption of all impacted teeth were facilitated.

CD patients mostly have skeletal deformations leading to postural deformities. It is suggested that skeletal morphology may have a role in the develop-

ment of temporomandibular joint (TMJ) disorders^[15]. CD patients have jaw deformities and thus, tend to develop TMJ disorders. Physiotherapy or splint therapy is indicated in CD patients with TMJ disorders. The patient in the current study did not suffer from any myofascial pain or TMJ disorders and did not need any treatment on this matter.

CD is a syndromic disease with a prevalence of 1/1000000^[16]. Dental manifestations of the disease is well-documented in the literature. Treatment planning in

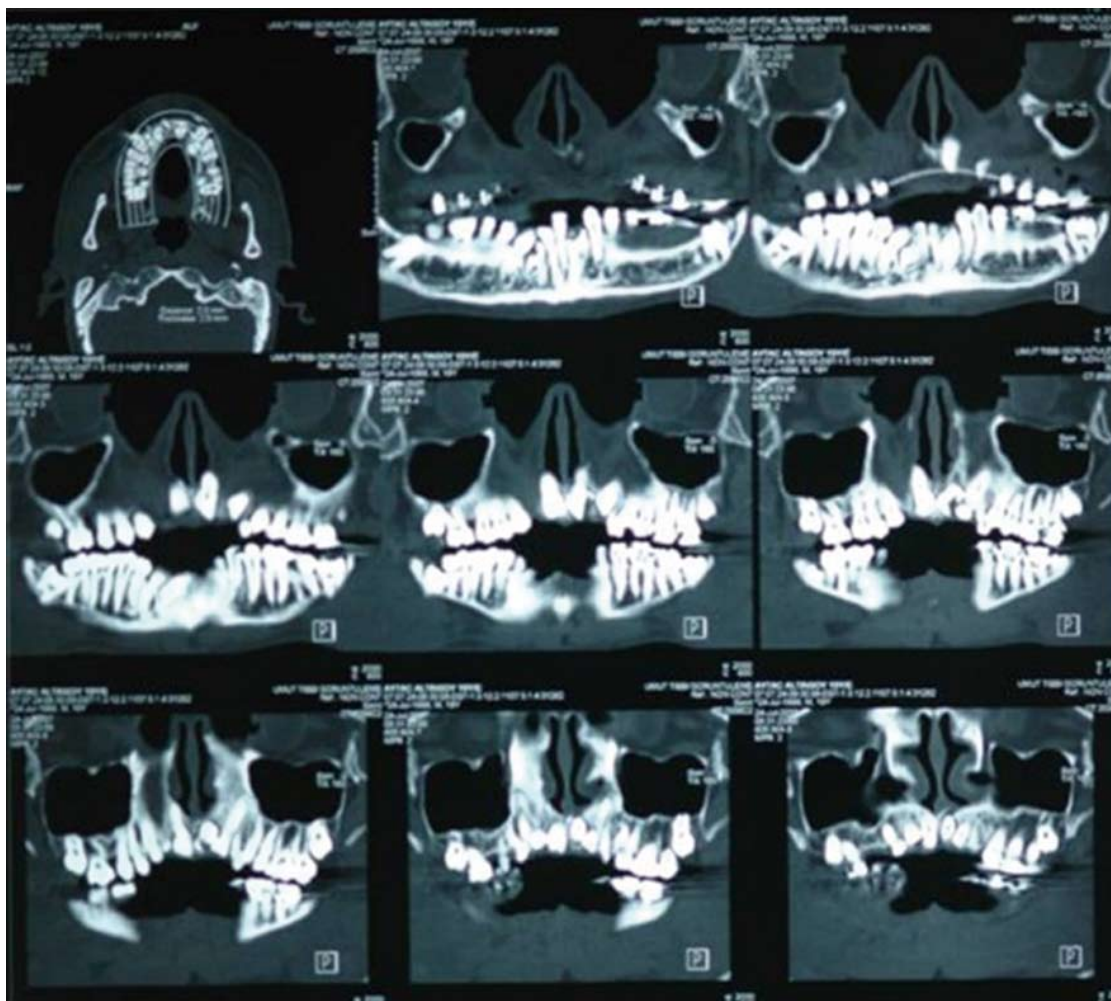


Figure 4 Frontal cone beam computerized tomography sections show impacted permanent and supernumerary teeth in detail.

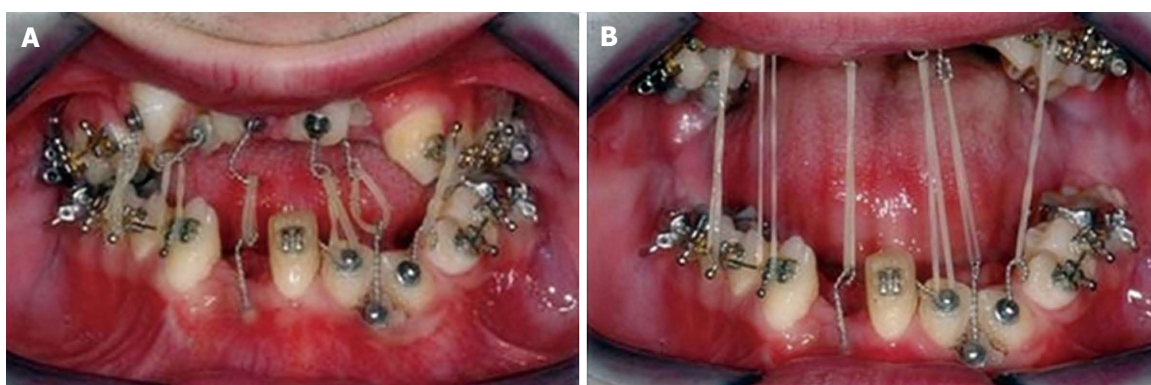


Figure 5 Intraoral elastics were applied between impacted teeth. A: Elastics remained passive when mouth is closed; B: They were activated when patient opened his mouth for daily activity such as speaking or drinking.

the rehabilitation of CD patients varies according to the degree of dental malocclusion, number of missing teeth and patients' expectations. The maintenance of force-aligned permanent teeth with elastic traction is also an important matter if the alignment of dental arches are provided with orthodontic treatment. Patients who are treated with combined surgical-orthodontic treatment

should be monitored with continuous follow-up periods during early adulthood as in the current case.

ACKNOWLEDGMENTS

This study was presented as poster presentation in 20th. International Congress of Oral and Maxillofacial Surgery,

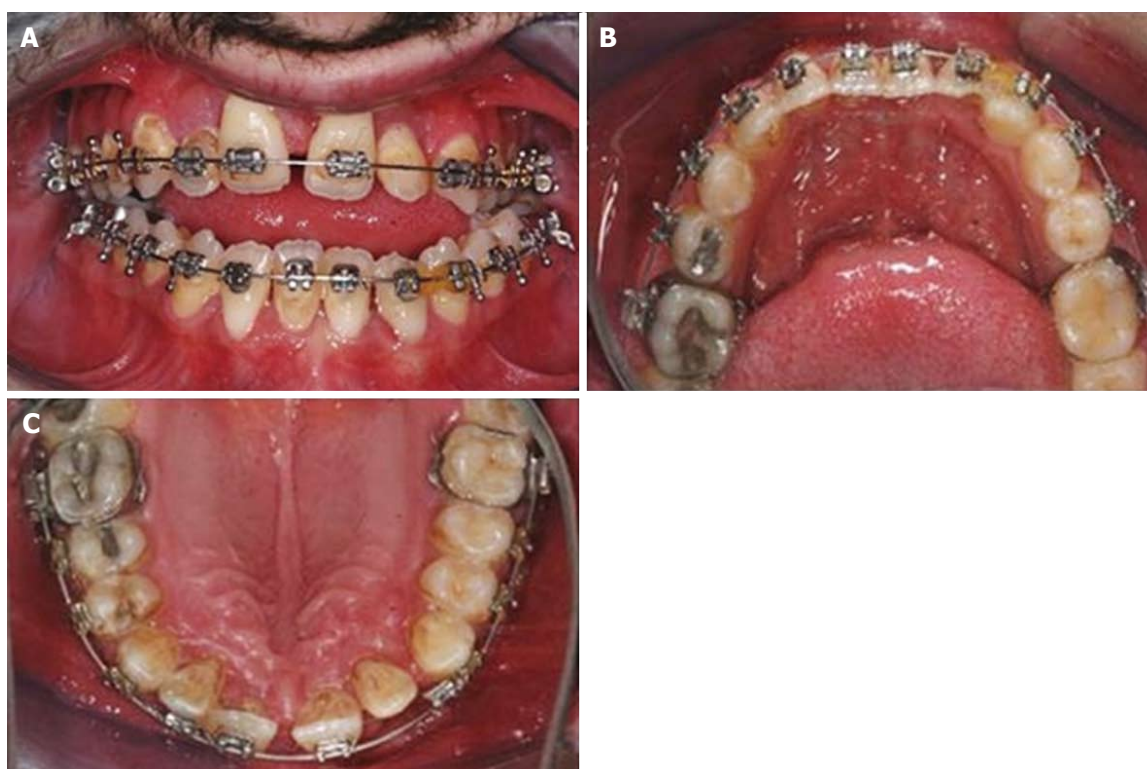


Figure 6 Clinical intraoral appearance after orthodontic treatment. A: The intraoral front-view of upper and lower dental archs after orthodontic traction and leveling treatment; B: Occlusal view of lower dental arch; C: Occlusal view of upper dental arch.

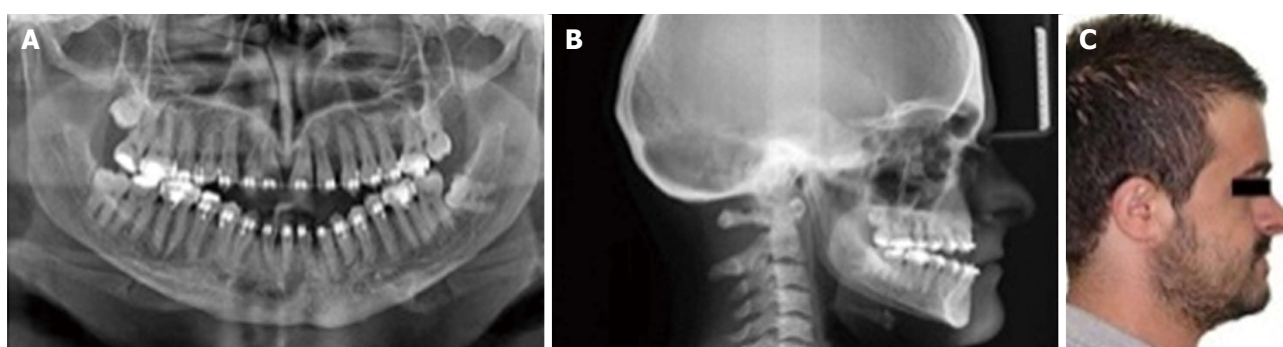


Figure 7 Radiographic and clinical evaluation after orthodontic treatment. A: Panoramic radiography after orthodontic leveling phase; B: Cephalometric radiography shows anterior open-bite malocclusion; C: Profile photograph of the patient after orthodontic leveling phase.

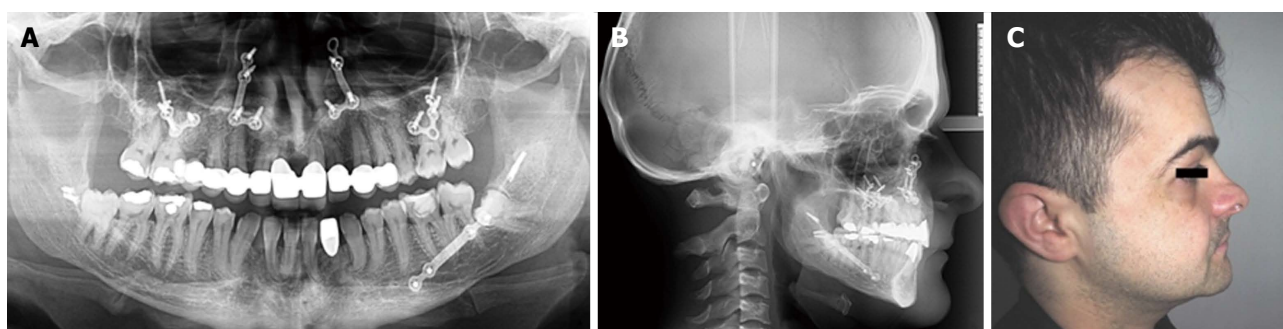


Figure 8 Radiographic and clinical evaluation after 5 years follow-up period. A: Panoramic radiography 5 years after orthognathic surgery reveals preserved and unchanged dental alignment; B: Dental class I occlusal relationship is clearly seen on cephalometric radiography; C: Profile appearance of the patient seems satisfying.

Santiago, Chile.

COMMENTS

Case characteristics

Cleidocranial dysplasia (CD) is a rare, dominantly inherited autosomal disease.

Clinical diagnosis

The main symptoms of CD includes hypoplastic or aplastic clavicles, supernumerary teeth, delayed eruption, impaction of permanent dentition and morphologic abnormalities of the maxilla and mandible.

Differential diagnosis

The differential diagnosis includes Crane-Heise syndrome, mandibuloacral dysplasia and pycnodysostosis.

Laboratory diagnosis

Laboratory testing methods are not needed in the diagnosis of CD.

Imaging diagnosis

Multiple impacted permanent or supernumerary teeth are detected in panoramic radiography or cone-beam computerized tomography sections of patients with CD.

Pathological diagnosis

Pathological examination is not needed in the diagnosis of CD.

Treatment

The treatment of CD includes orthodontics, orthognathic surgery or combined treatment modalities.

Experiences and lessons

The treatment of CD should be handled in a multidisciplinary basis. Follow-up is crucial after combined orthodontic-surgical therapy of cleidocranial dysplasia.

Peer-review

It is a well-written manuscript about a rare case.

REFERENCES

- 1 **Park TK**, Vargervik K, Oberoi S. Orthodontic and surgical management of cleidocranial dysplasia. *Korean J Orthod* 2013; **43**: 248-260 [PMID: 24228240 DOI: 10.4041/kjod.2013.43.5.248]
- 2 **Mundlos S**. Cleidocranial dysplasia: clinical and molecular genetics. *J Med Genet* 1999; **36**: 177-182 [PMID: 10204840]
- 3 **Ishii K**, Nielsen IL, Vargervik K. Characteristics of jaw growth in cleidocranial dysplasia. *Cleft Palate Craniofac J* 1998; **35**: 161-166 [PMID: 9527313]
- 4 **Yamashiro T**, Aberg T, Levanon D, Groner Y, Thesleff I. Expression of Runx1, -2 and -3 during tooth, palate and craniofacial bone development. *Mech Dev* 2002; **119** Suppl 1: S107-S110 [PMID: 14516670 DOI: 10.1016/S0925-4773(03)00101-1]
- 5 **Tanaka JL**, Ono E, Filho EM, Castilho JC, Moraes LC, Moraes ME. Cleidocranial dysplasia: importance of radiographic images in diagnosis of the condition. *J Oral Sci* 2006; **48**: 161-166 [PMID: 17023750 DOI: 10.2334/josn.48.161]
- 6 **Daskalogiannakis J**, Piedade L, Lindholm TC, Sándor GK, Carmichael RP. Cleidocranial dysplasia: 2 generations of management. *J Can Dent Assoc* 2006; **72**: 337-342 [PMID: 16684478]
- 7 **Becker A**, Shteyer A, Bimstein E, Lustmann J. Cleidocranial dysplasia: Part 2--Treatment protocol for the orthodontic and surgical modality. *Am J Orthod Dentofacial Orthop* 1997; **111**: 173-183 [PMID: 9057617 DOI: 10.1016/S0889-5406(97)70213-0]
- 8 **Smylski PT**, Woodside DG, Harnett BE. Surgical and orthodontic treatment of cleidocranial dysostosis. *Int J Oral Surg* 1974; **3**: 380-385 [PMID: 4217313 DOI: 10.1016/S0300-9785(74)80002-5]
- 9 **Hall RK**, Hyland AL. Combined surgical and orthodontic management of the oral abnormalities in children with cleidocranial dysplasia. *Int J Oral Surg* 1978; **7**: 267-273 [PMID: 100437 DOI: 10.1016/S0300-9785(78)80093-3]
- 10 **Behlfelt K**. Cleidocranial dysplasia: diagnosis and treatment concept. *Trans Eur Orthod Soc* 1987; **63**: 25
- 11 **Richardson A**, Swinson T. Combined orthodontic and surgical approach to cleidocranial dysostosis. *Trans Eur Ortod Soc* 1987; **63**: 23
- 12 **Kelly E**, Nakamoto RY. Cleidocranial dysostosis--a prosthodontic problem. *J Prosthet Dent* 1974; **31**: 518-526 [PMID: 4595888 DOI: 10.1016/0022-3913(74)90173-5]
- 13 **Kuroda S**, Yanagita T, Kyung HM, Takano-Yamamoto T. Titanium screw anchorage for traction of many impacted teeth in a patient with cleidocranial dysplasia. *Am J Orthod Dentofacial Orthop* 2007; **131**: 666-669 [PMID: 17482089 DOI: 10.1016/j.ajodo.2005.06.026]
- 14 **Rocha R**, Zasso MB, Floriano G, Derech C, Ribeiro GU, Locks A, Ritter D. Orthodontic traction in a patient with cleidocranial dysplasia: 3 years of follow-up. *Am J Orthod Dentofacial Orthop* 2014; **146**: 108-118 [PMID: 24975005 DOI: 10.1016/j.ajodo.2013.09.016]
- 15 **Kobayashi T**, Honma K, Izumi K, Hayashi T, Shingaki S, Nakajima T. Temporomandibular joint symptoms and disc displacement in patients with mandibular prognathism. *Br J Oral Maxillofac Surg* 1999; **37**: 455-458 [PMID: 10687906]
- 16 **Mahajan PS**, Mahajan AP, Mahajan PS. A rare case of cleidocranial dysplasia presenting with failure to thrive. *J Nat Sci Biol Med* 2015; **6**: 232-235 [PMID: 25810671 DOI: 10.4103/0976-9668.149198]

P- Reviewer: Hernandez-Sanchez S, Saedi B **S- Editor:** Ji FF
L- Editor: A **E- Editor:** Liu SQ





Published by **Baishideng Publishing Group Inc**

8226 Regency Drive, Pleasanton, CA 94588, USA

Telephone: +1-925-223-8242

Fax: +1-925-223-8243

E-mail: bpgoffice@wjgnet.com

Help Desk: <http://www.wjgnet.com/esps/helpdesk.aspx>

<http://www.wjgnet.com>

