

# World Journal of *Clinical Cases*

*World J Clin Cases* 2017 December 16; 5(12): 407-452



### ORIGINAL ARTICLE

#### Basic Study

- 407 Reliability of Sawai's classification for dental cervical abrasions: A pilot study  
*Sawai MA, Daing A, Adeel F, Chawla S*

#### Observational Study

- 412 Effect of *Helicobacter pylori* eradication on elder cases: Observational study in community-based medicine  
*Maruyama M, Kamimura K, Hoshiyama A, Hoshiyama K, Hoshiyama M, Hoshiyama Y, Terai S*

### CASE REPORT

- 419 Surgical resection of rare internal jugular vein aneurysm in neurofibromatosis type 1  
*Delvecchio K, Moghul F, Patel B, Seman S*
- 423 Human herpesvirus-8 positive iatrogenic Kaposi's sarcoma in the setting of refractory ulcerative colitis  
*Duh E, Fine S*
- 428 Sickle-cell and alpha-thalassemia traits resulting in non-atherosclerotic myocardial infarction: Beyond coincidence?  
*Nguyen LS, Redheuil A, Mangin O, Salem JE*
- 432 Taeniasis: A possible cause of ileal bleeding  
*Settesoldi A, Tozzi A, Tarantino O*
- 437 Do you want to participate in a clinical study as a healthy control? - Risk or benefit?  
*Giessen H, Nebiker CA, Bruehlmeier M, Spreitzer S, Mueller B, Schuetz P*
- 440 Embryonal rhabdomyosarcoma in the maxillary sinus with orbital involvement in a pediatric patient: Case report  
*de Melo ACR, Lyra TC, Ribeiro ILA, da Paz AR, Bonan PRF, de Castro RD, Valença AMG*
- 446 Topiramate induced peripheral neuropathy: A case report and review of literature  
*Hamed SA*

**ABOUT COVER**

Editorial Board Member of *World Journal of Clinical Cases*, Andreas G Schreyer, MD, Associate Professor, Department of Radiology, Regensburg University Medical Center, Regensburg 93051, Germany

**AIM AND SCOPE**

*World Journal of Clinical Cases* (*World J Clin Cases*, *WJCC*, online ISSN 2307-8960, DOI: 10.12998) is a peer-reviewed open access academic journal that aims to guide clinical practice and improve diagnostic and therapeutic skills of clinicians.

The primary task of *WJCC* is to rapidly publish high-quality Autobiography, Case Report, Clinical Case Conference (Clinicopathological Conference), Clinical Management, Diagnostic Advances, Editorial, Field of Vision, Frontier, Medical Ethics, Original Articles, Clinical Practice, Meta-Analysis, Minireviews, Review, Therapeutics Advances, and Topic Highlight, in the fields of allergy, anesthesiology, cardiac medicine, clinical genetics, clinical neurology, critical care, dentistry, dermatology, emergency medicine, endocrinology, family medicine, gastroenterology and hepatology, geriatrics and gerontology, hematology, immunology, infectious diseases, internal medicine, obstetrics and gynecology, oncology, ophthalmology, orthopedics, otolaryngology, pathology, pediatrics, peripheral vascular disease, psychiatry, radiology, rehabilitation, respiratory medicine, rheumatology, surgery, toxicology, transplantation, and urology and nephrology.

**INDEXING/ABSTRACTING**

*World Journal of Clinical Cases* is now indexed in PubMed, PubMed Central, Science Citation Index Expanded (also known as SciSearch®), and Journal Citation Reports/Science Edition.

**FLYLEAF**

I-V

Editorial Board

**EDITORS FOR THIS ISSUE**

Responsible Assistant Editor: *Xiang Li*  
Responsible Electronic Editor: *Ya-Jing Lu*  
Proofing Editor-in-Chief: *Lian-Sheng Ma*

Responsible Science Editor: *Jin-Xin Kong*  
Proofing Editorial Office Director: *Xiu-Xia Song*

**NAME OF JOURNAL**

*World Journal of Clinical Cases*

**ISSN**

ISSN 2307-8960 (online)

**LAUNCH DATE**

April 16, 2013

**FREQUENCY**

Monthly

**EDITORS-IN-CHIEF**

**Giuseppe Di Lorenzo, MD, PhD, Professor**, Genitourinary Cancer Section and Rare-Cancer Center, University Federico II of Napoli, Via Sergio Pansini, 5 Ed. 1, 80131, Naples, Italy

**Jan Jacques Michiels, MD, PhD, Professor**, Primary Care, Medical Diagnostic Center Rijnmond Rotterdam, Bloodcoagulation, Internal and Vascular Medicine, Erasmus University Medical Center, Rotterdam, Goodheart Institute and Foundation, Erasmus Tower, Veemnos 13, 3069 AT, Erasmus City, Rotterdam, The Netherlands

**Sandro Vento, MD**, Department of Internal Medicine, University of Botswana, Private Bag 00713, Gaborone, Botswana

**Shuhei Yoshida, MD, PhD**, Division of Gastroenterology, Beth Israel Deaconess Medical Center, Dana 509, Harvard Medical School, 330 Brookline Ave, Boston, MA 02215, United States

**EDITORIAL BOARD MEMBERS**

All editorial board members resources online at <http://www.wjgnet.com/2307-8960/editorialboard.htm>

**EDITORIAL OFFICE**

Xiu-Xia Song, Director  
*World Journal of Clinical Cases*  
Baishideng Publishing Group Inc  
7901 Stoneridge Drive, Suite 501, Pleasanton, CA 94588, USA  
Telephone: +1-925-2238242  
Fax: +1-925-2238243  
E-mail: [editorialoffice@wjgnet.com](mailto:editorialoffice@wjgnet.com)  
Help Desk: <http://www.f6publishing.com/helpdesk>  
<http://www.wjgnet.com>

**PUBLISHER**

Baishideng Publishing Group Inc  
7901 Stoneridge Drive,  
Suite 501, Pleasanton, CA 94588, USA  
Telephone: +1-925-2238242  
Fax: +1-925-2238243  
E-mail: [bpgoffice@wjgnet.com](mailto:bpgoffice@wjgnet.com)

Help Desk: <http://www.f6publishing.com/helpdesk>  
<http://www.wjgnet.com>

**PUBLICATION DATE**

December 16, 2017

**COPYRIGHT**

© 2017 Baishideng Publishing Group Inc. Articles published by this Open Access journal are distributed under the terms of the Creative Commons Attribution Non-commercial License, which permits use, distribution, and reproduction in any medium, provided the original work is properly cited, the use is non commercial and is otherwise in compliance with the license.

**SPECIAL STATEMENT**

All articles published in journals owned by the Baishideng Publishing Group (BPG) represent the views and opinions of their authors, and not the views, opinions or policies of the BPG, except where otherwise explicitly indicated.

**INSTRUCTIONS TO AUTHORS**

<http://www.wjgnet.com/bpg/gerinfo/204>

**ONLINE SUBMISSION**

<http://www.f6publishing.com>

## Surgical resection of rare internal jugular vein aneurysm in neurofibromatosis type 1

Khortnal Delvecchio, Fazaldin Moghul, Bipinchandra Patel, Susan Seman

Khortnal Delvecchio, Fazaldin Moghul, Bipinchandra Patel, Department of Surgery, Detroit Medical Center Huron Valley-Sinai Hospital, Commerce, MI 48382, United States

Khortnal Delvecchio, Fazaldin Moghul, Bipinchandra Patel, Susan Seman, Department of Surgery, Detroit Medical Center Sinai Grace Hospital, Detroit, MI 48235, United States

**Author contributions:** Delvecchio K, Moghul F and Patel B examined patient and collected clinical data; Moghul F and Patel B performed surgical resection and follow up; Delvecchio K and Moghul F wrote the paper; Patel B and Seman S edited the manuscript and had final approval.

**Institutional review board statement:** The authors' institution does not require IRB approval to publish a single case report.

**Informed consent statement:** Informed written consent was obtained from the patient prior to all procedures described in the report as well as for the use of the patient's clinical information and images for published scientific works.

**Conflict-of-interest statement:** All of the authors report no relationships that could be construed as a conflict of interest.

**Open-Access:** This article is an open-access article which was selected by an in-house editor and fully peer-reviewed by external reviewers. It is distributed in accordance with the Creative Commons Attribution Non Commercial (CC BY-NC 4.0) license, which permits others to distribute, remix, adapt, build upon this work non-commercially, and license their derivative works on different terms, provided the original work is properly cited and the use is non-commercial. See: <http://creativecommons.org/licenses/by-nc/4.0/>

**Manuscript source:** Unsolicited manuscript

**Correspondence to:** Khortnal Delvecchio, DO, General Surgery Resident, Department of Surgery, Detroit Medical Center Sinai Grace Hospital, Room M5H02, 6071 W. Outer Drive, Detroit, MI 48235, United States. [kdelvecc@dmc.org](mailto:kdelvecc@dmc.org)  
Telephone: +1-248-7906442  
Fax: +1-313-9664204

Received: February 26, 2017

Peer-review started: March 2, 2017

First decision: May 23, 2017

Revised: September 10, 2017

Accepted: November 22, 2017

Article in press: November 22, 2017

Published online: December 16, 2017

### Abstract

Neurofibromatosis type 1 is a congenital condition affecting neurons and connective tissue integrity including vasculature. On extremely rare occasions these patients present with venous aneurysms affecting the internal jugular vein. If they become large enough there presents a risk of rupture, thrombosis, embolization or compression of adjacent structures. In these circumstances, or when the patient becomes symptomatic, surgical exploration is warranted. We present a case of one of the largest aneurysms in the literature and one of only five associated with Neurofibromatosis type 1. A 63-year-old female who initially presented for a Hinchey III diverticulitis requiring laparotomy developed an incidentally discovered left neck swelling prior to discharge. After nonspecific clinical exam findings, imaging identified a thrombosed internal jugular vein aneurysm. Due to the risks associated with the particularly large size of our patient's aneurysm, our patient underwent surgical exploration with ligation and excision. Although several techniques have been reported, for similar presentations, we recommend this technique.

**Key words:** Internal jugular; Venous aneurysm; Ligation; Neurofibromatosis 1; Excision; Resection

© **The Author(s) 2017.** Published by Baishideng Publishing Group Inc. All rights reserved.

**Core tip:** Neurofibromatosis type 1 is a congenital condition occasionally affecting vascular connective tissue integrity. On extremely rare occasions these patients present with internal jugular venous aneurysms. We

present a case of the successful ligation and excision of one of the largest internal jugular vein aneurysms in the literature and one of only five associated with Neurofibromatosis type 1.

Delvecchio K, Moghul F, Patel B, Seman S. Surgical resection of rare internal jugular vein aneurysm in neurofibromatosis type 1. *World J Clin Cases* 2017; 5(12): 419-422 Available from: URL: <http://www.wjgnet.com/2307-8960/full/v5/i12/419.htm> DOI: <http://dx.doi.org/10.12998/wjcc.v5.i12.419>

## INTRODUCTION

Initially described by Gruber<sup>[1]</sup> in 1875, internal jugular (IJ) aneurysms are rare entities with under 400 reported in the last 100 years in the literature. As described by Lubianca-Neto *et al*<sup>[2]</sup> these lesions have historically been described as “congenital venous cyst, venous pseudoaneurysm, venous ectasia, venous aneurysm, venous cyst, venoma, and internal jugular phlebectasia” in the literature, with an average age of under 10 and over 60% under age 40<sup>[3,4]</sup>. They most commonly occur on the right side, however may be bilateral in as many as 10% of cases<sup>[5,6]</sup>. These aneurysms classically present as unilateral, asymptomatic, soft, compressible neck swellings that enlarge with Valsalva<sup>[1-3]</sup>. Due to the relationship of the IJ abutting the vagus nerve within the carotid sheath, patients may complain of hoarseness, dysphagia or foreign body sensation<sup>[1,5,7]</sup>. Moreover, the absence of bruit or pulsation on physical exam excludes a more ominous arterial pathology<sup>[1,8]</sup>.

While the underlying physiology that makes a particular patient susceptible to aneurysm formation is largely unknown, several inciting factors have been reported in the literature. These include trauma from central venous catheterization, positive-pressure ventilation, inflammation, distal obstruction from a mass, or unknown idiopathic causes<sup>[2,7,9]</sup>. Additionally, pathological analyses of resected aneurysms have described congenital thinning of the elastic and muscular layers of the venous wall, and/or elastin dysplasia<sup>[10,11]</sup>. Not surprisingly, disorders of connective tissue, including Ehlers-Danlos and Neurofibromatosis type 1 (NF1), have been linked to these anomalies<sup>[4,12-14]</sup>.

NF1 aka von Recklinghausen's disease is an autosomal dominant mutation of chromosome 17 occurring in 1 in 3000 people that alters the neurofibromin protein, affecting the structural integrity of connective tissues and nerves<sup>[12,13]</sup>. Typical presentations include neurofibromas, café au lait macules, Lisch hamartomas, meningiomas, and gliomas<sup>[13,14]</sup>. Rarer manifestations involve the vasculature which can be present in up to 6.4% of patients, however it primarily involves the arterial system<sup>[12,15]</sup>. We present a case of the successful ligation and excision of one of the largest IJ vein aneurysms in the literature and one of only five associated with NF1.

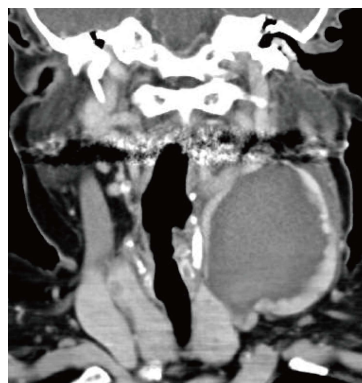

Figure 1 Coronal computed tomography of left internal jugular vein aneurysm.

## CASE REPORT

A 63-year-old Caucasian female with a medical history significant for Neurofibromatosis presented to the emergency room with bilateral lower quadrant abdominal pain, diarrhea, emesis and complaints of fevers and chills for one day. She was tachycardic and peritoneal on examination and thus taken to the operating room where she underwent sigmoid resection with end colostomy and Hartmann's pouch for Hinchey III diverticulitis. Postoperatively the patient remained intubated and was admitted to the ICU and had a left subclavian central venous catheter placed for vasopressor support. After a series of setbacks, the patient began to improve significantly around postoperative day (POD) 11 and her subclavian line was able to be removed. By POD 15 the patient was ready for discharge to rehab.

Upon preparing for departure the patient noticed in the mirror a bulge in her left neck that she did not previously feel. The nursing staff and subsequently physicians were notified. Upon examination there was no noticeable mass as the patient had significant submental ptosis. A computed tomography (CT) scan of the neck was performed which showed a 5.8 cm × 6.9 cm × 5.4 cm internal jugular collection with anterior displacement of the sternocleidomastoid (SCM) (Figures 1 and 2). The vascular surgeon was notified and a triplex ultrasound was performed showing a 6.9 cm × 3.8 cm × 6.5 cm internal jugular thrombus with minimal superior flow and a patent subclavian (Figure 3).

On POD 16 the patient was taken to the operating room where she underwent evacuation, resection and ligation of the internal jugular aneurysm *via* an anterior SCM incision. Small internal branches were ligated and the anterior vein wall was sutured closed. There was an estimated blood loss of 1 liter during dissection due to avulsion of many of these internal branches. The skin was closed and a Jackson-Pratt (JP) drain was left subcutaneously. Postoperatively the JP was removed on day 1 due to minimal output and the patient was able to be discharged home on day 2.



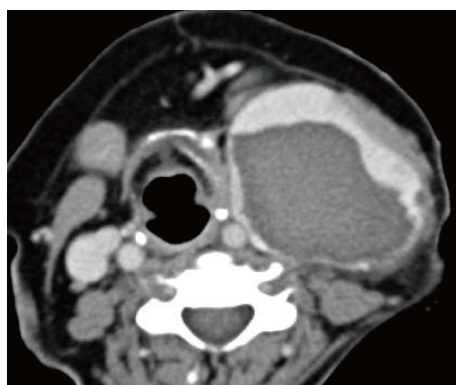

Figure 2 Transverse computed tomography of left internal jugular vein aneurysm.

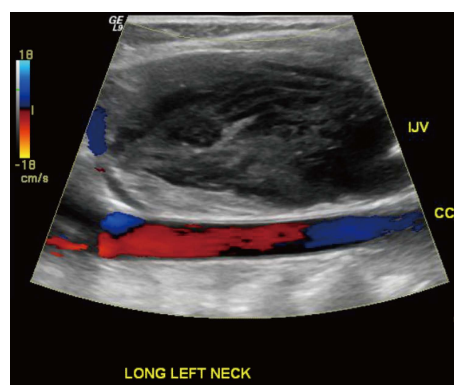


Figure 3 Color flow doppler ultrasound image depicting patent left common carotid artery and thrombosed left internal jugular vein aneurysm.

Table 1 Characteristics of Neurofibromatosis type 1-associated internal jugular aneurysms in the literature

Ref.	Age/sex	Side	Size (cm)	Treatment	Thrombosed	Confirmed NF1 in wall
Nopajaroonsri and Lurie <sup>[14]</sup> (1996)	62 M	Left	10 × 5 × 4.5	Resection	Yes	Yes
Oderich <i>et al</i> <sup>[13]</sup> (2007)	73 M	Right	"Giant"	Resection	Yes	
Belcastro <i>et al</i> <sup>[15]</sup> (2011)	60 F	Left	12 × 12 × 10	Resection	Yes	Yes
Hiraki <i>et al</i> <sup>[12]</sup> (2014)	60 M	Left	5.5 × 5 × 2	Resection	Yes	Yes
The present case	63 F	Left	6.9 × 5.8 × 5.4	Resection	Yes	

M: Male; F: Female; NF1: Neurofibromatosis type 1.

## DISCUSSION

Limitations to our workup include not submitting the aneurysmal wall for pathological analysis as 3 of the 4 described aneurysms associated with NF1 in the literature describe histopathological invasion of NF1 into the wall<sup>[12,14,15]</sup>. While not necessary for the diagnosis, it could have helped substantiate a more definitive pathological explanation. Additionally, several authors have recommended that the diagnostic workup include bilateral triplex ultrasound performed with Valsalva<sup>[4-6]</sup>. The importance of a size increase with Valsalva during examinations is underscored by the fact that the majority of differential diagnoses can be ruled out if absent, leaving phlebectasias, laryngoceles and superior mediastinal cyst<sup>[4]</sup>. The most common of these, laryngocele, can be ruled out with laryngoscopy, whereas mediastinal cysts can be ruled out with CT scan<sup>[5]</sup>. Although our patient's diagnosis was easily identified with CT and confirmed with triplex ultrasound, it was not performed with these particular suggestions in mind.

Although clinical exam can provide a significant amount of information, because of the low overall rate of complications there is often adequate time for definitive imaging. As mentioned previously, triplex ultrasound is the current standard for diagnostic accuracy as it will allow for characterization of the aneurysmal size as well as visualization of directional blood flow and thrombosis<sup>[2,4,5]</sup>. Additionally, Passariello *et al*<sup>[16]</sup>, described four cases in children that were successfully characterized with endovascular digital subtraction

contrast fluoroscopy which has the additional benefit of simultaneous diagnosis and intervention<sup>[17]</sup>.

As described above, a commonly cited etiology of IJ aneurysms is traumatic central venous catheterization<sup>[7]</sup>. A limitation with our case was the prolonged duration with which her left subclavian line was in place, possibly leading to thrombosis and propagation. It is difficult to definitively determine if the subclavian line was the inciting event, however it is likely it participated in a genetically susceptible patient.

IJ aneurysms have rarely been reported on and only a handful have been described in association with NF1 (Table 1)<sup>[12-15]</sup>. These lesions typically present much larger than other cases and ours, at 6.9 cm × 5.8 cm × 5.4 cm, is one of the largest described in the literature. Each of these aneurysms were surgically resected and each had significant blood loss<sup>[12-15]</sup>.

With regard to management, because IJ aneurysms are considered to be self-limiting, operative intervention is usually reserved for cosmetic or symptomatic reasons<sup>[2,5,10,18]</sup>. Although extremely rare, if there is significant concern for thrombosis, embolization or impending rupture, resection is justified<sup>[10]</sup>. Various approaches have been described which have been largely based on size and location, including anterior SCM, transverse cervical and median sternotomy incisions<sup>[4,5,15]</sup>. Additionally Chua *et al*<sup>[17]</sup>, describe a combined endovascular balloon ligation and open resection, allowing for a smaller incision. Regardless of the approach, it is important preoperatively to confirm contralateral patency for cerebral edema prevention<sup>[2]</sup> as Hu *et al*<sup>[8]</sup>, reported 2 cases of unilateral ligation of bilateral lesions resulting in 3

d of cerebral swelling. While many IJ vein aneurysms have reportedly been followed successfully without intervention for up to 15 years, no studies have been performed that compare long-term outcomes of any kind<sup>[6]</sup>. This leads to the suggestion of future randomized trials featuring long-term outcomes of conservative management vs various surgical procedures.

## COMMENTS

### Case characteristics

A 63-year-old woman with neurofibromatosis type 1 who developed an incidentally discovered internal jugular vein aneurysm that was surgically resected.

### Clinical diagnosis

Compressible left-sided neck swelling without dysphagia or respiratory compromise.

### Differential diagnosis

Differential diagnoses include phlebectasias, laryngoceles, superior mediastinal cyst, thyroglossal duct cyst, cystic hygroma, branchial cleft cyst, pharyngocoele, dermoid cyst, thyroid mass, arteriovenous malformation, carotid body tumor and squamous cell carcinoma of the neck.

### Laboratory diagnosis

All labs were within normal limits.

### Imaging diagnosis

Computed tomography scan showed a 5.8 cm × 6.9 cm × 5.4 cm internal jugular collection with anterior displacement of the sternocleidomastoid. A triplex ultrasound showed a 6.9 cm × 3.8 cm × 6.5 cm internal jugular thrombus with minimal superior flow and a patent subclavian.

### Treatment

Surgical evacuation, resection and ligation of the aneurysm.

### Related reports

Internal jugular venous aneurysms have historically gone by several names in the literature and despite very few resulting in significant morbidity with expectant management alone, they are frequently surgically resected.

### Term explanation

Triplex ultrasound is an imaging method that uses color to highlight direction of vascular flow. It is the recommended diagnostic method to characterize these lesions.

### Experiences and lessons

Patients with neurofibromatosis type 1 are particularly susceptible to internal jugular vein aneurysms due to vascular wall abnormalities, which should be noted when inciting etiological events occur such as central venous catheterization.

### Peer-review

The information and brief literature review provided was sufficient.

## REFERENCES

1 Sander S, Eliçevik M, Unal M, Vural O. Jugular phlebectasia in

- children: is it rare or ignored? *J Pediatr Surg* 1999; **34**: 1829-1832 [PMID: 10626865 DOI: 10.1016/S0022-3468(99)90323-8]
- 2 Lubianca-Neto JF, Mauri M, Prati C. Internal jugular phlebectasia in children. *Am J Otolaryngol* 1999; **20**: 415-418 [PMID: 10609490 DOI: 10.1016/S0196-0709(99)90085-6]
- 3 Refson JS, Wolfe JH. An aneurysm of the internal jugular vein. *Eur J Vasc Endovasc Surg* 1996; **11**: 371-372 [PMID: 8601253 DOI: 10.1016/S1078-5884(96)80089-X]
- 4 Jianhong L, Xuewu J, Tingze H. Surgical treatment of jugular vein phlebectasia in children. *Am J Surg* 2006; **192**: 286-290 [PMID: 16920419 DOI: 10.1016/j.amjsurg.2006.02.025]
- 5 Hung T, Campbell AI. Surgical repair of left internal jugular phlebectasia. *J Vasc Surg* 2008; **47**: 1337-1338 [PMID: 18514849 DOI: 10.1016/j.jvs.2007.12.040]
- 6 Haney JC, Shortell CK, McCann RL, Lawson JH, Stirling MJ, Stone DH. Congenital jugular vein phlebectasia: a case report and review of the literature. *Ann Vasc Surg* 2008; **22**: 681-683 [PMID: 18462919 DOI: 10.1016/j.avsg.2008.02.003]
- 7 Nakayama M, Fujita S, Kawamata M, Namiki A, Mayumi T. Traumatic aneurysm of the internal jugular vein causing vagal nerve palsy: a rare complication of percutaneous catheterization. *Anesth Analg* 1994; **78**: 598-600 [PMID: 8109783]
- 8 Hu X, Li J, Hu T, Jiang X. Congenital jugular vein phlebectasia. *Am J Otolaryngol* 2005; **26**: 172-174 [PMID: 15858772 DOI: 10.1016/j.amjoto.2005.02.009]
- 9 Spiro SA, Coccaro SF, Bogucki E. Aneurysm of the internal jugular vein manifesting after prolonged positive pressure ventilation. *Head Neck* 1991; **13**: 450-452 [PMID: 1938366 DOI: 10.1002/hed.2880130515]
- 10 Swaika S, Basu S, Bhadra RC, Maitra S. Multiple venous aneurysms of neck. *J Indian Assoc Pediatr Surg* 2013; **18**: 25-26 [PMID: 23599580 DOI: 10.4103/0971-9261.107013]
- 11 Danis RK. Isolated aneurysm of the internal jugular vein: a report of three cases. *J Pediatr Surg* 1982; **17**: 130-131 [PMID: 7077491 DOI: 10.1016/S0022-3468(82)80195-4]
- 12 Hiraki T, Higashi M, Goto Y, Kitazono I, Yokoyama S, Iuchi H, Nagano H, Tanimoto A, Yonezawa S. A rare case of internal jugular vein aneurysm with massive hemorrhage in neurofibromatosis type 1. *Cardiovasc Pathol* 2014; **23**: 244-247 [PMID: 24630569 DOI: 10.1016/j.carpath.2014.02.001]
- 13 Oderich GS, Sullivan TM, Bower TC, Gloviczki P, Miller DV, Babovic-Vuksanovic D, Macedo TA, Stanson A. Vascular abnormalities in patients with neurofibromatosis syndrome type I: clinical spectrum, management, and results. *J Vasc Surg* 2007; **46**: 475-484 [PMID: 17681709 DOI: 10.1016/j.jvs.2007.03.055]
- 14 Nopajaroonsri C, Lurie AA. Venous aneurysm, arterial dysplasia, and near-fatal hemorrhages in neurofibromatosis type 1. *Hum Pathol* 1996; **27**: 982-985 [PMID: 8816897 DOI: 10.1016/S0046-8177(96)90229-4]
- 15 Belcastro M, Palleschi A, Trovato RA, Landini R, Di Bisceglie M, Natale A. A rare case of internal jugular vein aneurysmal degeneration in a type 1 neurofibromatosis complicated by potentially life-threatening thrombosis. *J Vasc Surg* 2011; **54**: 1170-1173 [PMID: 21684713 DOI: 10.1016/j.jvs.2011.03.273]
- 16 Passariello R, Cozzi F, Casalena G, Colarossi G, Rossi P, Simonetti G. Angiographic diagnosis of jugular venous system dilatation in children. A report of five cases. *Pediatr Radiol* 1979; **8**: 247-250 [PMID: 514682]
- 17 Chua W, Xu G, Cheng SC. Hybrid surgical management of a saccular aneurysm of the internal jugular vein. *Singapore Med J* 2012; **53**: e90-e91 [PMID: 22584988]
- 18 Khashram M, Walker PJ. Internal jugular venous aneurysm. *J Vasc Surg Venous Lymphat Disord* 2015; **3**: 94 [PMID: 26993688 DOI: 10.1016/j.jvsv.2014.05.001]

P- Reviewer: Lai V S- Editor: Kong JX L- Editor: A  
E- Editor: Lu YJ





Published by **Baishideng Publishing Group Inc**  
7901 Stoneridge Drive, Suite 501, Pleasanton, CA 94588, USA  
Telephone: +1-925-223-8242  
Fax: +1-925-223-8243  
E-mail: [bpgoffice@wjgnet.com](mailto:bpgoffice@wjgnet.com)  
Help Desk: <http://www.f6publishing.com/helpdesk>  
<http://www.wjgnet.com>

