

World Journal of *Clinical Cases*

World J Clin Cases 2017 May 16; 5(5): 159-190





REVIEW

- 159 Evolution, current status and advances in application of platelet concentrate in periodontics and implantology
Agrawal AA

ORIGINAL ARTICLE

Observational Study

- 172 Robotic single-site supracervical hysterectomy with manual morcellation: Preliminary experience
Ding DC, Hong MK, Chu TY, Chang YH, Liu HW

CASE REPORT

- 178 Ticagrelor therapy and atrioventricular block: Do we need to worry?
De Maria E, Borghi A, Modonesi L, Cappelli S
- 183 Unusual presentation of nasopharyngeal carcinoma with rectal metastasis
Vogel M, Kourie HR, Piccart M, Lalami Y
- 187 *Elizabethkingia miricola*: A rare non-fermenter causing urinary tract infection
Gupta P, Zaman K, Mohan B, Taneja N

Contents

World Journal of Clinical Cases
Volume 5 Number 5 May 16, 2017

ABOUT COVER

Editorial Board Member of *World Journal of Clinical Cases*, Martin P Schencking, MD, Senior Lecturer, Department of Primary Care Research, University of Witten-Herdecke's Medical School, 58448 Witten, Germany

AIM AND SCOPE

World Journal of Clinical Cases (*World J Clin Cases*, *WJCC*, online ISSN 2307-8960, DOI: 10.12998) is a peer-reviewed open access academic journal that aims to guide clinical practice and improve diagnostic and therapeutic skills of clinicians.

The primary task of *WJCC* is to rapidly publish high-quality Autobiography, Case Report, Clinical Case Conference (Clinicopathological Conference), Clinical Management, Diagnostic Advances, Editorial, Field of Vision, Frontier, Medical Ethics, Original Articles, Clinical Practice, Meta-Analysis, Minireviews, Review, Therapeutics Advances, and Topic Highlight, in the fields of allergy, anesthesiology, cardiac medicine, clinical genetics, clinical neurology, critical care, dentistry, dermatology, emergency medicine, endocrinology, family medicine, gastroenterology and hepatology, geriatrics and gerontology, hematology, immunology, infectious diseases, internal medicine, obstetrics and gynecology, oncology, ophthalmology, orthopedics, otolaryngology, pathology, pediatrics, peripheral vascular disease, psychiatry, radiology, rehabilitation, respiratory medicine, rheumatology, surgery, toxicology, transplantation, and urology and nephrology.

INDEXING/ABSTRACTING

World Journal of Clinical Cases is now indexed in PubMed, PubMed Central.

FLYLEAF

I-V

Editorial Board

EDITORS FOR THIS ISSUE

Responsible Assistant Editor: *Xiang Li*
Responsible Electronic Editor: *Ya-Jing Lu*
Proofing Editor-in-Chief: *Lian-Sheng Ma*

Responsible Science Editor: *Jin-Xin Kong*
Proofing Editorial Office Director: *Xiu-Xia Song*

NAME OF JOURNAL

World Journal of Clinical Cases

ISSN

ISSN 2307-8960 (online)

LAUNCH DATE

April 16, 2013

FREQUENCY

Monthly

EDITORS-IN-CHIEF

Giuseppe Di Lorenzo, MD, PhD, Professor, Genitourinary Cancer Section and Rare-Cancer Center, University Federico II of Napoli, Via Sergio Pansini, 5 Ed. 1, 80131, Naples, Italy

Jan Jacques Michiels, MD, PhD, Professor, Primary Care, Medical Diagnostic Center Rijnmond Rotterdam, Bloodcoagulation, Internal and Vascular Medicine, Erasmus University Medical Center, Rotterdam, Goodheart Institute and Foundation, Erasmus Tower, Veemnos 13, 3069 AT, Erasmus City, Rotterdam, The Netherlands

Sandro Vento, MD, Department of Internal Medicine, University of Botswana, Private Bag 00713, Gaborone, Botswana

Shuhei Yoshida, MD, PhD, Division of Gastroenterology, Beth Israel Deaconess Medical Center, Dana 509, Harvard Medical School, 330 Brookline Ave, Boston, MA 02215, United States

EDITORIAL BOARD MEMBERS

All editorial board members resources online at <http://www.wjgnet.com/2307-8960/editorialboard.htm>

EDITORIAL OFFICE

Xiu-Xia Song, Director
World Journal of Clinical Cases
Baishideng Publishing Group Inc
7901 Stoneridge Drive, Suite 501, Pleasanton, CA 94588, USA
Telephone: +1-925-2238242
Fax: +1-925-2238243
E-mail: editorialoffice@wjgnet.com
Help Desk: <http://www.f6publishing.com/helpdesk>
<http://www.wjgnet.com>

PUBLISHER

Baishideng Publishing Group Inc
7901 Stoneridge Drive,
Suite 501, Pleasanton, CA 94588, USA
Telephone: +1-925-2238242
Fax: +1-925-2238243
E-mail: bpgoffice@wjgnet.com

Help Desk: <http://www.f6publishing.com/helpdesk>
<http://www.wjgnet.com>

PUBLICATION DATE

May 16, 2017

COPYRIGHT

© 2017 Baishideng Publishing Group Inc. Articles published by this Open Access journal are distributed under the terms of the Creative Commons Attribution Non-commercial License, which permits use, distribution, and reproduction in any medium, provided the original work is properly cited, the use is non commercial and is otherwise in compliance with the license.

SPECIAL STATEMENT

All articles published in journals owned by the Baishideng Publishing Group (BPG) represent the views and opinions of their authors, and not the views, opinions or policies of the BPG, except where otherwise explicitly indicated.

INSTRUCTIONS TO AUTHORS

<http://www.wjgnet.com/bpg/gerinfo/204>

ONLINE SUBMISSION

<http://www.f6publishing.com>

***Elizabethkingia miricola*: A rare non-fermenter causing urinary tract infection**

Parakriti Gupta, Kamran Zaman, Balvinder Mohan, Neelam Taneja

Parakriti Gupta, Kamran Zaman, Balvinder Mohan, Neelam Taneja, Department of Medical Microbiology, Postgraduate Institute of Medical Education and Research, Chandigarh 160012, India

Author contributions: All authors have contributed equally to the acquisition of data, writing, drafting the article and revision of the manuscript; all the authors have given the final approval for the article to be published.

Institutional review board statement: The present case report has been retrospectively reviewed and reported and it didn't require any institutional ethics committee approval.

Informed consent statement: The patient involved in this study has given written informed consent authorizing use and disclosure of his health information.

Conflict-of-interest statement: None.

Open-Access: This article is an open-access article which was selected by an in-house editor and fully peer-reviewed by external reviewers. It is distributed in accordance with the Creative Commons Attribution Non Commercial (CC BY-NC 4.0) license, which permits others to distribute, remix, adapt, build upon this work non-commercially, and license their derivative works on different terms, provided the original work is properly cited and the use is non-commercial. See: <http://creativecommons.org/licenses/by-nc/4.0/>

Manuscript source: Invited manuscript

Correspondence to: Dr. Neelam Taneja, Professor, Department of Medical Microbiology, Post Graduate Institute of Medical Education and Research, Sector 12, Chandigarh 160012, India. drneelamptgi@yahoo.com
Telephone: +91-172-2755160
Fax: +91-172-2744401

Received: November 16, 2016
Peer-review started: November 21, 2016
First decision: January 14, 2017
Revised: February 9, 2017
Accepted: March 12, 2017
Article in press: March 13, 2017
Published online: May 16, 2017

Abstract

Elizabethkingia miricola (*E. miricola*) is a gram-negative non-fermentative bacterium which is rarely encountered. It is usually misidentified or considered as a contaminant in routine microbiology laboratories due to the limitations in conventional biochemical techniques. However, with the advent of the matrix-assisted laser desorption ionization time-of-flight mass spectrometry (MALDI-TOF-MS), the identification of non-fermenters has become easy and this has led to enhanced understanding of the clinical significance of these uncommonly isolated microorganisms. The genus *Elizabethkingia* has only two species *E. meningoseptica* and *E. miricola*. Both of these organisms are known to be multi-drug resistant and therefore, their accurate identification and antimicrobial susceptibility testing are necessary prior to the initiation of appropriate therapy. In the world literature till date, only 3 cases of sepsis caused by *E. miricola* have been reported. We present the first case of *E. miricola* association with urinary tract infection.

Key words: *Elizabethkingia miricola*; Antibiotics; Urinary tract infections; Matrix-assisted laser desorption ionization time-of-flight; Non-fermenters

© The Author(s) 2017. Published by Baishideng Publishing Group Inc. All rights reserved.

Core tip: Non-fermenters except *Pseudomonas* and *Acinetobacter* are less commonly associated with urinary tract infection (UTI). But recently an upsurge in a number of reported cases has been noted due to the use of MALDI-TOF which is an easy and reliable identification technique. Till date in literature, there is no reported case of *Elizabethkingia miricola* (*E. miricola*) causing UTI, although its significance in blood and sputum samples of sepsis patients has been demonstrated earlier. This is the first case report showing a clinical association of *E. miricola* with symptomatic UTI and also demonstrating the multidrug resistance nature of this organism.

Gupta P, Zaman K, Mohan B, Taneja N. *Elizabethkingia miricola*: A rare non-fermenter causing urinary tract infection. *World J Clin Cases* 2017; 5(5): 187-190 Available from: URL: <http://www.wjgnet.com/2307-8960/full/v5/i5/187.htm> DOI: <http://dx.doi.org/10.12998/wjcc.v5.i5.187>

INTRODUCTION

Urinary tract infections (UTI) are amongst the most common bacterial infections occurring in human beings during their lifetime^[1]. The usual organisms responsible for UTI belong to the family *Enterobacteriaceae* and gram-positive bacteria like *Staphylococcus* and *Enterococcus*^[2]. UTI caused by non-fermenters (NF) is being increasingly reported especially in the nosocomial settings, with *Pseudomonas* and *Acinetobacter* spp. being the most common agents. However, UTI due to other NFs like *Alcaligenes*, *Flavobacterium*, *Oligella*, *Flavimonas*, *Agrobacter*, *Weeksiella* are also on the rise^[3]. Routine laboratory identification of NF is difficult and labour-intensive, which often misclassifies or misidentifies these agents and thereby may mask the exact clinical significance of these isolates. Nowadays, the identification of these NF has become easy by the advent of matrix-assisted laser desorption ionization time-of-flight mass spectrometry (MALDI-TOF-MS). We recently encountered a case of UTI caused by rare multidrug resistant non-fermenter *E. miricola*, which was identified by MALDI-TOF.

CASE REPORT

A 25-year-old female presented with complaints of increased bowel frequency, oliguria, fever and abdominal pain since one month. Detailed history revealed that the patient had difficulty in micturition for past two weeks. The routine laboratory investigations revealed a haemoglobin of 7.8 gm/dL, total leucocytes count 3200 cells/mm³, platelet count of 70000 cells/mm³. Renal function tests revealed normal sodium concentration (139 mEq/L), hyperkalemia (8.2 mEq/L), hyperuricemia (74 mg/dL) and elevated creatinine levels (7.5 mg/dL). Coagulation profile was normal. Ultrasonography (USG) revealed bilateral hydronephrosis with normal renal parenchyma and features of vesicoureteric reflux. The midstream urine sample was subjected to microbiological testing. The wet mount microscopic examination showed 1-2 RBCs, numerous pus cells and bacteria per high-power field^[4]. The semi-quantitative culture done on the cysteine lysine electrolyte deficient agar showed significant bacterial growth (colony count > 10⁵ CFU/mL). The colonies were non-lactose fermenting, translucent, greenish blue, smooth having entire edges and became mucoid on prolonged incubation. Subculture on MacConkey agar showed pale, translucent, glistening colonies with entire edges (Figure 1). Gram staining showed 0.5 µm × 2 µm gram-negative bacilli, with no

spores and no capsule. The isolate was also subjected to conventional identification using a battery of biochemical tests. The isolate was catalase positive, oxidase positive, produced indole, was non-nitrate reducing, mannitol fermenting, esculin and gelatinase hydrolysis positive. Urease was produced and this test helped to distinguish it from *E. meningoseptica*. The isolate was confirmed as *Elizabethkingia miricola* (*E. miricola*) (identification score of 2.29) by using MALDI-TOF-MS (BrukerDaltonics, Bremen, Germany). The antimicrobial susceptibility was carried out using Kirby-Bauer disc diffusion method and the antibiotics tested were chosen from the available literature as there are no CLSI guidelines available till now^[5,6]. The isolate was sensitive to gentamicin, ceftriaxone, aztreonam, piperacillin-tazobactam and imipenem, and resistant to ampicillin, ciprofloxacin, levofloxacin, vancomycin and colistin. The patient was started on piperacillin-tazobactam and responded well to the treatment. The patient improved clinically and the follow-up urine culture after two weeks of therapy was sterile.

DISCUSSION

E. miricola was first isolated from Mir space station, Russia and hence named as *E. miricola*^[7]. Previously, it was classified into genus *Chryseobacterium* but later in 2005, the genus was changed to *Elizabethkingia* on the basis of the comparative analytical studies involving DNA hybridization and sequencing of the 16S rRNA region^[8]. *E. miricola* is a gram-negative (0.5 µm × 1-2.5 µm), non-motile, non-spore-forming bacterium. It grows well on blood and MacConkey agar producing non-fermenting sticky colonies. Biochemical reactions show indole positive, citrate positive, produce acid from D-glucose, D-fructose, D-lactose, trehalose, D-mannitol, D-maltose, but not from D-xylose, L-arabinose, D-cellobiose, sucrose and raffinose. It can be differentiated from *Chryseobacterium* because of the absence of yellow pigment in culture. Urease production is the test used to differentiate *E. miricola* from *E. meningoseptica*^[8]. Till date, *E. miricola* has been isolated from blood and sputum and has been found to be responsible for sepsis. The first case of *E. miricola* was reported in 2008 in an adult with mantle cell carcinoma, who underwent stem cell transplant^[5]. In this case, *E. miricola* was isolated from sputum and blood and the identification was confirmed using 16S rRNA sequencing. Later on, *E. miricola* was isolated from the blood sample of a young female with alcoholic pancreatitis^[6]. More recently, *E. miricola* has been isolated from a patient with severe sepsis and pulmonary abscess^[9]. In both the above cases, the isolate was identified by MALDI-TOF. In the present case, *E. miricola* was isolated from the urine sample of a young female with clinical features of UTI and bilateral hydronephrosis. The clinical presentation pointed towards differential diagnosis like pyelonephritis, renal abscess, renal infarction, venous obstruction or ATN. However, the USG findings of bilateral hydronephrosis and sterile blood culture pointed

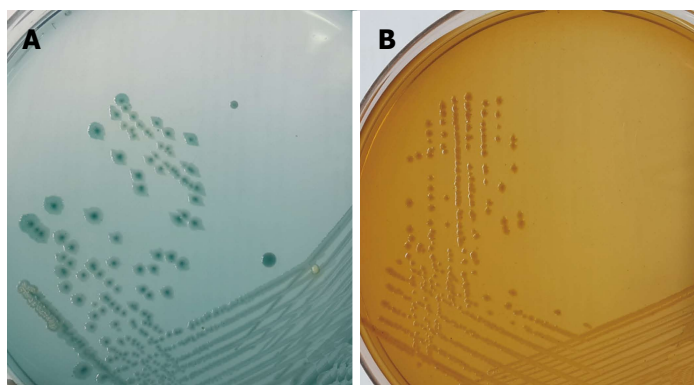


Figure 1 Culture plates showing the growth of *Elizabethkingia miricola* on (A) cystine-lactose-electrolyte-deficient medium agar and (B) MacConkey agar.

towards localised urinary tract infection.

E. miricola has been found to be multidrug resistant similar to *E. meningoseptica* which is known to harbor β -lactamases showing resistant to β -lactams and carbapenems^[10]. The *E. miricola* isolates have been found to be resistant to many antibiotics. Previous studies have shown resistance to ampicillin, ceftazidime, imipenem, gentamicin, cotrimoxazole, colistin and with variable susceptibility to ciprofloxacin, vancomycin and rifampicin^[5,6,11]. It is interesting to note that, *E. miricola* isolates in previous studies were sensitive to levofloxacin, but in our case, the isolate was resistant to both ciprofloxacin and levofloxacin. Limited clinical reports, varied susceptibility profiles, lack of antimicrobial susceptibility breakpoint and no defined consensus for the empiric treatment regimen makes it difficult to treat such rare organisms.

We present the first case report of human UTI caused by rare multidrug resistant *E. miricola*. The present case emphasizes the clinical importance of rare non-fermenters like *E. miricola* in human infections especially in case of UTI. The knowledge of newer species and their antimicrobial susceptibility profile will help in formulating appropriate antibiotic treatment regimens to tackle such rarely encountered bacteria.

COMMENTS

Case characteristics

A 25-year-old female complaining of difficulty in micturition, oliguria fever with abdominal pain.

Clinical diagnosis

Urinary tract infections (UTI) with bilateral hydronephrosis.

Differential diagnosis

Chronic pyelonephritis.

Laboratory diagnosis

The routine laboratory investigations revealed anemia, leucopenia, hyperkalemia, hyperuricaemia and elevated creatinine levels. Urine culture had significant bacterial growth (colony count $>10^5$ CFU/mL) of *Elizabethkingia miricola* (*E. miricola*).

Imaging diagnosis

Bilateral hydronephrosis.

Pathological diagnosis

Bilateral hydronephrosis with urinary tract infection.

Treatment

Piperacillin-tazobactam.

Related reports

E. miricola has been reported to cause sepsis and pulmonary infection.

Experiences and lessons

Rare non-fermenters can cause UTI and prompt identification is required to guide proper antimicrobial therapy. CLSI/EUCAST guidelines need to be developed.

Peer-review

Interesting case of unusual bacterial cause of UTI with a severe clinical scenario.

REFERENCES

- 1 **Hausler SM**. Urinary tract infections. Topley and Wilson's Microbiology and Microbial infections. 9th edition. London: Edward Arnold, 1998
- 2 **Warren JW**. Clinical presentations and epidemiology of urinary tract infection. In: Mobley HL, Warren JW, editors. Urinary tract infections molecular pathogenesis and clinical management. Washington DC: American Society for Microbiology Press, 1996: 3-27
- 3 **KLS, Rao GG, Kukkamalla AM**. Prevalence of Non-fermenters In Urinary Tract Infections In A Tertiary Care Hospital. *Webmed Central Microbiology* 2011; **2**: WMC001464
- 4 **Wilson ML, Gaido L**. Laboratory diagnosis of urinary tract infections in adult patients. *Clin Infect Dis* 2004; **38**: 1150-1158 [PMID: 15095222 DOI: 10.1086/383029]
- 5 **Green O, Murray P, Gea-Banacloche JC**. Sepsis caused by *Elizabethkingia miricola* successfully treated with tigecycline and levofloxacin. *Diagn Microbiol Infect Dis* 2008; **62**: 430-432 [PMID: 18842380 DOI: 10.1016/j.diagmicrobio.2008.07.015]
- 6 **Rossati A, Kroumova V, Bargiacchi O, Brustia D, Luigi Garavelli P**. *Elizabethkingia miricola* bacteremia in a young woman with acute alcoholic pancreatitis. *Presse Med* 2015; **44**: 1071-1072 [PMID: 26337359 DOI: 10.1016/j.lpm.2015.08.003]
- 7 **Li Y, Kawamura Y, Fujiwara N, Naka T, Liu H, Huang X, Kobayashi K, Ezaki T**. *Chryseobacterium miricola* sp. nov., a novel species isolated from condensation water of space station Mir. *Syst Appl Microbiol* 2003; **26**: 523-528 [PMID: 14666980 DOI: 10.1078/072320203770865828]
- 8 **Kim KK, Kim MK, Lim JH, Park HY, Lee ST**. Transfer of *Chryseobacterium meningosepticum* and *Chryseobacterium miricola* to *Elizabethkingia* gen. nov. as *Elizabethkingia meningoseptica* comb. nov. and *Elizabethkingia miricola* comb. nov. *Int J Syst Evol Microbiol* 2005; **55**: 1287-1293 [PMID: 15879269 DOI: 10.1099/

- ijs.0.63541-0]
- 9 **Gonzalez C**, Coolen-Allou N, Allyn J, Estève JB, Belmonte O, Allou N. [Severe sepsis and pulmonary abscess with bacteremia due to *Elizabethkingia miricola*]. *Med Mal Infect* 2016; **46**: 49-51 [PMID: 26607230 DOI: 10.1016/j.medmal.2015.10.011]
 - 10 **Jung SH**, Lee B, Mirrahimov AE, Hussain N. Septic shock caused by *Elizabethkingia meningoseptica*: a case report and review of literature. *BMJ Case Rep* 2013; **2013**: [PMID: 23559661 DOI: 10.1136/bcr-2013-009066]
 - 11 **Hoque SN**, Graham J, Kaufmann ME, Tabaqchali S. *Chryseobacterium* (*Flavobacterium*) *meningosepticum* outbreak associated with colonization of water taps in a neonatal intensive care unit. *J Hosp Infect* 2001; **47**: 188-192 [PMID: 11247678 DOI: 10.1053/jhin.2000.0908]

P- Reviewer: Simone G, Woo HH **S- Editor:** Song XX

L- Editor: A **E- Editor:** Lu YJ





Published by **Baishideng Publishing Group Inc**
7901 Stoneridge Drive, Suite 501, Pleasanton, CA 94588, USA
Telephone: +1-925-223-8242
Fax: +1-925-223-8243
E-mail: bpgoffice@wjgnet.com
Help Desk: <http://www.f6publishing.com/helpdesk>
<http://www.wjgnet.com>

