

World Journal of *Clinical Cases*

World J Clin Cases 2018 December 26; 6(16): 1073-1222





REVIEW

- 1073 Biliary endoscopic sphincterotomy: Techniques and complications
Köksal AS, Eminler AT, Parlak E

MINIREVIEWS

- 1087 Radiation exposure during image-guided endoscopic procedures: The next quality indicator for endoscopic retrograde cholangiopancreatography
Hayashi S, Takenaka M, Hosono M, Nishida T

ORIGINAL ARTICLE

Case Control Study

- 1094 Feasibility of laparoscopic total gastrectomy in overweight patients: Implications of less impact of overweight on laparoscopic versus open approach
Nakagawa M, Kojima K, Inokuchi M, Kobayashi K, Tanioka T, Okuno K, Gokita K

Retrospective Study

- 1101 Complications of newborn enterostomies
Wolf L, Gfroerer S, Fiegel H, Rolle U
- 1111 Background factors influencing postgastrectomy syndromes after various types of gastrectomy
Kinami S, Takahashi M, Urushihara T, Ikeda M, Yoshida M, Uenosono Y, Oshio A, Suzukamo Y, Terashima M, Koderä Y, Nakada K
- 1121 Safety of fecal microbiota transplantation in Chinese children: A single-center retrospective study
Zhang XY, Wang YZ, Li XL, Hu H, Liu HF, Li D, Xiao YM, Zhang T

Observational Study

- 1128 Mandatory meningococcal vaccine, and other recommended immunisations: Uptake, barriers, and facilitators among health care workers and trainees at Hajj
Badahdah AM, Alfelali M, Alqahtani AS, Alsharif S, Barasheed O, Rashid H; the Hajj Research Team

Randomized Clinical Trial

- 1136 Effect of clonidine on the cutaneous silent period during spinal anesthesia
Graf Zupcic S, Zupcic M, Duzel V, Šimurina T, Milošević M, Basic S, Vuletic V, Kapural L



- 1146 Safety of applying midazolam-ketamine-propofol sedation combination under the supervision of endoscopy nurse with patient-controlled analgesia pump in colonoscopy

Kayaaltı S, Kayaaltı Ö

CASE REPORT

- 1155 Renal aspergillosis in a liver transplant patient: A case report and review of literature

Smolovic B, Vukcevic B, Muhovic D, Ratkovic M

- 1160 Ureteral double J stent displaced into vena cava and management with laparoscopy: A case report and review of the literature

Mao XW, Xu G, Xiao JQ, Wu HF

- 1164 Combined silicosis and mixed dust pneumoconiosis with rapid progression: A case report and literature review

Yoon HY, Kim Y, Park HS, Kang CW, Ryu YJ

- 1169 Spontaneous cerebral abscess due to *Bacillus subtilis* in an immunocompetent male patient: A case report and review of literature

Tsonis I, Karamani L, Xaplanteri P, Kolonitsiou F, Zampakis P, Gatzounis G, Marangos M, Assimakopoulos SF

- 1175 Post-appendectomy pelvic abscess with extended-spectrum beta-lactamase producing *Escherichia coli*: A case report and review of literature

Tse A, Cheluvappa R, Selvendran S

- 1182 Gastric duplication cyst communicating to accessory pancreatic lobe: A case report and review of the literature

Rousek M, Kachlik D, Nikov A, Pintova J, Ryska M

- 1189 Oxygen insufflation *via* working channel in a fiberscope is a useful method: A case report and review of literature

Lee D, Baik J, Yun G, Kim E

- 1194 Primary sebaceous carcinoma of lacrimal gland: A case report and review of literature

Park H, Choi SG



- 1199** Uncommon cause of voiding dysfunction in a female patient-vaginal abscess: A case report
Yeh CC, Yang SSD, Huang SC, Wang YC
- 1202** Schwannoma originating from the recurrent laryngeal nerve in a thyroid cancer patient: A case report and review of the literature
Xu XQ, Hong T, Zheng CJ
- 1206** Posaconazole-associated severe hyperbilirubinemia in acute myeloid leukemia following chemotherapy: A case report
Song ZW, Pan YC, Huang ZC, Liu WX, Zhao RS, Jing HM, Dong F
- 1210** Chondromyxoid fibroma of the temporal bone: A case report and review of the literature
Zheng YM, Wang HX, Dong C
- 1217** Duodenal variceal bleeding secondary to idiopathic portal hypertension treated with transjugular intra-hepatic portosystemic shunt plus embolization: A case report
Xie BS, Zhong JW, Wang AJ, Zhang ZD, Zhu X, Guo GH

ABOUT COVER

Editorial Board Member of *World Journal of Clinical Cases*, Consolato M Sergi, FRCP (C), MD, PhD, Professor, Department of Lab. Medicine and Pathology, University of Alberta, Edmonton T6G 2B7, AB, Canada

AIM AND SCOPE

World Journal of Clinical Cases (*World J Clin Cases*, *WJCC*, online ISSN 2307-8960, DOI: 10.12998) is a peer-reviewed open access academic journal that aims to guide clinical practice and improve diagnostic and therapeutic skills of clinicians.

The primary task of *WJCC* is to rapidly publish high-quality Autobiography, Case Report, Clinical Case Conference (Clinicopathological Conference), Clinical Management, Diagnostic Advances, Editorial, Field of Vision, Frontier, Medical Ethics, Original Articles, Clinical Practice, Meta-Analysis, Minireviews, Review, Therapeutics Advances, and Topic Highlight, in the fields of allergy, anesthesiology, cardiac medicine, clinical genetics, clinical neurology, critical care, dentistry, dermatology, emergency medicine, endocrinology, family medicine, gastroenterology and hepatology, geriatrics and gerontology, hematology, immunology, infectious diseases, internal medicine, obstetrics and gynecology, oncology, ophthalmology, orthopedics, otolaryngology, pathology, pediatrics, peripheral vascular disease, psychiatry, radiology, rehabilitation, respiratory medicine, rheumatology, surgery, toxicology, transplantation, and urology and nephrology.

INDEXING/ABSTRACTING

World Journal of Clinical Cases (*WJCC*) is now indexed in PubMed, PubMed Central, Science Citation Index Expanded (also known as SciSearch®), and Journal Citation Reports/Science Edition. The 2018 Edition of Journal Citation Reports cites the 2017 impact factor for *WJCC* as 1.931 (5-year impact factor: N/A), ranking *WJCC* as 60 among 154 journals in Medicine, General and Internal (quartile in category Q2).

EDITORS FOR THIS ISSUE

Responsible Assistant Editor: *Xiang Li*
Responsible Electronic Editor: *Yun-XiaoJian Wu*
Proofing Editor-in-Chief: *Lian-Sheng Ma*

Responsible Science Editor: *Fang-Fang Ji*
Proofing Editorial Office Director: *Jin-Lei Wang*

NAME OF JOURNAL
World Journal of Clinical Cases

ISSN
ISSN 2307-8960 (online)

LAUNCH DATE
April 16, 2013

FREQUENCY
Semimonthly

EDITORS-IN-CHIEF
Sandro Vento, MD, Department of Internal Medicine, University of Botswana, Private Bag 00713, Gaborone, Botswana

EDITORIAL BOARD MEMBERS
All editorial board members resources online at <https://www.wjcn.net.com/2307-8960/editorialboard.htm>

EDITORIAL OFFICE
Jin-Lei Wang, Director

World Journal of Clinical Cases
Baishideng Publishing Group Inc
7901 Stoneridge Drive, Suite 501, Pleasanton, CA 94588, USA
Telephone: +1-925-2238242
Fax: +1-925-2238243
E-mail: editorialoffice@wjcn.net.com
Help Desk: <https://www.wjcn.net.com/helpdesk>
<https://www.wjcn.net.com>

PUBLISHER
Baishideng Publishing Group Inc
7901 Stoneridge Drive, Suite 501, Pleasanton, CA 94588, USA
Telephone: +1-925-2238242
Fax: +1-925-2238243
E-mail: bpgoffice@wjcn.net.com
Help Desk: <https://www.wjcn.net.com/helpdesk>
<https://www.wjcn.net.com>

PUBLICATION DATE
December 26, 2018

COPYRIGHT

© 2018 Baishideng Publishing Group Inc. Articles published by this Open Access journal are distributed under the terms of the Creative Commons Attribution Non-commercial License, which permits use, distribution, and reproduction in any medium, provided the original work is properly cited, the use is non commercial and is otherwise in compliance with the license.

SPECIAL STATEMENT

All articles published in journals owned by the Baishideng Publishing Group (BPG) represent the views and opinions of their authors, and not the views, opinions or policies of the BPG, except where otherwise explicitly indicated.

INSTRUCTIONS TO AUTHORS

<https://www.wjcn.net.com/bpg/gerinfo/204>

ONLINE SUBMISSION

<https://www.wjcn.net.com>

Ureteral double J stent displaced into vena cava and management with laparoscopy: A case report and review of the literature

Xia-Wa Mao, Gang Xu, Jia-Quan Xiao, Hui-Feng Wu

Xia-Wa Mao, Gang Xu, Jia-Quan Xiao, Hui-Feng Wu, Department of Urology, the Second Affiliated Hospital of Zhejiang University School of Medicine, Hangzhou 310009, Zhejiang Province, China

ORCID number: Xia-Wa Mao (0000-0001-9882-5366); Gang Xu (0000-0002-8837-3498); Jia-Quan Xiao (0000-0002-7311-3212); Hui-Feng Wu (0000-0001-9874-7599).

Author contributions: Mao XW designed the research; Mao XW, Xu G and Xiao JQ performed the research; Mao XW and Wu HF analyzed the data; Mao XW wrote the paper.

Supported by the Program of Medical and Health Technology Development in Zhejiang Province, No. 2016147031; and Natural Science Foundation of Zhejiang Province, No. LY14H050003.

Informed consent statement: All involved persons gave their written informed consent prior to study inclusion.

Conflict-of-interest statement: The authors declare that they have no conflicts of interest.

CARE Checklist (2016) statement: The authors have read the CARE Checklist (2016) and the manuscript was prepared and revised according to the CARE Checklist (2016).

Open-Access: This article is an open-access article which was selected by an in-house editor and fully peer-reviewed by external reviewers. It is distributed in accordance with the Creative Commons Attribution Non Commercial (CC BY-NC 4.0) license, which permits others to distribute, remix, adapt, build upon this work non-commercially, and license their derivative works on different terms, provided the original work is properly cited and the use is non-commercial. See: <http://creativecommons.org/licenses/by-nc/4.0/>

Manuscript source: Unsolicited manuscript

Corresponding author to: Xia-Wa Mao, MD, Surgeon, Department of Urology, the Second Affiliated Hospital of Zhejiang University School of Medicine, 88 Jiefang Road, Hangzhou 310009, Zhejiang Province,

China. mao_xiawa@zju.edu.cn
Telephone: +86-571-87783777
Fax: +86-571-87783777

Received: September 30, 2018
Peer-review started: September 30, 2018
First decision: October 12, 2018
Revised: October 15, 2018
Accepted: October 22, 2018
Article in press: October 22, 2018
Published online: December 26, 2018

Abstract

We reported displacement of a ureteral double J stent into the vena cava and laparoscopic management in a 69-year-old patient with a history of ureteral stent placement. Preoperative computed tomography and plain X-rays showed malpositioning of the double J stent and displacement into the inferior vena cava. The characteristics of stent misplacement precluded endovascular procedures and explorative laparoscopic surgery was performed. The intra- and postoperative periods were uneventful. Postoperative imaging demonstrated that the new double J stent was in the right position. The patient was discharged 7 d after the operation and was symptom free at the 4-mo follow-up.

Key words: Double J stent; Displacement; Inferior vena cava; Laparoscopy

© The Author(s) 2018. Published by Baishideng Publishing Group Inc. All rights reserved.

Core tip: Ureteral double J stent displacement into the vena cava is a rare complication in urology. Only six cases have been reported in the literature and all stents were removed by various methods that excluded

laparoscopy. Here, we report our experience with a case that involved laparoscopy.

Mao XW, Xu G, Xiao JQ, Wu HF. Ureteral double J stent displaced into vena cava and management with laparoscopy: a case report and review of the literature. *World J Clin Cases* 2018; 6(16): 1160-1163

URL: <https://www.wjgnet.com/2307-8960/full/v6/i16/1160.htm>

DOI: <https://dx.doi.org/10.12998/wjcc.v6.i16.1160>

INTRODUCTION

Ureteral double J stents are usually used for maintaining urine flow from the kidney to the bladder, preventing stenosis, and surgery of ureteral injuries^[1]. Traditionally, the procedure is performed under cystoscopic guidance with or without the aid of X-rays. Unavoidably, the double J stent will cause complications that include encrustation, fragmentation, distal and proximal migration, and lower urinary tract symptoms^[2]. Most of them are mild and self-limited and can be alleviated by conservative interventions. However, the double J stent is rarely displaced into the vena cava through the ureter. Stent displacement can be managed by percutaneous removal, or open surgery combined with vascular surgery^[3-8]. Here, we present a case of double J stent displacement into the vena cava and successful laparoscopic removal.

CASE REPORT

A 69-year-old patient with recurrent left flank pain and vomiting for 15 d was admitted to our hospital. He had a history of urinary stones and received extracorporeal shock wave lithotripsy for a left ureteral stone 8 and 3 years ago. Bilateral ureteral double J stents were placed due to anuria 1 d before the patient was referred to us. Postoperative X-rays demonstrated malpositioning of the left ureteral double J stent (Figure 1). Caval migration was highly suspected. Computed tomography (CT) showed that the left double J stent penetrated the bladder, then the left common iliac vein, and finally the inferior vena cava (IVC) (Figure 2). The upper end of the double J stent was at the level of the right renal vessels and not the heart, which made the case more complicated^[8].

We planned to remove the migrated catheter laparoscopically based on the following factors. First, it was likely that the catheter had migrated into the vena cava from a small vessel, indicating that it would be feasible to perform the surgery laparoscopically. Second, the surgeon had performed a large number of laparoscopic operations and had experienced several similar cases, although not entirely the same. Our surgical plan was divided into four main steps: removing the catheter, repairing the vessel, repairing

the ureter, and replacing the stent. Laparoscopic surgery was performed through three ports: optical access at a site 1 cm left of the umbilicus, 5 mm operative accesses on the lesion side, and one 10 mm access at the intersection of the umbilicus and anterior axillary line. After incising the peritoneum and reflecting the left colon, the ureter was identified. We noted by laparoscopic touch that the stent was not inside the ureter. Therefore, we opened the bladder and pulled the stent from the inside. A slight movement of one small vein near the bladder was observed. The vein, which proved to be the vena obturatoria, was thoroughly dissected and the stent was found inside the vein (Figure 3). The double J stent was removed from the vein from inside the bladder, and one Hem-o-lok clip was placed in the distal vein. Meanwhile, a minor ureteral injury was detected and repaired with 5/0 vicryl sutures. A new 6F double J stent was introduced into the ureter. The bladder was closed with 2/0 vicryl sutures. Finally, a small drain was inserted *via* the 5 mm port.

Postoperatively, the patient was started on anti-coagulation therapy for 3 d and had an uneventful recovery. Postoperative X-rays confirmed that the new double J stent was in the right position. The patient was discharged 7 d after the operation. The new double J stent was removed cystoscopically 4 wk after surgery. The patient was followed for 3 mo and 1 year after surgery, and no sequelae were found with CT and ultrasound.

DISCUSSION

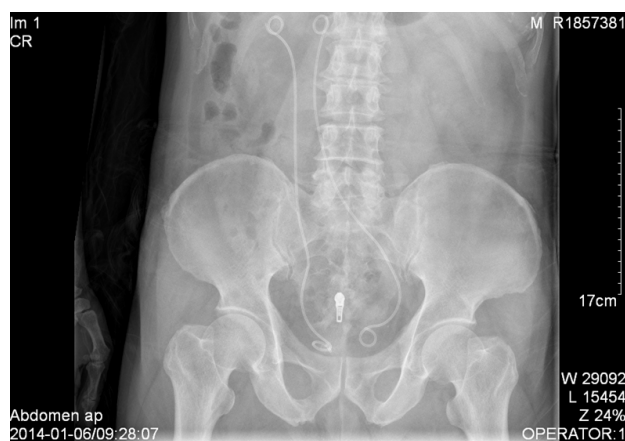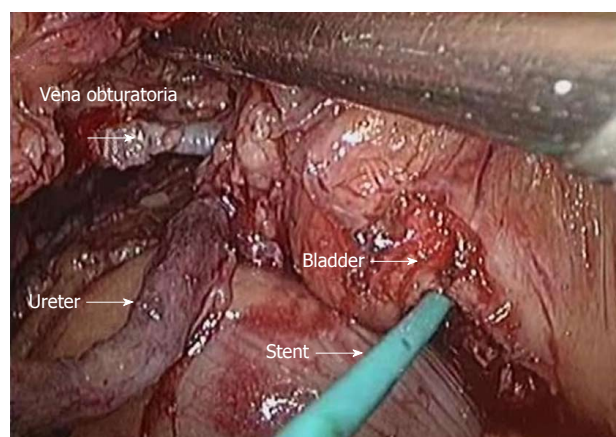
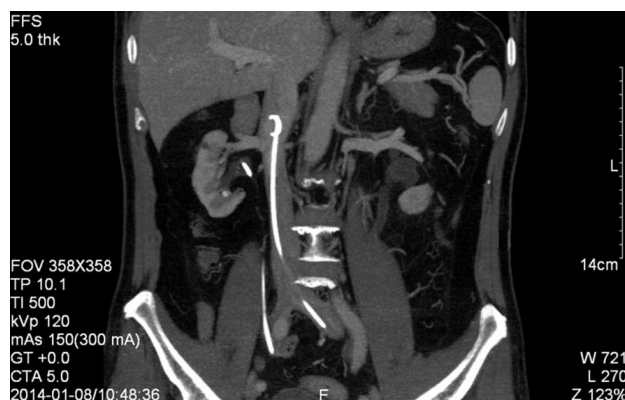Ureteral stent placement, either antegrade or retrograde, is a prevalent intervention procedure. It causes various complications, including encrustation, fracture, and migration proximally and distally. Rare complications include stent knotting and vascular migration (Table 1)^[3,6,7,9]. The presence of the stent within a ureter adjacent to a pulsating vascular structure, either a normal vessel or graft, appears to favor erosion^[10]. Michalopoulos *et al*^[4] first reported a case of intravascular migration of a stent placed intraoperatively in the right ureter that migrated into the venous circulation.

In our patient, due to ureteral twisting or fragile bladder mucosa, the surgeon might have had difficulty placing the guidewire, which possibly penetrated directly out of the lower part of the ureter, and then into the adjacent vessel. If so, this would have caused gross hematuria and poor surgical vision. Subsequently, a ureteral stent was introduced through the guidewire and ultimately displaced into the IVC. It should be noted that the procedure has to be performed under X-ray monitoring, which may detect such a complication. Accordingly, it would be possible for the surgeon to correct it during the operation. However, it was unusual in our case that displacement into the circulation did not cause severe bleeding but rather moderate gross hematuria, so it appeared that the procedure

Table 1 Published literature on the management of double J stent displacement into the inferior vena cava

First author	Year of publication	No. of patients	Clinical manifestation	Management	Upper end of stent	Primary disease
Michalopoulos <i>et al</i> ^[4]	2002	1	Pulmonary thromboembolism	Percutaneous removal through right femoral vein	IVC	Renal stone operation
Garrido <i>et al</i> ^[5]	2008	1	Loin pain and fever	Removal through percutaneous nephrostomy	IVC	Gynecologic surgery
Ioannou <i>et al</i> ^[6]	2009	1	Microscopic hematuria	Open surgery through left retroperitoneal approach	IVC	Obstructive pyelonephritis
Falahatkar <i>et al</i> ^[3]	2012	1	Urinary incontinence	Percutaneous removal through left femoral vein	Right atrium	Hysterectomy
Sabnis <i>et al</i> ^[7]	2013	1	History of ureteroscopy	Exploration through Gibson's incision	Right atrium	Ureteral stone operation
Hastaoglu <i>et al</i> ^[8]	2014	1	Hematuria	Open surgery under cardiopulmonary bypass	Right ventricle	Ureteral stone operation

IVC: Inferior vena cava.

**Figure 1** Plain kidney, ureter, and bladder X-ray showing the improperly positioned left ureteral stent.**Figure 3** Surgical video screen capture demonstrating the corresponding anatomy.**Figure 2** Computed tomography reconstruction of the abdomen confirmed the left ureteral stent in the inferior vena cava.

was uneventful. The diagnosis of stent displacement can be established by postoperative plain abdominal radiography and CT imaging.

Endovascular management of arterioureteral fistula has been previously described^[11-14]. It seems to be an ideal treatment in such a situation. Nevertheless, to

make it clear, we decided to perform laparoscopic exploration since the lower end of the stent was still inside the bladder. Furthermore, the bladder should be explored to confirm its integrity. As stent migration did not cause severe bleeding, we believed that the operation could be attempted by laparoscopy. During the procedure, we observed that the stent went into the left common iliac vein through the vena obturatoria, which is a small vein. Undoubtedly, if the stent had penetrated directly into the adjacent major vein, open surgery would have been more feasible and safer.

In conclusion, the displacement of ureteral stents into the vascular system is a rare complication in urology. The key to prevention includes scopic guidance with X-ray monitoring, a high degree of suspicion, and early intervention. Treatment options include endovascular, percutaneous or open surgery, as well as laparoscopy.

ARTICLE HIGHLIGHTS

Case characteristics

A rare case of ureteral stent displacement into the vena cava.

Clinical diagnosis

After admission, kidney, ureter, bladder X-ray (KUB) combined with computed tomography (CT) scan confirmed that the left ureteral stent was in the inferior vena cava (IVC).

Differential diagnosis

Theoretically, faulty ureteral stent positioning or placement outside of the ureter is not a rare complication. However, stent displacement into the IVC makes the case more complex and dangerous. CT scans can confirm the diagnosis.

Laboratory diagnosis

The laboratory tests showed normal plasma levels of hemoglobin (115 g/L, normal range 110-150 g/L) and minor gross hematuria (RBC³⁺).

Imaging diagnosis

CT reconstruction combined with KUB showed the left ureteral stent in the IVC. The upper pole of the stent was at the kidney level and the lower pole was inside the bladder.

Pathological diagnosis

Pathological examination was not necessary in this case.

Treatment

Based on previous experiences, we performed the operation laparoscopically and removed the stent successfully.

Term explanation

Ureteral stent displacement is defined as the stent not being in the right position but somewhere outside the ureter. Typically, the stent may only be placed in the nearby fat tissue and does not cause severe complications and sequelae.

Experiences and lessons

The ureteral stent has to be placed under X-ray guidance. Displacement of the stent should be suspected when unusual or unexpected bleeding occurs after endoscopic surgery.

REFERENCES

- 1 **Brotherhood H**, Lange D, Chew BH. Advances in ureteral stents. *Transl Androl Urol* 2014; **3**: 314-319 [PMID: 26816785 DOI: 10.3978/j.issn.2223-4683.2014.06.06]
- 2 **Ahallal Y**, Khallouk A, El Fassi MJ, Farih MH. Risk factor analysis and management of ureteral double-j stent complications. *Rev Urol* 2010; **12**: e147-e151 [PMID: 20811552]
- 3 **Falahatkar S**, Hemmati H, Gholamjani Moghaddam K. Intracaval migration: an uncommon complication of ureteral Double-J stent placement. *J Endourol* 2012; **26**: 119-121 [PMID: 22192115 DOI: 10.1089/end.2011.0469]
- 4 **Michalopoulos AS**, Tzoufi MJ, Theodorakis G, Mentzelopoulos SD. Acute postoperative pulmonary thromboembolism as a result of intravascular migration of a pigtail ureteral stent. *Anesth Analg* 2002; **95**: 1185-1188 [PMID: 12401589 DOI: 10.1097/0000539-200211000-00011]
- 5 **Garrido Abad P**, Fernández Arjona M, Fernández González I, Santos Arrontes D, Pereira Sanz I. [Proximal migration of a Double J catheter: case report and review of the literature]. *Arch Esp Urol* 2008; **61**: 428-431 [PMID: 18581681 DOI: 10.4321/S0004-06142008000300010]
- 6 **Ioannou CV**, Velegarakis J, Kostas T, Georgakarakos E, Touloupakis E, Anezinis P, Katsamouris AN. Caval migration of a ureteral J-stent after simultaneous ureter and iliac vein perforation during its placement for obstructive pyelonephritis. *Int Angiol* 2009; **28**: 421-424 [PMID: 19935599]
- 7 **Sabnis RB**, Ganpule AP, Ganpule SA. Migration of double J stent into the inferior vena cava and the right atrium. *Indian J Urol* 2013; **29**: 353-354 [PMID: 24235801 DOI: 10.4103/0970-1591.120125]
- 8 **Hastaoglu IO**, Tokoz H, Kavlak E, Bilgen F. Double J ureteral stent displaced through the right ventricle. *Interact Cardiovasc Thorac Surg* 2014; **18**: 853-854 [PMID: 24632423 DOI: 10.1093/icvts/ivu037]
- 9 **Sighinolfi MC**, De Stefani S, Micali S, Mofferdin A, Baisi B, Celia A, Bianchi G. A knotted multi-length ureteral stent: a rare complication. *Urol Res* 2005; **33**: 70-71 [PMID: 15625611 DOI: 10.1007/s00240-004-0441-7]
- 10 **Bergqvist D**, Pärsson H, Sherif A. Arterio-ureteral fistula--a systematic review. *Eur J Vasc Endovasc Surg* 2001; **22**: 191-196 [PMID: 11506509 DOI: 10.1053/ejvs.2001.1432]
- 11 **Asham EH**, Walsh M, Adiseshiah M. An unusual case of haematuria treated by endoluminal repair. *Eur J Vasc Endovasc Surg* 1999; **17**: 89-90 [PMID: 10071625 DOI: 10.1053/ejvs.1998.0673]
- 12 **el Khader K**. [Complications of double J ureteral stents]. *J Urol (Paris)* 1996; **102**: 173-175 [PMID: 9091568]
- 13 **Gibbons M**, O'Donnell S, Lukens M, Meglin A, Costabile RA. Treatment of a ureteroiliac artery fistula with an intraluminal endovascular graft. *J Urol* 1998; **159**: 2083-2084 [PMID: 9598529 DOI: 10.1016/S0022-5347(01)63260-9]
- 14 **Vandersteen DR**, Saxon RR, Fuchs E, Keller FS, Taylor LM Jr, Barry JM. Diagnosis and management of ureteroiliac artery fistula: value of provocative arteriography followed by common iliac artery embolization and extraanatomic arterial bypass grafting. *J Urol* 1997; **158**: 754-758 [PMID: 9258074 DOI: 10.1097/00005392-199709000-00015]

P- Reviewer: Desai DJ, Mazaris E **S- Editor:** Wang JL

L- Editor: Filipodia **E- Editor:** Wu YXJ





Published by **Baishideng Publishing Group Inc**
7901 Stoneridge Drive, Suite 501, Pleasanton, CA 94588, USA
Telephone: +1-925-223-8242
Fax: +1-925-223-8243
E-mail: bpgoffice@wjgnet.com
Help Desk: <https://www.f6publishing.com/helpdesk>
<https://www.wjgnet.com>

