

# World Journal of *Clinical Cases*

*World J Clin Cases* 2018 February 16; 6(2): 11-19





**CASE REPORT**

- 11 Fatal fulminant herpes simplex hepatitis following surgery in an adult

*Yokoi Y, Kaneko T, Sawayanagi T, Takano Y, Watahiki Y*

**ABOUT COVER**

Editorial Board Member of *World Journal of Clinical Cases*, Devinder M Thappa, MD, Head, Professor, Department of Dermatology and STD, Jawaharlal Institute of Postgraduate Medical Education and Research (JIPMER), Pondicherry 605006, India

**AIM AND SCOPE**

*World Journal of Clinical Cases* (*World J Clin Cases*, *WJCC*, online ISSN 2307-8960, DOI: 10.12998) is a peer-reviewed open access academic journal that aims to guide clinical practice and improve diagnostic and therapeutic skills of clinicians.

The primary task of *WJCC* is to rapidly publish high-quality Autobiography, Case Report, Clinical Case Conference (Clinicopathological Conference), Clinical Management, Diagnostic Advances, Editorial, Field of Vision, Frontier, Medical Ethics, Original Articles, Clinical Practice, Meta-Analysis, Minireviews, Review, Therapeutics Advances, and Topic Highlight, in the fields of allergy, anesthesiology, cardiac medicine, clinical genetics, clinical neurology, critical care, dentistry, dermatology, emergency medicine, endocrinology, family medicine, gastroenterology and hepatology, geriatrics and gerontology, hematology, immunology, infectious diseases, internal medicine, obstetrics and gynecology, oncology, ophthalmology, orthopedics, otolaryngology, pathology, pediatrics, peripheral vascular disease, psychiatry, radiology, rehabilitation, respiratory medicine, rheumatology, surgery, toxicology, transplantation, and urology and nephrology.

**INDEXING/ABSTRACTING**

*World Journal of Clinical Cases* is now indexed in PubMed, PubMed Central, Science Citation Index Expanded (also known as SciSearch®), and Journal Citation Reports/Science Edition.

**EDITORS FOR THIS ISSUE**

Responsible Assistant Editor: *Xiang Li*  
Responsible Electronic Editor: *Rui-Fang Li*  
Proofing Editor-in-Chief: *Lian-Sheng Ma*

Responsible Science Editor: *Li-Jun Cui*  
Proofing Editorial Office Director: *Xiu-Xia Song*

**NAME OF JOURNAL**

*World Journal of Clinical Cases*

**ISSN**

ISSN 2307-8960 (online)

**LAUNCH DATE**

April 16, 2013

**FREQUENCY**

Monthly

**EDITORS-IN-CHIEF**

**Giuseppe Di Lorenzo, MD, PhD, Professor**, Genitourinary Cancer Section and Rare-Cancer Center, University Federico II of Napoli, Via Sergio Pansini, 5 Ed. 1, 80131, Naples, Italy

**Jan Jacques Michiels, MD, PhD, Professor**, Primary Care, Medical Diagnostic Center Rijnmond Rotterdam, Bloodcoagulation, Internal and Vascular Medicine, Erasmus University Medical Center, Rotterdam, Goodheart Institute and Foundation, Erasmus Tower, Veennos 13, 3069 AT, Erasmus City, Rotterdam, The Netherlands

**Sandro Vento, MD**, Department of Internal Medicine, University of Botswana, Private Bag 00713, Gaborone, Botswana

**Shuhei Yoshida, MD, PhD**, Division of Gastroenterology, Beth Israel Deaconess Medical Center, Dana 509, Harvard Medical School, 330 Brookline Ave, Boston, MA 02215, United States

**EDITORIAL BOARD MEMBERS**

All editorial board members resources online at <http://www.wjnet.com/2307-8960/editorialboard.htm>

**EDITORIAL OFFICE**

Xiu-Xia Song, Director  
*World Journal of Clinical Cases*  
Baishideng Publishing Group Inc  
7901 Stoneridge Drive, Suite 501, Pleasanton, CA 94588, USA  
Telephone: +1-925-2238242  
Fax: +1-925-2238243  
E-mail: [editorialoffice@wjnet.com](mailto:editorialoffice@wjnet.com)  
Help Desk: <http://www.f6publishing.com/helpdesk>  
<http://www.wjnet.com>

**PUBLISHER**

Baishideng Publishing Group Inc  
7901 Stoneridge Drive,  
Suite 501, Pleasanton, CA 94588, USA  
Telephone: +1-925-2238242  
Fax: +1-925-2238243  
E-mail: [bpgoffice@wjnet.com](mailto:bpgoffice@wjnet.com)

Help Desk: <http://www.f6publishing.com/helpdesk>  
<http://www.wjnet.com>

**PUBLICATION DATE**

February 16, 2018

**COPYRIGHT**

© 2018 Baishideng Publishing Group Inc. Articles published by this Open Access journal are distributed under the terms of the Creative Commons Attribution Non-commercial License, which permits use, distribution, and reproduction in any medium, provided the original work is properly cited, the use is non commercial and is otherwise in compliance with the license.

**SPECIAL STATEMENT**

All articles published in journals owned by the Baishideng Publishing Group (BPG) represent the views and opinions of their authors, and not the views, opinions or policies of the BPG, except where otherwise explicitly indicated.

**INSTRUCTIONS TO AUTHORS**

<http://www.wjnet.com/bpg/gerinfo/204>

**ONLINE SUBMISSION**

<http://www.f6publishing.com>

## Fatal fulminant herpes simplex hepatitis following surgery in an adult

Yoshihiro Yokoi, Takeshi Kaneko, Tomoki Sawayanagi, Yasuo Takano, Yoichi Watahiki

Yoshihiro Yokoi, Takeshi Kaneko, Tomoki Sawayanagi, Yoichi Watahiki, Department of Surgery, Shinshiro Municipal Hospital, Shinshiro 441-1387, Japan

Yasuo Takano, Department of Pathology, Shinshiro Municipal Hospital, Shinshiro 441-1387, Japan

ORCID number: Yoshihiro Yokoi (0000-0001-9476-8085); Takeshi Kaneko (0000-0002-2263-1562); Tomoki Sawayanagi (0000-0003-1311-742X); Yasuo Takano (0000-0001-6300-6248); Yoichi Watahiki (0000-0001-5035-1413).

**Author contributions:** Yokoi Y, Kaneko T, Sawayanagi T and Watahiki Y participated in the diagnosis and management of this case; Takano Y provided a critical and valuable discussion on the histopathologic study.

**Informed consent statement:** Informed consent to publish was obtained from the family of the patient.

**Conflict-of-interest statement:** The authors state that they have no conflict of interest.

**Open-Access:** This article is an open-access article which was selected by an in-house editor and fully peer-reviewed by external reviewers. It is distributed in accordance with the Creative Commons Attribution Non Commercial (CC BY-NC 4.0) license, which permits others to distribute, remix, adapt, build upon this work non-commercially, and license their derivative works on different terms, provided the original work is properly cited and the use is non-commercial. See: <http://creativecommons.org/licenses/by-nc/4.0/>

**Manuscript source:** Unsolicited manuscript

Correspondence to: Yoshihiro Yokoi, MD, Doctor, Department of Surgery, Shinshiro Municipal Hospital, 32-1 Kitahata, Shinshiro 441-1387, Japan. [y.yokoi@hospital.shinshiro.aichi.jp](mailto:y.yokoi@hospital.shinshiro.aichi.jp)  
Telephone: +81-536-222171  
Fax: +81-536-222850

Received: November 4, 2017

Peer-review started: November 4, 2017

First decision: November 30, 2017

Revised: December 15, 2017

Accepted: January 16, 2018

Article in press: January 16, 2018

Published online: February 16, 2018

### Abstract

We present a case of a healthy 72-year-old man with herpes simplex hepatitis (HSVH) development soon after ordinary surgery for biliary stones. A sudden onset of hepatitis associated with high fever and leukopenia emerged on postoperative day 5, followed by a rapid and lethal course (died on day 9), despite an acyclovir therapy on day 8. Postmortem liver biopsy revealed positive immunostaining for herpes simplex virus (HSV) type-1. The serum tests (available after the death) were negative for anti-HSV immunoglobulins, but positive for HSV DNA. A review of 15 cases of postsurgical HSVH along with 42 cases of non-surgical HSH showed that (1): A wide spectrum of surgical procedures was involved; and (2): High mortality (87%) associated with lower rates of ante-mortem diagnosis (20%) and acyclovir treatment (20%). Due to the difficulty in diagnosis and lethal nature, an early clinical suspicion and prompt empirical anti-viral intervention are imperative for postsurgical hepatitis with undetermined etiology, characterized by fever and leucopenia.

**Key words:** Herpes simplex virus; Fulminant hepatitis; Postsurgical; Adult; Acyclovir

© The Author(s) 2018. Published by Baishideng Publishing Group Inc. All rights reserved.

**Core tip:** Fatal fulminant herpetic hepatitis developed in a 72-year-old healthy man following ordinary surgery for biliary stones. A sudden onset of hepatitis associated with high fever and leukopenia emerged on postoperative day 5, followed by a rapid and lethal course (died on day 9), despite an acyclovir treatment on day 8. A literature review showed that (1): A wide



spectrum of surgical procedures is involved; and (2): High mortality (87%) associated with low rates of ante-mortem diagnosis (20%) and acyclovir treatment (20%). An early clinical suspension and prompt empirical anti-viral intervention are imperative for postsurgical hepatitis with undetermined etiology, characterized by fever and leucopenia.

Yokoi Y, Kaneko T, Sawayanagi T, Takano Y, Watahiki Y. Fatal fulminant herpes simplex hepatitis following surgery in an adult. *World J Clin Cases* 2018; 6(2): 11-19 Available from: URL: <http://www.wjgnet.com/2307-8960/full/v6/i2/11.htm> DOI: <http://dx.doi.org/10.12998/wjcc.v6.i2.11>

## INTRODUCTION

Acute hepatitis represents a rare complication of herpes simplex virus (HSV) infection in adults and usually occurs in association with compromised cellular immunity<sup>[1]</sup>. However, the HSV hepatitis (HSVH) can occur in apparently healthy patients as well, and often cause fulminant hepatic failure with high mortality more than 70%<sup>[2-32]</sup>. Although the exact pathogenesis of HSVH in immunocompetent patients is unknown, several mechanisms are postulated including a large HSV inoculum at the time of initial infection that overcomes immunological defenses, an occult impairment in cellular immunity, reactivation of a latent virus in association with reinfection by a second strain of the HSV, and heterogeneity of the virus as a result of many atypical strains<sup>[12]</sup>. Because of a wide clinical spectrum and rarity, the HSVH needs further investigation for its etiology and pathogenesis. We here presented a previously healthy and immunocompetent man who ran lethal course due to HSVH following surgical therapy.

## CASE REPORT

A 72-year-old Japanese male was admitted to the hospital with a 1-wk history of fever and epigastric pain. The patient's past history was negative for chronic disease, excessive use of alcohol, and corticosteroid treatment. He was in healthy condition with body mass index of 20, but had smoking habit for 50 years. An endoscopic biliary stent and percutaneous trans-hepatic gallbladder drainage (PTGBD) were performed under the diagnosis of biliary and gallbladder stones, respectively. His symptom was rapidly resolved. *Escherichia coli* was grown from the bile culture.

After quitting smoking for 1 mo at home, he underwent open cholecystectomy and choledocholithotomy followed by two day course of antibiotics. Neither the patient nor his family had recent history of flu-like symptoms. The laboratory data before surgery showed mild anemia (hemoglobin 11.1 g/dL) and undernutrition (albumin 3.4 g/dL), but did not provide evidences of organ dysfunction and systemic inflammation or infection. His

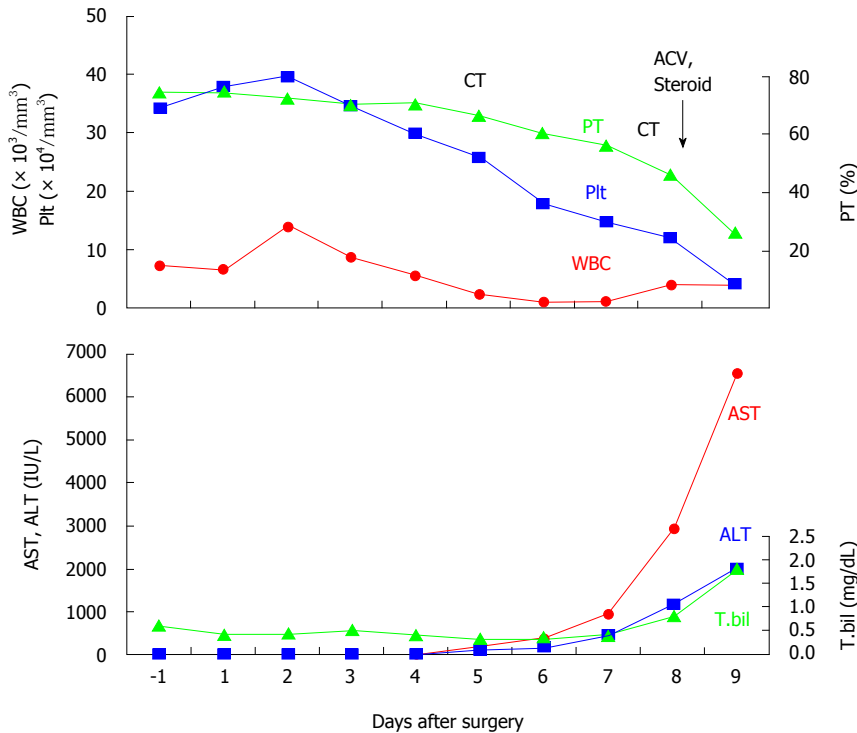
body mass index was 20.3, and cell counts of leukocytes, lymphocytes, and platelets were unremarkable. No mucocutaneous lesions were noticed anywhere including PTGBD site. The clinical course after surgery was summarized in Figure 1. On day 5 following uneventful postoperative course, he developed diarrhea and became febrile with sudden onset of leucopenia ( $2600/\text{mm}^3$ ) and elevation of aspartate aminotransferase (AST) and alanine aminotransferase (ALT). Hepatitis B virus (HBV) surface antigen and hepatitis C virus (HCV) antibody were negative. Bacterial cultures including blood and urine were unrevealing. A contrast-enhanced CT (CECT) denied the hepatic circulatory disproportions, biliary congestion, and abdominal abscess formation. No drugs had been treated since two day course of postoperative antibiotic coverage. On day 8, the patient showed a rapid elevation of liver aminotransferase without alteration of cholestasis (AST: 2946 IU/L, ALT: 1190 IU/L, total bilirubin: 1.0 mg/dL) as well as coagulation disorder (INR: 2.0, D-dimer: 155.4 mg/dL, platelets:  $8.3/\text{mm}^3$ ) (Figure 1). After having excluded a pharmacological etiology on the basis of a detailed examination of the patient's medical records, the viral and bacterial screening was repeated and empiric therapy with acyclovir (ACV) intravenous injection (10 mg/kg, every eight hours) was initiated. Methylprednisone (1 g/d), thrombomodulin, and transfusion of fresh frozen plasma and platelets were also treated. Late on this day, the patient developed a tremor and impaired consciousness, possibly caused by encephalopathy. A repeated CECT showed heterogeneous contrast distribution and a mottled liver without any abscess formation again. The patient developed hypotension and deep coma, and succumbed on day 9.

Postmortem liver biopsy revealed diffuse necrosis and loss of normal architecture with characteristic findings of intranuclear inclusion (Figure 2A and B). Immunostaining was positive for HSV-1 (Figure 2C), but not for HSV-2 and cytomegalovirus (CMV). Molecular analysis by PCR of liver tissues was negative for CMV infection.

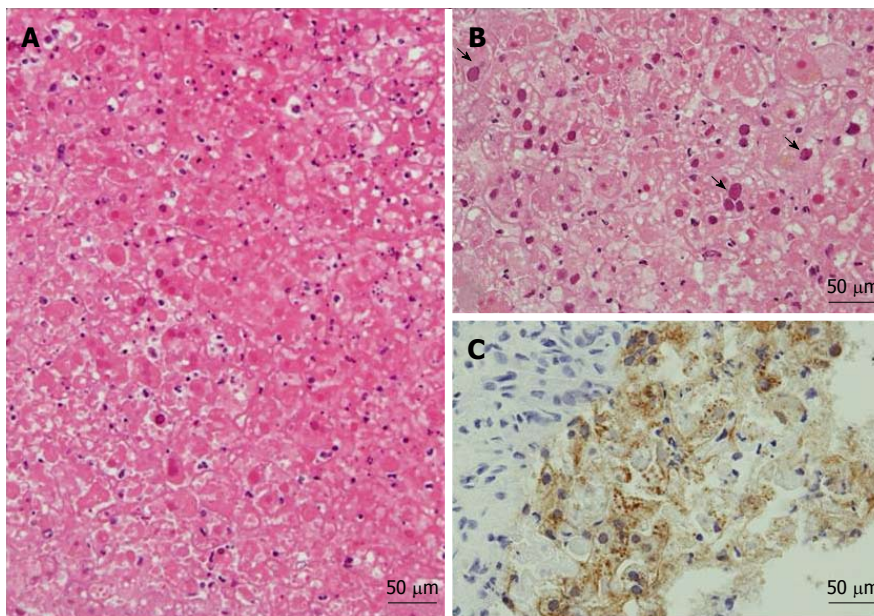
The results of serological tests that were available after the patient's death were as follows; negative for Hepatitis A IgM, Hepatitis B core IgM, Epstein Barr Virus IgM, and CMV IgG, HSV IgM and IgG, but positive for CMV IgM. Serum PCR was positive for HSV DNA, but HCV- and Hepatitis E Virus-RNA were undetectable.

## Literature review

A MEDLINE search using "fulminant hepatitis", "herpes", and "adult" as key words, and cross references from the reports found resulted in fourteen cases that seemed to be postsurgical HSVH (Table 1). These cases and the present case are summarized in Table 1. The median age was 58 years (15-93 years) with no gender differences. The nationality was United States ( $n = 8$ ) and Japan ( $n = 2$ ), followed by Canada, France, and Italy (each one). The predisposing factors associated with HSV infection included cancer ( $n = 5$ ), Hodgkin's disease ( $n = 1$ ), and immunosuppressive treatment ( $n = 4$ ). The operation was variable, pancreato-biliary ( $n = 5$ ),



**Figure 1 Clinical summary of the patient with herpes simplex hepatitis.** Fever and diarrhea emerged accompanied with rapid elevation of liver transaminase and decrease in the numbers of leukocyte and platelets on postoperative day 5. Liver dysfunction was characterized by marked elevation of transaminase levels (aspartate aminotransferase > alanine aminotransferase) with mild increase of total bilirubin levels (Anicteric hepatitis). In upper panel, prothrombin time, platelet count, and white blood cell count were indicated as green-, blue-, and red-line, respectively. In lower panel, the levels of AST, ALT, and total bilirubin, were indicated as red-, blue-, and green-line, respectively. AST: Aspartate aminotransferase; ALT: Alanine aminotransferase; ACV: Acyclovir; CT: Computed tomography; PT: Prothrombin time; T.bil: Total bilirubin.



**Figure 2 Histology of postmortem needle biopsies of the liver.** A: Massive hemorrhagic necrosis with minimum inflammatory infiltrates (hematoxylin-eosin stain; original magnification, 200  $\times$ ); B: Viral inclusions (arrow) scattered in infected hepatocytes (hematoxylin-eosin stain; original magnification, 200  $\times$ ); C: Immunostaining for herpes simplex virus type 1 (original magnification, 200  $\times$ ).

neurologic- ( $n = 4$ ) with postoperative glucocorticoids ( $n = 3$ ), gynecologic- ( $n = 2$ ), urological- ( $n = 1$ ), oral- ( $n = 1$ ), cardiovascular-surgery with glucocorticoids ( $n = 1$ ), splenectomy ( $n = 1$ ), and thymectomy ( $n = 1$ ). The involved diseases were benign nature ( $n = 10$ )

and malignancy ( $n = 5$ ). The postulated transmission was per-esophageal ( $n = 1$ ), genital tract ( $n = 2$ ), and unknown ( $n = 12$ ). As clinical manifestation, high fever was uniform (100%) and digestive disorders including nausea, vomiting and diarrhea ( $n = 6$ ), with rare

**Table 1** Reported cases of herpes simplex virus hepatitis in patients underwent non-transplant surgical procedures

| No. authors (year), (reference)        | Age (yr), sex/ races or nationality | Surgical procedures (diseases)/ transmission pathway                                               | Manifestation (days after surgery )/ herpetiform lesions                           | Laboratory data Leucocytes (/mm <sup>3</sup> ), Platelets (× 10 <sup>4</sup> /mm <sup>3</sup> ), AST/ALT (U/L), TB (mg/dL). Coagulopathy, encephalopathy | HSV serology (IgM/ IgG), HSV type, HSV PCR   | Ante-mortem diagnosis/ methods              | Treatment/ outcome (survival time after surgery, time after onset of liver dysfunction) |
|----------------------------------------|-------------------------------------|----------------------------------------------------------------------------------------------------|------------------------------------------------------------------------------------|----------------------------------------------------------------------------------------------------------------------------------------------------------|----------------------------------------------|---------------------------------------------|-----------------------------------------------------------------------------------------|
| 1. Douglas (1977) <sup>[53]</sup>      | 17, M/ United States                | Splenectomy, liver biopsy, Ln excision (remission of Hodgkin's disease)/ND                         | Fever (day 3), vomiting and diarrhea (day 4), liver dysfunction (day 5)/ none      | ND, ND, 8700/ND, ND                                                                                                                                      | ND/ND, ND, ND                                | No/ autopsy                                 | Supportive/ died (11 d, 6 d)                                                            |
| 2. Marrie (1982) <sup>[54]</sup>       | 28, M/ white, Canada                | Drainage, steroids (Brain stem injury)/ ND                                                         | Fever(12 HD)/ tongue, palate (20HD, 6 pod)                                         | ND, ND, 9000/7000, ND. Encephalopathy                                                                                                                    | ND/ND, HSV-1, ND                             | No/liver biopsy                             | Spontaneously improved                                                                  |
| 3. Williams (1985) <sup>[55]</sup>     | 57, M/ United States                | Aorto-coronary bypass, PSL (postcardiotomy syndrome)/esophagitis                                   | Nausea, weakness, epigastric discomfort, liver dysfunction (day 8)/ none           | ND, ND, 10050/4905, ND. Coagulopathy                                                                                                                     | ND/ND, HSV, ND                               | No/ autopsy                                 | Supportive/ died (10 d, 2 d)                                                            |
| 4. Fisher (1985) <sup>[56]</sup>       | 62, M/ United States                | Transperitoneal ureterolithotomy and cholecystectomy (ureteral obstruction and cholelithiasis)/ ND | Fever (day 3), vomiting (day 6), diarrhea (day 9), liver dysfunction (day 9)/ none | 5600, 8.1, > 500/ ND, 1.2, Coagulopathy, Encephalopathy                                                                                                  | ND/ND, HSV-1, ND                             | No/ autopsy                                 | Supportive/ died (14 d, 5 d)                                                            |
| 5-7, Goodman (1986) <sup>[8]</sup>     | 81, F/ United States                | Gastrectomy (stomach cancer)/ ND                                                                   | Fever (day 8)/ ND                                                                  | ND                                                                                                                                                       | ND/ND, ND, ND                                | No/ autopsy                                 | Supportive/ died (ND, 6 d)                                                              |
|                                        | 93, F/ United States                | Biliary bypass (bile duct cancer)/ ND                                                              | ND/ ND                                                                             | ND                                                                                                                                                       | ND/ND, ND, ND                                | No/ autopsy                                 | Supportive/ died (ND, 16 d)                                                             |
|                                        | 59, M/ United States                | PD (bile duct cancer ) stormy course /ND                                                           | ND/ ND                                                                             | ND                                                                                                                                                       | ND/ND, ND, ND                                | No/ autopsy                                 | Supportive/ died (ND, 30 d) <sup>2</sup>                                                |
| 8. Katz (1994) <sup>[57]</sup>         | 76, M/ United States                | Hemimandibulectomy, radical neck, and tracheotomy (plasmacytoma)/ND                                | Fever (day 6), diarrhea (day 9), liver dysfunction (day 11)/ none                  | 10100, ND, 7460/2970, ND. Coagulopathy, Encephalopathy                                                                                                   | ND/ND, ND, ND                                | No/ autopsy                                 | Supportive/ died (15 d, 4 d)                                                            |
| 9. Kaufman (1997) <sup>[58]</sup>      | 66, M/ United States                | Tumor excision, intraoperative PSL (meningioma)/ ND                                                | Fever (day 14), liver dysfunction (day 20), lethargic (day 20)/ mo                 | 4800, 2, 10340/ND, 1.9. Coagulopathy, Encephalopathy                                                                                                     | ND/ND, HSV-1, ND                             | No/autopsy                                  | Supportive/ died (21 d, 1 d)                                                            |
| 10. Price (2001) <sup>[59]</sup>       | Nulliparous/ United States          | Laparoscopy, hysteroscopy (tubal infertility)/genital tract                                        | Fever, nausea, abd pain, vaginal burning (day 3) /none                             | 900, ND, ND/ND, ND. Coagulopathy                                                                                                                         | -/-, HSV-1, ND                               | No/autopsy                                  | Supportive/ died (9 days, 6 d)                                                          |
| 11. Kohno (2001) <sup>[40]</sup>       | 58, M/ Japanese                     | Craniotomy (hypertensive cerebral hemorrhage)/ ND                                                  | Liver dysfunction (day 7)/none                                                     | 11100, 9.3, 10956/5327, 3.5. Coagulopathy, Encephalopathy                                                                                                | ND/ND, HSV-2, ND                             | No/autopsy                                  | Supportive/ died (16 d, 9 d)                                                            |
| 12. Ichai (2005) <sup>[20]</sup>       | 15 F/ France                        | Craniotomy (brain tumor) , PSL/ ND                                                                 | Fever (day 9), Liver dysfunction (day 12)/ none                                    | 9000, ND, 5000/ 4500, ND                                                                                                                                 | + /+, HSV-2, PCR positive                    | Yes/serology, explanted liver culture       | LT/ died (CR I yr)                                                                      |
| 13. Biancofiore (2007) <sup>[41]</sup> | 25, M/ Italy                        | Thymectomy (myasthenia gravis)/ ND                                                                 | Fever (day 2), liver dysfunction (day 10)/                                         | 7820, 3.8, 15000/6818, 2.1. Encephalopathy                                                                                                               | -/-, HSV-1, PCR positive                     | Yes/PCR (urine, blood, cerebrospinal fluid) | ACV (day 10) , LT (d 12)/died (12 d, 9 d after LT)                                      |
| 14. Chaudhary (2017) <sup>[42]</sup>   | 48 F/ Hispanic, United States       | Repair of vaginal cuff (Vaginal cuff dehiscence/ trans-vaginal                                     | liver dysfunction (day 1)/ vaginal ulcers                                          | ND, ND, 20692/63, 8.5. Encephalopathy                                                                                                                    | +/-, HSV-2, PCR (serum, cerebrospinal fluid) | Yes/ vaginal ulcers, serology, PCR          | ACV (day 4), foscarnet (day 10)/ survived                                               |
| 15. Present case                       | 72, M/ Japanese                     | cholecystectomy and choledocholithotomy (biliary stone)/ ND                                        | Fever (day 5), diarrhea (day 5), liver dysfunction (day 5)/ none                   | 1200, 4.3, 6557/2039, 2.0. Coagulopathy, Encephalopathy                                                                                                  | -/-, HSV-1, ND                               | No/ autopsyr                                | ACV (day 8)/ died (9 d, 4 d)                                                            |

|         |                                                                                                                                                                                                                         |                                                                                                                                                                                              |                                                                                                                                                                                                                                           |                                                                                                                                                                                                              |                                                                                                                                  |                                                                                                                                                                                                                                                                                                                                                                                                  |
|---------|-------------------------------------------------------------------------------------------------------------------------------------------------------------------------------------------------------------------------|----------------------------------------------------------------------------------------------------------------------------------------------------------------------------------------------|-------------------------------------------------------------------------------------------------------------------------------------------------------------------------------------------------------------------------------------------|--------------------------------------------------------------------------------------------------------------------------------------------------------------------------------------------------------------|----------------------------------------------------------------------------------------------------------------------------------|--------------------------------------------------------------------------------------------------------------------------------------------------------------------------------------------------------------------------------------------------------------------------------------------------------------------------------------------------------------------------------------------------|
| Summary | 58 yr (15-93)/<br>Male ( <i>n</i> = 8),<br>United States<br>( <i>n</i> = 10), Japan ( <i>n</i><br>= 2), Canada ( <i>n</i> =<br>5), France ( <i>n</i> = 2),<br>trans-esophagus ( <i>n</i> =<br>1), Italy ( <i>n</i> = 1) | Malignancy ( <i>n</i> = 5),<br>benign ( <i>n</i> = 10),<br>Immunosuppressive<br>status or treatment ( <i>n</i> =<br>1) surgical wound ( <i>n</i> =<br>1), trans-esophagus ( <i>n</i> =<br>1) | Fever: ( <i>n</i> = 15),<br>day 4.5 (day<br>1-14),<br>Digestive<br>symptoms ( <i>n</i> =<br>6): day 7 (day<br>4-9),<br>Liver<br>dysfunction ( <i>n</i> =<br>15) day 8.5 (day<br>1-20)/<br>Herpetiform<br>lesions: present<br>(3/11 cases) | Leukocytes: 3.905<br>(900-10100),<br>Plts: 4.3 (2-8.1),<br>AST/ALT: 10.340<br>(5000-20692)/5116<br>(2970-7000),<br>TB: 2.1 (2-8.5).<br>Coagulopathy<br>( <i>n</i> = 8),<br>Encephalopathy<br>( <i>n</i> = 7) | IgM +/- (2/3<br>cases)/ IgG +/- (1/4<br>cases),<br>HSV: type-1( <i>n</i> = 5),<br>type-2 ( <i>n</i> = 3),<br>PCR ( <i>n</i> = 3) | Yes/no: 3/12 cases, Supportive ( <i>n</i> =<br>Autopsy ( <i>n</i> = 12), 10), ACV ( <i>n</i> = 3),<br>biopsy ( <i>n</i> = 1), PCR<br>= 1), serology ( <i>n</i><br>= 1),<br>LT ( <i>n</i> = 2)/<br>Outcome:<br>survived ( <i>n</i> = 2),<br>died ( <i>n</i> = 13),<br>Survival time <sup>1</sup><br>after surgery: 13<br>(6-30) d,<br>Survival time<br>after liver<br>dysfunction: 5.5<br>(1-9) d |
|---------|-------------------------------------------------------------------------------------------------------------------------------------------------------------------------------------------------------------------------|----------------------------------------------------------------------------------------------------------------------------------------------------------------------------------------------|-------------------------------------------------------------------------------------------------------------------------------------------------------------------------------------------------------------------------------------------|--------------------------------------------------------------------------------------------------------------------------------------------------------------------------------------------------------------|----------------------------------------------------------------------------------------------------------------------------------|--------------------------------------------------------------------------------------------------------------------------------------------------------------------------------------------------------------------------------------------------------------------------------------------------------------------------------------------------------------------------------------------------|

The continuous data were expressed as median values (minimum-maximum values). <sup>1</sup>Survival time: Data were excluded those of surviving patients; <sup>2</sup>The patient was co-infected with multiple agents; bacteria and fungi in the abdominal abscess, cytomegalovirus in the pancreas and lungs, and HSV in the lung and liver. Abd: Abdominal; ACV: Acyclovir; ALT: Alanine aminotransferase; AST: Aspartate aminotransferase; CR: Chronic rejection; HD: Hospital day; HSV: Herpes simplex virus; Ln: Lymph node; LT: Liver transplantation; ND: Not determined or described; PCR: Polymerase chain reaction; POD: Postoperative days; PSL: Prednisolone; TB: Total bilirubin.

presentation of herpetiform lesions (*n* = 3, 27.3%). As clinical course, fever was the first presentation on median time of day 4.5 (day 1-14), followed by gastrointestinal symptoms on day 7 (day 4-9), and liver dysfunction on days 8.5 (day 1-20). Liver test showed predominance of AST (median of 10340 U/L) over ALT (median of 5116 U/L) with slight elevation of total bilirubin levels (median of 2.1 mg/dL). The HSV serotypes 1 and 2 were in 5 and 3 patients, respectively. Serological studies, IgM and IgG for HSV were positive in two (40%) and 1 (20%) in 5 patients. Ante-mortem diagnosis was achieved in 3 (20%) of 15 patients. ACV was treated in 3 (20%) patients, and liver transplantation was performed in two (13.3%) patients. Thirteen patients were died, accounting for mortality of 86.7%.

To further elucidate the clinico-laboratory feature of postsurgical HSVH, we compared with that of non-surgical and immunocompetent patients (non-surgical-HSVH)<sup>[2-32]</sup> (*n* = 42) (Table 2). As statistical analysis, differences were compared using Fisher's exact test or  $\chi^2$  test, and the Mann-Whitney *U* test for categorical variables and continuous measures, respectively. *P* value < 0.05 was considered statistically significant.

Although both patients were comparable in clinical manifestation of fever and digestive symptoms, herpetic lesion was found in smaller numbers in postsurgical HSVH (27.3% vs 51.2%). Viral transmission pathway was identified in three (20%) of the postsurgical HSVH patients including surgical wound (*n* = 2) and trans-esophageal (*n* = 1), the rate comparable that of non-surgical-HSVH patients (23.8%). Although reduction of leukocytes counts and mild elevation of total bilirubin levels were comparable, the levels of serum transaminase were significantly higher in postsurgical HSVH (AST: 10340 vs 5664 U/L, ALT: 5116 vs 3248 U/L, respectively). For laboratory diagnosis, the rates of positive serological study and performance of PCR were 40% and 53.8%, and 20% and 8.4%, respectively. Ante-mortem diagnosis was made in significantly (*P* = 0.017) smaller numbers of postsurgical HSVH patients (20% vs 57.1%). Similarly, in S-HSVH patients, ACV

was treated in significantly (*P* = 0.041) lower numbers of patients (20% vs 47.7%), and survival rates were lower as compared with in counterpart (13.3% vs 28.6%). The surviving days after symptom or surgery occurred, and those after detection of liver dysfunction were comparable between the patients (13 d vs 10 d, 5.5 d vs 5 d, respectively).

Treatment with anti-viral agent, ACV, dramatically decreases mortality and hospital stay of HSV hepatitis<sup>[23]</sup>. We reanalyzed the case reports since 1986 (ACV era), when ACV was first used in our collected papers<sup>[9]</sup> (Table 3). Although the rate of ante-mortem diagnosis before 1985 was achieved in less than half of patients in both groups, the rate since 1986 was significantly (*P* = 0.040) lower in postsurgical group than in non-surgical group (27.3% vs 63.4%). The increase of the rate in ACV era was greater in non-surgical group (63.3% from 33.3%) than in postsurgical group (27.3% from 0%), but not statistically significant. Likewise, in non-surgical HSVH patients, the rates of ACV use and survival during ACV era were significantly increased as compared with those before 1985 [63.4% vs 0%, (*P* = 0.013), and 36.4% vs 0%, (*P* = 0.0321), respectively]. In contrast, in postsurgical HSVH patients, those rates were marginally increased or conversely decreased during ACV era (27.3% vs 0%, and 9.2% vs 25%, respectively). The rates of ACV treatment and survival during ACV era was lower in postsurgical HSVH as compared with those in non-surgical HSVH [27.3% vs 63.4%, (*P* = 0.040), and 9.2% vs 36.4%, (*P* = 0.086), respectively]. Finally, the timing of ACV treatment after detection of liver dysfunction was comparable (8 d vs 10 d), and the survival rates of the patients treated with ACV were not statistically different in both HSVH patients [25% vs 57% (*P* = 0.322)].

## DISCUSSION

We presented a lethal case of HSVH developing soon after surgery. Clinical manifestation included high fever without herpetic mucocutaneous lesions, rapid and relentless



**Table 2 Clinico-laboratory findings of herpetic hepatitis in postsurgical and non-surgical immunocompetent patients**

|                                                                | Postsurgical patients (n = 15)                                           | Non-surgical patients (n = 42)                                                              | P value |
|----------------------------------------------------------------|--------------------------------------------------------------------------|---------------------------------------------------------------------------------------------|---------|
| Gender (M/F) (n)                                               | 8/7                                                                      | 18/24                                                                                       | 0.454   |
| Age (yr)                                                       | 58 (15-93) (n = 15)                                                      | 44 (15-87) (n = 43)                                                                         | 0.060   |
| Clinical manifestation (present/absent or ND)                  |                                                                          |                                                                                             |         |
| Fever (n)                                                      | 14/1                                                                     | 42/0                                                                                        | 0.263   |
| Nausea, vomiting, diarrhea (n)                                 | 6/9 (17.5%)                                                              | 10/32 (23.8%)                                                                               | 0.312   |
| Herpetic lesion present/none (n)                               | 3/8 (27.3%)                                                              | 20/19 (51.2%)                                                                               | 0.308   |
| Transmission route                                             |                                                                          |                                                                                             |         |
| Identified or suspected (n)                                    | 3 (20%)                                                                  | 10 (23.8%)                                                                                  | 0.535   |
|                                                                | Surgical wounds (Trans-genital tracts) (n = 2)<br>Tran-esophagus (n = 1) | Sexually (n = 6)<br>Percutaneous (n = 1)<br>Trans-esophagus (n = 2)<br>Trans-rectum (n = 1) |         |
| Leukocyte count (/mm <sup>3</sup> )                            | 3905 (900-10100) (n = 14)                                                | 2600 (1000-7300) (n = 39)                                                                   | 0.152   |
| AST (U/L)                                                      | 10,340 (5000-20692) (n = 10)                                             | 5664 (92-18937) (n = 39)                                                                    | 0.006   |
| ALT                                                            | 5116 (2970-7000) (n = 8)                                                 | 3248 (141-13980) (n = 29)                                                                   | 0.048   |
| Total bilirubin (mg/dL)                                        | 2.1 (2-8.5) (n = 6)                                                      | 4.4 (0.1-35) (n = 25)                                                                       | 0.154   |
| Serology                                                       |                                                                          |                                                                                             |         |
| positive/negative (n)                                          | 2/3 (40%)                                                                | 14/12 (53.8%)                                                                               | 0.654   |
| PCR analyzed (yes/no) (n)                                      | 3/12 (20%)                                                               | 5/39 (8.4%)                                                                                 | 0.407   |
| HSV type (1/2/1 and 2) (n)                                     | 5/3/0                                                                    | 14/14/3                                                                                     | 1.0     |
| Ante-mortem diagnosis                                          |                                                                          |                                                                                             |         |
| yes/no (n)                                                     | 3/12 (20%)                                                               | 24/18 (57.1%)                                                                               | 0.017   |
| ACV treatment                                                  |                                                                          |                                                                                             |         |
| Yes/ no (n)                                                    | 3/12 (20%)                                                               | 21 / 21 (50%)                                                                               | 0.041   |
| Liver transplantation                                          |                                                                          |                                                                                             |         |
| Yes/no (n)                                                     | 2/13                                                                     | 6/38                                                                                        | 1.0     |
| Outcome                                                        |                                                                          |                                                                                             |         |
| Survived/ died (overall) (n)                                   | 2/13 (13.3%)                                                             | 12/30 (28.6%)                                                                               | 0.312   |
| Survival time <sup>1,2</sup> (d)                               | 13 (6-30) (n = 12)                                                       | 10 (5-29) (n = 26)                                                                          | 0.729   |
| Survival time <sup>2</sup> after liver dysfunction emerged (d) | 5.5 (1-9) (n = 11)                                                       | 5 (1-16) (n = 18)                                                                           | 0.821   |

Continuous data were presented as median with range from minimum and maximum values. For categorical variables and continuous measures, differences were compared using Fisher's exact test or  $\chi^2$  test, and the Mann-Whitney *U* test, respectively. <sup>1</sup>Survival time: were expressed as the days after surgery or symptoms emerging; <sup>2</sup>Survival time: Data were excluded from the surviving patients. ACV: Acyclovir; ALT: Alanine aminotransferase; AST: Aspartate aminotransferase; HSV: Herpes simplex virus; LT: Liver transplantation; PCR: Polymerase chain reaction.

elevation of serum aminotransaminase values (AST > ALT) associated with a relative normal serum bilirubin concentration (anicteric hepatitis), leucopenia, negative serology for HSV, coagulopathy, and encephalopathy. Although serum IgM level for CMV was increased after the surgery, the pathological role of CMV co-infection seemed to be minimal, because no viral was detected by immunostaining and PCR analysis in the liver.

Development of fulminant HSVH following surgery is extremely rare. In a review of fifteen cases (Table 1), several features were pointed out. (1) A wide spectrum of diseases (benign and malignant) and surgery (pancreatobiliary-, neurologic-, gynecologic-, urologic-, and digestive-surgery) involved; (2) cancer and post-operative steroid use are risk factor; (3) fever is the first and uniform presentation on median time of post-operative day 4.5, followed by gastrointestinal symptoms on day 7, liver dysfunction and leucopenia on day 8.5, and death resulting on day 13; (4) rare presentation of herpetic lesions (27.3%); (5) vigorous deterioration of anicteric hepatitis; (6) low rates of positive IgM (40%) and IgG (20%); (7) extremely high mortality (87%) associated with low rates of ante-mortem diagnosis

(20%) and acyclovir treatment (20%). These findings suggest that postsurgical HSVH can develop in a wide surgical spectrum, but preferably occurs in latently immunocompromised hosts. There were no definite criteria for diagnosis. Nevertheless, sudden onset and rapid deterioration of the lethal hepatitis needs prompt diagnosis and anti-viral treatment for survival.

Although our patient was mildly anemic and under-nourished, he seemed to be non-immunocompromised, because he was healthy enough to undergo ordinary surgery for biliary stones and showed normal humoral response against CMV infection. However, there is a concern that immune-modulation by an excessive inflammation and viral entry by surgical manipulation may enhance to HSV infection and present with unique clinical course in postsurgical HSVH patients. The postsurgical HSVH as compared with non-surgical HSVH occurring in apparently healthy patients (Table 2) showed that (1) More vigorous liver necrosis as suggested by higher values of serum aminotransferases, although comparable magnitudes of disease rapidity and high mortality; (2) surgical wound as transmission pathway in only a few cases (20%). These findings do not likely support

**Table 3** Clinical features of herpetic hepatitis in surgical and non-surgical immunocompetent patients before 1985 and after 1986 (acyclovir era)

|                                                       | Postsurgical patients ( <i>n</i> = 15) | Non-surgical patients ( <i>n</i> = 42) | <i>P</i> value<br>(Postsurgical <i>vs</i> Non-surgical) |
|-------------------------------------------------------|----------------------------------------|----------------------------------------|---------------------------------------------------------|
| Ante-mortem diagnosis                                 |                                        |                                        |                                                         |
| Yes/ no (before 1985) ( <i>n</i> )                    | 0/4 (0%)                               | 3/6 (33.3%)                            | 0.497                                                   |
| Yes/ no (since 1986) ( <i>n</i> )                     | 3/8 (27.3%)                            | 21/12 (63.4%)                          | 0.040                                                   |
| <i>P</i> values<br>(before 1985 <i>vs</i> since 1986) | 0.363                                  | 0.166                                  |                                                         |
| ACV treatment                                         |                                        |                                        |                                                         |
| Yes/ no (before 1985) ( <i>n</i> )                    | 0/4 (0%)                               | 0/9 (0%)                               | 1.0                                                     |
| Yes/ no (since 1986) ( <i>n</i> )                     | 3/8 (27.3%)                            | 21/12 (63.4%)                          | 0.040                                                   |
| <i>P</i> values<br>(before 1985 <i>vs</i> since 1986) | 0.363                                  | 0.013                                  |                                                         |
| Outcome                                               |                                        |                                        |                                                         |
| Survived/ died (before 1985) ( <i>n</i> )             | 1/3 (25%)                              | 0/9 (0%)                               | 0.308                                                   |
| Survived/ died (since 1986) ( <i>n</i> )              | 1/10 (9.2%)                            | 12/21 (36.4%)                          | 0.086                                                   |
| <i>P</i> values<br>(before 1985 <i>vs</i> since 1986) | 0.476                                  | 0.0321                                 |                                                         |
| Timing of ACV treatment <sup>†</sup>                  | 8 (4-10) ( <i>n</i> = 3)               | 10 (6-15) ( <i>n</i> = 16)             | 0.365                                                   |
| Outcome after ACV treatment                           |                                        |                                        |                                                         |
| Survived/ died                                        | 1/3 (25%)                              | 12/9 (57%)                             | 0.322                                                   |

Continuous data were presented as median with range from minimum and maximum values. For categorical variables and continuous measures, differences were compared using Fisher's exact test or  $\chi^2$  test and the Mann-Whitney *U* test, respectively. <sup>†</sup>Timing of ACV treatment: Data were expressed as the days after liver dysfunction emerged. ACV: Acyclovir.

immunological disturbance and viral entry conferred by surgery as the major factors for postsurgical HSVH development. Alternatively, large HSV inoculums at the time of initial infection and/or viral heterogeneity (hepatovirulent strain) may be possible mechanisms<sup>[12]</sup>.

It is of interest that establishment of ante-mortem diagnosis, ACV application and survival were significantly improved in non-surgical HSVH during ACV era (since 1986), whereas the improvement was limited in postsurgical HSVH (Table 3). Since survival benefit was comparably conferred by ACV treatment, a delay or failure in diagnosis as well as anti-viral therapy may result in worse prognosis of postsurgical HSVH. Several factors specific for postsurgical condition including hemodynamic changes, hepatotoxic drugs, anesthesia<sup>[33,36,37]</sup>, and septic infection make complicated in differential diagnosis of postoperative hepatitis. CT image is helpful for excluding circulatory or abscess changes, but it does not lead to direct diagnosis. HSV serological examination has also limitations and herpetic lesions are frequently lacked as shown in this patient<sup>[20,26]</sup>. For diagnosis of HSV hepatitis, liver biopsy is gold standard, but coexisting coagulopathy often hampers its practice. Alternatively, PCR detection of the viral genome is recommended<sup>[20]</sup>, but the use of sophisticated equipment is not always available in local hospitals. Nevertheless, due to a wide clinical spectrum, we can encounter the disease in non-specialized facilities, as presented here. Due to the difficulty and delay in diagnosis, rapid and lethal process of the disease

nature, and low risk-benefit ratio, we propose empiric ACV therapy for postsurgical patients presenting with fulminant hepatitis of undetermined etiology.

In conclusion, postsurgical HSVH develops in a wide surgical spectrum with predisposing factors of malignancy and postoperative immunosuppression. Because of the difficulty in definite diagnosis and lethal nature of the disease, a high index of suspicion along with empiric antiviral intervention is imperative for undetermined fulminant hepatitis characterized by fever and leucopenia.

## ARTICLE HIGHLIGHTS

### Case characteristics

A healthy 72-year-old man developed fatal herpes simplex hepatitis soon after ordinary surgery for biliary stones.

### Clinical diagnosis

A sudden onset of hepatitis associated with high fever and leukopenia emerged on postoperative day 5, followed by a rapid and lethal course (died on day 9).

### Differential diagnosis

Several factors specific for postsurgical condition including hemodynamic changes, hepatotoxic drugs, anesthesia, and septic infection make complicated in differential diagnosis of postoperative hepatitis.

### Laboratory diagnosis

A rapid elevation of liver aminotransferases (aspartate aminotransferase > alanine aminotransferase) without alteration of cholestasis was followed by coagulation disorder and encephalopathy.

## Imaging diagnosis

A contrast-enhanced computed tomography showed heterogeneous contrast distribution and a mottled liver without any abscess formation.

## Pathological diagnosis

Postmortem liver biopsy revealed diffuse necrosis and loss of normal architecture with characteristic findings of intranuclear inclusions.

## Treatment

Empiric therapy with acyclovir, intravenous injection (10 mg/kg, every eight hours) was initiated on postoperative day 8.

## Related reports

Fatal herpetic hepatitis occurs in non-surgical healthy adults as well, whereas the disease following surgery is rarer and is more difficult for precise diagnosis.

## Term explanation

Development of herpetic hepatitis is fatal complication following surgery, because of the difficulty for precise diagnosis and rapid deterioration of the disease.

## Experiences and lessons

Due to the difficulty in diagnosis and lethal nature, an early clinical suspension and prompt empirical anti-viral intervention are imperative for postsurgical hepatitis with undetermined etiology, characterized by fever and leucopenia.

## ACKNOWLEDGEMENTS

The authors would like to appreciate Dr. Makoto Kuroda, Department of Pathology, Fujita Health University, for his definite diagnosis and valuable advice. We also appreciate Drs. Satoshi Baba and Isao Kosugi, Department of Pathology, Hamamatsu University School of Medicine, for their excellent immunostaining for CMV virus in the liver tissues.

## REFERENCES

- 1 Bliss SJ, Moseley RH, Del Valle J, Saint S. Clinical problem-solving. A window of opportunity. *N Engl J Med* 2003; **349**: 1848-1853 [PMID: 14602884 DOI: 10.1056/NEJMcps031315]
- 2 Francis TI, Osuntokun BO, Kemp GE. Fulminant hepatitis due to herpes hominis in an adult human. *Am J Gastroenterol* 1972; **57**: 329-332 [PMID: 4337299]
- 3 Joseph TJ, Vogt PJ. Disseminated herpes with hepatoadrenal necrosis in an adult. *Am J Med* 1974; **56**: 735-739 [PMID: 4363476 DOI: 10.1016/0002-9343(74)90643-3]
- 4 Eron L, Kosinski K, Hirsch MS. Hepatitis in an adult caused by Herpes simplex virus type I. *Gastroenterology* 1976; **71**: 500-504 [PMID: 181286]
- 5 Connor RW, Lorts G, Gilbert DN. Lethal herpes simplex virus type 1 hepatitis in a normal adult. *Gastroenterology* 1979; **76**: 590-594 [PMID: 218866]
- 6 Whorton CM, Thomas DM, Denham SW. Fatal systemic herpes simplex virus type 2 infection in a healthy young woman. *South Med J* 1983; **76**: 81-83 [PMID: 6297097 DOI: 10.1097/00007611-198301000-000217]
- 7 Rubin MH, Ward DM, Painter CJ. Fulminant hepatic failure caused by genital herpes in a healthy person. *JAMA* 1985; **253**: 1299-301 [PMID: 298204 DOI: 10.1001/jama.1985.03350330097031]
- 8 Goodman ZD, Ishak KG, Sesterhenn IA. Herpes simplex hepatitis in apparently immunocompetent adults. *Am J Clin Pathol* 1986; **85**: 694-699 [PMID: 3518404 DOI: 10.1093/ajcp/85.6.694]
- 9 Baxter RP, Phillips LE, Faro S, Hoffman L. Hepatitis due to herpes simplex virus in a nonpregnant patient: treatment with acyclovir. *Sex Transm Dis* 1986; **13**: 174-176 [PMID: 3764630 DOI: 10.1097/00007435-198607000-00014]
- 10 Andre PM, Camus C, Ruffault A, Cartier F. Herpes hepatitis and high levels of circulating interferon. *J Infect Dis* 1987; **156**: 529 [PMID: 2440956 DOI: 10.1093/infdis/156.3.529]
- 11 McMin PC, Lim IS, McKenzie PE, van Deth AG, Simmons A. Disseminated herpes simplex virus infection in an apparently immunocompetent woman. *Med J Aust* 1989; **151**: 588-590; 592; 594 [PMID: 2687652]
- 12 Miyazaki Y, Akizuki S, Sakaoka H, Yamamoto S, Terao H. Disseminated infection of herpes simplex virus with fulminant hepatitis in a healthy adult. A case report. *APMIS* 1991; **99**: 1001-1007 [PMID: 1659835 DOI: 10.1111/j.1699-0463.1991.tb01292.x]
- 13 Tomita T, Garcia F, Mowry M. Herpes simplex hepatitis before and after acyclovir treatment. Immunohistochemical and in situ hybridization study. *Arch Pathol Lab Med* 1992; **116**: 173-177 [PMID: 1310245]
- 14 Lasserre M, Huguet C, Terno O. Acute severe herpes simplex hepatitis with virus-associated hemophagocytic syndrome in an immunocompetent adult. *J Hepatol* 1993; **18**: 256-257 [PMID: 8409342 DOI: 10.1016/S0168-8278(05)80255-7]
- 15 Farr RW, Short S, Weissman D. Fulminant hepatitis during herpes simplex virus infection in apparently immunocompetent adults: report of two cases and review of the literature. *Clin Infect Dis* 1997; **24**: 1191-1194 [PMID: 9195081 DOI: 10.1086/513646]
- 16 Velasco M, Llamas E, Guijarro-Rojas M, Ruiz-Yagüe M. Fulminant herpes hepatitis in a healthy adult: a treatable disorder? *J Clin Gastroenterol* 1999; **28**: 386-389 [PMID: 10372946 DOI: 10.1097/00004836-199906000-00025]
- 17 Peters DJ, Greene WH, Ruggiero F, McGarrity TJ. Herpes simplex-induced fulminant hepatitis in adults: a call for empiric therapy. *Dig Dis Sci* 2000; **45**: 2399-2404 [PMID: 11258565 DOI: 10.1023/A:1005699210816]
- 18 Fahy RJ, Crouser E, Pacht ER. Herpes simplex type 2 causing fulminant hepatic failure. *South Med J* 2000; **93**: 1212-1216 [PMID: 11142460 DOI: 10.1097/00007611-2000093120-00015]
- 19 Pinna AD, Rakela J, Demetris AJ, Fung JJ. Five cases of fulminant hepatitis due to herpes simplex virus in adults. *Dig Dis Sci* 2002; **47**: 750-754 [PMID: 11991604 DOI: 10.1023/A:1014779614525]
- 20 Ichai P, Roque Afonso AM, Sebah M, Gonzalez ME, Codés L, Azoulay D, Saliba F, Karam V, Dussaix E, Guettier C, Castaing D, Samuel D. Herpes simplex virus-associated acute liver failure: a difficult diagnosis with a poor prognosis. *Liver Transpl* 2005; **11**: 1550-1555 [PMID: 16315311 DOI: 10.1002/lt.20545]
- 21 Czartoski T, Liu C, Koelle DM, Schmechel S, Kalus A, Wald A. Fulminant, acyclovir-resistant, herpes simplex virus type 2 hepatitis in an immunocompetent woman. *J Clin Microbiol* 2006; **44**: 1584-1586 [PMID: 16597901 DOI: 10.1128/JCM.44.4.1584-1586.2006]
- 22 Abbo L, Alcaide ML, Pano JR, Robinson PG, Campo RE. Fulminant hepatitis from herpes simplex virus type 2 in an immunocompetent adult. *Transpl Infect Dis* 2007; **9**: 323-326 [PMID: 17605748 DOI: 10.1111/j.1399-3062.2007.00207.x]
- 23 Norvell JP, Blei AT, Jovanovic BD, Levitsky J. Herpes simplex virus hepatitis: an analysis of the published literature and institutional cases. *Liver Transpl* 2007; **13**: 1428-1434 [PMID: 17902129 DOI: 10.1002/lt.21250]
- 24 Levitsky J, Duddempudi AT, Lakeman FD, Whitley RJ, Luby JP, Lee WM, Fontana RJ, Blei AT, Ison MG; US Acute Liver Failure Study Group. Detection and diagnosis of herpes simplex virus infection in adults with acute liver failure. *Liver Transpl* 2008; **14**: 1498-1504 [PMID: 18825709 DOI: 10.1002/lt.21567]
- 25 Lakhan SE, Harle L. Fatal fulminant herpes simplex hepatitis secondary to tongue piercing in an immunocompetent adult: a case report. *J Med Case Rep* 2008; **2**: 356 [PMID: 19021902 DOI: 10.1186/1752-1947-2-356]
- 26 Beersma MF, Verjans GM, Metselaar HJ, Osterhaus AD, Berrington WR, van Doornum GJ. Quantification of viral DNA and liver enzymes in plasma improves early diagnosis and management

- of herpes simplex virus hepatitis. *J Viral Hepat* 2011; **18**: e160-e166 [PMID: 20704650 DOI: 10.1111/j.1365-2893.2010.01352.x]
- 27 **Poley RA**, Snowdon JF, Howes DW. Herpes Simplex Virus Hepatitis in an Immunocompetent Adult: A Fatal Outcome due to Liver Failure. *Case Rep Crit Care* 2011; **2011**: 138341 [PMID: 24826316 DOI: 10.1155/2011/138341.]
  - 28 **Wind L**, van Herwaarden M, Sebens F, Gerding M. Severe hepatitis with coagulopathy due to HSV-1 in an immunocompetent man. *Neth J Med* 2012; **70**: 227-229 [PMID: 22744924]
  - 29 **Takeshita A**, Tsuda Y, Fukunishi S, Asai A, Fukuda A, Hayashi M, Hirose Y. Two healthy females with fulminant hepatic failure caused by herpes simplex virus infection. *Pathol Int* 2014; **64**: 48-50 [PMID: 24471971 DOI: 10.1111/pin.12128]
  - 30 **Schuermans W**, Mulliez S, Padalko E, Reynders M, Boel A, Van Vaerenbergh K, De Beenhouwer H. Let's not forget herpes simplex virus in case of fulminant hepatic failure. *Acta Gastroenterol Belg* 2014; **77**: 359-361 [PMID: 25509210]
  - 31 **Czakó L**, Dobra M, Terzin V, Tiszlavicz L, Wittmann T. Sepsis and hepatitis together with herpes simplex esophagitis in an immunocompetent adult. *Dig Endosc* 2013; **25**: 197-199 [PMID: 23368515 DOI: 10.1111/j.1443-1661.2012.01345.x]
  - 32 **Rimawi BH**, Meserve J, Rimawi RH, Min Z, Gnann JW Jr. Disseminated Herpes Simplex Virus with Fulminant Hepatitis. *Case Reports Hepatol* 2015; **2015**: 463825 [PMID: 26290760 DOI: 10.1155/2015/463825]
  - 33 **Douglas HJ**, Eger EI 2nd, Biava CG, Renzi C. Hepatic necrosis associated with viral infection after enflurane anesthesia. *N Engl J Med* 1977; **296**: 553-555 [PMID: 189190 DOI: 10.1056/NEJM197703102961007]
  - 34 **Marrie TJ**, McDonald AT, Conen PE, Boudreau SF. Herpes simplex-hepatitis use of immunoperoxidase to demonstrate the viral antigen in hepatocytes. *Gastroenterology* 1982; **82**: 71-76 [PMID: 6273252]
  - 35 **Williams TL**, Morgan JR, Denzler TB. Fulminant herpes simplex hepatitis following coronary bypass and postcardiotomy syndrome. *Am Heart J* 1985; **110**: 679-680 [PMID: 3876021 DOI: 10.1016/0002-8703(85)90098-5]
  - 36 **Fisher NA**, Iwata RT, Eger EI 2nd, Smuckler EA. Hepatic necrosis associated with herpes virus after isoflurane anesthesia. *Anesth Analg* 1985; **64**: 1131-1133 [PMID: 2996384 DOI: 10.1213/00000539-198511000-00018]
  - 37 **Katz J**, Magee J, Baker B, Eger EI 2nd. Hepatic necrosis associated with herpesvirus after anesthesia with desflurane and nitrous oxide. *Anesth Analg* 1994; **78**: 1173-1176 [PMID: 8198278 DOI: 10.1213/00000539-199406000-00026]
  - 38 **Kaufman B**, Gandhi SA, Louie E, Rizzi R, Illei P. Herpes simplex virus hepatitis: case report and review. *Clin Infect Dis* 1997; **24**: 334-338 [PMID: 9114181 DOI: 10.1093/clinids/24.3.334]
  - 39 **Price TM**, Harris JB. Fulminant hepatic failure due to herpes simplex after hysteroscopy. *Obstet Gynecol* 2001; **98**: 954-956 [PMID: 11704219]
  - 40 **Kohno M**, Hoshino U, Kobayashi J, Shiota G. A case of fulminant hepatitis caused by herpes simplex virus type 2 after the operation for hypertensive intracerebral hemorrhage. *Kanzo* 2001; **42**: 217-222 [DOI: 10.2957/kanzo.42.217]
  - 41 **Biancofiore G**, Bisà M, Bindi LM, Urbani L, Tascini C, Menichetti F, Filippini F. Liver transplantation due to Herpes Simplex virus-related sepsis causing massive hepatic necrosis after thoracoscopic thymectomy. *Minerva Anesthesiol* 2007; **73**: 319-322 [PMID: 17529922]
  - 42 **Chaudhary D**, Ahmed S, Liu N, Marsano-Obando L. Acute Liver Failure from Herpes Simplex Virus in an Immunocompetent Patient Due to Direct Inoculation of the Peritoneum. *ACG Case Rep J* 2017; **4**: e23 [PMID: 28286789 DOI: 10.14309/crj.2017.23]

P- Reviewer: Rajcani B S- Editor: Cui LJ L- Editor: A  
E- Editor: Li RF







Published by **Baishideng Publishing Group Inc**  
7901 Stoneridge Drive, Suite 501, Pleasanton, CA 94588, USA  
Telephone: +1-925-223-8242  
Fax: +1-925-223-8243  
E-mail: [bpgoffice@wjgnet.com](mailto:bpgoffice@wjgnet.com)  
Help Desk: <http://www.f6publishing.com/helpdesk>  
<http://www.wjgnet.com>

