

World Journal of *Clinical Cases*

World J Clin Cases 2019 July 6; 7(13): 1535-1731





REVIEW

- 1535 Intracranial pressure monitoring: Gold standard and recent innovations
Nag DS, Sahu S, Swain A, Kant S

- 1554 Role of the brain-gut axis in gastrointestinal cancer
Di YZ, Han BS, Di JM, Liu WY, Tang Q

MINIREVIEWS

- 1571 Cholestatic liver diseases: An era of emerging therapies
Samant H, Manatsathit W, Dies D, Shokouh-Amiri H, Zibari G, Boktor M, Alexander JS

ORIGINAL ARTICLE

Basic Study

- 1582 Neural metabolic activity in idiopathic tinnitus patients after repetitive transcranial magnetic stimulation
Kan Y, Wang W, Zhang SX, Ma H, Wang ZC, Yang JG

Retrospective Study

- 1591 Neuroendoscopic and microscopic transsphenoidal approach for resection of nonfunctional pituitary adenomas
Ding ZQ, Zhang SF, Wang QH

- 1599 Safety and efficacy of transjugular intrahepatic portosystemic shunt combined with palliative treatment in patients with hepatocellular carcinoma
Luo SH, Chu JG, Huang H, Yao KC

- 1611 Leveraging machine learning techniques for predicting pancreatic neuroendocrine tumor grades using biochemical and tumor markers
Zhou RQ, Ji HC, Liu Q, Zhu CY, Liu R

Clinical Trials Study

- 1623 Development and validation of a model to determine risk of refractory benign esophageal strictures
Lu Q, Lei TT, Wang YL, Yan HL, Lin B, Zhu LL, Ma HS, Yang JL

SYSTEMATIC REVIEWS

- 1634 Hydatid cyst of the colon: A systematic review of the literature
Lataat-Córdoba MÁ, Ruiz-Blanco S, Sanchez M, Santiago-Boyer C, Soto-García P, Sun W, Ramia JM

CASE REPORT

- 1643** Colon cancer arising from colonic diverticulum: A case report
Kayano H, Ueda Y, Machida T, Hiraiwa S, Zakoji H, Tajiri T, Mukai M, Nomura E
- 1652** Endoscopic submucosal dissection as excisional biopsy for anorectal malignant melanoma: A case report
Manabe S, Boku Y, Takeda M, Usui F, Hirata I, Takahashi S
- 1660** Gastrointestinal infection-related disseminated intravascular coagulation mimicking Shiga toxin-mediated hemolytic uremic syndrome - implications of classical clinical indexes in making the diagnosis: A case report and literature review
Li XY, Mai YF, Huang J, Pai P
- 1671** A complicated case of innominate and right common arterial aneurysms due to Takayasu's arteritis
Wang WD, Sun R, Zhou MX, Liu XR, Zheng YH, Chen YX
- 1677** Multimodality-imaging manifestations of primary renal-allograft synovial sarcoma: First case report and literature review
Xu RF, He EH, Yi ZX, Lin J, Zhang YN, Qian LX
- 1686** Chronic progression of recurrent orthokeratinized odontogenic cyst into squamous cell carcinoma: A case report
Wu RY, Shao Z, Wu TF
- 1696** Gastric adenocarcinoma of fundic gland type after *Helicobacter pylori* eradication: A case report
Yu YN, Yin XY, Sun Q, Liu H, Zhang Q, Chen YQ, Zhao QX, Tian ZB
- 1703** Synchronous multiple primary gastrointestinal cancers with *CDH1* mutations: A case report
Hu MN, Lv W, Hu RY, Si YF, Lu XW, Deng YJ, Deng H
- 1711** Primary hepatoid adenocarcinoma of the lung in Yungui Plateau, China: A case report
Shi YF, Lu JG, Yang QM, Duan J, Lei YM, Zhao W, Liu YQ
- 1717** Liver failure associated with benzbromarone: A case report and review of the literature
Zhang MY, Niu JQ, Wen XY, Jin QL
- 1726** Giant low-grade appendiceal mucinous neoplasm: A case report
Yang JM, Zhang WH, Yang DD, Jiang H, Yu L, Gao F

ABOUT COVER

Editorial Board Member of *World Journal of Clinical Cases*, Hitoshi Hirose, MD, PhD, Associate Professor, Department of Cardiothoracic Surgery, Thomas Jefferson University, Philadelphia, PA 19107, United States

AIMS AND SCOPE

World Journal of Clinical Cases (*World J Clin Cases*, *WJCC*, online ISSN 2307-8960, DOI: 10.12998) is a peer-reviewed open access academic journal that aims to guide clinical practice and improve diagnostic and therapeutic skills of clinicians.

The primary task of *WJCC* is to rapidly publish high-quality Case Report, Clinical Management, Editorial, Field of Vision, Frontier, Medical Ethics, Original Articles, Meta-Analysis, Minireviews, and Review, in the fields of allergy, anesthesiology, cardiac medicine, clinical genetics, clinical neurology, critical care, dentistry, dermatology, emergency medicine, endocrinology, family medicine, gastroenterology and hepatology, etc.

INDEXING/ABSTRACTING

The *WJCC* is now indexed in PubMed, PubMed Central, Science Citation Index Expanded (also known as SciSearch®), and Journal Citation Reports/Science Edition. The 2019 Edition of Journal Citation Reports cites the 2018 impact factor for *WJCC* as 1.153 (5-year impact factor: N/A), ranking *WJCC* as 99 among 160 journals in Medicine, General and Internal (quartile in category Q3).

RESPONSIBLE EDITORS FOR THIS ISSUE

Responsible Electronic Editor: *Yan-Xia Xing*

Proofing Production Department Director: *Yun-Xiaojuan Wu*

NAME OF JOURNAL

World Journal of Clinical Cases

ISSN

ISSN 2307-8960 (online)

LAUNCH DATE

April 16, 2013

FREQUENCY

Semimonthly

EDITORS-IN-CHIEF

Dennis A Bloomfield, Sandro Vento

EDITORIAL BOARD MEMBERS

<https://www.wjnet.com/2307-8960/editorialboard.htm>

EDITORIAL OFFICE

Jin-Lei Wang, Director

PUBLICATION DATE

July 6, 2019

COPYRIGHT

© 2019 Baishideng Publishing Group Inc

INSTRUCTIONS TO AUTHORS

<https://www.wjnet.com/bpg/gerinfo/204>

GUIDELINES FOR ETHICS DOCUMENTS

<https://www.wjnet.com/bpg/GerInfo/287>

GUIDELINES FOR NON-NATIVE SPEAKERS OF ENGLISH

<https://www.wjnet.com/bpg/gerinfo/240>

PUBLICATION MISCONDUCT

<https://www.wjnet.com/bpg/gerinfo/208>

ARTICLE PROCESSING CHARGE

<https://www.wjnet.com/bpg/gerinfo/242>

STEPS FOR SUBMITTING MANUSCRIPTS

<https://www.wjnet.com/bpg/GerInfo/239>

ONLINE SUBMISSION

<https://www.f6publishing.com>

Colon cancer arising from colonic diverticulum: A case report

Hajime Kayano, Yusuhiko Ueda, Takashi Machida, Shinichiro Hiraiwa, Hidenori Zakoji, Takuma Tajiri, Masaya Mukai, Eiji Nomura

ORCID number: Hajime Kayano (0000-0002-8304-1136); Yasuhiko Ueda (0000-0003-1130-9209); Takashi Machida (0000-0002-4122-1016); Shinichiro Hiraiwa (0000-0003-4946-9144); Hidenori Zakoji (0000-0002-9886-5429); Takuma Tajiri (0000-0002-3051-4489); Masaya Mukai (0000-0001-6120-0012); Eiji Nomura (0000-0002-7365-115X).

Author contributions: All authors contributed to the acquisition of data, writing, and revision of this manuscript.

Informed consent statement: Consent was obtained from the patient for publication of this report and any accompanying images.

Conflict-of-interest statement: All the authors declare that they have no conflict of interest.

CARE Checklist (2016) statement: The authors have read the CARE Checklist (2016), and the manuscript was prepared and revised according to the CARE Checklist (2016).

Open-Access: This article is an open-access article which was selected by an in-house editor and fully peer-reviewed by external reviewers. It is distributed in accordance with the Creative Commons Attribution Non Commercial (CC BY-NC 4.0) license, which permits others to distribute, remix, adapt, build upon this work non-commercially, and license their derivative works on different terms, provided the original work is properly cited and the use is non-commercial. See:

Hajime Kayano, Yusuhiko Ueda, Takashi Machida, Masaya Mukai, Eiji Nomura, Department of Gastroenterological and General Surgery, Tokai University Hachioji Hospital, Tokyo, Hachioji 192-0032, Japan

Shinichiro Hiraiwa, Takuma Tajiri, Departments of Pathology, Tokai University Hachioji Hospital, Tokyo, Hachioji 192-0032, Japan

Hidenori Zakoji, Departments of Urology, Tokai University Hachioji Hospital, Tokyo, Hachioji 192-0032, Japan

Corresponding author: Hajime Kayano, MD, PhD, Assistant Professor, Doctor, Surgeon, Department of Gastroenterological and General Surgery, Tokai University Hachioji Hospital, 1838 Ishikawa-machi, Tokyo, Hachioji 192-0032, Japan. h.kayano@tsc.u-tokai.ac.jp

Telephone: +81-42-6391111

Fax: +81-42-6391144

Abstract

BACKGROUND

Colonic diverticulosis is a common disease, and the coexistence of colonic diverticulosis and colorectal cancer is often seen clinically. It is very rare that colon cancer arises from the mucosa of a colonic diverticulum. When colon cancer arises in a diverticulum and then tends to develop outside the wall, without developing within the lumen, the differential diagnosis from complicating lesions due to colonic diverticulitis is difficult.

CASE SUMMARY

A 76-year-old man was admitted to a nearby clinic with a chief complaint of discomfort and urinary frequency. Since a vesicosigmoidal fistula was seen on abdominal computed tomography, he was referred to our hospital. Laparoscopic sigmoidectomy was performed because the various diagnostic findings were diagnosed as a vesicosigmoidal fistula with diverticulitis of the sigmoid colon. However, on histopathological examination, it was diagnosed as a vesicosigmoidal fistula due to colon cancer arising in the diverticulum. Laparoscopic partial resection of the bladder was performed because local recurrence was observed in the bladder wall one and a half years after surgery. It is currently one year after reoperation, but there has been no recurrence or metastasis.

CONCLUSION

Colon cancer arising in a diverticulum of the colon should be considered when diverticulitis with complications is observed.

<http://creativecommons.org/licenses/by-nc/4.0/>

Manuscript source: Unsolicited manuscript

Received: February 26, 2019

Peer-review started: February 27, 2019

First decision: April 18, 2019

Revised: April 28, 2019

Accepted: May 1, 2019

Article in press: May 1, 2019

Published online: July 6, 2019

P-Reviewer: Contini S, Fabozzi M

S-Editor: Dou Y

L-Editor: A

E-Editor: Wang J



Key words: Colon cancer; Diverticulum; Colovesical fistula; Laparoscopic surgery; Diverticulitis; Case report

©The Author(s) 2019. Published by Baishideng Publishing Group Inc. All rights reserved.

Core tip: Cancers arising from a diverticulum of the colon are extremely rare, and few cases have been reported. Cancer of a colonic diverticulum has difficulty progressing into the lumen, and it is often difficult to identify by imaging examinations. In addition, due to the anatomical characteristics of the diverticulum, it is easy for the cancer to progress outside the colon wall. Thus, it is often in an advanced stage at the time of discovery, and careful attention is needed.

Citation: Kayano H, Ueda Y, Machida T, Hiraiwa S, Zakoji H, Tajiri T, Mukai M, Nomura E. Colon cancer arising from colonic diverticulum: A case report. *World J Clin Cases* 2019; 7(13): 1643-1651

URL: <https://www.wjgnet.com/2307-8960/full/v7/i13/1643.htm>

DOI: <https://dx.doi.org/10.12998/wjcc.v7.i13.1643>

INTRODUCTION

The co-existence of colorectal diverticulosis and colorectal cancer is seen clinically, and so far there have been many research reports and case reports^[1-4]. However, it is extremely rare for colon cancer to develop from within a diverticulum of the colon. In this case, laparoscopic surgery was performed for a vesicosigmoidal fistula with diverticulitis of the sigmoid colon, and the postoperative histopathological examination showed colon cancer arising in the diverticulum. The clinical features of colon cancer arising in the diverticulum are reviewed, along with past reports^[5-20] and including this case.

CASE PRESENTATION

Chief complaints

Discomfort during urination and frequent urination.

History of present illness

A 76-year-old man became conscious of urgency when urinating three months earlier and developed frequent urination. He also recognized food residue in the urine three days earlier and consulted a nearby clinic. Since a vesicosigmoidal fistula was found on abdominal computed tomography (CT), he was referred to our hospital and admitted for the purpose of intensive examination and treatment.

History of past illness

The patient had a history of spinal posterior fusion surgery for disc herniation. There was no history of trauma, abdominal disease, abdominal surgery, or urological disease. Moreover, there was no history of colonoscopy or upper esophagogastroduodenoscopy.

Personal and family history

The patient was taking Olmetec OD tablets (olmesartan medoxomil) for hypertension, Allopurinol tablets (Allopurinol) for hyperuricaemia, and Urief tablets (Silodosin) and Cernilton tablets (cernitin pollen extract) for prostate enlargement. His family medical history was unremarkable.

Physical examination upon admission

The patient's abdomen was smooth and soft, with no tenderness and no palpable tumor.

Laboratory examinations

The results of hematological examinations were: White blood cell count 8200/ μ L; C-reactive protein 4.635 mg/dL; Hb 11.8 g/dL; Plt 15.3×10^4 / μ L; BUN 19 mg/dL; Cre 1.00 mg/dL; and HbA1c 6.1%. Thus, there was a mild inflammatory response and

anemia. The tumor markers were not elevated (CEA 1 ng/mL, CA19-9 15.3 U/mL). On urinalysis, the leukocyte reaction was 3+, and occult blood was 1+.

Imaging examinations

Enhanced abdominal CT showed multiple diverticula in the sigmoid colon, and an increased CT value of panniculitis was observed around the large intestinal tract. Inflammatory changes around the large intestinal tract continued to the left bladder wall, and the bladder wall was slightly thickened. Neither a tumorous lesion nor swelling of the para colic lymph nodes was seen (Figure 1A). Similarly, enhanced abdominal magnetic resonance imaging (MRI) showed a penetrating portion continuous with the sigmoid colon on the upper left side wall of the bladder. However, tumorous lesions were not seen (Figure 1B). With an enema of a water-soluble contrast agent (Figure 1C) and colonoscopy, only multiple diverticula were found in the sigmoid colon. Cystoscopy showed inflammatory changes on the mucosal surface of the bladder, but there was no fistula; no intestinal fluid flowed into the bladder, and no tumorous lesion was seen.

Preoperative diagnosis

Vesicosigmoidal fistula with diverticulitis of the sigmoid colon.

TREATMENT

Laparoscopic sigmoidectomy and fistulectomy were performed. At surgery, fistula formation was observed in the sigmoid colon and the upper left side of the bladder wall (Figure 2). To resect the fistula, blunt dissection was first performed using a suction tube followed by sharp dissection using bipolar scissors. Although the fistula was somewhat firm, it was relatively easily separated from the surrounding tissue during the dissection. The bladder wall was preserved because no tumorous lesions that suggested cancer were observed. Finally, sigmoidectomy was performed. Anastomosis was completed with a double stapling technique, and the operation was completed. A colostomy was not created.

FINAL DIAGNOSIS

In the resected specimen, macroscopic findings only showed diffuse diverticula in the sigmoid colon lumen. A diverticulum was found in the area of fistula formation, but no tumorous lesions were observed (Figure 3A, 3B). On microscopic examination, a protruding lesion appeared toward the diverticular lumen, and well-differentiated cylindrical cancer cells proliferated in a papillary or tubular pattern, indicating a diagnosis of well-differentiated adenocarcinoma (Figure 3C). The depth of invasion was diagnosed as exceeding the serosal surface, and the resection margin was positive. Metastasis was not observed in the para colic lymph nodes near the lesions. The patient was offered additional resection, but refused. Thus, strict observation was performed. For follow-up, the patient's serum carcinoembryonic antigen level was tested at a 3-mo interval, chest and abdomino-pelvic CT were performed at a 6-mo interval, and colonoscopy was performed at a 1-year interval.

OUTCOME AND FOLLOW-UP

A tumorous lesion about 1-cm in size was noted in the bladder wall on enhanced abdominal CT (Figure 4) one and a half years after the operation, and tumor biopsy was performed transurethrally by urological surgery. On histopathological examination, well-differentiated adenocarcinoma was recognized, which was similar in appearance to the cancer in the diverticulum operated previously, and it was diagnosed as recurrence in the bladder wall. The condition of the disease was again explained to the patient and family, and informed consent was obtained for laparoscopic partial resection of the bladder. On follow-up after the surgery, there has been no recurrence or metastasis one year after re-operation.

DISCUSSION

The co-existence of colonic diverticulosis, colon cancer, and adenoma is often seen clinically. However, there have been various reports as to whether there is a

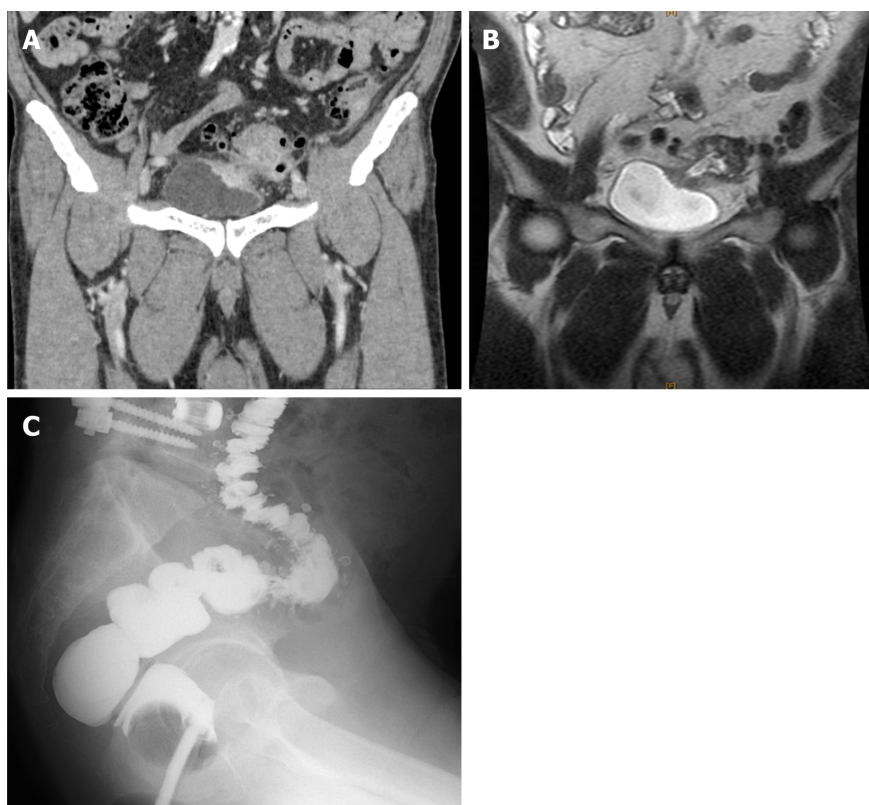


Figure 1 Preoperative computed tomography, magnetic resonance imaging, and gastrografin enema examination. A: The inflammatory changes around the intestinal tract continue to the left bladder wall, and the bladder wall is slightly thickened. Tumor cannot be seen; B: A penetrating portion continuous with the sigmoid colon is visible on the upper left side wall of the bladder; C: Only a diverticulum is found in the sigmoid colon.

difference in the incidence of colorectal cancer due to the presence or absence of colonic diverticula, and the relationship is unclear^[1-4]. As for the effect of the presence of diverticula on carcinogenesis, it has been reported that carcinogenesis may be caused by repeated chronic inflammation due to diverticulitis and changes in the intestinal bacterial flora caused by multiple diverticula^[5]. On the other hand, colorectal cancer that arises in the diverticulum of the colon is extremely rare. The relevant English literature was retrieved from the PubMed database from 1990 to 2018 using the keywords “colon cancer”, “diverticulum”, “diverticulosis”, and “diverticulitis”. The clinical features of cancers in diverticula were considered based on the 17 cases identified and the present case^[5-20] (Table 1). The cancer was detected due to the appearance of various symptoms, such as abdominal pain, urination pain due to abscess formation, and bleeding from a tumor. Abdominal examination was performed, but only 47% (8/17) of cases were diagnosed with colorectal cancer by colonoscopy or enema before surgery, and in abdominal CT, only 37% (4/7) of cases were suspected colorectal cancer. Suspected colorectal cancer/colorectal cancer was diagnosed in about 50% (9/18) of cases preoperatively. About half of the cases were operated for complications due to colonic diverticulitis, and in many cases the diagnosis of colorectal cancer arising in the diverticulum was made for the first time after surgery. Even in the present case, it was not possible to identify the colorectal cancer in all examinations performed, including enhanced abdominal CT, enhanced abdominal MRI, and enema and colonoscopy. Therefore, it was decided to perform surgery based on the diagnosis of a vesicosigmoidal fistula caused by sigmoid colon diverticulitis. On pathological examination, no tumorous lesion was observed on macroscopic observation. Microscopic findings showed that the tumor developed slightly in the mucous membrane of the luminal side, but progressed mainly from the inside of the diverticulum in which the muscularis propria was missing. Colorectal cancer generally grows and progresses along the mucous membrane direction (horizontal development) and the membrane direction (vertical development). Compared with common colorectal cancer, the colon cancer that develops from within a diverticulum has less mucosal direction toward the luminal side (horizontal development), despite the fact that the cancer propagates easily from the diverticulum in the direction of the serosa (vertical development) out the wall. This is due to the anatomical characteristics of the diverticular lumen, which spreads widely in the

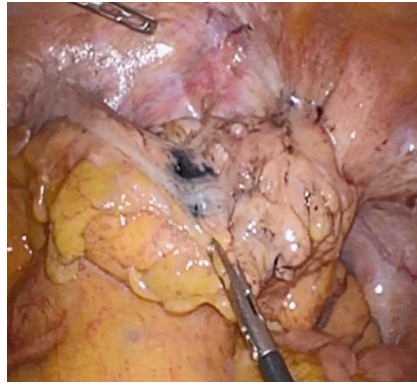


Figure 2 Intraoperative findings. A portion of the fistula with the sigmoid colon is observed on the upper left side of the bladder wall.

colon diverticulum, but the diverticular orifice area is narrower than the diverticular lumen. Thus, it seems that it is difficult for the cancer to develop in the direction of the luminal side. Unlike usual colorectal cancer, due to such anatomical features that restrict development, it is difficult to identify lesions on colonoscopy with an enema of the lower gastrointestinal tract. Furthermore, another anatomical characteristic of the colonic diverticulum is that it is a pseudo diverticulum in which the muscularis propria is deficient, and compared with usual colorectal cancer, colon cancer that arises from within the diverticulum progresses more in the direction of the membrane towards the mucosal surface than in the direction of the mucosal surface. Therefore, at the time of detection, the depth of invasion is already above T3 in over 80% (15/18) of cases. Furthermore, infiltration into other organs is not uncommon in T4a cases (4/18 22.2%). As to the histopathological type, there were 5 cases of mucinous carcinoma (5/18, 27%). Since it is generally reported that mucinous carcinoma is seen in 3.5% to 5.1% of colon cancer cases^[21-23], this is a higher rate than in normal colon cancer. Since the histopathological feature of mucinous carcinoma is development to the center of the submucosa, and it is difficult for it to be exposed on the mucosal surface, early detection is difficult. In the case of multiple diverticula, there are cases where the intestinal wall hardens or shortens and the lumen narrows due to chronic inflammation; therefore, detailed observation of mucous membranes is often difficult in colonoscopy. From the above, it was thought that cancers arising from the inside of the diverticulum of the colon are difficult to identify by various examinations and are difficult to detect at an early stage. As a result, it is necessary to always keep in mind the coexistence of colon cancer in patients with colon diverticulosis/diverticulitis.

Colon diverticulosis/diverticulitis is usually diagnosed by first performing abdominal CT examination in most cases. If there is no inflammation and only diverticula exist, careful examination such as colonoscopy cannot be performed. On the other hand, as to whether colonoscopy is necessary for colon diverticulitis found on abdominal CT, some studies^[24-26] have reported that colonoscopy is not necessary for colon diverticulitis without complications, but in cases with complications such as abscess formation and penetration, the possibility of finding colon cancer or polyps increases. Moreover, it has been reported that CT findings of a wall thickness > 6 mm, abscess, lymphadenopathy, localized mass, and obstruction are predictive of malignancy^[27]. One report also noted that patients with CT findings of local perforation, abscess, and fistula have higher odds of malignancy than patients with diverticulitis without complications^[25].

Based on the present case, it was considered important to conduct a detailed examination at the time of colonoscopy. Even when a preoperative diagnosis is made, many cases present with T4 invasion, so treatment requires combined resection. In cases where early detection was possible, even for Tis cases, which are oncologically indicated for endoscopic resection, because it is difficult to safely and completely excise tumorous lesions in diverticula without endoscopically causing perforation, some cases^[15] are treated with combined laparoscopic surgery. In this case, it seems that recurrence could be prevented by performing partial resection of the bladder in addition to fistula resection as initial surgery. However, in the present case, no lesions were seen before surgery, and the presence of cancer was not considered. Moreover, surgery for a colonic urinary bladder fistula due to colon diverticulitis has been performed previously with colon resection and partial resection of the bladder, but recently, partial resection of the bladder has not been considered necessary^[28,29]. From the above two perspectives, partial resection of the bladder was not performed.

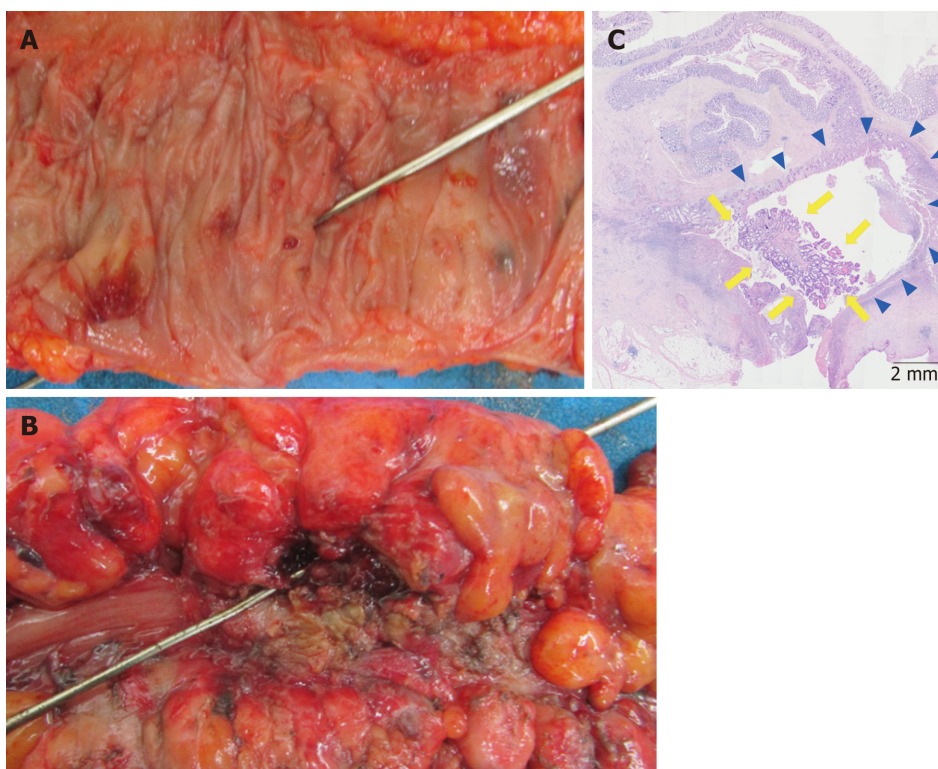


Figure 3 Histopathological examination findings. A, B: Macroscopically, several diverticulum are visible in the colonic lumen, but tumorous lesions around the fistula are not observed; C: Histologically, there is tumor characterized by mild exophytic papillary growth (arrowheads) along the diverticular lumen (arrows). It was diagnosed as well-differentiated adenocarcinoma (HE staining, $\times 100$).

However, in cases of complications of abscess formation and fistula formation of colonic diverticulitis, given the possibility of cancer developing in a colonic diverticulum as in the present case, even in the absence of mass lesions on the luminal side, it is considered necessary to add intraoperative rapid pathologic diagnosis for the fistula.

CONCLUSION

It is difficult to detect cancer arising in a diverticulum of the colon, and it is not easy to differentiate it from complications caused by diverticulitis. Therefore, with this in mind, imaging examinations and surgery are needed.

Table 1 Clinical characteristics of reported cases of colon cancer arising in a colonic diverticulum

Case	Ref.	Yr	Age (yr)/Sex	Symptom	Seen on CT	Seen on CS/CE	Preoperative diagnosis	Tumor site	Operation	TNM (UICC)	Differentiation
1	Tolley <i>et al</i> ^[6]	1967	59/M	Constipation	ND ²	Yes	Diverticulitis	Cecum	Right hemicolectomy	T4N0M0	Mucinous
2	Drut <i>et al</i> ^[7]	1974	84/M	Abdominal pain	ND	No	Diverticulitis	Sigmoid	Left hemicolectomy	T4N3M0	Adenosquamous
3	Hines <i>et al</i> ^[8]	1975	55/F	Abdominal pain	ND	No	Diverticulitis	Descending	Left hemicolectomy	T4N0M0	Mucinous
4	McCrow <i>et al</i> ^[5]	1976	80/M	Hematochezia	ND	No	Diverticulitis	Sigmoid	Sigmoidectomy	T3N0M0	Mucinous
5	Prescott <i>et al</i> ^[9]	1992	89/F	Abdominal pain	ND	No	Giant diverticulum	Sigmoid	Sigmoidectomy	T3N0M0	Well
6	Cohn <i>et al</i> ^[10]	1993	80/M	Abdominal pain	ND	ND	Ileus	Sigmoid	Hartmann operation	T3N0M0	Mucinous
7	Cohn <i>et al</i> ^[10]	1993	61/M	Hematochezia	ND	Yes	Bulky tumor	Sigmoid	Sigmoidectomy	T2N0M0	Well
8	Kajiwarra <i>et al</i> ^[11]	1996	67/M	Hematochezia	No	Yes	Cancer	Ascending	Right hemicolectomy	T3N0M0	Mucinous
9	Kikuchi <i>et al</i> ^[12]	1999	58/F	No symptom	ND	Yes	Tumor	Cecum	Ileocecal resection	TisNxM0	Moderate
10	Bellows <i>et al</i> ^[13]	2002	63/M	Hematochezia	No	No	Vesicosigmoidal fistula	Sigmoid	Sigmoidectomy, Partial resection of the urinary bladder	T4aN0M0	Moderate
11	Van Beyrden <i>et al</i> ^[14]	2008	54/M	ND	No	No	Diverticulitis	Sigmoid	Sigmoidectomy	T4aN2M0	Moderate
12	Fu <i>et al</i> ^[15]	2010	71/M	Hematochezia	ND	Yes	Tumor	Descending	EMR with the assistance of laparoscopy	TisNxM0	Well
13	Merkow <i>et al</i> ^[16]	2011	60/M	Abdominal pain	Yes	No	Bulky tumor	Sigmoid	Sigmoidectomy	T4bN2M0	Poorly
14	Parsyan <i>et al</i> ^[18]	2013	60/M	ND	Yes	Yes	Cancer	Sigmoid	Left hemicolectomy	T3N1M0	Moderate
15	Yagi <i>et al</i> ^[19]	2014	73/M	Hematuria	Yes	Yes	Cancer	Sigmoid	Sigmoidectomy, total resection of the urinary bladder	T4bN0M0	Well
16	Nomi <i>et al</i> ^[20]	2014	64/F	Anemia	Yes	No	Bulky tumor	Transverse	Right hemicolectomy	T4bN0M0	Well
17	Our case	-	76/M	Dysuria	No	No	Vesicosigmoidal fistula	Sigmoid	Laparoscopic sigmoidectomy	T4bN0M0	Well

TNM: Tumor, Node and Metastasis (TNM) classification; ND: Not described; CT: Computed tomography; CS: Colonoscopy; CE: Contrast enema; F: Female; M: Male.

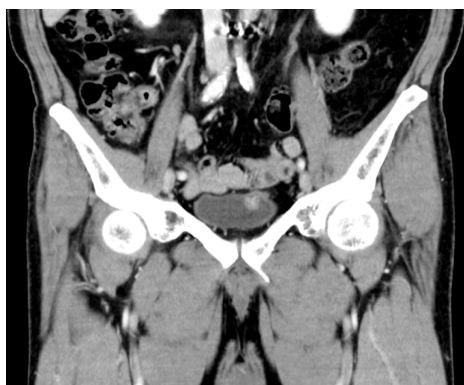

Figure 4 Computed tomography one and a half years after surgery. A tumor lesion about 1 cm in size is seen in the bladder wall.

REFERENCES

- 1 **Jaruvongvanich V**, Sanguankeo A, Wijarnpreecha K, Upala S. Risk of colorectal adenomas, advanced adenomas and cancer in patients with colonic diverticular disease: Systematic review and meta-analysis. *Dig Endosc* 2017; **29**: 73-82 [PMID: 27454544 DOI: 10.1111/den.12701]
- 2 **Kieff BJ**, Eckert GJ, Imperiale TF. Is diverticulosis associated with colorectal neoplasia? A cross-sectional colonoscopic study. *Am J Gastroenterol* 2004; **99**: 2007-2011 [PMID: 15447764 DOI: 10.1111/j.1572-0241.2004.30332.x]
- 3 **Soran A**, Harlak A, Wilson JW, Nesbitt L, Lembersky BC, Wienad HS, O'Connell MJ. Diverticular disease in patients with colon cancer: subgroup analysis of national surgical adjuvant breast and bowel project protocol C-06. *Clin Colorectal Cancer* 2006; **6**: 140-145 [PMID: 16945170 DOI: 10.3816/CCC.2006.n.031]
- 4 **Choi YH**, Koh SJ, Kim JW, Kim BG, Lee KL, Im JP, Kim JS, Jung HC. Do we need colonoscopy following acute diverticulitis detected on computed tomography to exclude colorectal malignancy? *Dig Dis Sci* 2014; **59**: 2236-2242 [PMID: 24723071 DOI: 10.1007/s10620-014-3151-1]
- 5 **McCraw RC**, Wilson SM, Brown FM, Gardner WA. Adenocarcinoma arising in a sigmoid diverticulum: report of a case. *Dis Colon Rectum* 1976; **19**: 553-556 [PMID: 964114 DOI: 10.1007/BF02590952]
- 6 **Tolley JA**. Chronic diverticulitis with perforation and associated carcinoma of the cecum. *Dis Colon Rectum* 1967; **10**: 389-393 [PMID: 6052919 DOI: 10.1007/BF02617025]
- 7 **Drut R**. Adenocarcinoma arising in a diverticulum of the colon: report of a case. *Dis Colon Rectum* 1974; **17**: 258-261 [PMID: 4819277 DOI: 10.1007/BF02588113]
- 8 **Hines JR**, Gordon RT. Adenocarcinoma arising in a diverticular abscess of the colon: report of a case. *Dis Colon Rectum* 1975; **18**: 49-51 [PMID: 165048 DOI: 10.1007/BF02587240]
- 9 **Prescott RJ**, Haboubi NY, Dunaway DJ, Kiff ES. Carcinoma arising in a diverticulum of sigmoid colon. *Histopathology* 1992; **21**: 387-389 [PMID: 1398544 DOI: 10.1111/j.1365-2559.1992.tb00415.x]
- 10 **Cohn KH**, Weimar JA, Fani K, DeSoto-LaPaix F. Adenocarcinoma arising within a colonic diverticulum: report of two cases and review of the literature. *Surgery* 1993; **113**: 223-226 [PMID: 8430371]
- 11 **Kajiwara H**, Umemura S, Mukai M, Sadahiro S, Tsutsumi Y. Adenocarcinoma arising within a colonic diverticulum. *Pathol Int* 1996; **46**: 538-539 [PMID: 8870012 DOI: 10.1111/j.1440-1827.1996.tb03651.x]
- 12 **Kikuchi T**, Kotanagi H, Kon H, Koyama K, Ito S, Otaka M. Mucosal carcinoma within a colonic diverticulum. *J Gastroenterol* 1999; **34**: 622-625 [PMID: 10535492 DOI: 10.1007/s005350050383]
- 13 **Bellows CF**, Haque S. Adenocarcinoma within a diverticulum: a common tumor arising in an uncommon location. *Dig Dis Sci* 2002; **47**: 2758-2759 [PMID: 12498297 DOI: 10.1023/A:1021013423752]
- 14 **van Beurden A**, Baeten CI, Lange CP, Doornwaard H, Tseng LN. Adenocarcinoma Arising within a Colonic Diverticulum in a Patient with Recurrent Diverticulitis. *Clin Med Oncol* 2008; **2**: 529-531 [PMID: 21892327 DOI: 10.4137/CMO.S693]
- 15 **Fu KI**, Hamahata Y, Tsujinaka Y. Early colon cancer within a diverticulum treated by magnifying chromoendoscopy and laparoscopy. *World J Gastroenterol* 2010; **16**: 1545-1547 [PMID: 20333800 DOI: 10.3748/wjg.v16.i12.1545]
- 16 **Merkow RP**, Sun JH. Metastatic adenocarcinoma arising within a diverticulum: endoscopist's nightmare. *Am Surg* 2011; **77**: 109-110 [PMID: 21396317]
- 17 **Anusionwu CC**, Novick DM, Anusionwu NU, Akram S. Malignant Polyp in a Colonic Diverticulum: a Rare Cause of Diverticular Hemorrhage. *J Gastrointest Cancer* 2012; **43** Suppl 1: S104-S107 [PMID: 21952946 DOI: 10.1007/s12029-011-9327-4]
- 18 **Parsyan A**, Cardin MJ, Hassoun H, Andalib A, Tataryn D, Meterissian S, Roy I. Challenging diagnosis of intra-diverticular colonic adenocarcinoma with submucosal localization. *Int J Colorectal Dis* 2013; **28**: 1735-1737 [PMID: 23728595 DOI: 10.1007/s00384-013-1720-y]
- 19 **Yagi Y**, Shoji Y, Sasaki S, Yoshikawa A, Tsukioka Y, Fukushima W, Hirosawa H, Izumi R, Saito K. Sigmoid colon cancer arising in a diverticulum of the colon with involvement of the urinary bladder: a case report and review of the literature. *BMC Gastroenterol* 2014; **14**: 90 [PMID: 24884743 DOI: 10.1186/1471-230X-14-90]
- 20 **Nomi M**, Umemoto S, Kikutake T, Hosaka S, Mase T, Kawamoto S, Yoshida T. [A case of carcinoma arising in a diverticulum of the transverse colon]. *Gan To Kagaku Ryoho* 2014; **41**: 1680-1682 [PMID: 25731294]
- 21 **Greene FL**, Balch CM, Page DL, Haller DG, Fleming ID, Morrow M, Fritz AG. *American Joint Committee on Cancer: Staging Manual*. New York: Springer 2002;
- 22 **Kang H**, O'Connell JB, Maggard MA, Sack J, Ko CY. A 10-year outcomes evaluation of mucinous and signet-ring cell carcinoma of the colon and rectum. *Dis Colon Rectum* 2005; **48**: 1161-1168 [PMID: 16111682 DOI: 10.1007/s10620-005-0111-1]

- 15868237 DOI: [10.1007/s10350-004-0932-1](https://doi.org/10.1007/s10350-004-0932-1)]
- 23 **Pande R**, Sunga A, Levea C, Wilding GE, Bshara W, Reid M, Fakhri MG. Significance of signet-ring cells in patients with colorectal cancer. *Dis Colon Rectum* 2008; **51**: 50-55 [PMID: [18030531](https://pubmed.ncbi.nlm.nih.gov/18030531/) DOI: [10.1007/s10350-007-9073-7](https://doi.org/10.1007/s10350-007-9073-7)]
- 24 **Suhardja TS**, Norhadi S, Seah EZ, Rodgers-Wilson S. Is early colonoscopy after CT-diagnosed diverticulitis still necessary? *Int J Colorectal Dis* 2017; **32**: 485-489 [PMID: [28035461](https://pubmed.ncbi.nlm.nih.gov/28035461/) DOI: [10.1007/s00384-016-2749-5](https://doi.org/10.1007/s00384-016-2749-5)]
- 25 **Lau KC**, Spilsbury K, Farooque Y, Kariyawasam SB, Owen RG, Wallace MH, Makin GB. Is colonoscopy still mandatory after a CT diagnosis of left-sided diverticulitis: can colorectal cancer be confidently excluded? *Dis Colon Rectum* 2011; **54**: 1265-1270 [PMID: [21904141](https://pubmed.ncbi.nlm.nih.gov/21904141/) DOI: [10.1097/DCR.0b013e31822899a2](https://doi.org/10.1097/DCR.0b013e31822899a2)]
- 26 **Andrade P**, Ribeiro A, Ramalho R, Lopes S, Macedo G. Routine Colonoscopy after Acute Uncomplicated Diverticulitis - Challenging a Putative Indication. *Dig Surg* 2017; **34**: 197-202 [PMID: [27941344](https://pubmed.ncbi.nlm.nih.gov/27941344/) DOI: [10.1159/000449259](https://doi.org/10.1159/000449259)]
- 27 **Elmi A**, Hedgire SS, Pargaonkar V, Cao K, McDermott S, Harisinghani M. Is early colonoscopy beneficial in patients with CT-diagnosed diverticulitis? *AJR Am J Roentgenol* 2013; **200**: 1269-1274 [PMID: [23701063](https://pubmed.ncbi.nlm.nih.gov/23701063/) DOI: [10.2214/AJR.12.9539](https://doi.org/10.2214/AJR.12.9539)]
- 28 **Royds J**, O'Riordan JM, Eguare E, O'Riordan D, Neary PC. Laparoscopic surgery for complicated diverticular disease: a single-centre experience. *Colorectal Dis* 2012; **14**: 1248-1254 [PMID: [22182066](https://pubmed.ncbi.nlm.nih.gov/22182066/) DOI: [10.1111/j.1463-1318.2011.02924.x](https://doi.org/10.1111/j.1463-1318.2011.02924.x)]
- 29 **Cirocchi R**, Arezzo A, Renzi C, Cochetti G, D'Andrea V, Fingerhut A, Mearini E, Binda GA. Is laparoscopic surgery the best treatment in fistulas complicating diverticular disease of the sigmoid colon? A systematic review. *Int J Surg* 2015; **24**: 95-100 [PMID: [26584958](https://pubmed.ncbi.nlm.nih.gov/26584958/) DOI: [10.1016/j.ijssu.2015.11.007](https://doi.org/10.1016/j.ijssu.2015.11.007)]



Published By Baishideng Publishing Group Inc
7041 Koll Center Parkway, Suite 160, Pleasanton, CA 94566, USA
Telephone: +1-925-2238242
Fax: +1-925-2238243
E-mail: bpgoffice@wjgnet.com
Help Desk: <https://www.f6publishing.com/helpdesk>
<https://www.wjgnet.com>

