

World Journal of *Clinical Cases*

World J Clin Cases 2019 July 6; 7(13): 1535-1731



**REVIEW**

- 1535** Intracranial pressure monitoring: Gold standard and recent innovations
Nag DS, Sahu S, Swain A, Kant S

- 1554** Role of the brain-gut axis in gastrointestinal cancer
Di YZ, Han BS, Di JM, Liu WY, Tang Q

MINIREVIEWS

- 1571** Cholestatic liver diseases: An era of emerging therapies
Samant H, Manatsathit W, Dies D, Shokouh-Amiri H, Zibari G, Boktor M, Alexander JS

ORIGINAL ARTICLE**Basic Study**

- 1582** Neural metabolic activity in idiopathic tinnitus patients after repetitive transcranial magnetic stimulation
Kan Y, Wang W, Zhang SX, Ma H, Wang ZC, Yang JG

Retrospective Study

- 1591** Neuroendoscopic and microscopic transsphenoidal approach for resection of nonfunctional pituitary adenomas
Ding ZQ, Zhang SF, Wang QH

- 1599** Safety and efficacy of transjugular intrahepatic portosystemic shunt combined with palliative treatment in patients with hepatocellular carcinoma
Luo SH, Chu JG, Huang H, Yao KC

- 1611** Leveraging machine learning techniques for predicting pancreatic neuroendocrine tumor grades using biochemical and tumor markers
Zhou RQ, Ji HC, Liu Q, Zhu CY, Liu R

Clinical Trials Study

- 1623** Development and validation of a model to determine risk of refractory benign esophageal strictures
Lu Q, Lei TT, Wang YL, Yan HL, Lin B, Zhu LL, Ma HS, Yang JL

SYSTEMATIC REVIEWS

- 1634** Hydatid cyst of the colon: A systematic review of the literature
Lataat-Córdoba MÁ, Ruiz-Blanco S, Sanchez M, Santiago-Boyer C, Soto-García P, Sun W, Ramia JM

CASE REPORT

- 1643** Colon cancer arising from colonic diverticulum: A case report
Kayano H, Ueda Y, Machida T, Hiraiwa S, Zakoji H, Tajiri T, Mukai M, Nomura E
- 1652** Endoscopic submucosal dissection as excisional biopsy for anorectal malignant melanoma: A case report
Manabe S, Boku Y, Takeda M, Usui F, Hirata I, Takahashi S
- 1660** Gastrointestinal infection-related disseminated intravascular coagulation mimicking Shiga toxin-mediated hemolytic uremic syndrome - implications of classical clinical indexes in making the diagnosis: A case report and literature review
Li XY, Mai YF, Huang J, Pai P
- 1671** A complicated case of innominate and right common arterial aneurysms due to Takayasu's arteritis
Wang WD, Sun R, Zhou MX, Liu XR, Zheng YH, Chen YX
- 1677** Multimodality-imaging manifestations of primary renal-allograft synovial sarcoma: First case report and literature review
Xu RF, He EH, Yi ZX, Lin J, Zhang YN, Qian LX
- 1686** Chronic progression of recurrent orthokeratinized odontogenic cyst into squamous cell carcinoma: A case report
Wu RY, Shao Z, Wu TF
- 1696** Gastric adenocarcinoma of fundic gland type after *Helicobacter pylori* eradication: A case report
Yu YN, Yin XY, Sun Q, Liu H, Zhang Q, Chen YQ, Zhao QX, Tian ZB
- 1703** Synchronous multiple primary gastrointestinal cancers with *CDH1* mutations: A case report
Hu MN, Lv W, Hu RY, Si YF, Lu XW, Deng YJ, Deng H
- 1711** Primary hepatoid adenocarcinoma of the lung in Yungui Plateau, China: A case report
Shi YF, Lu JG, Yang QM, Duan J, Lei YM, Zhao W, Liu YQ
- 1717** Liver failure associated with benzbromarone: A case report and review of the literature
Zhang MY, Niu JQ, Wen XY, Jin QL
- 1726** Giant low-grade appendiceal mucinous neoplasm: A case report
Yang JM, Zhang WH, Yang DD, Jiang H, Yu L, Gao F

ABOUT COVER

Editorial Board Member of *World Journal of Clinical Cases*, Hitoshi Hirose, MD, PhD, Associate Professor, Department of Cardiothoracic Surgery, Thomas Jefferson University, Philadelphia, PA 19107, United States

AIMS AND SCOPE

World Journal of Clinical Cases (*World J Clin Cases*, *WJCC*, online ISSN 2307-8960, DOI: 10.12998) is a peer-reviewed open access academic journal that aims to guide clinical practice and improve diagnostic and therapeutic skills of clinicians.

The primary task of *WJCC* is to rapidly publish high-quality Case Report, Clinical Management, Editorial, Field of Vision, Frontier, Medical Ethics, Original Articles, Meta-Analysis, Minireviews, and Review, in the fields of allergy, anesthesiology, cardiac medicine, clinical genetics, clinical neurology, critical care, dentistry, dermatology, emergency medicine, endocrinology, family medicine, gastroenterology and hepatology, etc.

INDEXING/ABSTRACTING

The *WJCC* is now indexed in PubMed, PubMed Central, Science Citation Index Expanded (also known as SciSearch®), and Journal Citation Reports/Science Edition. The 2019 Edition of Journal Citation Reports cites the 2018 impact factor for *WJCC* as 1.153 (5-year impact factor: N/A), ranking *WJCC* as 99 among 160 journals in Medicine, General and Internal (quartile in category Q3).

RESPONSIBLE EDITORS FOR THIS ISSUE

Responsible Electronic Editor: *Yan-Xia Xing*

Proofing Production Department Director: *Yun-Xiaojuan Wu*

NAME OF JOURNAL

World Journal of Clinical Cases

ISSN

ISSN 2307-8960 (online)

LAUNCH DATE

April 16, 2013

FREQUENCY

Semimonthly

EDITORS-IN-CHIEF

Dennis A Bloomfield, Sandro Vento

EDITORIAL BOARD MEMBERS

<https://www.wjnet.com/2307-8960/editorialboard.htm>

EDITORIAL OFFICE

Jin-Lei Wang, Director

PUBLICATION DATE

July 6, 2019

COPYRIGHT

© 2019 Baishideng Publishing Group Inc

INSTRUCTIONS TO AUTHORS

<https://www.wjnet.com/bpg/gerinfo/204>

GUIDELINES FOR ETHICS DOCUMENTS

<https://www.wjnet.com/bpg/GerInfo/287>

GUIDELINES FOR NON-NATIVE SPEAKERS OF ENGLISH

<https://www.wjnet.com/bpg/gerinfo/240>

PUBLICATION MISCONDUCT

<https://www.wjnet.com/bpg/gerinfo/208>

ARTICLE PROCESSING CHARGE

<https://www.wjnet.com/bpg/gerinfo/242>

STEPS FOR SUBMITTING MANUSCRIPTS

<https://www.wjnet.com/bpg/GerInfo/239>

ONLINE SUBMISSION

<https://www.f6publishing.com>

A complicated case of innominate and right common arterial aneurysms due to Takayasu's arteritis

Wen-Da Wang, Rui Sun, Meng-Xin Zhou, Xing-Rong Liu, Yue-Hong Zheng, Yue-Xin Chen

ORCID number: Wen-Da Wang (0000-0003-0955-2912); Rui Sun (0000-0003-3718-5849); Meng-Xin Zhou (0000-0003-1922-0508); Xing-Rong Liu (0000-0002-0749-1469); Yue-Hong Zheng (0000-0002-0704-5469); Yue-Xin Chen (0000-0002-2011-3083).

Author contributions: Chen YX and Liu XY performed the operation; Wang WD collected the case data and drafted the article; Sun R and Zhou MX consulted literature material; Chen YX and Zheng YH made critical revisions to the manuscript.

Informed consent statement: Consent was obtained from the patient for publication of this report and any accompanying images.

Conflict-of-interest statement: The authors have no conflicts of interest to declare.

CARE Checklist (2016) statement: CARE Checklist (2016) statement has been uploaded.

Open-Access: This article is an open-access article which was selected by an in-house editor and fully peer-reviewed by external reviewers. It is distributed in accordance with the Creative Commons Attribution Non Commercial (CC BY-NC 4.0) license, which permits others to distribute, remix, adapt, build upon this work non-commercially, and license their derivative works on different terms, provided the original work is properly cited and the use is non-commercial. See: <http://creativecommons.org/licenses/by-nc/4.0/>

Wen-Da Wang, Rui Sun, Meng-Xin Zhou, Yue-Hong Zheng, Yue-Xin Chen, Department of Vascular Surgery, Peking Union Medical College Hospital, Chinese Academy of Medical Sciences and Peking Union Medical College, Beijing 100730, China

Xing-Rong Liu, Department of Cardiac Surgery, Peking Union Medical College Hospital, Chinese Academy of Medical Sciences and Peking Union Medical College, Beijing 100730, China

Corresponding author: Yue-Xin Chen, MD, Department of Vascular Surgery, Peking Union Medical College Hospital, No. 1, Shuaifuyuan, Dongcheng District, Beijing 100730, China. chenyuexin@pumch.cn

Telephone: +86-10-69152501

Fax: +86-10-69152501

Abstract

BACKGROUND

Innominate artery aneurysms (IAAs) are relatively rare. Endovascular therapy has been an alternative to open surgery in some IAA cases, but open repair is still necessary in complicated cases.

CASE SUMMARY

We report a 35-year-old female who suffered from Takayasu's arteritis. The patient did not get regular treatment, and IAA and right common carotid artery aneurysm developed, which complicated with occlusion of the left carotid artery, subclavian artery, and the initial part of the left vertebral artery. The patient also had moderate aortic valve insufficiency. With inflammation being controlled well, the patient received the surgery for arterial aneurysms of innominate and right common carotid arteries and aortic valve insufficiency. The shunts for cerebral blood supply were designed to protect the brain and the surgery was conducted successfully under extracorporeal circulation.

CONCLUSION

The case illustrates that open surgery may be appropriate for some complicated IAAs, and brain protection is important.

Key words: Case report; Innominate artery aneurysm; Takayasu's arteritis; Shunts; Brain protection

©The Author(s) 2019. Published by Baishideng Publishing Group Inc. All rights reserved.

ses/by-nc/4.0/

Manuscript source: Unsolicited Manuscript

Received: February 13, 2019

Peer-review started: February 15, 2019

First decision: March 8, 2019

Revised: March 15, 2019

Accepted: May 1, 2019

Article in press: May 1, 2019

Published online: July 6, 2019

P-Reviewer: Kai K

S-Editor: Ma YJ

L-Editor: Wang TQ

E-Editor: Wang J



Core tip: This is a very interesting case of Takayasu's arteritis, which is a relatively rare reason for innominate artery aneurysm. The patient had innominate artery and right carotid artery aneurysms. The patient also suffered from occlusion of the left carotid artery, subclavian artery, and the initial part of the left vertebral artery. The condition of aortic valve insufficiency also increased the difficulty of the surgery.

Citation: Wang WD, Sun R, Zhou MX, Liu XR, Zheng YH, Chen YX. A complicated case of innominate and right common arterial aneurysms due to Takayasu's arteritis. *World J Clin Cases* 2019; 7(13): 1671-1676

URL: <https://www.wjgnet.com/2307-8960/full/v7/i13/1671.htm>

DOI: <https://dx.doi.org/10.12998/wjcc.v7.i13.1671>

INTRODUCTION

Innominate artery aneurysms (IAAs) are rare and account for only 3% of supra-aortic arterial aneurysms^[1]. The complications of IAA include rupture, embolization, and compression of adjacent structures. Surgery may be recommended in IAA patients to prevent the complications^[2]. Endovascular therapy has been an alternative to open surgery in some IAA cases^[2,3], but open repair is still necessary in complicated cases. We herein report a successful open surgery for a particular patient with IAA due to Takayasu's arteritis.

CASE PRESENTATION

Chief complaints

Chest distress and hard breath for about 4 mo.

History of present illness

A 35-year-old woman who suffered from chest distress and hard breath for about 4 mo came to our hospital on June 20, 2018. She was diagnosed with Takayasu's arteritis 10 years ago and did not get regular treatment. She began to take prednisone orally about half a year ago. An ultrasound scan at local hospital revealed a right carotid aneurysm. The patient came to our hospital and computed tomography angiography (CTA) revealed that the innominate and right common carotid arteries formed aneurysms with occlusion of multiple contralateral cervical arteries. Echocardiography revealed moderate aortic valve insufficiency.

History of past illness

Takayasu's arteritis for 10 years.

Physical examination

A 3 cm × 1 cm pulsatile mass was found on the right side of the neck, and vascular murmurs could be heard. No left carotid or radial pulse was felt. Diastolic murmurs were heard in the aortic valve area.

Laboratory examinations

Routine blood test and parameters of hepatorenal function and coagulation function were within normal ranges. The white blood count was $6.70 \times 10^9/L$, red blood cell count was $4.28 \times 10^{12}/L$, and hemoglobin was 127 g/L. The cTnI was 0.017 µg/L, and NT-proBNP was 830 pg/mL. The inflammation markers were also in normal limits, with ESR being 12 mm/h, and hsCRP being 0.32 mg/L.

Imaging examinations

CTA revealed that the innominate and right common carotid arteries formed aneurysms (the maximum cross-section diameter was 3.3 cm and 1.6 cm, respectively) (Figure 1). The left common carotid, internal carotid, subclavian artery, and initial part of the left vertebral artery were occlusive. The right vertebral artery displayed well with patency of anterior and posterior communicating arteries.

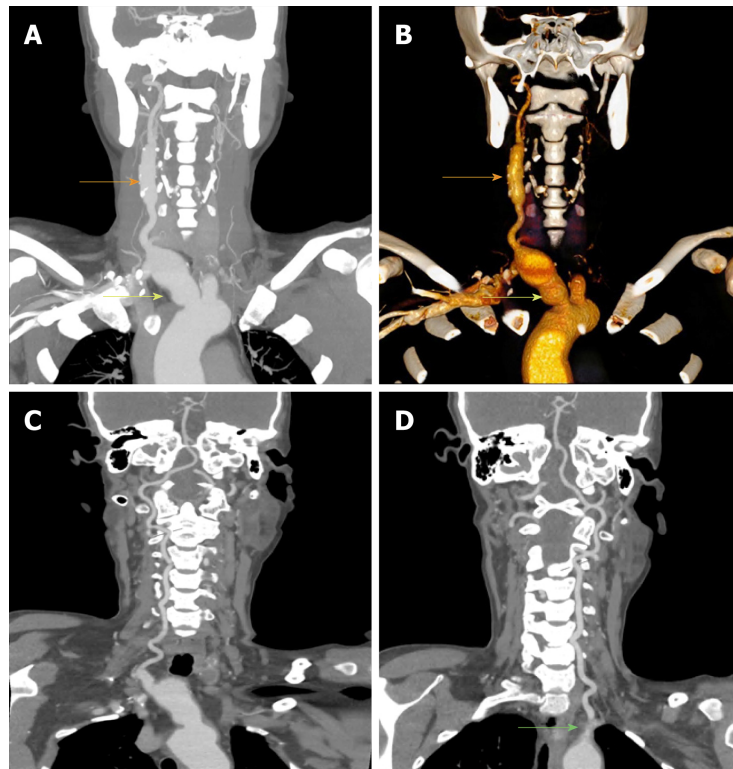


Figure 1 Preoperative computed tomography angiography of the patient. A and B: Innominate (yellow arrow) and right common carotid (orange arrow) arterial aneurysms and no display of the left carotid and subclavian arteries; C: Patency of the right vertebral artery; D: Occlusion of the initial part of the left vertebral artery (green arrow).

FINAL DIAGNOSIS

The patient had innominate and right common carotid artery aneurysms with occlusion of the left common carotid, internal carotid, subclavian, and vertebral arteries. The patient also had aortic valve insufficiency. The etiology was considered as Takayasu's arteritis.

TREATMENT

A multiple disciplinary team (MDT) discussion was performed. The key issues for surgery were considered as below: (1) How to control inflammation during the perioperative period? (2) Should the aortic valve insufficiency be resolved in the same-stage surgery? and (3) The most important question is how to realize cerebral protection?

Inflammation was controlled by taking prednisone 10 mg/d orally before operation, and the prednisone was replaced by hydrocortisone on the operation day (50 mg q8h i.v.) and the first postoperative day (100 mg q12h i.v.). The surgery was performed by doctors of Vascular and Cardiac Surgery Department together. Ice-cap was used, and electroencephalogram (EEG) and cerebral oxygen monitoring were performed. Cardiopulmonary bypass was established routinely. Then a Φ 8 mm prosthesis was end-to-side anastomosed with the right axillary artery, and the prosthesis was connected with the outflow tract of an extracorporeal circulation machine. A catheter sheath was placed in the right femoral artery and was also connected with the outflow tract of the extracorporeal circulation machine. Both the two pathways were prepared for aneurysm resection. After performing the aortic valve replacement during cardiac pulmonary bypass, aneurysm resection and vascular reconstruction were conducted. The end of a 14 mm \times 7 mm \times 7 mm Y-shape artificial vessel was connected with the aortic arch (end-to-side). Then, the root of the innominate artery was blocked with an aorta side wall clamp, and the innominate artery was cut off at the initial part. The broken end of aorta side was sutured. During this stage, the blood supply for the right carotid and vertebral arteries was from the pathway of the right axillary artery. Whereafter, a shunt tube was placed into the right common carotid artery distally to the carotid aneurysm. The shunt tube was

connected to the catheter sheath of the femoral artery using a connecting tube. So the shunt to the right carotid artery was established. Then, the carotid artery was cut off at the distal end of the carotid aneurysm. The innominate and carotid arterial aneurysms were excised. The distal end of the common carotid artery was sutured to one 7 mm end of the artificial vessel. The shunt tube was pulled out at the end of anastomosis. Then, cardiopulmonary bypass was stopped and the distal end of the subclavian artery was connected to another 7 mm end of the artificial vessel. The pathways of the right axillary artery and femoral artery were removed. Then, the incisions were sutured with placement of drain tubes. The final pathology showed chronic inflammation of vascular wall with hyaline and mucinous degeneration of both vascular wall and aortic valve (Figure 2).

OUTCOME AND FOLLOW-UP

The patient was discharged without complications on the 18th day after operation. The patient had no complaints of dyspnea or chest stuffy at one month after discharge from hospital. The CTA revealed patency of artificial innominate and right carotid arteries (Figure 3), and echocardiography presented no relapse of aortic valvular regurgitation. The patient continued treatment of prednisone orally (10 mg daily) and the re-examination of ESR was 12 mm/h.

DISCUSSION

About 1%-3% of all arterial aneurysms are IAAs^[1,4]. IAAs are mainly caused by atherosclerosis recently, and other causes include infections (syphilis, tuberculosis, *etc.*), immune diseases (Kawasaki disease, Takayasu's arteritis, Behçet disease, Marfan syndrome, *etc.*), angiosarcoma, and trauma^[2,5]. Wang *et al*^[3] reviewed the literature and reported that only 8/120 (7.2%) of IAAs resulted from Takayasu's arteritis. The common clinical manifestations include distal embolization and thrombosis, compression of adjacent structures, and spontaneous rupture^[2,6]. The indications for surgery include ruptured and symptomatic aneurysms, and asymptomatic aneurysms with a saccular appearance or a maximum transverse diameter > 3 cm^[6].

Kieffer *et al*^[6] divided IAAs into three categories: group A, no involvement of origin of the innominate artery; group B, involvement of origin of the innominate artery but not of the aorta; group C, involvement of both the innominate artery and aorta. And our case should be classified into group B. The different involvement conditions need distinct surgical treatment techniques, including lateral suture of the aorta, patch angioplasty of the aorta, replacement of the ascending aorta, and replacement of the ascending aorta and transverse aortic arch in association with distal elephant trunk prosthesis. Endovascular repair has been a considerable alternative to conventional surgical therapy, which generally needs median sternotomy and even cardiopulmonary bypass. When reviewing the literature, two reports were found to analyze the IAA patients due to Takayasu's arteritis. Kieffer *et al*^[6] reported 27 IAA patients in 2001, among whom seven were due to Takayasu's arteritis. Traditional surgical repairs were performed in these patients. The authors mentioned distal bypass graft anastomosis to the right subclavian artery in two patients with extensive right carotid occlusion, and to the right common carotid artery in one with axillosubclavian artery occlusion. Angiletta *et al*^[2] reported a female patient who received stent graft repair for IAA, and the stent was still patent with complete thrombosis of the aneurysmal sac when she came back for reexamination 8 years later.

When considering our patient, it was hard to perform endovascular repair because the patient also had occlusive lesions in the left side. So temporary balloon block of the right side during endovascular therapy was dangerous and might lead to cerebral ischemia. The only way to resolve the problem was to design reasonable temporal shunts. We established two pathways for blood supply to the right carotid and vertebral arteries successively, and successfully realized brain protection. On the other hand, the patient also had aortic valvular regurgitation which also had indication for treatment, and re-thoracotomy might be much more difficult.

For the etiology of this case is Takayasu's arteritis, perioperative inflammation control is crucial. Except for emergency conditions, the surgery should be performed until the inflammation is controlled to reduce the risk of complications, including restenosis, thrombosis, anastomotic failure, and pseudoaneurysm formation^[2]. The postoperative long-term control of inflammation is also necessary. On the other hand, prompt and regular treatment for Takayasu's arteritis is important to avoid severe vascular lesions. The patient should receive continuous follow-up to ensure regular

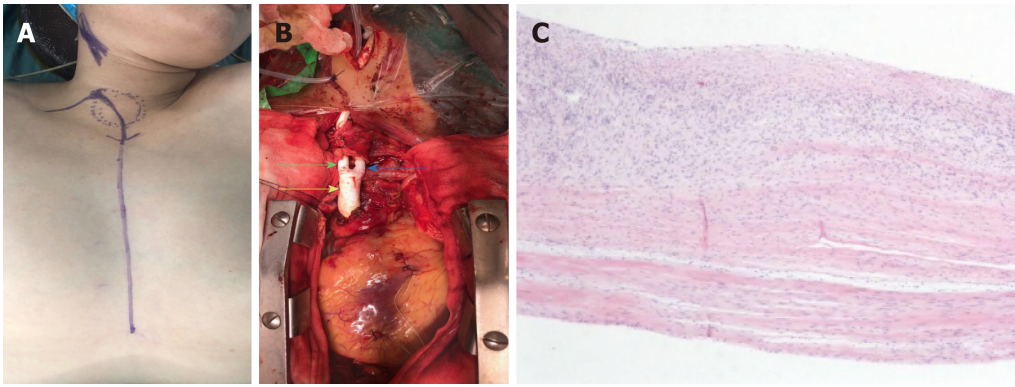


Figure 2 Macroscopic photograph of surgery and hematoxylin-eosin staining of vascular tissue. A: The main thoracic incision; B: The replaced artificial vessel (green arrow: subclavian end; blue arrow: carotid end; yellow arrow: aortic end); C: Hematoxylin-eosin staining of vascular tissue excised.

anti-inflammatory therapy and to evaluate long-term outcome of the surgery.

CONCLUSION

In conclusion, we report a rare case of innominate and right common arterial aneurysms due to Takayasu's arteritis which was successfully treated by well-considered surgical strategy. Open surgery may be more appropriate for complicated IAAs such as our case, and brain protection is important during surgery.

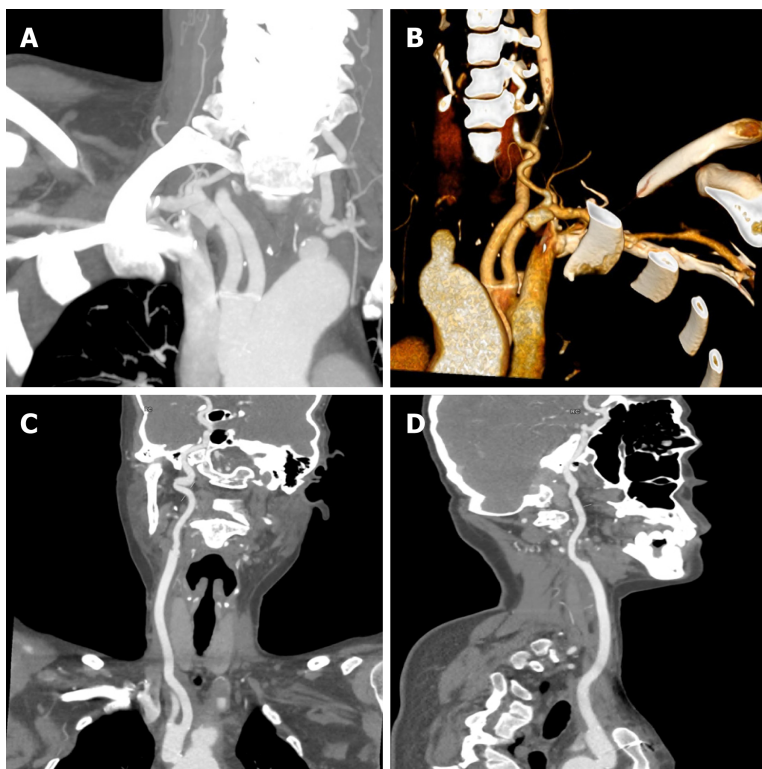


Figure 3 Computed tomography angiography images obtained 1 mo after surgery demonstrating patency of the artificial vessel with no dilatation.

REFERENCES

- 1 Cury M, Greenberg RK, Morales JP, Mohabbat W, Hernandez AV. Supra-aortic vessels aneurysms: diagnosis and prompt intervention. *J Vasc Surg* 2009; **49**: 4-10 [PMID: [19174249](#) DOI: [10.1016/j.jvs.2008.08.088](#)]
- 2 Angiletta D, Marinazzo D, Guido G, Fullone M, Pulli R, Regina G. Eight-year follow-up of endovascular repair of a brachiocephalic trunk aneurysm due to Takayasu's arteritis. *J Vasc Surg* 2012; **56**: 504-507 [PMID: [22554423](#) DOI: [10.1016/j.jvs.2012.02.031](#)]
- 3 Wang XL, Guan XL, Jiang WJ, Liu O, Zhang HJ. Innominate artery aneurysm, how to solve it? *J Int Med Res* 2017; **45**: 1279-1284 [PMID: [28553761](#) DOI: [10.1177/0300060517711087](#)]
- 4 Chambers CM, Curci JA. Treatment of nonaortic aneurysms in the endograft era: aneurysms of the innominate and subclavian arteries. *Semin Vasc Surg* 2005; **18**: 184-190 [PMID: [16360574](#) DOI: [10.1053/j.semvascsurg.2005.09.003](#)]
- 5 Soylu E, Harling L, Ashrafian H, Anagnostakou V, Tassopoulos D, Charitos C, Kokotsakis J, Athanasiou T. Surgical treatment of innominate artery and aortic aneurysm: a case report and review of the literature. *J Cardiothorac Surg* 2013; **8**: 141 [PMID: [23725538](#) DOI: [10.1186/1749-8090-8-141](#)]
- 6 Kieffer E, Chiche L, Koskas F, Bahnini A. Aneurysms of the innominate artery: surgical treatment of 27 patients. *J Vasc Surg* 2001; **34**: 222-228 [PMID: [11496272](#) DOI: [10.1067/mva.2001.115807](#)]



Published By Baishideng Publishing Group Inc
7041 Koll Center Parkway, Suite 160, Pleasanton, CA 94566, USA
Telephone: +1-925-2238242
Fax: +1-925-2238243
E-mail: bpgoffice@wjgnet.com
Help Desk: <https://www.f6publishing.com/helpdesk>
<https://www.wjgnet.com>

