

# World Journal of *Clinical Cases*

*World J Clin Cases* 2019 September 26; 7(18): 2658-2915



**OPINION REVIEW**

- 2658** Effective use of the Japan Narrow Band Imaging Expert Team classification based on diagnostic performance and confidence level  
*Hirata D, Kashida H, Iwatate M, Tochio T, Teramoto A, Sano Y, Kudo M*

**MINIREVIEWS**

- 2666** Low fermentable oligosaccharides, disaccharides, monosaccharides, and polyols diet in children  
*Fodor I, Man SC, Dumitrascu DL*
- 2675** High-resolution colonic manometry and its clinical application in patients with colonic dysmotility: A review  
*Li YW, Yu YJ, Fei F, Zheng MY, Zhang SW*

**ORIGINAL ARTICLE****Retrospective Study**

- 2687** Predictors of rebleeding and in-hospital mortality in patients with nonvariceal upper digestive bleeding  
*Lazăr DC, Ursoniu S, Goldiș A*
- 2704** Analgesic effect of parecoxib combined with ropivacaine in patients undergoing laparoscopic hepatectomy  
*Huang SS, Lv WW, Liu YF, Yang SZ*
- 2712** Prognostic significance of 14v-lymph node dissection to D2 dissection for lower-third gastric cancer  
*Zheng C, Gao ZM, Sun AQ, Huang HB, Wang ZN, Li K, Gao S*

**Observational Study**

- 2722** Wall shear stress can improve prediction accuracy for transient ischemic attack  
*Liu QY, Duan Q, Fu XH, Jiang M, Xia HW, Wan YL*

**Prospective Study**

- 2734** Characterization of microbiota in systemic-onset juvenile idiopathic arthritis with different disease severities  
*Dong YQ, Wang W, Li J, Ma MS, Zhong LQ, Wei QJ, Song HM*

**SYSTEMATIC REVIEWS**

- 2746** Sinusoidal obstruction syndrome: A systematic review of etiologies, clinical symptoms, and magnetic resonance imaging features  
*Zhang Y, Jiang HY, Wei Y, Song B*

**META-ANALYSIS**

- 2760** Respiratory training interventions improve health status of heart failure patients: A systematic review and network meta-analysis of randomized controlled trials  
*Wang MH, Yeh ML*

**CASE REPORT**

- 2776** *Mycobacterium chimaera* infections following cardiac surgery in Treviso Hospital, Italy, from 2016 to 2019: Cases report  
*Inojosa WO, Giobbia M, Muffato G, Minniti G, Baldasso F, Carniato A, Farina F, Forner G, Rossi MC, Formentini S, Rigoli R, Scotton PG*
- 2787** Giant squamous cell carcinoma of the gallbladder: A case report  
*Junior MAR, Favaro MDL, Santin S, Silva CM, Iamarino APM*
- 2794** Liver re-transplantation for donor-derived neuroendocrine tumor: A case report  
*Mrzljak A, Kocman B, Skrtic A, Furac I, Popic J, Franusic L, Zunec R, Mayer D, Mikulic D*
- 2802** Calcifying fibrous tumor originating from the gastrohepatic ligament that mimicked a gastric submucosal tumor: A case report  
*Kwan BS, Cho DH*
- 2808** Pancreatitis, panniculitis, and polyarthritis syndrome caused by pancreatic pseudocyst: A case report  
*Jo S, Song S*
- 2815** Glomus tumor of uncertain malignant potential of the brachial plexus: A case report  
*Thanindrarn P, Chobpenthai T, Phorkhar T, Nelson SD*
- 2823** Conservative pulp treatment for Oehlers type III dens invaginatus: A case report  
*Lee HN, Chen YK, Chen CH, Huang CY, Su YH, Huang YW, Chuang FH*
- 2831** Propofol pump controls nonconvulsive status epilepticus in a hepatic encephalopathy patient: A case report  
*Hor S, Chen CY, Tsai ST*
- 2838** Teriparatide as nonoperative treatment for femoral shaft atrophic nonunion: A case report  
*Tsai MH, Hu CC*
- 2843** Successful repair of acute type A aortic dissection during pregnancy at 16<sup>th</sup> gestational week with maternal and fetal survival: A case report and review of the literature  
*Chen SW, Zhong YL, Ge YP, Qiao ZY, Li CN, Zhu JM, Sun LZ*
- 2851** Inferior pancreaticoduodenal artery pseudoaneurysm in a patient with calculous cholecystitis: A case report  
*Xu QD, Gu SG, Liang JH, Zheng SD, Lin ZH, Zhang PD, Yan J*

- 2857** ALK-positive anaplastic large cell lymphoma of the thoracic spine occurring in pregnancy: A case report  
*Yang S, Jiang WM, Yang HL*
- 2864** Endoscopic mucosal resection of a bile duct polyp: A case report  
*Yang S, Yang L, Wang XY, Yang YM*
- 2871** Multiple gastric adenocarcinoma of fundic gland type: A case report  
*Chen O, Shao ZY, Qiu X, Zhang GP*
- 2879** Repair of the portal vein using a hepatic ligamentum teres patch for laparoscopic pancreatoduodenectomy: A case report  
*Wei Q, Chen QP, Guan QH, Zhu WT*
- 2888** Drug coated balloon angioplasty for renal artery stenosis due to Takayasu arteritis: Report of five cases  
*Bi YH, Ren JZ, Yi MF, Li JD, Han XW*
- 2894** Entrapment of the temporal horn secondary to postoperative gamma-knife radiosurgery in intraventricular meningioma: A case report  
*Liu J, Long SR, Li GY*
- 2899** Pleomorphic lipoma in the anterior mediastinum: A case report  
*Mao YQ, Liu XY, Han Y*
- 2905** Guillain-Barré syndrome in a patient with multiple myeloma after bortezomib therapy: A case report  
*Xu YL, Zhao WH, Tang ZY, Li ZQ, Long Y, Cheng P, Luo J*
- 2910** Bowen's disease on the palm: A case report  
*Yu SR, Zhang JZ, Pu XM, Kang XJ*

**ABOUT COVER**

Editorial Board Member of *World Journal of Clinical Cases*, Shao-Ping Yu, MD, Associate Professor, Chief Doctor, Department of Gastroenterology and Hepatology, Dongguan Kanghua Hospital, Dongguan 523080, Guangdong Province, China

**AIMS AND SCOPE**

The primary aim of *World Journal of Clinical Cases* (*WJCC*, *World J Clin Cases*) is to provide scholars and readers from various fields of clinical medicine with a platform to publish high-quality clinical research articles and communicate their research findings online.

*WJCC* mainly publishes case reports, case series, and articles reporting research results and findings obtained in the field of clinical medicine and covering a wide range of topics including diagnostic, therapeutic, and preventive modalities.

**INDEXING/ABSTRACTING**

The *WJCC* is now indexed in PubMed, PubMed Central, Science Citation Index Expanded (also known as SciSearch®), and Journal Citation Reports/Science Edition. The 2019 Edition of Journal Citation Reports cites the 2018 impact factor for *WJCC* as 1.153 (5-year impact factor: N/A), ranking *WJCC* as 99 among 160 journals in Medicine, General and Internal (quartile in category Q3).

**RESPONSIBLE EDITORS FOR THIS ISSUE**

Responsible Electronic Editor: Ji-Hong Liu

Proofing Production Department Director: Yun-Xiaoqian Wu

**NAME OF JOURNAL**

*World Journal of Clinical Cases*

**ISSN**

ISSN 2307-8960 (online)

**LAUNCH DATE**

April 16, 2013

**FREQUENCY**

Semimonthly

**EDITORS-IN-CHIEF**

Dennis A Bloomfield, Bao-Gan Peng, Sandro Vento

**EDITORIAL BOARD MEMBERS**

<https://www.wjgnet.com/2307-8960/editorialboard.htm>

**EDITORIAL OFFICE**

Jin-Lei Wang, Director

**PUBLICATION DATE**

September 26, 2019

**COPYRIGHT**

© 2019 Baishideng Publishing Group Inc

**INSTRUCTIONS TO AUTHORS**

<https://www.wjgnet.com/bpg/gerinfo/204>

**GUIDELINES FOR ETHICS DOCUMENTS**

<https://www.wjgnet.com/bpg/GerInfo/287>

**GUIDELINES FOR NON-NATIVE SPEAKERS OF ENGLISH**

<https://www.wjgnet.com/bpg/gerinfo/240>

**PUBLICATION MISCONDUCT**

<https://www.wjgnet.com/bpg/gerinfo/208>

**ARTICLE PROCESSING CHARGE**

<https://www.wjgnet.com/bpg/gerinfo/242>

**STEPS FOR SUBMITTING MANUSCRIPTS**

<https://www.wjgnet.com/bpg/GerInfo/239>

**ONLINE SUBMISSION**

<https://www.f6publishing.com>

# Entrapment of the temporal horn secondary to postoperative gamma-knife radiosurgery in intraventricular meningioma: A case report

Jia Liu, Sheng-Rong Long, Guang-Yu Li

**ORCID number:** Jia Liu (0000-0002-6270-0745); Sheng-Rong Long (0000-0002-5831-4235); Guang-Yu Li (0000-0002-5949-7221).

**Author contributions:** Long SR contributed to the acquisition of data; Liu J wrote the paper; Li GY contributed to revision of this manuscript.

## Informed consent statement:

Written informed consent was obtained from the patient for publication of this report and any accompanying images.

**Conflict-of-interest statement:** The authors declare that they have no conflict of interest.

## CARE Checklist (2016) statement:

The authors have read the CARE Checklist (2013), and the manuscript was prepared and revised according to the CARE Checklist (2016).

**Open-Access:** This article is an open-access article which was selected by an in-house editor and fully peer-reviewed by external reviewers. It is distributed in accordance with the Creative Commons Attribution Non Commercial (CC BY-NC 4.0) license, which permits others to distribute, remix, adapt, build upon this work non-commercially, and license their derivative works on different terms, provided the original work is properly cited and the use is non-commercial. See: <http://creativecommons.org/licenses/by-nc/4.0/>

Jia Liu, Sheng-Rong Long, Guang-Yu Li, Department of Neurosurgery, the First Hospital of China Medical University, Shenyang 110001, Liaoning Province, China

**Corresponding author:** Guang-Yu Li, PhD, MD, Surgeon, Department of Neurosurgery, the First Hospital of China Medical University, 155 Nanjingbei Street, Heping District, Shenyang 110001, Liaoning Province, China. [tyjk1972@163.com](mailto:tyjk1972@163.com)

**Telephone:** +86-13998156450

## Abstract

### BACKGROUND

Entrapment of the temporal horn (ETH) is a rare pathologic condition. It is a kind of focal hydrocephalus caused by obstruction of flow pathway of cerebrospinal fluid. It is caused by various conditions, but ETH secondary to postoperative gamma-knife radiosurgery (GKS) is extremely rare.

### CASE SUMMARY

A 52-year old previously healthy woman underwent resection of a large intraventricular meningioma. A small fragment of residual tumor with no obvious enlargement of the temporal horn was observed 3 mo after surgery, and she was referred for GKS. Two months after GKS, she complained of headache and progressive paralysis of the left limb. Magnetic resonance imaging revealed enlargement of the temporal horn. There was a second procedure to resect the residual tumor 8 mo after GKS. After the second procedure, she recovered smoothly. As of the date of this writing, she has remained in good condition.

### CONCLUSION

This case reminds us that ETH should be considered in the treatment of intraventricular meningiomas, especially before GKS.

**Key words:** Entrapment of the temporal horn; Gamma-knife radiosurgery; Intraventricular meningioma; Case report

©The Author(s) 2019. Published by Baishideng Publishing Group Inc. All rights reserved.

**Core tip:** Entrapment of the temporal horn (ETH) is a rare pathologic condition. Here we present a case of ETH secondary to postoperative gamma-knife radiosurgery (GKS) in intraventricular meningioma. A 52-year old women received gamma knife therapy 3 mo

**Manuscript source:** Unsolicited Manuscript

**Received:** April 22, 2019

**Peer-review started:** May 8, 2019

**First decision:** June 17, 2019

**Revised:** July 23, 2019

**Accepted:** July 27, 2019

**Article in press:** July 27, 2019

**Published online:** September 26, 2019

**P-Reviewer:** El-Razek AA, Jiang B, Sotelo J

**S-Editor:** Cui LJ

**L-Editor:** Wang TQ

**E-Editor:** Xing YX



after first operation of intraventricular meningioma due to residual tumor. Then, ETH occurred 2 mo after GKS. A second operation to resect the residual tumor 8 mo after GKS was performed and the patient recovered smoothly. This case reminded us that ETH should be considered in the treatment of intraventricular meningiomas, especially before GKS.

**Citation:** Liu J, Long SR, Li GY. Entrapment of the temporal horn secondary to postoperative gamma-knife radiosurgery in intraventricular meningioma: A case report. *World J Clin Cases* 2019; 7(18): 2894-2898

**URL:** <https://www.wjgnet.com/2307-8960/full/v7/i18/2894.htm>

**DOI:** <https://dx.doi.org/10.12998/wjcc.v7.i18.2894>

## INTRODUCTION

Entrapment of the temporal horn (ETH) is characterized by dilation of the temporal horn of the lateral ventricle, caused by cerebrospinal fluid (CSF) obstruction at the trigone level. It is secondary to several pathological conditions, including infection<sup>[1]</sup>, intraventricular hematoma<sup>[2]</sup>, parasitic infection<sup>[3]</sup>, arteriovenous malformation<sup>[4]</sup>, and intraventricular tumors<sup>[5]</sup>. Most reported cases of ETH were secondary to these pathological conditions. However, gamma-knife radiosurgery (GKS) also can lead to ETH, although this situation has been rarely reported. Here we report the first case of ETH secondary to postoperative GKS.

## CASE PRESENTATION

### Chief complaints

A 52-year old woman was admitted to our hospital with a complaint of weakness of the left limb and lethargy.

### History of present illness

She felt weakness of the left limb 3 mo before admission and became lethargy 3 d before admission.

### History of past illness

No past illness was complained by the patient.

### Physical examination

On admission, the patient was somnolent. Physical examination showed weakness of the left limbs and bilateral papilledema. After admission, her condition deteriorated rapidly.

### Laboratory examinations

No obvious abnormality was revealed in laboratory examinations.

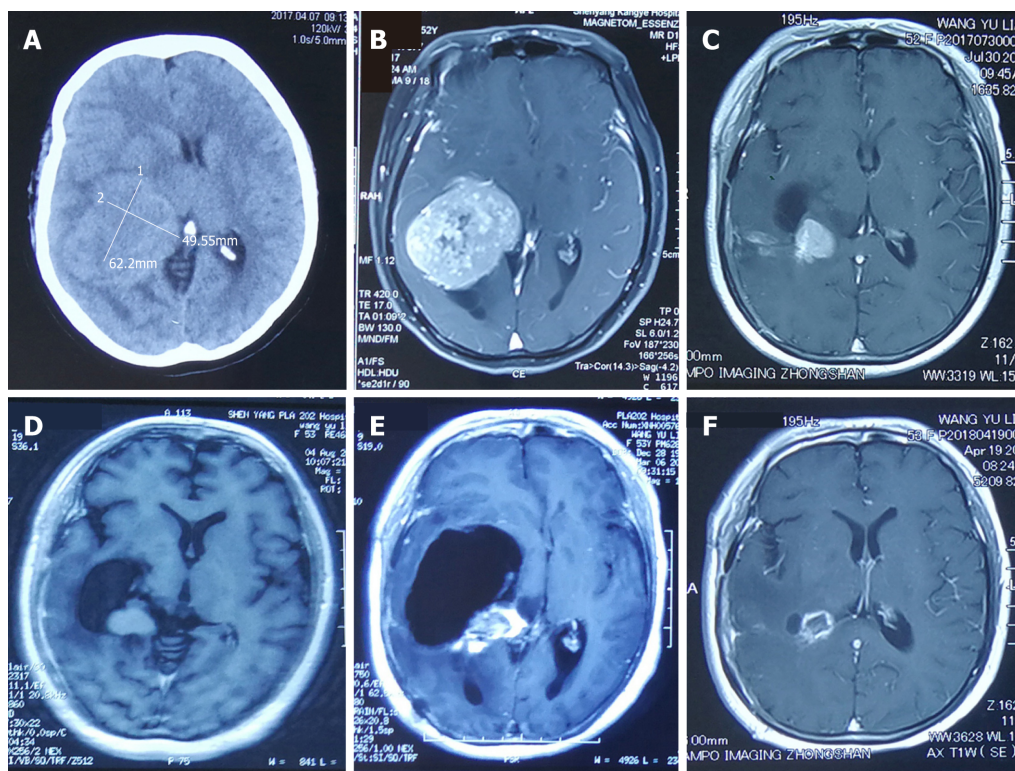
### Imaging examinations

A computed tomography (CT) scan showed a homodensity lesion in the right trigone of the ventricle, and magnetic resonance imaging (MRI) showed a lesion with homogenous enhancement in the right trigone of the ventricle. No enlargement of the ventricle was observed (Figure 1).

## TREATMENT

She underwent intraventricular meningioma resection under general anesthesia *via* a transcortical approach. A small piece of tumor remained during the operation because of unstable vital signs. Postoperative pathological diagnosis confirmed meningioma. The patient recovered smoothly after surgery and symptoms disappeared gradually. A follow-up at 3 mo after surgery revealed residual tumor. She was in good condition at the time. She was then referred for GKS. Radiosurgery was performed with 32 Gy of five central points and a marginal dose of 16 Gy to 50% isodose curve, which lasted 2325 s. Two months after GKS, she developed a headache and progressive paralysis of





**Figure 1** Entrapment of the temporal horn secondary to postoperative gamma-knife radiosurgery in intraventricular meningioma. A: A computed tomography scan showing a lesion in the right trigone of the ventricle; B: Magnetic resonance imaging (MRI) before the first operation showing a lesion with homogenous enhancement in the right trigone of the ventricle; C: MRI at 3 mo after the first operation showing residual tumor without substantial dilation of the temporal horn; D: MRI at 1 mo after gamma-knife radiosurgery (GKS) showing slight dilation of the temporal horn; E: MRI at 8 mo after GKS showing substantial dilation of the temporal horn; F: MRI at 1 mo after the second operation showing a normal temporal horn.

the left limb. Follow-up magnetic resonance imaging revealed progressive expansion of the ventricular temporal horn. She then underwent a second operation 11 mo after the first procedure. At the second operation, the residual tumor was resected completely and the choroid plexus was coagulated (Figure 2).

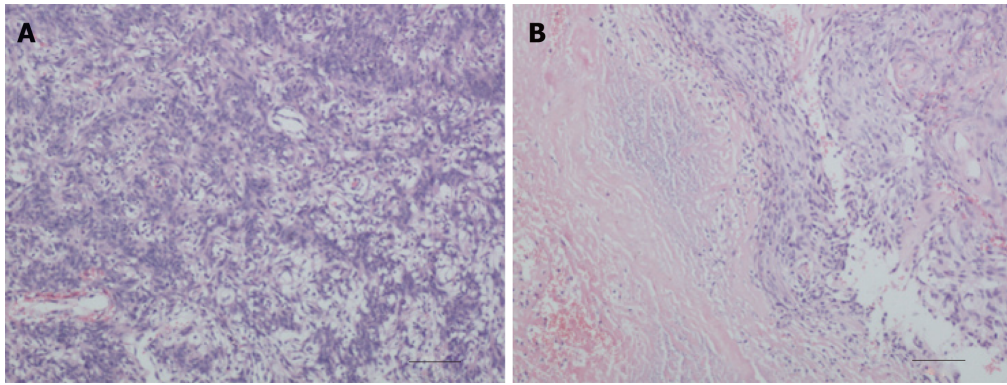
## OUTCOME AND FOLLOW-UP

After the second operation, she recovered rapidly with disappearance of headache and hemiparesis. She has remained well until the most recent follow-up 9 mo after the second surgery (Figure 3).

## DISCUSSION

Recently, ETH after operation of the trigone meningioma has been brought into focus, which was seldom discovered before. As the development of imaging plays an important role in neurosurgery<sup>[6,7]</sup>, dilation of the ventricle can be monitored by CT and MRI. In fact, dilation of the temporal horn of the lateral ventricle is not rare after surgery for intraventricular lesions<sup>[8]</sup>, especially for trigone meningioma<sup>[9]</sup>. However, most are asymptomatic or can be treated with conservative therapy. Only few cases require surgical intervention because of progressive intracranial hypertension and mass effect caused by dilated temporal horn. Several factors were reported to be related to the occurrence of postoperative ETH, including meningitis after surgery, neurologic deficits after operation, and inappropriate ventricular drainage<sup>[5]</sup>. In our case, a large trigone meningioma was resected. None of the factors mentioned above were present in our case. Despite a small residual piece of tumor, no substantial dilation of the temporal horn occurred 3 mo after surgery. Nevertheless, two months after GKS, she suffered from headache and gradual symptom worsening. In our case, no high-risk factor related with ETH was observed; therefore, we speculated that ETH in our case was secondary to radiation damage induced by GKS. Radiation led to brain damage, including to the ventricular wall; this may have led to occlusion of CSF





**Figure 2** Entrapment of the temporal horn secondary to postoperative gamma-knife radiosurgery in intraventricular meningioma. A: Pathology after first operation. Microscopically, the tumor cells were spindle-shaped and bundle-shaped with slightly larger and darker nuclei, and the diagnosis was meningioma; B: Pathology after second operation. Microscopically, the tumor cells were patchy, densely arranged, and slightly atypical, with massive necrosis and hemorrhage locally. The diagnosis was atypical meningioma.

flow. Radiation-associated ETH was reported in only a girl with a diffuse parietoccipital AVM who underwent GKS<sup>[10]</sup>. GKS also can cause tumor edema and increase tumor volume, leading to ETH. To the best of our knowledge, ETH secondary to GKS in trigone meningioma has not been reported previously.

There are many methods to manage ETH, including V-P shunt<sup>[2]</sup>, endoscopic temporal ventriculocisternostomy<sup>[11,12]</sup>, frontal-to-temporal horn shunt<sup>[13]</sup>, and temporal horn to prepontine cistern shunt<sup>[14]</sup>. In this case, resection of residual tumor was performed, and the patient recovered smoothly thereafter.

## CONCLUSION

In conclusion, to the best of our knowledge, this is the first case of ETH after GKS in an intraventricular meningioma. This case reminds us that ETH should be considered when treating intraventricular meningiomas, especially before GKS.

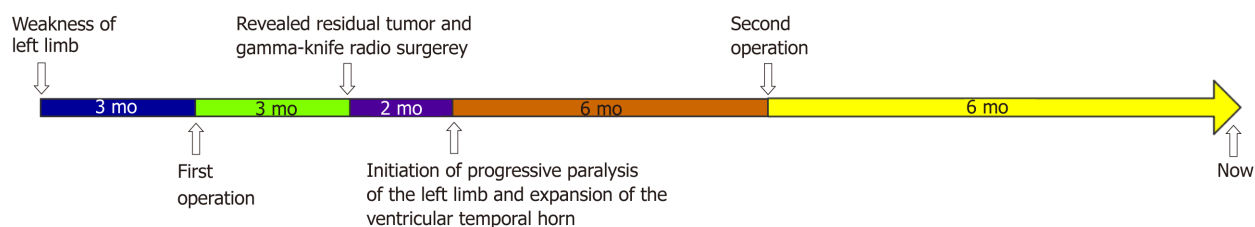


Figure 3 Timeline showing events starting from the onset of symptoms until ultimate outcome.

## REFERENCES

- 1 Tsugane R, Shimoda M, Yamaguchi T, Yamamoto I, Sato O. Entrapment of the temporal horn: a form of focal non-communicating hydrocephalus caused by intraventricular block of cerebrospinal fluid flow--report of two cases. *Neurol Med Chir (Tokyo)* 1992; **32**: 210-214 [PMID: [1378565](#) DOI: [10.2176/nmc.32.210](#)]
- 2 Maurice-Williams RS, Choksey M. Entrapment of the temporal horn: a form of focal obstructive hydrocephalus. *J Neurol Neurosurg Psychiatry* 1986; **49**: 238-242 [PMID: [3958736](#) DOI: [10.1136/jnnp.49.3.238](#)]
- 3 Kamali NI, Huda MF, Srivastava VK. Intraventricular hydatid cyst causing entrapped temporal horn syndrome: Case report and review of literature. *Trop Parasitol* 2011; **1**: 113-115 [PMID: [23508788](#) DOI: [10.4103/2229-5070.86953](#)]
- 4 Paredes I, Orduna J, Fustero D, Salgado JA, de Diego JM, de Mesa FG. Endoscopic temporal ventriculocisternostomy for the management of temporal horn entrapment: report of 4 cases. *J Neurosurg* 2017; **126**: 298-303 [PMID: [27081903](#) DOI: [10.3171/2016.1.JNS152248](#)]
- 5 Wang Y, Lin Z, Li Z, Zhao M, Hu M, Zhang H, Chen X, Jiang Z. The Incidence and Risk Factors of Postoperative Entrapped Temporal Horn in Trigone Meningiomas. *World Neurosurg* 2016; **90**: 511-517 [PMID: [27012837](#) DOI: [10.1016/j.wneu.2016.03.040](#)]
- 6 Abdel Razek AAK, El-Serougy L, Abdelsalam M, Gaballa G, Talaat M. Differentiation of Primary Central Nervous System Lymphoma From Glioblastoma: Quantitative Analysis Using Arterial Spin Labeling and Diffusion Tensor Imaging. *World Neurosurg* 2019; **123**: e303-e309 [PMID: [30502475](#) DOI: [10.1016/j.wneu.2018.11.155](#)]
- 7 Razek AAK, El-Serougy L, Abdelsalam M, Gaballa G, Talaat M. Differentiation of residual/recurrent gliomas from postradiation necrosis with arterial spin labeling and diffusion tensor magnetic resonance imaging-derived metrics. *Neuroradiology* 2018; **60**: 169-177 [PMID: [29218370](#) DOI: [10.1007/s00234-017-1955-3](#)]
- 8 Zhang B, Wang X, Li C, Li Z. Neuroendoscopic Fenestration for Entrapped Temporal Horn After Surgery: Report of 3 Cases. *World Neurosurg* 2018; **112**: 77-80 [PMID: [29371166](#) DOI: [10.1016/j.wneu.2018.01.096](#)]
- 9 Ma J, Cheng L, Wang G, Lin S. Surgical management of meningioma of the trigone area of the lateral ventricle. *World Neurosurg* 2014; **82**: 757-769 [PMID: [24878623](#) DOI: [10.1016/j.wneu.2014.05.026](#)]
- 10 Yeon JY, Shin HJ, Kim JS, Hong SC, Lee JI. Clinico-radiological outcomes following gamma knife radiosurgery for pediatric arteriovenous malformations. *Childs Nerv Syst* 2011; **27**: 1109-1119 [PMID: [21286730](#) DOI: [10.1007/s00381-011-1401-5](#)]
- 11 Krähenbühl AK, Baldauf J, Gaab MR, Schroeder HW. Endoscopic temporal ventriculocisternostomy: an option for the treatment of trapped temporal horns. *J Neurosurg Pediatr* 2013; **11**: 568-574 [PMID: [23521153](#) DOI: [10.3171/2013.2.PEDS12417](#)]
- 12 Arenas-Ruiz JA, Martinez-Maldonado H, Gonzalez-Carranza V, Torres-García S, Chico-Ponce de Leon F. Endoscopic ventriculo-cisterno-ventricular approach in the treatment of bilateral trapped temporal horn related to fungal infection in a child: case report and review of the literature. *Childs Nerv Syst* 2018; **34**: 1593-1597 [PMID: [29557511](#) DOI: [10.1007/s00381-018-3776-z](#)]
- 13 Hervey-Jumper SL, Ziewacz JE, Heth JA, Sullivan SE. Frontal-to-temporal horn shunt as treatment for temporal horn entrapment. *J Neurosurg* 2010; **112**: 410-413 [PMID: [19408983](#) DOI: [10.3171/2009.3](#)]
- 14 Chen CC, Kasper EM, Zinn PO, Warnke PC. Management of entrapped temporal horn by temporal horn to prepontine cistern shunting. *World Neurosurg* 2013; **79**: 404.e7-404.10 [PMID: [22120406](#) DOI: [10.1016/j.wneu.2011.02.025](#)]



Published By Baishideng Publishing Group Inc  
7041 Koll Center Parkway, Suite 160, Pleasanton, CA 94566, USA  
Telephone: +1-925-2238242  
E-mail: [bpgoffice@wjgnet.com](mailto:bpgoffice@wjgnet.com)  
Help Desk: <https://www.f6publishing.com/helpdesk>  
<https://www.wjgnet.com>

