

World Journal of *Clinical Cases*

World J Clin Cases 2019 October 6; 7(19): 2916-3167



**REVIEW**

- 2916** DNA methylation detection methods used in colorectal cancer
Zhan YX, Luo GH

ORIGINAL ARTICLE**Case Control Study**

- 2930** Expression and predictive value of miR-489 and miR-21 in melanoma metastasis
Mo H, Guan J, Yuan ZC, Lin X, Wu ZJ, Liu B, He JL

Observational Study

- 2942** Association of stiff-person syndrome with autoimmune endocrine diseases
Lee YY, Chen IW, Chen ST, Wang CC
- 2953** Hyperthyroid heart disease in pregnancy: Retrospective analysis of a case series and review of the literature
Shan D, Bai Y, Chen QH, Wu YX, Chen Q, Hu YY
- 2963** Changes of serum inflammatory factors and miR-145 expression in patients with osteoarthritis before and after treatment and their clinical value
Wang XZ, Li WX

Prospective Study

- 2976** Immediate muscle strengthening by an end-effector type gait robot with reduced real-time use of leg muscles: A case series and review of literature
Hwang CH

Randomized Clinical Trial

- 2986** Comparison of perceived pain and patients' satisfaction with traditional local anesthesia and single tooth anesthesia: A randomized clinical trial
Al-Obaida MI, Haider M, Hashim R, AlGheriri W, Celur SL, Al-Saleh SA, Al-Madi EM

SYSTEMATIC REVIEW

- 2995** Treatment of laryngopharyngeal reflux disease: A systematic review
Lechien JR, Mouawad F, Barillari MR, Nacci A, Khoddami SM, Enver N, Raghunandhan SK, Calvo-Henriquez C, Eun YG, Saussez S

CASE REPORT

- 3012** Keratoconus in a patient with Alport syndrome: A case report
Moshirfar M, Skanchy DF, Gomez AT, Ronquillo YC, Buckner B, Hoopes PC

- 3018** Successful multidisciplinary clinical approach and molecular characterization by whole transcriptome sequencing of a cardiac myxofibrosarcoma: A case report
Saponara M, Indio V, Pizzi C, Serban ED, Urbini M, Astolfi A, Paolisso P, Suarez SM, Nannini M, Pacini D, Agostini V, Leone O, Ambrosini V, Tarantino G, Fanti S, Niro F, Buia F, Attinà D, Pantaleo MA
- 3027** Laparoscopic hysterectomy as optimal approach for 5400 grams uterus with associated polycythemia: A case report
Macciò A, Chiappe G, Lavra F, Sanna E, Nieddu R, Madeddu C
- 3033** Malignant sweat gland tumor of breast arising in pre-existing benign tumor: A case report
An JK, Woo JJ, Hong YO
- 3039** Bronchobiliary fistula after ramucirumab treatment for advanced gastric cancer: A case report
Kim HB, Na YS, Lee HJ, Park SG
- 3047** Severe heterotopic ossification in a seronegative spondyloarthritis patient after cervical Bryan disc arthroplasty: A case report
Huang CW, Tang CL, Pan HC, Tzeng CY, Tsou HK
- 3055** Underlying IgM heavy chain amyloidosis in treatment-refractory IgA nephropathy: A case report
Wu HT, Wen YB, Ye W, Liu BY, Shen KN, Gao RT, Li MX
- 3062** Diagnosis of myocardial infarction with nonobstructive coronary arteries in a young man in the setting of acute myocardial infarction after endoscopic retrograde cholangiopancreatography: A case report
Li D, Li Y, Wang X, Wu Y, Cui XY, Hu JQ, Li B, Lin Q
- 3069** Hemophagocytic lymphohistiocytosis complicated by polyserositis: A case report
Zhu P, Ye Q, Li TH, Han T, Wang FM
- 3074** Hair regrowth following fecal microbiota transplantation in an elderly patient with alopecia areata: A case report and review of the literature
Xie WR, Yang XY, Xia HHX, Wu LH, He XX
- 3082** How should congenital absence of cruciate ligaments be treated? A case report and literature review
Lu R, Zhu DP, Chen N, Sun H, Li ZH, Cao XW
- 3090** Kaposi's sarcoma manifested as lower gastrointestinal bleeding in a HIV/HBV-co-infected liver cirrhosis patient: A case report
Zhou QH, Guo YZ, Dai XH, Zhu B
- 3098** Primary renal synovial sarcoma: A case report
Cai HJ, Cao N, Wang W, Kong FL, Sun XX, Huang B
- 3104** Type I neurofibromatosis with spindle cell sarcoma: A case report
Zhang Y, Chao JJ, Liu XF, Qin SK

- 3111** Primary hypoparathyroidism accompanied by rhabdomyolysis induced by infection: A case report
Ding LN, Wang Y, Tian J, Ye LF, Chen S, Wu SM, Shang WB
- 3120** Effects of combined rTMS and visual feedback on the rehabilitation of supernumerary phantom limbs in a patient with spinal cord injury: A case report
Lu YS, Tong P, Guo TC, Ding XH, Zhang S, Zhang XJ
- 3126** Clear cell sarcoma of soft tissue in pleural cavity: A case report
Chen YT, Yang Z, Li H, Ni CH
- 3132** Primary hyperparathyroidism in a woman with multiple tumors: A case report
Hui CC, Zhang X, Sun JR, Deng DT
- 3138** Gastric adenocarcinoma mimicking a submucosal tumor: A case report
Cheng XL, Liu H
- 3145** Hypereosinophilia, mastectomy, and nephrotic syndrome in a male patient: A case report
Wu J, Li P, Chen Y, Yang XH, Lei MY, Zhao L
- 3153** Flapless immediate implant placement into fresh molar extraction socket using platelet-rich fibrin: A case report
Sun XL, Mudalal M, Qi ML, Sun Y, Du LY, Wang ZQ, Zhou YM
- 3160** Advanced primary amelanotic malignant melanoma of the esophagus: A case report
Zhang RX, Li YY, Liu CJ, Wang WN, Cao Y, Bai YH, Zhang TJ

ABOUT COVER

Editorial Board Member of *World Journal of Clinical Cases*, Enver Zerem, MD, PhD, Professor, Department of Medical Science, Academy of Sciences and Arts of Bosnia and Herzegovina, University Clinical Centre Tuzla, Tuzla 75000, Bosnia and Herzegovina

AIMS AND SCOPE

The primary aim of *World Journal of Clinical Cases* (*WJCC*, *World J Clin Cases*) is to provide scholars and readers from various fields of clinical medicine with a platform to publish high-quality clinical research articles and communicate their research findings online.

WJCC mainly publishes case reports, case series, and articles reporting research results and findings obtained in the field of clinical medicine and covering a wide range of topics including diagnostic, therapeutic, and preventive modalities.

INDEXING/ABSTRACTING

The *WJCC* is now indexed in PubMed, PubMed Central, Science Citation Index Expanded (also known as SciSearch®), and Journal Citation Reports/Science Edition. The 2019 Edition of Journal Citation Reports cites the 2018 impact factor for *WJCC* as 1.153 (5-year impact factor: N/A), ranking *WJCC* as 99 among 160 journals in Medicine, General and Internal (quartile in category Q3).

RESPONSIBLE EDITORS FOR THIS ISSUE

Responsible Electronic Editor: *Yan-Xia Xing*

Proofing Production Department Director: *Xiang Li*

NAME OF JOURNAL

World Journal of Clinical Cases

ISSN

ISSN 2307-8960 (online)

LAUNCH DATE

April 16, 2013

FREQUENCY

Semimonthly

EDITORS-IN-CHIEF

Dennis A Bloomfield, Bao-Gan Peng, Sandro Vento

EDITORIAL BOARD MEMBERS

<https://www.wjnet.com/2307-8960/editorialboard.htm>

EDITORIAL OFFICE

Jin-Lei Wang, Director

PUBLICATION DATE

October 6, 2019

COPYRIGHT

© 2019 Baishideng Publishing Group Inc

INSTRUCTIONS TO AUTHORS

<https://www.wjnet.com/bpg/gerinfo/204>

GUIDELINES FOR ETHICS DOCUMENTS

<https://www.wjnet.com/bpg/GerInfo/287>

GUIDELINES FOR NON-NATIVE SPEAKERS OF ENGLISH

<https://www.wjnet.com/bpg/gerinfo/240>

PUBLICATION MISCONDUCT

<https://www.wjnet.com/bpg/gerinfo/208>

ARTICLE PROCESSING CHARGE

<https://www.wjnet.com/bpg/gerinfo/242>

STEPS FOR SUBMITTING MANUSCRIPTS

<https://www.wjnet.com/bpg/GerInfo/239>

ONLINE SUBMISSION

<https://www.f6publishing.com>

Hypereosinophilia, mastectomy, and nephrotic syndrome in a male patient: A case report

Jian Wu, Peng Li, Yu Chen, Xiang-Hong Yang, Meng-Yun Lei, Li Zhao

ORCID number: Jian Wu (0000-0002-3439-7435); Peng Li (0000-0002-6060-0089); Yu Chen (0000-0001-9767-4797); Xiang-Hong Yang (0000-0001-9223-3677); Meng-Yun Lei (0000-0001-8578-9204); Li Zhao (0000-0002-2544-0876).

Author contributions: Wu J, Li P, Chen Y, Yang XH, Lei MY, and Zhao L contributed to the manuscript writing and revision.

Informed consent statement: Written informed consent was obtained from the patient.

Conflict-of-interest statement: The authors declare no conflict of interest.

CARE Checklist (2016) statement: The authors have read the CARE Checklist (2013), and the manuscript was prepared and revised according to the CARE Checklist (2016).

Open-Access: This article is an open-access article which was selected by an in-house editor and fully peer-reviewed by external reviewers. It is distributed in accordance with the Creative Commons Attribution Non Commercial (CC BY-NC 4.0) license, which permits others to distribute, remix, adapt, build upon this work non-commercially, and license their derivative works on different terms, provided the original work is properly cited and the use is non-commercial. See: <http://creativecommons.org/licenses/by-nc/4.0/>

Manuscript source: Unsolicited manuscript

Jian Wu, Department of Anesthesiology, Shengjing Hospital, China Medical University, Shenyang 110004, Liaoning Province, China

Peng Li, Yu Chen, Li Zhao, Department of Respiratory Medicine, Shengjing Hospital, China Medical University, Shenyang 110004, Liaoning Province, China

Xiang-Hong Yang, Department of Pathology, Shengjing Hospital, China Medical University, Shenyang 110004, Liaoning Province, China

Meng-Yun Lei, Department of Endocrinology, Shengjing Hospital, China Medical University, Shenyang 110004, Liaoning Province, China

Corresponding author: Yu Chen, MD, PhD, Professor, Department of Respiratory Medicine, Shengjing Hospital, China Medical University, No. 36, Sanhao Street, Shenyang 110004, Liaoning Province, China. chenyusy@hotmail.com
Telephone: +86-18940256915

Abstract

BACKGROUND

Hypereosinophilia (HE) is a heterogeneous disease of unknown etiology in which tissue and organ injury is inflicted by excess numbers of circulating or infiltrating eosinophils. Herein, we describe a patient with rare organ damage due to HE and review the pertinent literature.

CASE SUMMARY

A 43 year-old Chinese man with a 13-year history of eosinophilia and shortness of breath for 7 d presented to our hospital. During the course of his illness, the patient variably presented with gastrointestinal symptoms, eczema, vitiligo, mastitis, joint symptoms, nephrotic syndrome, and interstitial pneumonia. The chronic mastitis proved burdensome, necessitating bilateral mastectomy. HE was diagnosed by repeat bone marrow biopsy, and a kidney biopsy showed focal segmental glomerulosclerosis. Intermittent steroidal therapy is typically initiated to relieve such symptoms, although relapse and organ involvement often ensue once treatment is withdrawn. We administered methylprednisolone sodium succinate (40 mg/d) intravenously for 3 d, followed by oral tablets at the same dose. Subsequent computed tomography (CT) of the chest CT showed relative improvement of the interstitial pneumonia. The patient is currently on a continuous regimen of oral steroid, and his condition is stable.

CONCLUSION

HE is heterogeneous condition. This is the first reported case of bilateral

Received: March 14, 2019
Peer-review started: March 15, 2019
First decision: July 30, 2019
Revised: September 3, 2019
Accepted: September 11, 2019
Article in press: September 11, 2019
Published online: October 6, 2019

P-Reviewer: Yorioka N
S-Editor: Dou Y
L-Editor: Wang TQ
E-Editor: Xing YX



mastectomy in a male patient with longstanding HE.

Key words: Hypereosinophilia; Mastectomy; Nephrotic syndrome; Interstitial pneumonia; Case report

©The Author(s) 2019. Published by Baishideng Publishing Group Inc. All rights reserved.

Core tip: Hypereosinophilia (HE) is a heterogeneous disease of unknown etiology in which excessive circulating and infiltrating eosinophils cause injury to bodily tissues and organs. We have treated a male patient with HE and unusual organ involvement, namely, mastitis, nephrotic syndrome, and interstitial pneumonia. Intermittent glucocorticoid therapy may relieve symptoms, but relapses and renewed organ damage are common after withdrawal. This particular patient is currently stable on a continuous oral steroid regimen. This is the first reported case of bilateral mastectomy in a male patient with HE.

Citation: Wu J, Li P, Chen Y, Yang XH, Lei MY, Zhao L. Hypereosinophilia, mastectomy, and nephrotic syndrome in a male patient: A case report. *World J Clin Cases* 2019; 7(19): 3145-3152

URL: <https://www.wjgnet.com/2307-8960/full/v7/i19/3145.htm>

DOI: <https://dx.doi.org/10.12998/wjcc.v7.i19.3145>

INTRODUCTION

Hypereosinophilia (HE) is a disease defined by one or more of the following: (1) Peripheral blood eosinophil counts $> 1.5 \times 10^9/L$ on two occasions at intervals > 1 mo; (2) A ratio of eosinophils to nucleated cells in bone marrow $> 20\%$; (3) Pathologic confirmation of extensive tissue infiltration by eosinophils; and (4) Conditions marked by substantial deposition of eosinophil granuloproteins^[1]. Multiorgan involvement and resultant dysfunction are common, given the intensity of eosinophilic infiltration and/or extensive proteinaceous deposits. There may be fibrosis of the lungs, heart, digestive tract, skin, or other organs; thrombosis with or without embolism; cutaneous or mucosal changes [erythema, edema (perhaps vascular in nature), ulceration, pruritus, or eczema]; and peripheral or central nervous system derangements, with or without chronic or recurrent neurologic dysfunction^[1]. Herein, we report a male patient with multiorgan involvement, eosinophilic mastitis, and nephrotic syndrome due to longstanding HE.

CASE PRESENTATION

Chief complaints

A 43-year-old Chinese man, who complained of shortness of breath on exertion for 7 d and a 13-year history of peripheral blood eosinophilia, was admitted to our hospital.

History of present illness

The patient was treated at a local hospital in August 2005 because routine blood examination showed a white blood cell count of $8.5 \times 10^9/L$, with 24.2% of eosinophils ($2 \times 10^9/L$). In a bone marrow biopsy, eosinophils accounted for 13.5%, most with normally segmented rod nuclei. Once oral triamcinolone was initiated (4 mg, tid), the eosinophil counts rapidly normalized. After gradual dosage reduction in a span of 6 mo and eventual discontinuation, hyperplastic and nodular changes developed in both breasts, accompanied by abnormal lactation and bilateral axillary node enlargement. This condition was sufficiently burdensome to require surgery. Bilateral mastectomy was subsequently performed (January 2006) for chronic mastitis. Postoperative pathology examination disclosed male breast development and severe chronic inflammation (*i.e.*, dilatation of mammary ducts with interstitial influx of eosinophils) (Figure 1).

One month later, the patient presented with joint pain of the trunk and limbs, movement dysfunction, and an exacerbated skin rash. Dexamethasone and prednisone were prescribed. An herbal extract (*Tripterygium wilfordii*) was also used

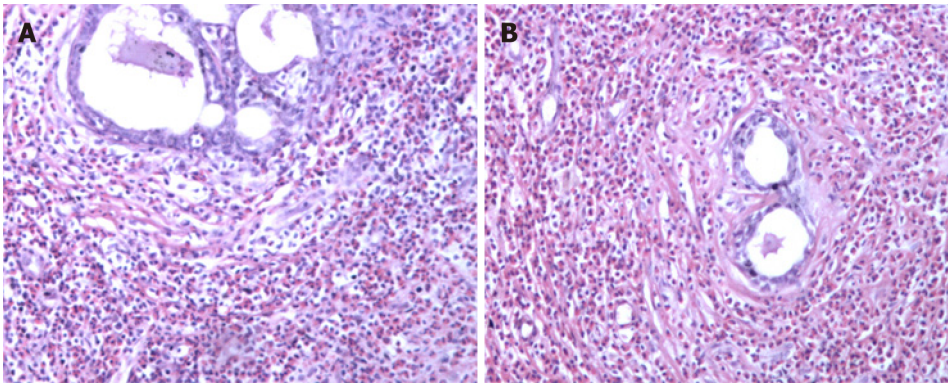


Figure 1 Breast pathology showing breast involvement by analysis of cell morphology (hematoxylin-eosin staining, $\times 100$). A and B: Intra-tissue ductal dilatation and interstitial eosinophil infiltration are shown.

shortly and then abandoned due to severe treatment-related alopecia. Thereafter, the joint symptoms gradually relented, allowing the patient to resume work. In April 2017, however, bilateral lower extremity edema developed spontaneously (blood pressure, 150/100 mmHg; plasma albumin, 15.6 g/L; low-density lipoproteins, 6.87 mmol/L; and 24-h urinary protein, 14.78 g/d), prompting a clinical diagnosis of nephrotic syndrome. A kidney biopsy was performed, establishing a pathologic diagnosis of focal segmental glomerulosclerosis, non-specific type (Figures 2 and 3). A second bone marrow puncture again was indicative of eosinophilia, but qualitative polymerase chain reaction failed to detect the *FIP1L1-PDGFR* fusion gene. The patient was given prednisone orally at an initial dose of 60 mg (12 tablets) per day. This was gradually reduced and discontinued in March 2018, at which time all parameters of nephrotic syndrome were stable.

One month after medication withdrawal, hospital readmission was brought on by shortness of breath (April 2018).

History of past illness

He initially presented in December 2004 with constipation, abdominal distension, and persistent vomiting. Gastroscopic inspection revealed superficial gastritis, duodenal bulbar inflammation, and gastric retention. Enteroscopy was then performed, showing rectosigmoid mucositis. Interstitial inflammatory infiltrates were prominent in gastric and colonic mucosal biopsies. After symptomatic treatment, the digestive symptoms gradually abated and disappeared. Several months later, the patient developed an erythematous papular skin rash and vitiligo. The rash coalesced in places but was largely confined to the dorsa of hands and limbs in a symmetric distribution, without itching. Vitiligo chiefly affected the face and trunk.

Personal and family history

Historically, the patient's birth was premature (8 mo of gestation). There was one episode of pertussis during childhood and many instances of pneumonia. The patient's father had succumbed to gastric cancer at the age of 50.

Physical examination upon admission

Physical examination revealed alopecia, loss of facial and trunk pigmentation, and an erythematous rash on the dorsa of both hands and limbs (Figure 4). No dry or wet rales were detected in either lung.

Laboratory examinations

Pertinent laboratory results were as follows: Blood eosinophil count, $0.41 \times 10^9/L$; total IgE, 1491 IU/ml; PaO_2 , 53.6 mmHg; and SaO_2 , 91.2%. In bronchoscopic alveolar lavage fluid, eosinophils represented 30.0% of cells ($CD4+/CD8+ = 0.15$).

Imaging examinations

Chest computed tomography (CT) showed interstitial pneumonia (Figure 5A).

FINAL DIAGNOSIS

Our final diagnosis was HE with pulmonary involvement.

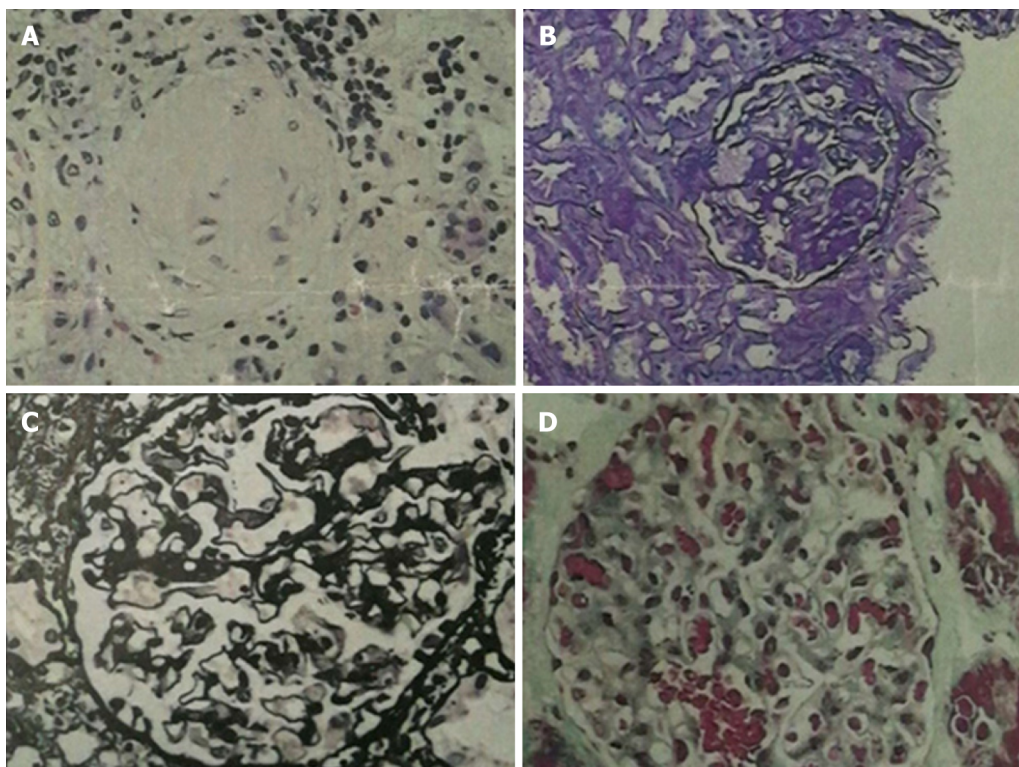


Figure 2 Renal pathology of nephrotic syndrome by analysis of morphological pattern using different staining methods. The specimens were sliced at three layers, mainly in the renal cortex. The number of glomeruli at three layers was 23, 28, and 25, respectively. Glomerular sclerosis in four glomeruli, and glomerular segmental sclerosis and podocyte proliferation in one were found in 28 glomeruli of the second layer. The glomerular mesangial cells and matrix proliferated slightly, the capillary loops opened, and the basement membrane did not thicken. There was no obvious deposition of immunoglobulin in the mesangium, subepithelium, or subendothelium, and no mesangial insertion or double track formation. No proliferation of parietal cells and no crescent formation were noted. The epithelial cells of renal tubules showed vacuolar degeneration, focal atrophy (about 5%), infiltration of small focal inflammatory cells in the renal interstitium, thickening of small arterial wall, and narrowing of lumen. Under fluorescence, IgM (+), IgA, IgG, C3, and C1q (-), and C3 (+) of arterioles were observed. The diagnosis was focal segmental glomerulosclerosis, non-specific type (FSGS, NOS). A: Hematoxylin-eosin stained ($\times 400$) histological image showing a sclerotic glomerulus; B: Periodic acid-Schiff stained ($\times 400$) histological image showing segmental glomerulosclerosis; C: Periodic acid-Schiff methenamine stained ($\times 400$) histological image showing open capillary loops and no significant thickening of basement membrane; D: Masson stained ($\times 400$) histological image showing no significant deposition of hemophilic protein.

TREATMENT

Methylprednisolone sodium succinate (40 mg/d) was administered intravenously for 3 d, followed by the oral formulation at the same dose.

OUTCOME AND FOLLOW-UP

After one week of steroid treatment, repeat chest CT suggested some resolution of the interstitial pneumonia (Figure 5B). Four months after resuming steroid therapy, a number of scattered high-density patches in both lungs were further reduced in CT images (Figure 5C). The patient is currently continuing an oral steroid regimen.

DISCUSSION

Multisystem organ involvement is a precarious aspect of HE. When analyzing the clinical data of 188 patients with HE, Ogbogu *et al*^[2] documented cutaneous manifestations in 37% of cases, respiratory symptoms in 25%, and gastrointestinal complaints in 14%. Heart involvement in early-stage disease was evident in < 5%, and there were no clinical symptoms attributable to eosinophilia in 6%. Over the course of > 10 years, this patient has been plagued by gastrointestinal, skin, breast, joint, kidney, lung, and other organ involvement. Some of the developments, such as gastroenteritis, mastitis, and arthritis, were transient, whereas others (*i.e.*, eczema and vitiligo) had persisted. Although HE may incite mastitis in male patients, bilateral mastectomy has not been reported in the literature to date, and HE with nephrotic

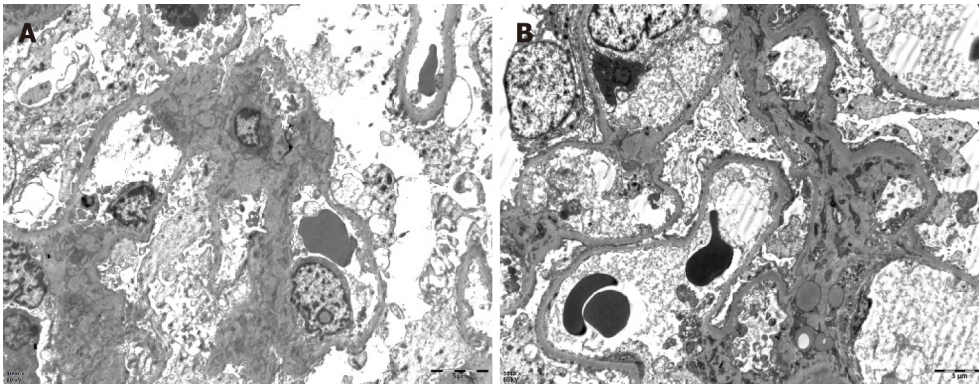


Figure 3 Renal pathology of nephrotic syndrome by electron microscopy. After toluidine blue staining, two glomeruli were observed. One of them was observed by ultrathin section of glomerulus under an electron microscope. Erythrocytes aggregated in glomerular capillary lumen, capillary endothelial cells did not proliferate, and capillary loops were open. No obvious thickening of the wall of renal capsule, vacuolar degeneration of the wall cells, or proliferation of the wall cells was observed. Basement membrane showed no obvious thickening, with a thickness of about 300-450 nm. Visceral epithelial cells showed swelling, vacuolar degeneration, and diffuse fusion of foot processes. In the mesenchymal area, mesenchymal cells and matrix proliferated slightly, no exact electron dense deposits were found, and no electron dense deposits were found under the epithelium and endothelium. Vacuolar degeneration of renal tubular epithelial cells was noted, without special pathological changes in renal interstitium. Erythrocyte aggregation was seen in the lumen of individual renal interstitial capillaries. A diagnosis of focal segmental glomerulosclerosis was made (bar = 0.5 μ m).

syndrome is exceedingly rare.

In past reports of HE, we have discovered only one case of breast involvement^[3]. The patient was a 51-year-old woman who complained of bilateral mammary erythema, pain, and swelling for 1 wk. Histologically, tissue from both breasts displayed ductal eosinophilic infiltration, moderate to severe ductal dilatation, ductal epithelial necrosis, and substantial infiltration of surrounding matrix by eosinophils. However, the patient's prognosis after steroid therapy was good. These symptoms and pathologic features resemble those of our patient, confirming that the breast is one of the rare target organs of HE. Because our patient was male, gender proclivity seems unlikely, but no prior reports of breast involvement in men with HE has surfaced. Bilateral mastectomy was performed in this particular patient due to the morbidity imposed by symmetric enlargement, nodularity, abnormal lactation, swelling, pain, and enlarged axillary nodes. Had steroid therapy been otherwise considered, surgery may have been avoidable.

Although kidney involvement is rare in the setting of HE, it may well be life-threatening. There are two main causes: (1) Direct kidney damage by eosinophilic granules; and (2) Iatrogenic insults during the treatment of HE (*i.e.*, cholesterol embolism, adverse drug reactions, immunologic reactions, eosinophilic helminth infection, and ongoing hemodialysis)^[4]. In relevant clinical case reports with glomerulonephritis as the chief clinical manifestation^[5-8], only one instance of nephrotic syndrome is reported in a 7-year-old boy^[9]. The pathologic spectrum of renal damage is rather broad in this regard, including capillary proliferative glomerulonephritis^[5], eosinophilic interstitial nephritis^[6], crescent glomerulonephritis^[7], and membranous nephropathy^[8]. It is likely that immune reactivity leads to deposition of complexes within glomeruli. The release of damaging cytokines and other mediators, especially leukotrienes^[4], by multinucleated eosinophils may be implicated as well. A non-specific type of focal segmental glomerulosclerosis was identified in our patient. Unfortunately, pathologic classification of renal injury due to HE was specified in one case report only^[10] and in the absence of nephrotic syndrome. The authors refer to "focal segmental sclerotic-like" in their description. The patient in question showed various manifestations of nephrotic syndrome (hypertension, massive proteinuria, hyperlipidemia, and hypoproteinemia). Thus, although the pathologic underpinnings may be shared, there is an inherent heterogeneity that remains unexplained.

Our patient also had vitiligo, which was self-limited and stable in recent years. In our review of the literature, we found no correlation between HE and vitiligo other than two patients with eosinophilic fasciitis (Shulman syndrome) and vitiligo^[11,12]. This discovery hints at a suspected link for which further research is needed.

Pulmonary involvement in HE is common, typically marked by symmetric ground-glass opacities of both lungs and consolidation. At the same time, the blood eosinophil count may be within the normal range^[13], which is inconsistent with the actual clinical picture.

Glucocorticoids are primarily indicated as a treatment for HE, using hydroxyurea,

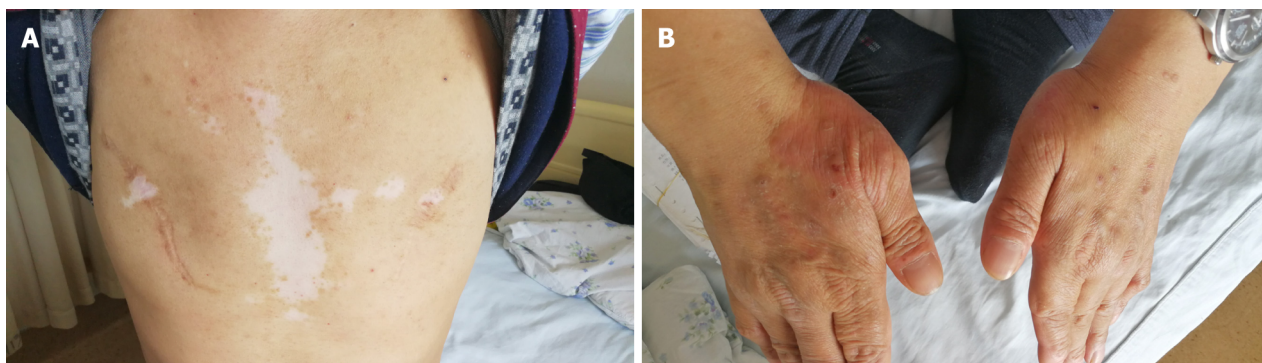


Figure 4 Skin changes of the patient. A: Chest vitiligo and breast surgery: Irregular depigmentation areas in the middle of the patient's forechest and postoperative changes of bilateral mammary glands; B: Eczema on the back of both hands: Red rash on the back of the thumb root of the patient's hands, which fused into pieces.

interferon- α , imatinib, or mepolizumab as alternative agents. The prognosis of patients with HE is generally good^[14].

CONCLUSION

HE is a heterogeneous disease of unknown etiology. Herein is the first reported case of bilateral mastectomy for mastitis in a male patient with HE and nephrotic syndrome. In retrospect, surgery may have been avoided by using a continuous steroidal regimen instead.

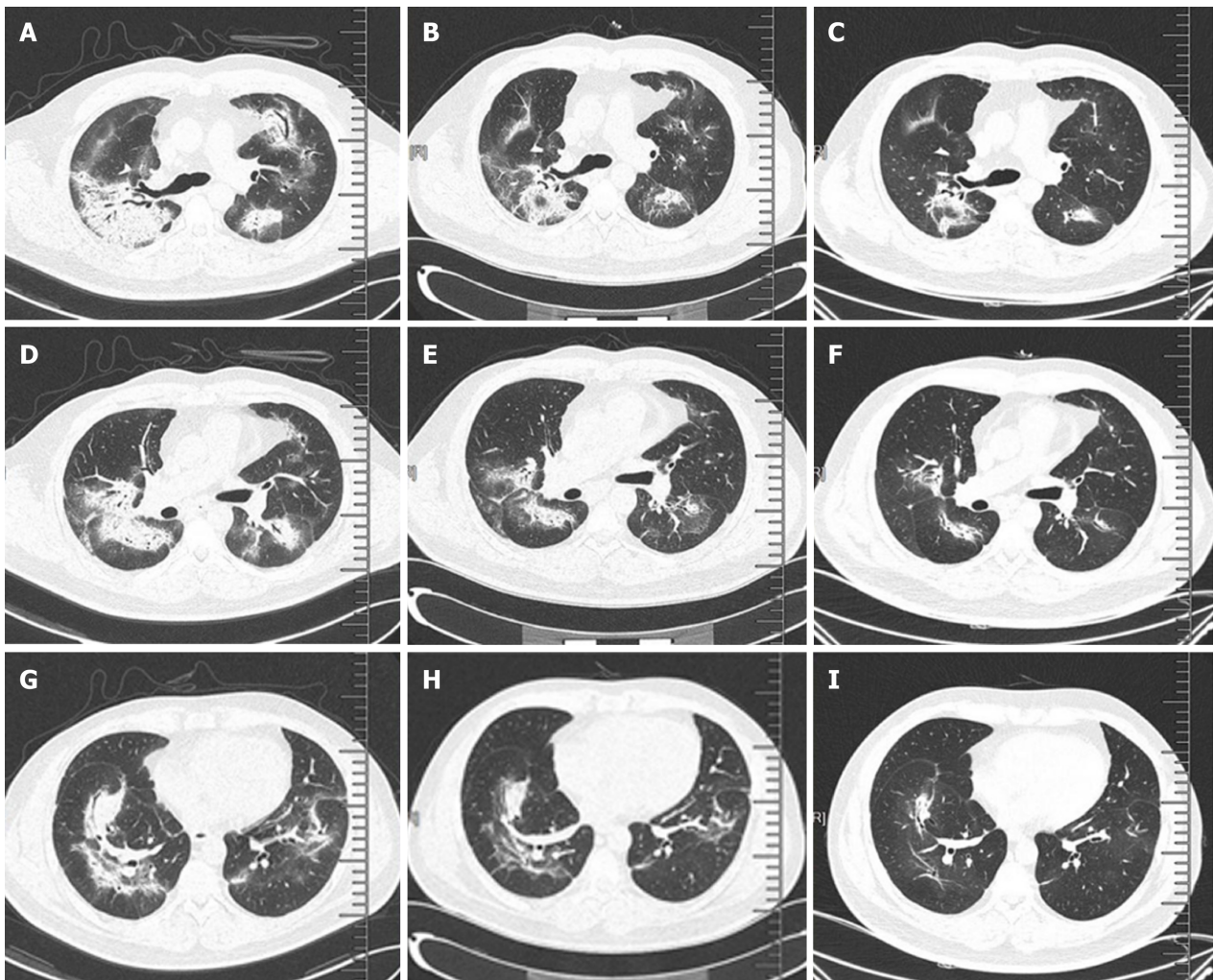


Figure 5 Pulmonary interstitial changes and review after hormone therapy. A, D, and G: Chest computed tomography (CT) scan (lung window) showed scattered high-density patches in both lungs, some with soft tissue density, and bronchial shadow in them; B, E, and H: One month after admission (one week after hormone therapy), chest CT scan (lung window) showed that the range of scattered high-density patches in both lungs was less than before; C, F, and I: Four months after hormone therapy, chest CT scan (lung window) showed that the range of scattered high-density patches in both lungs was further reduced than before.

REFERENCES

- 1 **Leukemia and Lymphoma Group, Chinese Society of Hematology, Chinese Medical Association.** Chinese expert consensus on the diagnosis and treatment of eosinophilia (2017). *Zhonghua Xue Ye Xue Za Zhi* 2017; **38**: 561-565 [PMID: 28810320 DOI: 10.3760/cma.j.issn.0253-2727.2017.07.001]
- 2 **Ogbogu PU, Bochner BS, Butterfield JH, Gleich GJ, Huss-Marp J, Kahn JE, Leiferman KM, Nutman TB, Pfab F, Ring J, Rothenberg ME, Roufosse F, Sajous MH, Sheikh J, Simon D, Simon HU, Stein ML, Wardlaw A, Weller PF, Klion AD.** Hypereosinophilic syndrome: a multicenter, retrospective analysis of clinical characteristics and response to therapy. *J Allergy Clin Immunol* 2009; **124**: 1319-25.e3 [PMID: 19910029 DOI: 10.1016/j.jaci.2009.09.022]
- 3 **Thompson AB, Barron MM, Lapp NL.** The hypereosinophilic syndrome presenting with eosinophilic mastitis. *Arch Intern Med* 1985; **145**: 564-565 [PMID: 4038872 DOI: 10.1001/archinte.145.3.564]
- 4 **Giudicelli CP, Didelot F, Duvic C, Desrame J, Herody M, Nedelec G.** Eosinophilia and renal pathology. *Med Trop (Mars)* 1998; **58**: 477-481 [PMID: 10410369]
- 5 **Walker A, Ellis J, Irama M, Senkungu J, Nansera D, Axton J, Coward RJ, Peat DS, Bode HH, Mathieson PW.** Eosinophilic glomerulonephritis in children in Southwestern Uganda. *Kidney Int* 2007; **71**: 569-573 [PMID: 17228362 DOI: 10.1038/sj.ki.5002085]
- 6 **Bulucu F, Can C, Inal V, Baykal Y, Eriği S.** Renal involvement in a patient with idiopathic hypereosinophilic syndrome. *Clin Nephrol* 2002; **57**: 171-173 [PMID: 11863130 DOI: 10.5414/CNP57171]
- 7 **Richardson P, Dickinson G, Nash S, Hoffman L, Steingart R, Germain M.** Crescentic glomerulonephritis and eosinophilic interstitial infiltrates in a patient with hypereosinophilic syndrome. *Postgrad Med J* 1995; **71**: 175-178 [PMID: 7746781 DOI: 10.1136/pgmj.71.833.175]
- 8 **Frigui M, Hmida MB, Jallouli M, Kechaou M, Frikha F, Bahloul Z.** Membranous glomerulopathy associated with idiopathic hypereosinophilic syndrome. *Saudi J Kidney Dis Transpl* 2010; **21**: 320-322 [PMID: 20228521]
- 9 **Zhong YL, Dang XQ.** Hypereosinophilic syndrome involving nephrotic syndrome: a case report. *Zhongguo Dang Dai Er Ke Za Zhi* 2011; **13**: 850-851 [PMID: 22000448]

- 10 **Grcevska L**, Polenaković M, Breskovska G. Focal segmental glomerular-sclerosis-like lesions associated with eosinophilic pneumonia and trimethoprim and penicillin treatment. *Nephron* 1993; **64**: 325-326 [PMID: [8321374](#) DOI: [10.1159/000187343](#)]
- 11 **Lakjiri S**, Meziane M, Benani A, Harmouch T, Amarti A, Mernissi FZ. Eosinophilic fasciitis, morphea and vitiligo in a single patient. *Ann Dermatol Venereol* 2014; **141**: 598-602 [PMID: [25288063](#) DOI: [10.1016/j.annder.2014.06.019](#)]
- 12 **Stork J**, Němcová D, Hoza J, Kodetová D. Eosinophilic fasciitis in an adolescent girl with lymphadenopathy and vitiligo-like and linear scleroderma-like changes. A case report. *Clin Exp Rheumatol* 1996; **14**: 337-341 [PMID: [8809452](#)]
- 13 **Roufosse F**, Weller PF. Practical approach to the patient with hypereosinophilia. *J Allergy Clin Immunol* 2010; **126**: 39-44 [PMID: [20538328](#) DOI: [10.1016/j.jaci.2010.04.011](#)]
- 14 **Dulohery MM**, Patel RR, Schneider F, Ryu JH. Lung involvement in hypereosinophilic syndromes. *Respir Med* 2011; **105**: 114-121 [PMID: [21036585](#) DOI: [10.1016/j.rmed.2010.09.011](#)]



Published By Baishideng Publishing Group Inc
7041 Koll Center Parkway, Suite 160, Pleasanton, CA 94566, USA
Telephone: +1-925-2238242
E-mail: bpgoffice@wjgnet.com
Help Desk: <https://www.f6publishing.com/helpdesk>
<https://www.wjgnet.com>

