

# World Journal of *Clinical Cases*

*World J Clin Cases* 2019 November 6; 7(21): 3384-3682





### EDITORIAL

- 3384** Current controversies in treating remnant gastric cancer: Are minimally invasive approaches feasible?  
*Ma FH, Liu H, Ma S, Li Y, Tian YT*

### ORIGINAL ARTICLE

#### Retrospective Study

- 3394** Efficient management of secondary haemophagocytic lymphohistiocytosis with intravenous steroids and  $\gamma$ -immunoglobulin infusions  
*Georgiadou S, Gatselis NK, Stefos A, Zachou K, Makaritsis K, Rigopoulou EI, Dalekos GN*
- 3407** Impress of intergenerational emotional support on the depression in non-cohabiting parents  
*Jia YH, Ye ZH*
- 3419** Nomograms for pre- and postoperative prediction of long-term survival among proximal gastric cancer patients: A large-scale, single-center retrospective study  
*Chen QY, Hong ZL, Zhong Q, Liu ZY, Huang XB, Que SJ, Li P, Xie JW, Wang JB, Lin JX, Lu J, Cao LL, Lin M, Tu RH, Zheng CH, Huang CM*

#### Observational Study

- 3436** Modified Cortex Mori Capsules improving the successful rate of functional filtering blebs after reclinical glaucoma filtering surgery  
*Yu J, Qiu LX, Qing GP, Zhao BW, Wang H*
- 3446** Effect of cognitive behavior therapy combined with exercise intervention on the cognitive bias and coping styles of diarrhea-predominant irritable bowel syndrome patients  
*Zhao SR, Ni XM, Zhang XA, Tian H*

#### Prospective Study

- 3463** Normal values of shear wave velocity in liver tissue of healthy children measured using the latest acoustic radiation force impulse technology  
*Sun PX, Tong YY, Shi J, Zhang H, Liu SJ, Du J*

### SYSTEMATIC REVIEW

- 3474** Characteristics of clear cell renal cell carcinoma metastases to the thyroid gland: A systematic review  
*Khaddour K, Marernych N, Ward WL, Liu J, Pappa T*
- 3486** Irritable bowel syndrome and functional constipation management with integrative medicine: A systematic review  
*Dai L, Zhong LL, Ji G*

- 3505** How about the reporting quality of case reports in nursing field?

*Yang KL, Lu CC, Sun Y, Cai YT, Wang B, Shang Y, Tian JH*

### CASE REPORT

- 3517** Gastro-gastric intussusception in the setting of a neuroendocrine tumor: A case report

*Zhornitskiy A, Le L, Tareen S, Abdullahi G, Karunasiri D, Tabibian JH*

- 3524** Retroperitoneal perivascular epithelioid cell tumours: A case report and review of literature

*Touloumis Z, Giannakou N, Sioros C, Trigka A, Cheilakea M, Dimitriou N, Griniatsos J*

- 3535** First Italian outbreak of VIM-producing *Serratia marcescens* in an adult polyvalent intensive care unit, August-October 2018: A case report and literature review

*Iovene MR, Pota V, Galdiero M, Corvino G, Di Lella FM, Stelitano D, Passavanti MB, Pace MC, Alfieri A, Di Franco S, Aurilio C, Sansone P, Niyas VKM, Fiore M*

- 3549** Transfemoral aortic valve implantation in the case of pre-existing mitral prosthesis and pure aortic regurgitation: A case report

*Erdem A, Esen Zencirci A, Ozden K, Terzi S*

- 3553** Methotrexate-related lymphoproliferative disorders in the liver: Case presentation and mini-review

*Mizusawa T, Kamimura K, Sato H, Suda T, Fukunari H, Hasegawa G, Shibata O, Morita S, Sakamaki A, Yokoyama J, Saito Y, Hori Y, Maruyama Y, Yoshimine F, Hoshi T, Morita S, Kanefuji T, Kobayashi M, Terai S*

- 3562** Re-revision surgery for re-recurrent valgus deformity after revision total knee arthroplasty in a patient with a severe valgus deformity: A case report

*Du YQ, Sun JY, Ni M, Zhou YG*

- 3569** Liver transplantation for severe portopulmonary hypertension: A case report and literature review

*Chen XJ, Zhu ZJ, Sun LY, Wei L, Zeng ZG, Liu Y, Qu W, Zhang L*

- 3575** Leiomyosarcoma of the stomach: A case report

*Kang WZ, Xue LY, Tian YT*

- 3583** Out-of-hospital cardiac arrest in a young adult survivor with sequelae of childhood Kawasaki disease: A case report

*Zhu KF, Tang LJ, Wu SZ, Tang YM*

- 3590** Squamous cell carcinoma of the nail bed: A case report

*Li PF, Zhu N, Lu H*

- 3595** Multidisciplinary treatment of a patient with necrotizing fasciitis caused by *Staphylococcus aureus*: A case report

*Xu LQ, Zhao XX, Wang PX, Yang J, Yang YM*

- 3603** Myocardial ischemic changes of electrocardiogram in intracerebral hemorrhage: A case report and review of literature  
*Lin XQ, Zheng LR*
- 3615** Adenomyoma of the distal common bile duct demonstrated by endoscopic ultrasound: A case report and review of the literature  
*Xu LM, Hu DM, Tang W, Wei SH, Chen W, Chen GQ*
- 3622** Child with Wiskott–Aldrich syndrome underwent atypical immune reconstruction after umbilical cord blood transplantation: A case report  
*Li BH, Hu SY*
- 3632** Epiphyseal distraction and hybrid reconstruction using polymethyl methacrylate construct combined with free non-vascularized fibular graft in pediatric patients with osteosarcoma around knee: A case report  
*Liang YH, He HB, Zhang C, Liu YP, Wan J*
- 3639** Bilateral common carotid artery common trunk with aberrant right subclavian artery combined with right subclavian steal syndrome: A case report  
*Sun YY, Zhang GM, Zhang YB, Du X, Su ML*
- 3649** Giant gastroduodenal trichobezoar: A case report  
*Dong ZH, Yin F, Du SL, Mo ZH*
- 3655** Compound heterozygous mutation of *MUSK* causing fetal akinesia deformation sequence syndrome: A case report  
*Li N, Qiao C, Lv Y, Yang T, Liu H, Yu WQ, Liu CX*
- 3662** Hypoparathyroidism with Fahr's syndrome: A case report and review of the literature  
*Zhou YY, Yang Y, Qiu HM*
- 3671** Primitive neuroectodermal tumors of the abdominal wall and vulva in children: Report of two cases and review of the literature  
*Xu QQ, Xing WW, Chen G, Dang YW, Luo YG, Chen P, Liang SW, Chen JB*

**ABOUT COVER**

Editorial Board Member of *World Journal of Clinical Cases*, Shiu-Yin Cho, MSc, Doctor, Department of Health, 286 Queen's Road East, Hong Kong, China

**AIMS AND SCOPE**

The primary aim of *World Journal of Clinical Cases* (WJCC, *World J Clin Cases*) is to provide scholars and readers from various fields of clinical medicine with a platform to publish high-quality clinical research articles and communicate their research findings online.

WJCC mainly publishes articles reporting research results and findings obtained in the field of clinical medicine and covering a wide range of topics, including case control studies, retrospective cohort studies, retrospective studies, clinical trials studies, observational studies, prospective studies, randomized controlled trials, randomized clinical trials, systematic reviews, meta-analysis, and case reports.

**INDEXING/ABSTRACTING**

The WJCC is now indexed in PubMed, PubMed Central, Science Citation Index Expanded (also known as SciSearch®), and Journal Citation Reports/Science Edition. The 2019 Edition of Journal Citation Reports cites the 2018 impact factor for WJCC as 1.153 (5-year impact factor: N/A), ranking WJCC as 99 among 160 journals in Medicine, General and Internal (quartile in category Q3).

**RESPONSIBLE EDITORS FOR THIS ISSUE**

Responsible Electronic Editor: *Yan-Xia Xing*

Proofing Production Department Director: *Xiang Li*

**NAME OF JOURNAL**

*World Journal of Clinical Cases*

**ISSN**

ISSN 2307-8960 (online)

**LAUNCH DATE**

April 16, 2013

**FREQUENCY**

Semimonthly

**EDITORS-IN-CHIEF**

Dennis A Bloomfield, Bao-Gan Peng, Sandro Vento

**EDITORIAL BOARD MEMBERS**

<https://www.wjnet.com/2307-8960/editorialboard.htm>

**EDITORIAL OFFICE**

Jin-Lei Wang, Director

**PUBLICATION DATE**

November 6, 2019

**COPYRIGHT**

© 2019 Baishideng Publishing Group Inc

**INSTRUCTIONS TO AUTHORS**

<https://www.wjnet.com/bpg/gerinfo/204>

**GUIDELINES FOR ETHICS DOCUMENTS**

<https://www.wjnet.com/bpg/GerInfo/287>

**GUIDELINES FOR NON-NATIVE SPEAKERS OF ENGLISH**

<https://www.wjnet.com/bpg/gerinfo/240>

**PUBLICATION MISCONDUCT**

<https://www.wjnet.com/bpg/gerinfo/208>

**ARTICLE PROCESSING CHARGE**

<https://www.wjnet.com/bpg/gerinfo/242>

**STEPS FOR SUBMITTING MANUSCRIPTS**

<https://www.wjnet.com/bpg/GerInfo/239>

**ONLINE SUBMISSION**

<https://www.f6publishing.com>

## Observational Study

## Modified Cortex Mori Capsules improving the successful rate of functional filtering blebs after reclinical glaucoma filtering surgery

Jing Yu, Li-Xin Qiu, Guo-Ping Qing, Bo-Wen Zhao, Hui Wang

**ORCID number:** Jing Yu (0000-0001-6910-0657); Li-Xin Qiu (0000-0003-2188-6501); Guo-Ping Qing (0000-0002-9273-9907); Bo-Wen Zhao (0000-0002-8988-126X); Hui Wang (0000-0003-0987-4348).

**Author contributions:** Qiu LX designed the research; Yu J, Qiu LX, Qing GP, Zhao BW and Wang H performed the research; Qing GP contributed new reagents/analytic tools; Yu J and Qiu LX analyzed the data; Yu J and Zhao BW wrote the paper.

**Institutional review board**

**statement:** The study protocol was approved by the institutional review board of Beijing Tongren Hospital in China.

**Informed consent statement:** The patient involved in this study gave written informed consent.

**Conflict-of-interest statement:** The authors report no conflicts of interest related to the subject matter of the manuscript.

**Data sharing statement:** No additional unpublished data are available.

**STROBE statement:** The authors have revised the manuscript according to the STROBE.

**Open-Access:** This article is an open-access article which was selected by an in-house editor and fully peer-reviewed by external reviewers. It is distributed in accordance with the Creative Commons Attribution Non Commercial (CC BY-NC 4.0) license, which permits others to

Jing Yu, Li-Xin Qiu, Guo-Ping Qing, Bo-Wen Zhao, Hui Wang, Beijing Tongren Eye Center, Laboratory of Ophthalmology and Visual Science in Beijing, Beijing Tongren Hospital, Capital Medical University, Beijing 100730, China

**Corresponding author:** Li-Xin Qiu, MD, PhD, Doctor, Beijing Tongren Eye Center, Laboratory of Ophthalmology and Visual Science in Beijing, Beijing Tongren Hospital, Capital Medical University, NO. 1 Dong Jiao Min Xiang, Dongcheng District, Beijing 100730, China.

[qiulixin65@163.com](mailto:qiulixin65@163.com)

**Telephone:** +86-10-58269604

**Fax:** +86-10-58269604

## Abstract

## BACKGROUND

The major reason for filtering bleb failure or scarring of the bleb site is due to excessive scarring after glaucoma filtration surgery in the clinic. Traditional Chinese medicine has preeminence in the prevention of fibrosis formation through the regulation of systemic circulation and improvement of the properties of the inflammatory cells in the blood.

## AIM

To examine the clinical efficacy of using the Modified Cortex Mori Capsules (MCMC; Chinese name: *Jiawei Sangbaipi Capsules*) in the success rate of functional filtering blebs after glaucoma filtering surgery in clinical patients.

## METHODS

Sixty resurgery glaucoma patients were randomly divided into two groups: 30 patients in surgery with the placebo group and 30 patients in surgery with the MCMC group. Patients took either the placebo or the MCMC 2 wk before and after surgery. Postoperative morphology and function filtering bleb, visual acuity, intraocular pressure, postoperative complications, the success rate of filtration surgery and clinical efficacy were observed.

## RESULTS

Fifty patients completed the study. The percentage of functional filtering blebs in the surgery plus MCMC group was 84% at 6 mo after surgery, which was higher than surgery plus placebo group (64%,  $P < 0.05$ ). The surgical success rate in the MCMC and placebo groups were  $79\% \pm 8.3\%$  and  $57\% \pm 10.6\%$  respectively ( $P < 0.05$ ). The visual acuity, intraocular pressure and the postoperative complications in the two groups had no significant differences.



distribute, remix, adapt, build upon this work non-commercially, and license their derivative works on different terms, provided the original work is properly cited and the use is non-commercial. See: <http://creativecommons.org/licenses/by-nc/4.0/>

**Manuscript source:** Unsolicited manuscript

**Received:** July 12, 2019

**Peer-review started:** July 16, 2019

**First decision:** September 9, 2019

**Revised:** September 27, 2019

**Accepted:** October 5, 2019

**Article in press:** October 5, 2019

**Published online:** November 6, 2019

**P-Reviewer:** Georgescu EF, Siddiqui I

**S-Editor:** Wang JL

**L-Editor:** Filipodia

**E-Editor:** Liu MY



## CONCLUSION

Glaucoma filtering surgery while taking MCMC not only reduced excessive scar formation and increased the success rate of functional filtering blebs but also improved the success of glaucoma filtration operations.

**Key words:** Glaucoma; Traditional Chinese medicine; Modified Cortex Mori Capsules; Jiawei Sangbaipi Capsules; Filtering bleb; Scar formation

©The Author(s) 2019. Published by Baishideng Publishing Group Inc. All rights reserved.

**Core tip:** Glaucoma is one of the leading causes of irreversible blindness.

Trabeculectomy is one of the effective surgical techniques, which creates a new drainage channel, resulting in the formation of a subconjunctival bleb. The major reason for filtering bleb failure or scarring of the bleb site is due to excessive scarring after surgery. In this study, we established that the Modified Cortex Mori Capsules have a propensity to increase functional filtering bleb formation and enhance surgical success rate after glaucoma filtering surgery. Intervening with traditional Chinese medicine could be an effective way for improving surgical success.

**Citation:** Yu J, Qiu LX, Qing GP, Zhao BW, Wang H. Modified Cortex Mori Capsules improving the successful rate of functional filtering blebs after reclinical glaucoma filtering surgery. *World J Clin Cases* 2019; 7(21): 3436-3445

**URL:** <https://www.wjgnet.com/2307-8960/full/v7/i21/3436.htm>

**DOI:** <https://dx.doi.org/10.12998/wjcc.v7.i21.3436>

## INTRODUCTION

Glaucoma is one of the leading causes of irreversible blindness worldwide, and it affects more than 70 million people with approximately 10% being bilaterally blind<sup>[1]</sup>. Glaucoma is an optic neuropathy characterized by the progressive degeneration of retinal ganglion cells<sup>[2-4]</sup>. Degeneration of these nerves results in visual field defects, optic disc cupping and visual loss<sup>[5]</sup>. The biological basis and pathological mechanisms of glaucoma remain poorly understood, and the factors contributing to its progression have not been fully described<sup>[6]</sup>. Slowing disease progression and preservation of quality of life are the main goals for glaucoma treatment.

Currently, reduction of intraocular pressure (IOP) is the only proven method to treat glaucoma<sup>[7]</sup>. Glaucoma filtering surgery is the most common treatment used to control IOP<sup>[8]</sup>. Trabeculectomy is an effective surgical option that creates a new drainage channel to filter aqueous humor from the anterior chamber to the outer surface of the sclera, resulting in the formation of a subconjunctival bleb and a decrease in IOP<sup>[9,10]</sup>. However, the filter can fail if scar tissue forms between the conjunctiva/Tenon's capsule and the sclera at the surgical site<sup>[11]</sup>. Scar formation is most commonly due to the proliferation of fibroblasts and the synthesis of the extracellular matrix (mainly collagen synthesis and glucose glycan ammonia)<sup>[12]</sup>. In current clinical practice, first-line perioperative antiproliferative drugs are 5-fluorouracil and mitomycin-C (MMC). MMC is an antitumor drug that inhibits fibroblast proliferation and alters conjunctival vascular epithelium<sup>[8]</sup>. It has improved the success rate of filtration surgery. MMC is nonspecific and can increase the risk of severe side effects such as cornea toxicity reaction, conjunctival wound leak, low IOP, etc<sup>[13,14]</sup>. Therefore, therapeutic agents that can either alone or with MMC improve the reduction of bleb scarring and inhibit complications need to be investigated.

In traditional Chinese medicine (TCM), the scar formation after glaucoma filtering surgery mostly belongs to Phlegm-heat. The Modified Cortex Mori Capsules (MCMC, Jiawei Sangbaipi Capsules) has been used to treat Phlegm-heat syndrome. The pharmaceutical composition of MCMC is based on the concept of TCM and can treat both the symptoms and the causes of glaucoma. It contains a combination of raw materials from herbs that can nourish vital energy, promote blood stasis and prevent bleeding, clear and/or soften phlegm, promote the absorption exudate, edema, and hemorrhage and reduce angiogenesis lesion, thereby improving functional filtering bleb formation. From a contemporary biological point of view, the compounds in the pharmaceutical composition could also target oxidative stress and inflammation. In

this study, we evaluate the clinical effects of MCMC on prevention scarring of the filtering bleb after trabeculectomy.

## MATERIALS AND METHODS

### Study subjects

The study protocol was approved by the institutional review board of Beijing Tongren Hospital in China and took place from Jan 2016 to Dec 2018. The inclusion criteria were as follows: (1) Subjects were 20–60 years old; (2) Subjects were diagnosed with primary angle-closure glaucoma and primary open-angle glaucoma; (3) Subjects underwent at least once trabeculectomy and needed resurgery; (4) Subjects diagnosed with Phlegm-heat in TCM dialectical syndrome: TCM syndrome diagnosis standards were according to Disease Diagnosis Curative of TCM 'Jin Gan' (phlyctenular conjunctivitis). Phlegm-heat dialectical syndrome was defined as phlyctenular conjunctivitis, conjunctival congestion, more secretions, dry eye, red tongue, yellow coating and rapid pulse; and (5) Subjects signed written informed consent.

Exclusion criteria were as follows: (1) Subjects had neovascular glaucoma and diagnosed as secondary glaucoma; (2) Subjects had scar diathesis; (3) Subjects had other eye diseases, including non-glaucomatous optic neuropathy or severe cataract; (4) Subjects had received cataract surgery within the previous 3 mo; (5) Subjects had a serious systemic disease or mental illness; (6) Subjects had uveitis, retinal detachment, optic nerve diseases or highly myopic eyes; (7) Subjects had significant cardiovascular, liver, kidney, or hematopoietic systems diseases, mental illness and other serious medical conditions; (8) Subjects were pregnant, planning to become pregnant or lactating; (9) Subjects were allergic to Chinese herbal medicines; and (10) Subjects had participated in any other clinical trials in the previous month.

### MCMC and placebo preparation

MCMC (*Jiawei Sangbaipi Capsules*) contains Cortex Mori (*Sangbaipi*), Bark of Chinese Wolfberry (*Digupi*), Root of Baikal Skullcap (*Huangqin*), Root of Dwarf Lilyturf (*Maidong*), Platycodon Root (*Jiegeng*), Fruit of Seville Orange (*Zhiqiao*), Chrysanthemum Flower (*Juhua*) and Inula Flower (*Xuanfuhua*). The herbs' quality was tested by our hospital TCM pharmacy. The capsule was made with an equal weight of all herbs (15 g) in our hospital TCM pharmacy. Each capsule contains 15 mg total herb medicine. The placebo was made with an equal weight of starch. Four capsules of MCMC or placebo were taken orally two times a day, 30 min after breakfast and dinner.

### Study protocol

From initial screening visits, 60 glaucoma patients with trabeculectomy resurgery were recruited from the eye department of Beijing Tongren Hospital in China. All subjects received standard treatment without any dietary intervention. A biostatistician conducted a stratified sample, the block randomization method. Patients were assigned into two groups: 30 patients receiving placebo and 30 patients receiving MCMC. After 6 mo, 50 patients completed the study.

Subjects were orally administered with MCMC capsules and placebo two times daily, 30 min after breakfast and dinner. Each capsule pill contained 15 mg of herbal medicine. The Pharmacy of Tongren Hospital provided all study medications. The treatment for each group started 2 wk before surgery and lasted 2 wk after surgery (four consecutive weeks).

### Glaucoma filtering operation

All patients underwent standard trabeculectomy by two specified ophthalmologists according to the modification of Cairns using a fornix-based conjunctival flap<sup>[15]</sup>. Briefly, the IOP must be controlled under 21 mmHg before surgery, and 20% mannitol intravenous may be used when necessary. After raising a fornix-based conjunctival flap, a rectangular 4 mm x 4 mm x 0.3 mm scleral flap was dissected at the 12-o'clock position. Surgical absorbent sponge pieces soaked in a 0.04% MMC solution prepared just before use were placed between the episclera and conjunctival flap for 5 min. After removal of the sponge pieces, the site was rinsed with 100 mL of balanced salt solution. Then, a 2 mm x 3 mm sclerotomy was created, after which a peripheral iridectomy was performed. The sclera flap was closed using two relatively loose 10-0 nylon sutures. Finally, the conjunctiva was closed and topical tobramycin 0.3% and dexamethasone 0.1% (Tobradex, Alcon Pharmaceuticals, Fort Worth, TX, United States) were given every day until the 6<sup>th</sup> week postoperatively.



### Clinical evaluation

Follow-up visits were scheduled at day 1, day 3, day 7, day 14, 1 mo, 3 mo and 6 mo after the operation. After 14 d, each examination included best-corrected visual acuity, the IOP (average of three separate readings), slit-lamp microscopy (including bleb appearance and anterior chamber inflammation), fundoscopic examination and visual field.

Four types of filtering bleb were diagnosed as follow: Type I (small cystic type): thin capsule wall, no vessels with tiny cystic; Type II (flat diffuse type): thicker capsule wall, flat, diffuse and pale filtering bleb; Type III (scar type): no filtering bleb or conjunctiva congestion, rich vessels and scarring on the filtering bleb; and Type IV (package type): cystic hyperplasia, limitations of uplift filtering bleb (Figure 1). Type I and Type II are functional filtering bleb, while Type III and Type IV are dysfunctional filtering bleb<sup>[6]</sup>.

The following indicators determined a successful surgery: (1) The IOP maintained under 15 mmHg after surgery; (2) No visual acuity progressive decrease; (3) No visual field continued damage; and (4) No cup-to-disc ratio increase.

The postoperative complication examination included corneal epithelium damage, conjunctiva wound leakage, shallow anterior chamber, uveitis, low IOP, choroid detachment, retinal detachment, hemorrhage, aggravate lens opacity, endophthalmitis and filtering bleb rupture.

### Statistical analysis

Categorical variables were analyzed using the chi-square test, and continuous variables were analyzed using the unpaired Student's *t*-test. The data were analyzed using SPSS software (version 19.0, SPSS Inc., Chicago, IL, United States). Correlation was considered significant as *P* value < 0.05.

## RESULTS

Sixty subjects who met the inclusion criteria in the clinic in the eye department of Beijing Tongren Hospital were enrolled in this study and were placed randomly into either the placebo or MCMC group. The mean age of the subjects was 40.5 years old, and among them 37 were female. The variance test of the IOP value, medicine intake and number of glaucoma surgeries had no significant difference between the two groups (Table 1). At the 6-mo follow up, 50 subjects had completed the study.

Six months after the operation, there were 84% functional filtering bleb in the combination surgery and MCMC group, while there were 64% functional filtering bleb in the surgery and placebo group. Comparison between the two groups had a significant difference (*P* < 0.05, Table 2 and Figure 2). The successful surgery was determined with the IOP controlled under 15 mmHg, no progressive visual acuity, visual field and optic disc damage. The rate of success 6 mon after surgery in the MCMC group was 79% ± 8.3 %, which was significantly higher than the placebo group (57% ± 10.6%, *P* < 0.05, Table 2 and Figures 2 and 3).

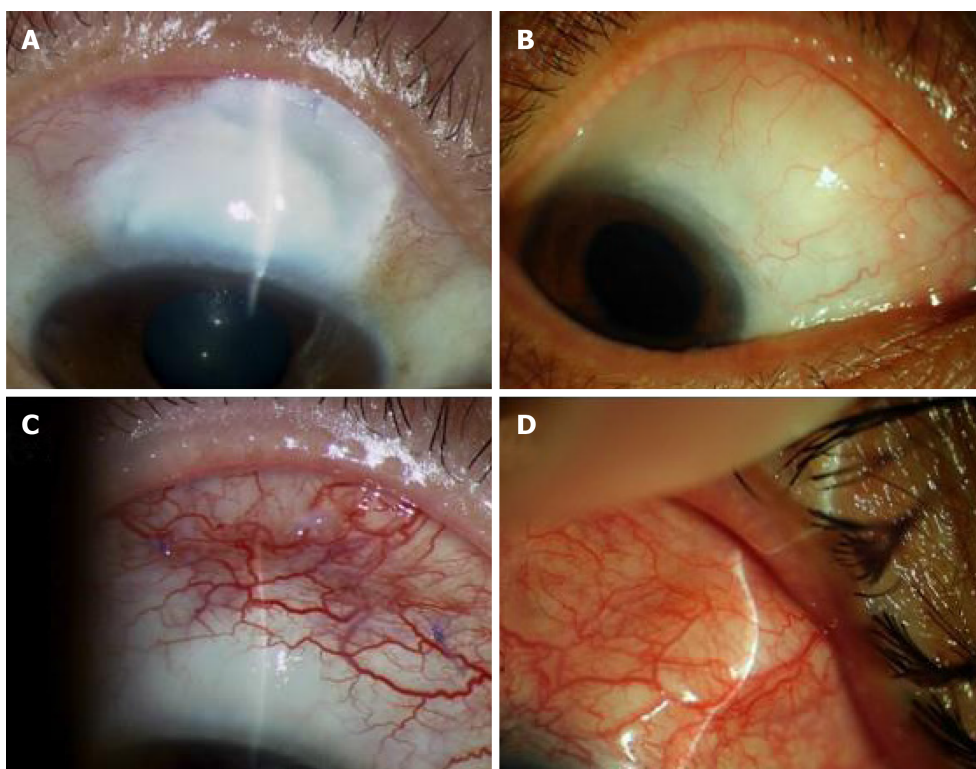
During the 6 mo follow up after trabeculectomy surgery, the complications including corneal epithelium damage, shallow anterior chamber and aggravated lens opacity, but there were no significant differences between the two groups (*P* > 0.05, Table 3). However, the MCMC group showed less local postoperative inflammation such as local blood congestions and swellings in the conjunctiva. The IOP measurement at different times showed a significant decrease in IOP value post operation and maintained around 15 mmHg in both the MCMC and placebo group (Figure 4). However, we observed the trend of the IOP level becoming more stable in the MCMC group compared to the placebo group.

No adverse effects with clinical signs were observed in the two groups during the study using the chi-square test. The number of reported minor adverse effects in the placebo was observed, but there was no statistically significant difference in the frequency of adverse effects between the groups (*P* = 0.622, Table 3).

## DISCUSSION

Glaucoma is one of the progressive eye diseases that cause irreversible blindness, and there are no cures so far. Currently, IOP is the primary and most effective proven therapeutic method<sup>[7,8]</sup>. Trabeculectomy is considered the gold standard in surgical management of glaucoma<sup>[17]</sup>. However, surgery failures often happen in some patients<sup>[18,19]</sup>.

The most prevalent reason for failure in filtration surgery is post operation scarring



**Figure 1 Four types of filtering bleb were diagnosed.** A: Type I (small cystic type): Thin capsule wall, no vessels with tiny cystic; B: Type II (flat diffuse type): Thicker capsule wall, flat, diffuse and pale filtering bleb; C: Type III (scar type): No filtering bleb or conjunctiva congestion, rich vessels and scarring on the filtering bleb; D: Type IV (package type): Cystic hyperplasias, limitations of uplift filtering bleb.

in the filtration path, and the failure rate reaches 15%-25% within two years post operation<sup>[20]</sup>. Due to the overhealing of subconjunctiva at the bleb and sclerotomy site, the successful rate of reoperation is only 36%-51%<sup>[21]</sup>; therefore scarring of the filtration path is the most intractable problem for filtration surgery. Currently, the first line of perioperative antiproliferative treatment is MMC. MMC is an antitumor antibiotic isolated from *Streptomyces*, inhibits the synthesis of DNA and protein, prevents fibroblasts, produces collagen material and improves the success rate of the filtration surgery. But still, some patients need surgery even with MMC because the time of MMC immersion is deficient. The efficacy of the antimetabolism treatment is transient or is due to the systemic conditions of the patient. Therefore, to find an effective, long-lasting alternative that can assist MMC with antiscarring is an important area for further investigation for glaucoma.

TCM is used in treating cancer, preventing carcinogenesis, inhibiting cell proliferation, arresting the cell cycle, inducing apoptosis, inhibiting angiogenesis and regulating immune function<sup>[22-24]</sup>. TCM is also used to inhibit myocardial fibrosis by inhibiting expression of inflammatory mediators associated with NF- $\kappa$ B signaling thereby blocking the upregulation of pro-inflammatory cytokines (IL-1 $\beta$ , TNF $\alpha$ ) and chemokine (MCP-1), macrophage infiltration and inactivating TGF- $\beta$ /Smad3 signaling. These actions suppress fibrosis including expression of fibronectin, collagen I and collagen IV<sup>[25,26]</sup>. TCM's mechanisms of action differ greatly from that of Western medicine. Whereas Western medicine employs purified molecules that exert a concentrated, single target effect, the effects of TCM are generally regarded as multifunctional and through a systemic regulation to affect the target. These effects are due to the complex formulation of herbal medicine that exerts global effects on multiple organ systems or targets. As we know, herbs contain many active components<sup>[27-29]</sup>. Thus, in many cases, using a general or crude extract that contains multiple active components is more biologically powerful than a purified extraction containing only one or a few active components<sup>[30]</sup>. The modern approach of using standardized extracts and herbal formulas can offer a high degree of quality control and standardization for a crude extract of TCM when they are used in the research of herbal bio effects, thus preserving the multisystem targets for neuroprotection that is possible from TCM tonics<sup>[31]</sup>.

Glaucoma belongs to "Lü Feng Nei Zhang" and/or "Qing Feng Nei Zhang" in the theory of TCM. According to TCM classical literature of "Shen Shi Yao Han" (written by Ren-Yu Fu *et al.*, 1671) and "Mu Jing Da Cheng" (Written by Ting-Jing Huang, 1741),

**Table 1** The variance text between surgery and placebo and surgery and Modified Cortex Mori Capsules

	Placebo	MCMC	P value
Gender	1.20 ± 0.23	1.19 ± 0.28 <sup>1</sup>	> 0.05
Age	40.30 ± 8.82	39.79 ± 6.15	> 0.05
IOP	38.20 ± 2.47	37.88 ± 3.16	> 0.05
C/D	0.70 ± 0.32	0.70 ± 0.17	> 0.05
Surgery times	1.35 ± 0.56	1.33 ± 0.53	> 0.05

<sup>1</sup>For male, <sup>2</sup>For female. MCMC: Modified cortex mori capsules.

the guidance of clinical practice in TCM ophthalmology is the theory of “Five Wheels of the Eye.” The bulbar conjunctiva and sclera in this theory are called “Bai Jing” and named “Qi Wheel.” These tissues’ corresponding organ is the “Lung,” and in the clinic of TCM ophthalmology, the conjunctiva and sclera diseases are treated often from “Lung” dysfunction. This perspective of TCM, the dysfunction of “lung heat” causes bulbar conjunctiva and sclera disorder or inflammation, which cause scarring. “Sang Bai Pi Tang” is a typical method that treats “lung heat” in clinics of TCM, such as chronic conjunctivitis, dry eye disease and shallow scleritis.

MCMC is the crude herb formula compound produced from the formula of “Sang Bai Pi Tang” and clinical experiences. In this study, MCMC can significantly improve functional filtering bleb formation, increase success rate of the surgery and decrease local inflammation. The MCMC formula contains *Sangbaipi*, *Digupi*, *Huangqin*, *Maidong*, *Jiegeng*, *Zhiqiao*, *Juhua* and *Xuanfuhua* that are strong and effective in clearing heat and moistening the lung, which could systemically regulate blood circulation and immune cell properties that were important for the local inflammation formation. Nevertheless, approving the efficacy of MCMC requires not only requires a large number of clinical trials and long-term observations but also requires *in vitro* experiments. Further animal experiments or cell culture may further identify the mechanism of MCMC in the improvement of the functional filtering blebs after reclinical glaucoma filtering surgery.

In conclusion, in this study, we established that MCMC has a propensity to increase functional filtering bleb formation and enhance surgical success rate after glaucoma filtering surgery. There is no significant difference in the postoperative complications between the MCMC and placebo groups. Intervening with TCM could be an effective way for improving surgical success, and it may open an avenue to treat glaucoma by combining TCM and western medicine.

**Table 2** The rate of functional filtering bleb

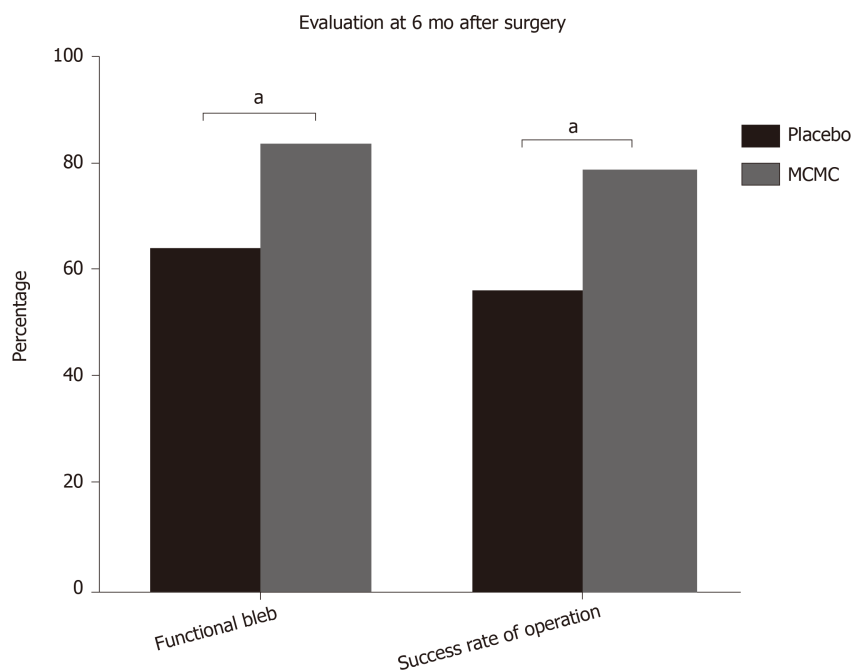
	Placebo	MCMC	<i>P</i> value
Functional filtering bleb	16	21	
Dysfunctional filtering bleb	9	4	
Rate, %	64	84	< 0.05

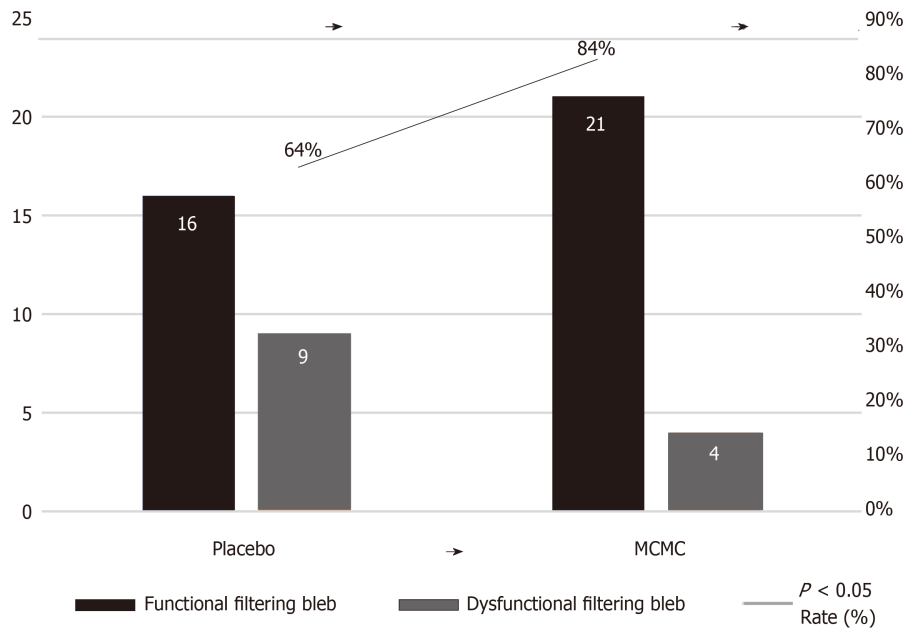
MCMC: Modified cortex mori capsules.

**Table 3** The complications after trabeculectomy surgery at 6 mo

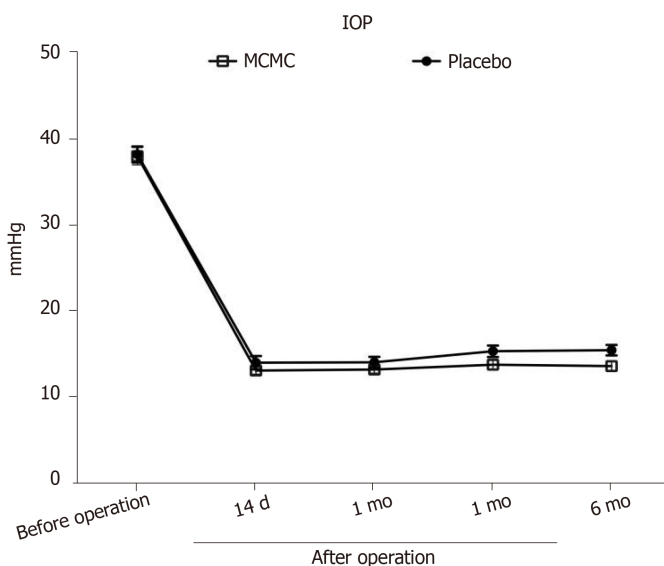
	Placebo	MCMC	<i>P</i> value
Corneal epithelium damage	7	5	> 0.05
Conjunctiva wound leakage	0	0	> 0.05
Shallow anterior chamber	2	1	> 0.05
Uveitis	0	0	> 0.05
Low IOP	0	0	> 0.05
Choroid detachment	0	0	> 0.05
Progressive lens opacity	2	2	> 0.05
Endophthalmitis	0	0	> 0.05
Filtering bleb rupture	0	0	> 0.05

IOP: Intraocular pressure; MCMC: Modified cortex mori capsules.

**Figure 2** Histogram shows percentage comparisons of the functional bleb and success rate of operation after 6 mo. Comparison between Modified Cortex Mori Capsules and placebo group were significantly different (<sup>a</sup>*P* < 0.05). MCMC: Modified Cortex Mori Capsules.



**Figure 3** The rate of functional filtering bleb. MCMC: Modified cortex mori capsules.



**Figure 4** Dynamic changes of intraocular pressure during pre-operation and postoperation at different time points. The results showed that the intraocular pressure level is similar pre-operation between the Modified Cortex Mori Capsules group and the placebo group. During the post-operative period, the IOP levels in the Modified Cortex Mori Capsules group were lower than the placebo but not significantly ( $P > 0.05$ ). IOP: Intraocular pressure; MCMC: Modified Cortex Mori Capsules.

## ARTICLE HIGHLIGHTS

### Research background

Trabeculectomy is one of the effective surgical techniques for glaucoma, which creates a new drainage channel, resulting in the formation of a subconjunctival bleb. Scarring of the bleb site is the main cause of the failure of the filter. Use of antiproliferative drugs has improved the success rate of the filtration surgery, but they also increase the risk of severe side effects. In our study, we established that the Modified Cortex Mori Capsules (MCMC) have a propensity to increase functional filtering bleb formation and enhance surgical success rate after glaucoma filtering surgery.

### Research motivation

To find an effective method to inhibit scar tissue formation at the filtering surgery surgical site.

According to the theory of traditional Chinese medicine (TCM), the scar formation after glaucoma filtering surgery mostly belongs to Phlegm-heat. The pharmaceutical composition of MCMC is based on the concept of TCM and can treat both the symptoms and the causes of the glaucoma. In this study, we evaluated the clinical effects of MCMC in prevention of scarring of the filtering bleb after trabeculectomy.

### Research objectives

Our aim was to examine the clinical effects by using MCMC (Chinese name: *Jiawei Sangbaipi Capsules*) in the success rate of functional filtering blebs after filtering surgery.

### Research methods

This study was a prospective clinical randomized controlled study. The enrollment of patients was in strict accordance with inclusion and exclusion criteria. Sixty postoperative patients were randomly divided into two groups: 30 patients in the surgery and placebo group and 30 patients in the surgery and MCMC group. Patients took the placebo or the MCMC 2 wk before and after surgery. Categorical variables and continuous variables were analyzed.

### Research results

The percentage of functional filtering blebs in MCMC group was 84% at 6 mo after surgery, which was significantly higher than placebo group. The surgical success rate in the MCMC group and the placebo group were 79%  $\pm$  8.3% and 57%  $\pm$  10.6%, respectively ( $P < 0.05$ ); Other indicators of the two groups had no significant differences. MCMC not only reduced excessive scar formation and increased success rate of functional filtering blebs but also improved the success of glaucoma filtration operations.

### Research conclusions

In this study, we observed that MCMC can significantly improve functional filtering bleb formation, increase success rate of the surgery and decrease local inflammation. The mechanisms of MCMC in improving the functional filtering blebs after reclinical glaucoma filtering surgery require further investigation.

### Research perspectives

Surgery is one of the most effective methods to treat glaucoma. The reasons that cause the failure of the surgery are very complicated. The theory of TCM recognizes glaucomatous postoperative signs differently than western medicine. TCM provides a new choice to improve the success rate of glaucoma filtering surgery. The efficacy of MCMC still needs large clinical trials and long-term observations as well as *in vitro* experiments.

## REFERENCES

- 1 Quigley HA, Broman AT. The number of people with glaucoma worldwide in 2010 and 2020. *Br J Ophthalmol* 2006; **90**: 262-267 [PMID: 16488940 DOI: 10.1136/bjo.2005.081224]
- 2 Kwon YH, Fingert JH, Kuehn MH, Alward WL. Primary open-angle glaucoma. *N Engl J Med* 2009; **360**: 1113-1124 [PMID: 19279343 DOI: 10.1056/NEJMra0804630]
- 3 Quigley HA, Dunkelberger GR, Green WR. Retinal ganglion cell atrophy correlated with automated perimetry in human eyes with glaucoma. *Am J Ophthalmol* 1989; **107**: 453-464 [PMID: 2712129 DOI: 10.1016/0002-9394(89)90488-1]
- 4 Kerrigan-Baumrind LA, Quigley HA, Pease ME, Kerrigan DF, Mitchell RS. Number of ganglion cells in glaucoma eyes compared with threshold visual field tests in the same persons. *Invest Ophthalmol Vis Sci* 2000; **41**: 741-748 [PMID: 10711689 DOI: 10.1097/00004397-200004000-00015]
- 5 Weinreb RN, Khaw PT. Primary open-angle glaucoma. *Lancet* 2004; **363**: 1711-1720 [PMID: 15158634 DOI: 10.1016/s0140-6736(04)16257-0]
- 6 Nickells RW, Howell GR, Soto I, John SW. Under pressure: cellular and molecular responses during glaucoma, a common neurodegeneration with axonopathy. *Annu Rev Neurosci* 2012; **35**: 153-179 [PMID: 22524788 DOI: 10.1146/annurev.neuro.051508.135728]
- 7 Heijl A, Leske MC, Bengtsson B, Hyman L, Bengtsson B, Hussein M; Early Manifest Glaucoma Trial Group. Reduction of intraocular pressure and glaucoma progression: results from the Early Manifest Glaucoma Trial. *Arch Ophthalmol* 2002; **120**: 1268-1279 [PMID: 12365904 DOI: 10.1001/archophth.120.10.1268]
- 8 Weinreb RN, Aung T, Medeiros FA. The pathophysiology and treatment of glaucoma: a review. *JAMA* 2014; **311**: 1901-1911 [PMID: 24825645 DOI: 10.1001/jama.2014.3192]
- 9 Cairns JE. Trabeculectomy. Preliminary report of a new method. *Am J Ophthalmol* 1968; **66**: 673-679 [PMID: 4891876 DOI: 10.1016/0002-9394(68)91288-9]
- 10 Razeghinejad MR, Fudenberg SJ, Spaeth GL. The changing conceptual basis of trabeculectomy: a review of past and current surgical techniques. *Surv Ophthalmol* 2012; **57**: 1-25 [PMID: 22137574 DOI: 10.1016/j.survophthal.2011.07.005]
- 11 Skuta GL, Parrish RK 2nd. Wound healing in glaucoma filtering surgery. *Surv Ophthalmol* 1987; **32**: 149-170 [PMID: 3328315 DOI: 10.1016/0039-6257(87)90091-9]
- 12 Chang L, Crowston JG, Cordeiro MF, Akbar AN, Khaw PT. The role of the immune system in conjunctival wound healing after glaucoma surgery. *Surv Ophthalmol* 2000; **45**: 49-68 [PMID: 10946081 DOI: 10.1016/s0039-6257(00)00135-1]
- 13 Bindlish R, Condon GP, Schlosser JD, D'Antonio J, Lauer KB, Lehrer R. Efficacy and safety of mitomycin-C in primary trabeculectomy: five-year follow-up. *Ophthalmology* 2002; **109**: 1336-41; discussion 1341-2 [PMID: 12093659 DOI: 10.1016/s0161-6420(02)01069-2]
- 14 Beckers HJ, Kinders KC, Webers CA. Five-year results of trabeculectomy with mitomycin C. *Graefes Arch Clin Exp Ophthalmol* 2003; **241**: 106-110 [PMID: 12605264 DOI: 10.1007/s00417-002-0621-5]



- 15 **Cairns JE.** Surgical treatment of primary open-angle glaucoma. *Trans Ophthalmol Soc U K* 1972; **92**: 745-756 [PMID: [4515550](#) DOI: [10.1016/j.jfo.2011.10.008](#)]
- 16 **Addicks EM, Quigley HA, Green WR, Robin AL.** Histologic characteristics of filtering blebs in glaucomatous eyes. *Arch Ophthalmol* 1983; **101**: 795-798 [PMID: [6847472](#) DOI: [10.1001/archophth.1983.01040010795021](#)]
- 17 **Agrawal P, Bradshaw SE.** Systematic Literature Review of Clinical and Economic Outcomes of Micro-Invasive Glaucoma Surgery (MIGS) in Primary Open-Angle Glaucoma. *Ophthalmol Ther* 2018; **7**: 49-73 [PMID: [29725860](#) DOI: [10.1007/s40123-018-0131-0](#)]
- 18 **Feiner L, Piltz-Seymour JR;** Collaborative Initial Glaucoma Treatment Study. Collaborative Initial Glaucoma Treatment Study: a summary of results to date. *Curr Opin Ophthalmol* 2003; **14**: 106-111 [PMID: [12698052](#) DOI: [10.1097/00055735-200304000-00010](#)]
- 19 **Edmunds B, Thompson JR, Salmon JF, Wormald RP.** The National Survey of Trabeculectomy. III. Early and late complications. *Eye (Lond)* 2002; **16**: 297-303 [PMID: [12032721](#) DOI: [10.1038/sj.eye.6700148](#)]
- 20 **Fourman S.** Effects of aminopropionitrile on glaucoma filter blebs in rabbits. *Ophthalmic Surg* 1988; **19**: 649-652 [PMID: [3186175](#) DOI: [10.1055/s-2008-1050266](#)]
- 21 **Law SK, Shih K, Tran DH, Coleman AL, Caprioli J.** Long-term outcomes of repeat vs initial trabeculectomy in open-angle glaucoma. *Am J Ophthalmol* 2009; **148**: 685-695.e1 [PMID: [19596220](#) DOI: [10.1016/j.ajo.2009.05.032](#)]
- 22 **Hu B, An HM, Wang SS, Chen JJ, Xu L.** Preventive and Therapeutic Effects of Chinese Herbal Compounds against Hepatocellular Carcinoma. *Molecules* 2016; **21**: 142 [PMID: [26828466](#) DOI: [10.3390/molecules21020142](#)]
- 23 **Lu XL, He SX, Ren MD, Wang YL, Zhang YX, Liu EQ.** Chemopreventive effect of saikosaponin-d on diethylnitrosamine-induced hepatocarcinogenesis: involvement of CCAAT/enhancer binding protein  $\beta$  and cyclooxygenase-2. *Mol Med Rep* 2012; **5**: 637-644 [PMID: [22159471](#) DOI: [10.3892/mmr.2011.702](#)]
- 24 **Rui W, Xie L, Liu X, He S, Wu C, Zhang X, Zhang L, Yang Y.** Compound Astragalus and Salvia miltiorrhiza extract suppresses hepatocellular carcinoma progression by inhibiting fibrosis and PAI-1 mRNA transcription. *J Ethnopharmacol* 2014; **151**: 198-209 [PMID: [24247078](#) DOI: [10.1016/j.jep.2013.10.022](#)]
- 25 **Zhao T, Sun S, Zhang H, Huang X, Yan M, Dong X, Wen Y, Wang H, Lan HY, Li P.** Therapeutic Effects of Tangshen Formula on Diabetic Nephropathy in Rats. *PLoS One* 2016; **11**: e0147693 [PMID: [26807792](#) DOI: [10.1371/journal.pone.0147693](#)]
- 26 **Ding YF, Peng YR, Shen H, Shu L, Wei YJ.** Gualou Xiebai decoction inhibits cardiac dysfunction and inflammation in cardiac fibrosis rats. *BMC Complement Altern Med* 2016; **16**: 49 [PMID: [26846090](#) DOI: [10.1186/s12906-016-1012-5](#)]
- 27 **Chang RC, So KF.** Use of anti-aging herbal medicine, Lycium barbarum, against aging-associated diseases. What do we know so far? *Cell Mol Neurobiol* 2008; **28**: 643-652 [PMID: [17710531](#) DOI: [10.1007/s10571-007-9181-x](#)]
- 28 **Li HL, Ashpole NE, Navarro ID, Lam TC, Chan HL, To CH, Stamer WD, Do CW.** *Baicalin lowers intraocular pressure and increases outflow facility in mouse eye.* Denver: Association for Research in Vision and Ophthalmology 2015; 4853-A0006
- 29 **Man D, Huang Y, Zhang H.** Effects observation of treating glaucoma by trabeculectomy plus TCM. *Zhongyi Linchuang Yanjiu* 2011; **14**: 1674-1680
- 30 **Luo Q, Cai Y, Yan J, Sun M, Corke H.** Hypoglycemic and hypolipidemic effects and antioxidant activity of fruit extracts from Lycium barbarum. *Life Sci* 2004; **76**: 137-149 [PMID: [15519360](#) DOI: [10.1016/j.lfs.2004.04.056](#)]
- 31 **Sun ZK, Yang HQ, Chen SD.** Traditional Chinese medicine: a promising candidate for the treatment of Alzheimer's disease. *Transl Neurodegener* 2013; **2**: 6 [PMID: [23445907](#) DOI: [10.1186/2047-9158-2-6](#)]



Published By Baishideng Publishing Group Inc  
7041 Koll Center Parkway, Suite 160, Pleasanton, CA 94566, USA  
Telephone: +1-925-2238242  
E-mail: [bpgoffice@wjgnet.com](mailto:bpgoffice@wjgnet.com)  
Help Desk: <https://www.f6publishing.com/helpdesk>  
<https://www.wjgnet.com>

