

World Journal of *Clinical Cases*

World J Clin Cases 2019 December 6; 7(23): 3915-4171



**REVIEW**

- 3915** Overview of organic anion transporters and organic anion transporter polypeptides and their roles in the liver
Li TT, An JX, Xu JY, Tuo BG

ORIGINAL ARTICLE**Observational Study**

- 3934** Value of early diagnosis of sepsis complicated with acute kidney injury by renal contrast-enhanced ultrasound
Wang XY, Pang YP, Jiang T, Wang S, Li JT, Shi BM, Yu C
- 3945** Value of elastography point quantification in improving the diagnostic accuracy of early diabetic kidney disease
Liu QY, Duan Q, Fu XH, Fu LQ, Xia HW, Wan YL
- 3957** Resection of recurrent third branchial cleft fistulas assisted by flexible pharyngotomy
Ding XQ, Zhu X, Li L, Feng X, Huang ZC
- 3964** Therapeutic efficacy of acupuncture combined with neuromuscular joint facilitation in treatment of hemiplegic shoulder pain
Wei YH, Du DC, Jiang K
- 3971** Comparison of intra-articular injection of parecoxib *vs* oral administration of celecoxib for the clinical efficacy in the treatment of early knee osteoarthritis
Lu L, Xie Y, Gan K, Huang XW

Retrospective Study

- 3980** Celiomesenteric trunk: New classification based on multidetector computed tomography angiographic findings and probable embryological mechanisms
Tang W, Shi J, Kuang LQ, Tang SY, Wang Y

Prospective Study

- 3990** Interaction of arylsulfatases A and B with maspin: A possible explanation for dysregulation of tumor cell metabolism and invasive potential of colorectal cancer
Kovacs Z, Jung I, Szalman K, Baniás L, Bara TJ, Gurzu S

CASE REPORT

- 4004** Recuperation of severe tumoral calcinosis in a dialysis patient: A case report
Westermann L, Isbell LK, Breitenfeldt MK, Arnold F, Röthele E, Schneider J, Widmeier E

- 4011** Robotic wedge resection of a rare gastric perivascular epithelioid cell tumor: A case report
Marano A, Maione F, Woo Y, Pellegrino L, Geretto P, Sasia D, Fortunato M, Orcioni GF, Priotto R, Fasoli R, Borghi F
- 4020** Primary parahiatal hernias: A case report and review of the literature
Preda SD, Pătrașcu Ș, Ungureanu BS, Cristian D, Bințișan V, Nica CM, Calu V, Strâmbu V, Sapalidis K, Șurlin VM
- 4029** Diagnosis of Laron syndrome using monoplex-polymerase chain reaction technology with a whole-genome amplification template: A case report
Neumann A, Alcántara-Ortigoza MÁ, González-del Ángel A, Camargo-Diaz F, López-Bayghen E
- 4036** *In-vitro* proliferation assay with recycled ascitic cancer cells in malignant pleural mesothelioma: A case report
Anayama T, Taguchi M, Tatenuma T, Okada H, Miyazaki R, Hirohashi K, Kume M, Matsusaki K, Orihashi K
- 4044** Distant metastasis in choroidal melanoma with spontaneous corneal perforation and intratumoral calcification: A case report
Wang TW, Liu HW, Bee YS
- 4052** Secondary Parkinson disease caused by breast cancer during pregnancy: A case report
Li L
- 4057** Pulmonary embolism and deep vein thrombosis caused by nitrous oxide abuse: A case report
Sun W, Liao JP, Hu Y, Zhang W, Ma J, Wang GF
- 4063** Micronodular thymic tumor with lymphoid stroma: A case report and review of the literature
Wang B, Li K, Song QK, Wang XH, Yang L, Zhang HL, Zhong DR
- 4075** Diffuse large B cell lymphoma with bilateral adrenal and hypothalamic involvement: A case report and literature review
An P, Chen K, Yang GQ, Dou JT, Chen YL, Jin XY, Wang XL, Mu YM, Wang QS
- 4084** Urethral pressure profilometry in artificial urinary sphincter implantation: A case report
Meng LF, Liu XD, Wang M, Zhang W, Zhang YG
- 4091** Hydroxyurea-induced cutaneous squamous cell carcinoma: A case report
Xu Y, Liu J
- 4098** Recurrent hypotension induced by sacubitril/valsartan in cardiomyopathy secondary to Duchenne muscular dystrophy: A case report
Li JM, Chen H
- 4106** Complete duodenal obstruction induced by groove pancreatitis: A case report
Wang YL, Tong CH, Yu JH, Chen ZL, Fu H, Yang JH, Zhu X, Lu BC

- 4111** Radiological aspects of giant hepatocellular adenoma of the left liver: A case report
Zheng LP, Hu CD, Wang J, Chen XJ, Shen YY
- 4119** Mixed serous-neuroendocrine neoplasm of the pancreas: A case report and review of the literature
Xu YM, Li ZW, Wu HY, Fan XS, Sun Q
- 4130** Rigid esophagoscopy combined with angle endoscopy for treatment of superior mediastinal foreign bodies penetrating into the esophagus caused by neck trauma: A case report
Wang D, Gao CB
- 4137** Left armpit subcutaneous metastasis of gastric cancer: A case report
He FJ, Zhang P, Wang MJ, Chen Y, Zhuang W
- 4144** Bouveret syndrome: A case report
Wang F, Du ZQ, Chen YL, Chen TM, Wang Y, Zhou XR
- 4150** Fatal complications in a patient with severe multi-space infections in the oral and maxillofacial head and neck regions: A case report
Dai TG, Ran HB, Qiu YX, Xu B, Cheng JQ, Liu YK
- 4157** Management of massive fistula bleeding after endoscopic ultrasound-guided pancreatic pseudocyst drainage using hemostatic forceps: A case report
Ge N, Sun SY
- 4163** Pure squamous cell carcinoma of the gallbladder locally invading the liver and abdominal cavity: A case report and review of the literature
Jin S, Zhang L, Wei YF, Zhang HJ, Wang CY, Zou H, Hu JM, Jiang JF, Pang LJ

ABOUT COVER

Editorial Board Member of *World Journal of Clinical Cases*, Consolato M Sergi, FRCP (C), MD, PhD, Professor, Department of Lab Medicine and Pathology, University of Alberta, Edmonton T6G 2B7, Canada

AIMS AND SCOPE

The primary aim of *World Journal of Clinical Cases* (WJCC, *World J Clin Cases*) is to provide scholars and readers from various fields of clinical medicine with a platform to publish high-quality clinical research articles and communicate their research findings online.

WJCC mainly publishes articles reporting research results and findings obtained in the field of clinical medicine and covering a wide range of topics, including case control studies, retrospective cohort studies, retrospective studies, clinical trials studies, observational studies, prospective studies, randomized controlled trials, randomized clinical trials, systematic reviews, meta-analysis, and case reports.

INDEXING/ABSTRACTING

The WJCC is now indexed in PubMed, PubMed Central, Science Citation Index Expanded (also known as SciSearch®), and Journal Citation Reports/Science Edition. The 2019 Edition of Journal Citation Reports cites the 2018 impact factor for WJCC as 1.153 (5-year impact factor: N/A), ranking WJCC as 99 among 160 journals in Medicine, General and Internal (quartile in category Q3).

RESPONSIBLE EDITORS FOR THIS ISSUE

Responsible Electronic Editor: *Yan-Xia Xing*

Proofing Production Department Director: *Xiang Li*

NAME OF JOURNAL

World Journal of Clinical Cases

ISSN

ISSN 2307-8960 (online)

LAUNCH DATE

April 16, 2013

FREQUENCY

Semimonthly

EDITORS-IN-CHIEF

Dennis A Bloomfield, Bao-Gan Peng, Sandro Vento

EDITORIAL BOARD MEMBERS

<https://www.wjnet.com/2307-8960/editorialboard.htm>

EDITORIAL OFFICE

Jin-Lei Wang, Director

PUBLICATION DATE

December 6, 2019

COPYRIGHT

© 2019 Baishideng Publishing Group Inc

INSTRUCTIONS TO AUTHORS

<https://www.wjnet.com/bpg/gerinfo/204>

GUIDELINES FOR ETHICS DOCUMENTS

<https://www.wjnet.com/bpg/GerInfo/287>

GUIDELINES FOR NON-NATIVE SPEAKERS OF ENGLISH

<https://www.wjnet.com/bpg/gerinfo/240>

PUBLICATION MISCONDUCT

<https://www.wjnet.com/bpg/gerinfo/208>

ARTICLE PROCESSING CHARGE

<https://www.wjnet.com/bpg/gerinfo/242>

STEPS FOR SUBMITTING MANUSCRIPTS

<https://www.wjnet.com/bpg/GerInfo/239>

ONLINE SUBMISSION

<https://www.f6publishing.com>



Pulmonary embolism and deep vein thrombosis caused by nitrous oxide abuse: A case report

Wen Sun, Ji-Ping Liao, Yan Hu, Wei Zhang, Jing Ma, Guang-Fa Wang

ORCID number: Wen Sun (0000-0002-9209-4889); Ji-Ping Liao (000-0003-2007-1917); Yan Hu (0000-0003-1908-4892); Wei Zhang (0000-0001-8081-1134); Jing Ma (0000-0003-3902-0917); Guang-Fa Wang (0000-0001-5949-2124).

Author contributions: All authors contributed to the acquisition of data and the writing and revision of the manuscript.

Informed consent statement: Consent was obtained from the patient for publication of this report and any accompanying images.

Conflict-of-interest statement: All the authors declare that they have no conflict of interest.

CARE Checklist (2016) statement: The manuscript was prepared and revised according to the CARE Checklist (2016).

Open-Access: This article is an open-access article which was selected by an in-house editor and fully peer-reviewed by external reviewers. It is distributed in accordance with the Creative Commons Attribution Non Commercial (CC BY-NC 4.0) license, which permits others to distribute, remix, adapt, build upon this work non-commercially, and license their derivative works on different terms, provided the original work is properly cited and the use is non-commercial. See: <http://creativecommons.org/licenses/by-nc/4.0/>

Manuscript source: Unsolicited manuscript

Wen Sun, Ji-Ping Liao, Yan Hu, Wei Zhang, Jing Ma, Guang-Fa Wang Department of Pulmonary and Critical Care Medicine, Peking University First Hospital, Beijing 100034, China

Corresponding author: Ji-Ping Liao, MD, Professor, Associate Chief, Department of Pulmonary and Critical Care Medicine, Peking University First Hospital, No. 8, Xishiku Street, Xicheng District, Beijing 100034, China. jipingliao@hotmail.com
Telephone: +86-10-83575753
Fax: +86-10-66551208

Abstract

BACKGROUND

Nitrous oxide (N₂O) has gained increasing popularity as a recreational drug, causing hallucinations, excitation, and psychological dependence. However, side effects have been reported in recent years. Our case report proposes a correlation among N₂O, pulmonary embolism (PE), and deep vein thrombosis (DVT) and emphasizes the role of homocysteine (Hcy) in thrombotic events.

CASE SUMMARY

A 29-year-old man with long-term N₂O abuse sought evaluation after acute chest pain. A diagnostic workup revealed PE, DVT, and hyperhomocysteinemia. The patient was successfully treated with thrombolytic and anticoagulant therapy. Moreover, his Hcy level decreased and returned to normal after Hcy-lowering therapy.

CONCLUSION

Chronic N₂O abuse might increase the risk of PE and DVT, although there have been few studies previously.

Key words: Nitrous oxide; Pulmonary embolism; Deep vein thrombosis; Homocysteine; Case report

©The Author(s) 2019. Published by Baishideng Publishing Group Inc. All rights reserved.

Core tip: Pulmonary embolism and deep vein thrombosis arising from nitrous oxide use are extremely rare, although the mechanism seems reasonable, and few cases have been reported. In this case, chronic nitrous oxide abuse might be a direct or an indirect factor contributing to pulmonary embolism and deep vein thrombosis. Moreover, the treatment is unknown, and the prognosis is uncertain. Thus, we report this rare case and include a detailed discussion.

Received: August 16, 2019

Peer-review started: August 16, 2019

First decision: October 24, 2019

Revised: November 4, 2019

Accepted: November 14, 2019

Article in press: November 14, 2019

Published online: December 6, 2019

P-Reviewer: Bazeed MF, Chiu KW, Tajiri K

S-Editor: Zhang L

L-Editor: Wang TQ

E-Editor: Liu MY



Citation: Sun W, Liao JP, Hu Y, Zhang W, Ma J, Wang GF. Pulmonary embolism and deep vein thrombosis caused by nitrous oxide abuse: A case report. *World J Clin Cases* 2019; 7(23): 4057-4062

URL: <https://www.wjgnet.com/2307-8960/full/v7/i23/4057.htm>

DOI: <https://dx.doi.org/10.12998/wjcc.v7.i23.4057>

INTRODUCTION

Nitrous oxide (N_2O) is a small and simple inorganic chemical molecule that has been used for more than 150 years in clinical practice due to its analgesic, anxiolytic, and anesthetic properties^[1].

Pulmonary embolism (PE) refers to obstruction of the pulmonary artery or one of its branches by an embolus such as a thrombus, tumor, air, or fat. Together with deep vein thrombosis (DVT), PE is a form of venous thromboembolism (VTE) that is common and sometimes fatal in acute situations or disabling in the chronic phase^[2].

N_2O is correlated with hyperhomocysteinemia (HHcy) to some extent, and the latter has been found to be a potential risk factor for VTE. To the best of our knowledge, there are only a few reports of PE and DVT that were possibly triggered by HHcy secondary to N_2O use.

CASE PRESENTATION

Chief complaints

Sudden-onset chest pain for 1 d.

History of present illness

A 29-year-old man complained of sudden precordial pain with no remission for 1 d prior to hospital admission but denied hemoptysis, dyspnea, or syncope. He sought evaluation and was admitted for the purpose of intensive examination and treatment.

History of past illness

The patient had been addicted to N_2O for 1 year; as a result, peripheral neuropathy had occurred and was treated with vitamin B12 (Vit B₁₂). His medical history included poor blood glucose control and anxiety. However, he had no history of thrombosis, malignant tumor, recent trauma, or prolonged air travel.

Personal and family history

The patient has smoked over 13 pack-years and did not have alcoholism or a positive family history.

Physical examination upon admission

The initial assessment revealed that the patient was overweight and fragile, with a body mass index of 31.12 kg/m², temperature of 36.3 °C, blood pressure of 110-120/70-80 mmHg, heart rate over 110 beats/min, respiratory rate over 30 breaths/min, and pulse oximetry of 93% when the fraction of inspired oxygen was 49%. Moreover, the physical examination indicated diminished breath sounds on both sides and the accentuation of pulmonic second sounds.

Laboratory examinations

Laboratory data showed a high leukocyte count and an increased hemoglobin level, suggested abnormal liver biochemistry and hyperlipidemia, and revealed HHcy (24.12 μmol/L), high Vit B₁₂ (734 μmol/L), and normal folate (14.39 nmol/L). The results of the protein S, protein C, anti-thrombin III antibody, anti-cardiolipin antibody, lupus anticoagulant, anti-β₂gp1 autoantibody, and other autoantibodies were within normal limits. The clotting profile was normal, other than the D-dimer value (1.13 mg/L), and thrombophilia screening was negative. As markers in the risk stratification of PE, the levels of brain natriuretic peptide (BNP) and cardiac troponin I (CTnI) were 533 pg/mL and 0.334 ng/mL, respectively. Arterial blood gas levels measured with an oxygen concentration of 49% showed the following: pH, 7.44; PaCO₂, 30 mmHg; and PaO₂, 74 mmHg.

Imaging examinations

An electrocardiogram (ECG, **Figure 1A**) showed sinus tachycardia with typical

changes on SIQIIIITI (S wave in the aVL lead, Q wave and T wave in the III lead). Ultrasonic cardiogram demonstrated right ventricular enlargement with left ventricular compression. Color Doppler scans were used to explore femoral, popliteal, and calf muscular venous thrombosis in the right extremity. Computed tomographic pulmonary angiography (CTPA) revealed occlusion of the pulmonary artery trunk, lobar artery, and arterial branches on both sides and signs of increased right heart load (Figure 2A and B).

FINAL DIAGNOSIS

Moderate-high risk PE and DVT along with N₂O abuse.

TREATMENT

The patient received a diagnosis of acute massive PE and newly discovered proximal and distal DVT, which was treated with a half dose of alteplase (50 mg) intravenously over two hours and anticoagulant therapy, and the HHcy was treated with folate.

OUTCOME AND FOLLOW-UP

After treatment, the laboratory parameters, including D-dimer, CTnI, BNP, and HCY levels, approached normal levels, the abnormal ECG waves disappeared on re-examination (Figure 1B), the areas of embolization were reduced on repeat CTPA (Figure 2C and Figure 2D) and finally disappeared, but the old lower extremity thrombosis still existed. Our patient was no longer taking N₂O in regular follow-up.

DISCUSSION

Research reports on the correlation between N₂O and VTE are very rare, although the mechanism seems reasonable. Chronic N₂O abuse is known to decrease active VitB₁₂ levels, inhibit methionine synthase, which plays a key role in the metabolism of methionine and folate, and eventually result in HHcy and thrombosis^[3]. In a case of aortic arch thrombus caused by N₂O, the HCY level was decreased when N₂O use was stopped and then increased upon N₂O reuse^[4].

N₂O may be one of the initial factors that caused PE. Previous research^[5] supported that elimination of N₂O from the inspired gas rapidly reduced pulmonary artery pressure, decreased wasted ventilation, and increased cardiac output in non-lethal venous air embolism. However, the data are insufficient to perform a meta-analysis on the relationship between N₂O and PE^[6], and ENIGMA-II trials showed that the number of acute HHcy cases after N₂O exposure was negligible^[7]. This obvious inconsistency may be due to different entrance conditions and a lower concentration and shorter duration of N₂O in such trials.

HHcy has been found to be an intermediate factor for arterial and venous thrombosis^[4,8-10]. As a potential risk factor for cardiovascular disease, HHcy may cause endothelium dysfunction, platelet and clotting activation, impaired fibrinolysis, and a shift of the balance of methylation^[8,11-12]. Meanwhile, the relative risk for VTE in patients with HHcy is 2.5-2.95 that of the normal population^[13-14]. Approximately 25% of patients with VTE have HHcy. In contrast, approximately one-third of HHcy patients subsequently develop VTE, and these patients have a 3.99-fold increased risk for PE^[12].

HHcy may also be a risk factor for recurrent VTE. A multicenter study^[15] prospectively followed patients with single idiopathic VTE after oral anticoagulant withdrawal and found that HHcy patients were more likely to have recurrent VTE than those with normal Hcy levels. In addition, other studies^[16] have shown that HHcy complicated with PE may lead to aggravated pulmonary circulation and unstable hemodynamics by increasing the release of vascular endothelial inflammatory factors.

In this case, the young man had abused N₂O for a long time and had a previous history of peripheral neuropathy. In this patient with no evidence of thrombophilia, PE and DVT were diagnosed successively with the presence of HHcy. Considering his medical history and examination data, we suggested that N₂O abuse was possibly a key link to PE, even though other risk factors for venous thrombosis were present, including lack of exercise, smoking, and obesity.

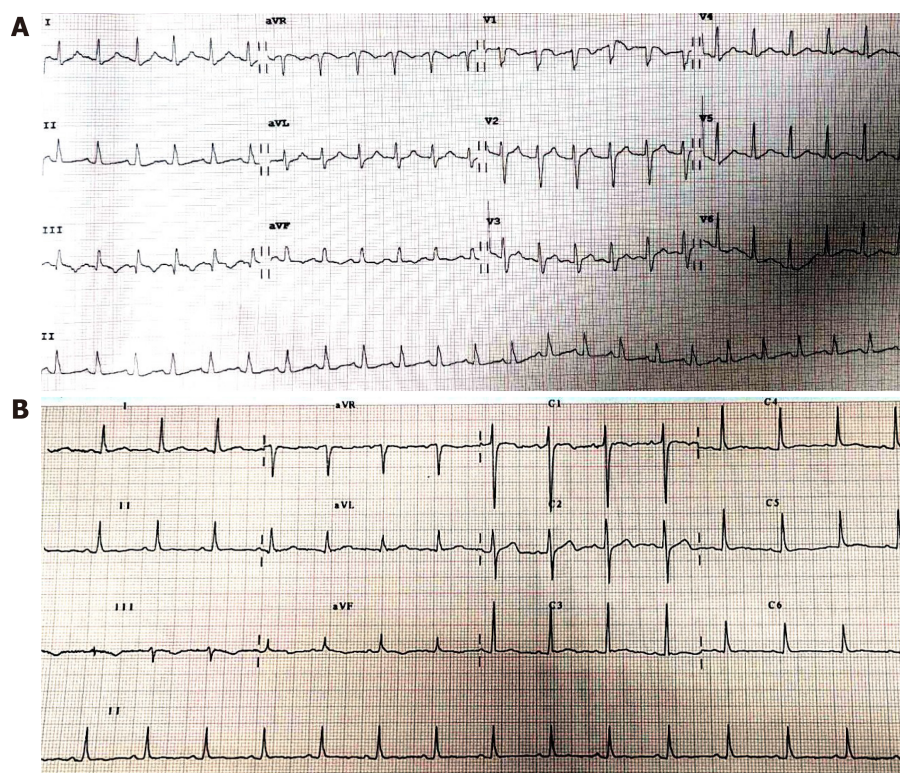


Figure 1 Electrocardiogram before and after thrombolysis. A: Electrocardiogram (ECG) before thrombolysis showed (as indicated by arrows) S wave in I lead (SI), Q wave in III lead (QIII), and negative T wave in III lead (TIII); B: ECG changes after thrombolysis were: SI decreased, QIII disappeared, and TIII wave inversion shallowed.

Although elevated HCY levels can be decreased by 25% by daily use of a folic acid supplement, even at a low dose of 0.5 mg, and by VitB₆ and B₁₂ supplementation, whether this reduces the incidence and recurrence rates of VTE is still controversial^[17]. In a case^[9] of upper extremity deep vein thrombosis and pulmonary embolism in a patient with methylene tetrahydrofolate reductase deficiency-related HHcy, vitamin and folic acid supplementation were suggested until the levels were in normal ranges. Additionally, in another case^[10] of pernicious anemia and HHcy in a patient with a G2010A prothrombin gene mutation, no further episodes of thrombosis occurred after treatment with homocysteine-lowering therapy.

However, a secondary analysis of data from the HOPE-2 trial found that homocysteine-lowering therapy (folic acid, VitB₆, and B₁₂) did not significantly reduce the incidence rate of venous thromboembolism [hazard rate (HR): 1.01; confidence interval (CI): 0.66-1.53]^[18].

A similar randomized trial enrolling 701 patients showed that vitamin supplementation did not prevent recurrent venous thrombosis (HR: 0.84, 95%CI: 0.56-1.26)^[19]. We retrospectively reviewed the case of our patient, who had a high risk of drug relapse and a low likelihood of avoiding other risk factors, and we recommended supplementation with folic acid and vitamins to prevent recurrence of VTE.

CONCLUSION

N₂O was likely a direct or indirect factor in the pathogenesis of thrombosis in this case, and Hcy played an intermediate role. Furthermore, N₂O can cause fatal embolism in severe cases and during the acute stage. We strongly recommend stopping N₂O abuse and supplementation with folic acid and vitamins in patients at a high risk of recurrence, although the treatment protocols remain uncertain.

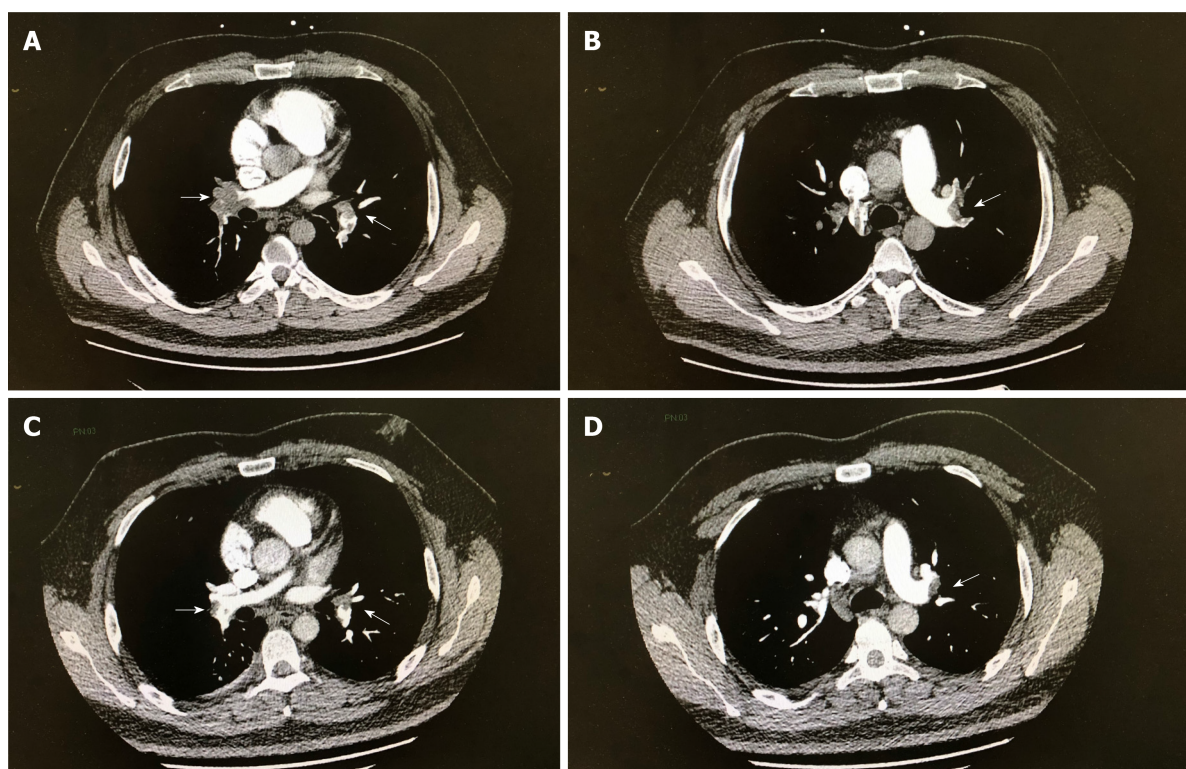


Figure 2 Computed tomographic pulmonary angiography images. A and B (before thrombolysis): The diameter of the left and right pulmonary artery trunks was increased, and there were multiple large filling defects; C and D (5 d after thrombolysis): The extent of filling defect was significantly obviously reduced.

REFERENCES

- Emmanouil DE, Quock RM. Advances in understanding the actions of nitrous oxide. *Anesth Prog* 2007; **54**: 9-18 [PMID: [17352529](#) DOI: [10.2344/0003-3006\(2007\)54\[9:AIUTAO\]2.0.CO;2](#)]
- Guyatt GH, Akl EA, Crowther M, Gutterman DD, Schünemann HJ; American College of Chest Physicians Antithrombotic Therapy and Prevention of Thrombosis Panel. Executive summary: Antithrombotic Therapy and Prevention of Thrombosis, 9th ed: American College of Chest Physicians Evidence-Based Clinical Practice Guidelines. *Chest* 2012; **141**: 7S-47S [PMID: [22315257](#) DOI: [10.1378/chest.1412S3](#)]
- Chanarin I. The effects of nitrous oxide on cobalamins, folates, and on related events. *Crit Rev Toxicol* 1982; **10**: 179-213 [PMID: [6127188](#) DOI: [10.3109/10408448209037455](#)]
- den Uil SH, Vermeulen EGJ, Metz R, Rijbroek A, de Vries M. Aortic arch thrombus caused by nitrous oxide abuse. *J Vasc Surg Cases Innov Tech* 2018; **4**: 80-82 [PMID: [29942888](#) DOI: [10.1016/j.jvscit.2018.01.001](#)]
- Munson ES. Effect of nitrous oxide on the pulmonary circulation during venous air embolism. *Anesth Analg* 1971; **50**: 785-793 [PMID: [5165428](#) DOI: [10.1213/00005539-197150050-00018](#)]
- Imberger G, Orr A, Thorlund K, Wetterslev J, Myles P, Möller AM. Does anaesthesia with nitrous oxide affect mortality or cardiovascular morbidity? A systematic review with meta-analysis and trial sequential analysis. *Br J Anaesth* 2014; **112**: 410-426 [PMID: [24408738](#) DOI: [10.1093/bja/aet416](#)]
- Myles PS, Leslie K, Chan MT, Forbes A, Peyton PJ, Paech MJ, Beattie WS, Sessler DI, Devereaux PJ, Silbert B, Schricker T, Wallace S; ANZCA Trials Group for the ENIGMA-II investigators. The safety of addition of nitrous oxide to general anaesthesia in at-risk patients having major non-cardiac surgery (ENIGMA-II): a randomised, single-blind trial. *Lancet* 2014; **384**: 1446-1454 [PMID: [25142708](#) DOI: [10.1016/S0140-6736\(14\)60893-X](#)]
- Cellai AP, Lami D, Antonucci E, Liotta AA, Rogolino A, Fedi S, Fiorillo C, Becatti M, Cenci C, Marcucci R, Abbate R, Prisco D. Hyperhomocysteinemia in patients with pulmonary embolism is associated with impaired plasma fibrinolytic capacity. *J Thromb Thrombolysis* 2014; **38**: 45-49 [PMID: [23963720](#) DOI: [10.1007/s11239-013-0981-1](#)]
- Gao L, Kolanuvada B, Naik G, Zhang Y, Zhao M, Sun L, Alaie D, Petrillo RL. Hyperhomocysteinemia-induced upper extremity deep vein thrombosis and pulmonary embolism in a patient with methyltetrahydrofolate reductase mutation: a case report and literature review. *Blood Coagul Fibrinolysis* 2016; **27**: 720-723 [PMID: [26650456](#) DOI: [10.1097/MBF.0000000000000458](#)]
- Caldera A, Mora J, Kotler M, Eiger G. Pulmonary embolism in a patient with pernicious anemia and hyperhomocysteinemia. *Chest* 2002; **122**: 1487-1488 [PMID: [12377886](#) DOI: [10.1378/chest.122.4.1487](#)]
- Ingrosso D, Cimmino A, Perna AF, Masella L, De Santo NG, De Bonis ML, Vacca M, D'Esposito M, D'Urso M, Galletti P, Zappia V. Folate treatment and unbalanced methylation and changes of allelic expression induced by hyperhomocysteinemia in patients with uraemia. *Lancet* 2003; **361**: 1693-1699 [PMID: [12767735](#) DOI: [10.1016/S0140-6736\(03\)13372-7](#)]
- Ridker PM, Hennekens CH, Selhub J, Miletich JP, Malinow MR, Stampfer MJ. Interrelation of hyperhomocyst(e)inemia, factor V Leiden, and risk of future venous thromboembolism. *Circulation* 1997; **95**: 1777-1782 [PMID: [9107163](#) DOI: [10.1161/01.cir.95.7.1777](#)]

- 13 **van Guldener C**, Stehouwer CD. Hyperhomocysteinaemia and vascular disease--a role for DNA hypomethylation? *Lancet* 2003; **361**: 1668-1669 [PMID: [12767729](#) DOI: [10.1016/S0140-6736\(03\)13380-6](#)]
- 14 **den Heijer M**, Koster T, Blom HJ, Bos GM, Briet E, Reitsma PH, Vandenbroucke JP, Rosendaal FR. Hyperhomocysteinemia as a risk factor for deep-vein thrombosis. *N Engl J Med* 1996; **334**: 759-762 [PMID: [8592549](#) DOI: [10.1056/NEJM199603213341203](#)]
- 15 **Eichinger S**, Stümpflen A, Hirschl M, Bialonczyk C, Herkner K, Stain M, Schneider B, Pabinger I, Lechner K, Kyrle PA. Hyperhomocysteinemia is a risk factor of recurrent venous thromboembolism. *Thromb Haemost* 1998; **80**: 566-569 [PMID: [9798970](#)]
- 16 **Taheri SA**, Shenoy SS, Mousa S. Circulating soluble tumor necrosis factor receptor as a marker for diagnosis of pulmonary embolus. *J Med* 2001; **32**: 163-168 [PMID: [11563814](#)]
- 17 Lowering blood homocysteine with folic acid based supplements: meta-analysis of randomised trials. Homocysteine Lowering Trialists' Collaboration. *BMJ* 1998; **316**: 894-898 [PMID: [9569395](#)]
- 18 **Ray JG**, Kearon C, Yi Q, Sheridan P, Lonn E; Heart Outcomes Prevention Evaluation 2 (HOPE-2) Investigators. Homocysteine-lowering therapy and risk for venous thromboembolism: a randomized trial. *Ann Intern Med* 2007; **146**: 761-767 [PMID: [17470822](#) DOI: [10.7326/0003-4819-146-11-200706050-00157](#)]
- 19 **den Heijer M**, Willems HP, Blom HJ, Gerrits WB, Cattaneo M, Eichinger S, Rosendaal FR, Bos GM. Homocysteine lowering by B vitamins and the secondary prevention of deep vein thrombosis and pulmonary embolism: A randomized, placebo-controlled, double-blind trial. *Blood* 2007; **109**: 139-144 [PMID: [16960155](#) DOI: [10.1182/blood-2006-04-014654](#)]



Published By Baishideng Publishing Group Inc
7041 Koll Center Parkway, Suite 160, Pleasanton, CA 94566, USA
Telephone: +1-925-2238242
E-mail: bpgoffice@wjgnet.com
Help Desk: <https://www.f6publishing.com/helpdesk>
<https://www.wjgnet.com>

