

# World Journal of *Clinical Cases*

*World J Clin Cases* 2019 December 6; 7(23): 3915-4171



**REVIEW**

- 3915** Overview of organic anion transporters and organic anion transporter polypeptides and their roles in the liver  
*Li TT, An JX, Xu JY, Tuo BG*

**ORIGINAL ARTICLE****Observational Study**

- 3934** Value of early diagnosis of sepsis complicated with acute kidney injury by renal contrast-enhanced ultrasound  
*Wang XY, Pang YP, Jiang T, Wang S, Li JT, Shi BM, Yu C*
- 3945** Value of elastography point quantification in improving the diagnostic accuracy of early diabetic kidney disease  
*Liu QY, Duan Q, Fu XH, Fu LQ, Xia HW, Wan YL*
- 3957** Resection of recurrent third branchial cleft fistulas assisted by flexible pharyngotomy  
*Ding XQ, Zhu X, Li L, Feng X, Huang ZC*
- 3964** Therapeutic efficacy of acupuncture combined with neuromuscular joint facilitation in treatment of hemiplegic shoulder pain  
*Wei YH, Du DC, Jiang K*
- 3971** Comparison of intra-articular injection of parecoxib *vs* oral administration of celecoxib for the clinical efficacy in the treatment of early knee osteoarthritis  
*Lu L, Xie Y, Gan K, Huang XW*

**Retrospective Study**

- 3980** Celiomesenteric trunk: New classification based on multidetector computed tomography angiographic findings and probable embryological mechanisms  
*Tang W, Shi J, Kuang LQ, Tang SY, Wang Y*

**Prospective Study**

- 3990** Interaction of arylsulfatases A and B with maspin: A possible explanation for dysregulation of tumor cell metabolism and invasive potential of colorectal cancer  
*Kovacs Z, Jung I, Szalman K, Baniás L, Bara TJ, Gurzu S*

**CASE REPORT**

- 4004** Recuperation of severe tumoral calcinosis in a dialysis patient: A case report  
*Westermann L, Isbell LK, Breitenfeldt MK, Arnold F, Röthele E, Schneider J, Widmeier E*

- 4011** Robotic wedge resection of a rare gastric perivascular epithelioid cell tumor: A case report  
*Marano A, Maione F, Woo Y, Pellegrino L, Geretto P, Sasia D, Fortunato M, Orcioni GF, Priotto R, Fasoli R, Borghi F*
- 4020** Primary parahiatal hernias: A case report and review of the literature  
*Preda SD, Pătrașcu Ș, Ungureanu BS, Cristian D, Bințișan V, Nica CM, Calu V, Strâmbu V, Sapalidis K, Șurlin VM*
- 4029** Diagnosis of Laron syndrome using monoplex-polymerase chain reaction technology with a whole-genome amplification template: A case report  
*Neumann A, Alcántara-Ortigoza MÁ, González-del Ángel A, Camargo-Diaz F, López-Bayghen E*
- 4036** *In-vitro* proliferation assay with recycled ascitic cancer cells in malignant pleural mesothelioma: A case report  
*Anayama T, Taguchi M, Tatenuma T, Okada H, Miyazaki R, Hirohashi K, Kume M, Matsusaki K, Orihashi K*
- 4044** Distant metastasis in choroidal melanoma with spontaneous corneal perforation and intratumoral calcification: A case report  
*Wang TW, Liu HW, Bee YS*
- 4052** Secondary Parkinson disease caused by breast cancer during pregnancy: A case report  
*Li L*
- 4057** Pulmonary embolism and deep vein thrombosis caused by nitrous oxide abuse: A case report  
*Sun W, Liao JP, Hu Y, Zhang W, Ma J, Wang GF*
- 4063** Micronodular thymic tumor with lymphoid stroma: A case report and review of the literature  
*Wang B, Li K, Song QK, Wang XH, Yang L, Zhang HL, Zhong DR*
- 4075** Diffuse large B cell lymphoma with bilateral adrenal and hypothalamic involvement: A case report and literature review  
*An P, Chen K, Yang GQ, Dou JT, Chen YL, Jin XY, Wang XL, Mu YM, Wang QS*
- 4084** Urethral pressure profilometry in artificial urinary sphincter implantation: A case report  
*Meng LF, Liu XD, Wang M, Zhang W, Zhang YG*
- 4091** Hydroxyurea-induced cutaneous squamous cell carcinoma: A case report  
*Xu Y, Liu J*
- 4098** Recurrent hypotension induced by sacubitril/valsartan in cardiomyopathy secondary to Duchenne muscular dystrophy: A case report  
*Li JM, Chen H*
- 4106** Complete duodenal obstruction induced by groove pancreatitis: A case report  
*Wang YL, Tong CH, Yu JH, Chen ZL, Fu H, Yang JH, Zhu X, Lu BC*

- 4111** Radiological aspects of giant hepatocellular adenoma of the left liver: A case report  
*Zheng LP, Hu CD, Wang J, Chen XJ, Shen YY*
- 4119** Mixed serous-neuroendocrine neoplasm of the pancreas: A case report and review of the literature  
*Xu YM, Li ZW, Wu HY, Fan XS, Sun Q*
- 4130** Rigid esophagoscopy combined with angle endoscopy for treatment of superior mediastinal foreign bodies penetrating into the esophagus caused by neck trauma: A case report  
*Wang D, Gao CB*
- 4137** Left armpit subcutaneous metastasis of gastric cancer: A case report  
*He FJ, Zhang P, Wang MJ, Chen Y, Zhuang W*
- 4144** Bouveret syndrome: A case report  
*Wang F, Du ZQ, Chen YL, Chen TM, Wang Y, Zhou XR*
- 4150** Fatal complications in a patient with severe multi-space infections in the oral and maxillofacial head and neck regions: A case report  
*Dai TG, Ran HB, Qiu YX, Xu B, Cheng JQ, Liu YK*
- 4157** Management of massive fistula bleeding after endoscopic ultrasound-guided pancreatic pseudocyst drainage using hemostatic forceps: A case report  
*Ge N, Sun SY*
- 4163** Pure squamous cell carcinoma of the gallbladder locally invading the liver and abdominal cavity: A case report and review of the literature  
*Jin S, Zhang L, Wei YF, Zhang HJ, Wang CY, Zou H, Hu JM, Jiang JF, Pang LJ*

**ABOUT COVER**

Editorial Board Member of *World Journal of Clinical Cases*, Consolato M Sergi, FRCP (C), MD, PhD, Professor, Department of Lab Medicine and Pathology, University of Alberta, Edmonton T6G 2B7, Canada

**AIMS AND SCOPE**

The primary aim of *World Journal of Clinical Cases* (WJCC, *World J Clin Cases*) is to provide scholars and readers from various fields of clinical medicine with a platform to publish high-quality clinical research articles and communicate their research findings online.

WJCC mainly publishes articles reporting research results and findings obtained in the field of clinical medicine and covering a wide range of topics, including case control studies, retrospective cohort studies, retrospective studies, clinical trials studies, observational studies, prospective studies, randomized controlled trials, randomized clinical trials, systematic reviews, meta-analysis, and case reports.

**INDEXING/ABSTRACTING**

The WJCC is now indexed in PubMed, PubMed Central, Science Citation Index Expanded (also known as SciSearch®), and Journal Citation Reports/Science Edition. The 2019 Edition of Journal Citation Reports cites the 2018 impact factor for WJCC as 1.153 (5-year impact factor: N/A), ranking WJCC as 99 among 160 journals in Medicine, General and Internal (quartile in category Q3).

**RESPONSIBLE EDITORS FOR THIS ISSUE**

Responsible Electronic Editor: *Yan-Xia Xing*

Proofing Production Department Director: *Xiang Li*

**NAME OF JOURNAL**

*World Journal of Clinical Cases*

**ISSN**

ISSN 2307-8960 (online)

**LAUNCH DATE**

April 16, 2013

**FREQUENCY**

Semimonthly

**EDITORS-IN-CHIEF**

Dennis A Bloomfield, Bao-Gan Peng, Sandro Vento

**EDITORIAL BOARD MEMBERS**

<https://www.wjnet.com/2307-8960/editorialboard.htm>

**EDITORIAL OFFICE**

Jin-Lei Wang, Director

**PUBLICATION DATE**

December 6, 2019

**COPYRIGHT**

© 2019 Baishideng Publishing Group Inc

**INSTRUCTIONS TO AUTHORS**

<https://www.wjnet.com/bpg/gerinfo/204>

**GUIDELINES FOR ETHICS DOCUMENTS**

<https://www.wjnet.com/bpg/GerInfo/287>

**GUIDELINES FOR NON-NATIVE SPEAKERS OF ENGLISH**

<https://www.wjnet.com/bpg/gerinfo/240>

**PUBLICATION MISCONDUCT**

<https://www.wjnet.com/bpg/gerinfo/208>

**ARTICLE PROCESSING CHARGE**

<https://www.wjnet.com/bpg/gerinfo/242>

**STEPS FOR SUBMITTING MANUSCRIPTS**

<https://www.wjnet.com/bpg/GerInfo/239>

**ONLINE SUBMISSION**

<https://www.f6publishing.com>

# Management of massive fistula bleeding after endoscopic ultrasound-guided pancreatic pseudocyst drainage using hemostatic forceps: A case report

Nan Ge, Si-Yu Sun

**ORCID number:** Nan Ge (0000-0002-5764-7054); Si-Yu Sun (0000-0002-7308-0473).

**Author contributions:** Ge N and Sun SY contributed to study planning and manuscript drafting.

**Informed consent statement:** Consent was obtained from the relatives of the patient.

**Conflict-of-interest statement:** All authors declare no conflict of interests for this article.

**CARE Checklist (2016) statement:** The guidelines of the CARE Checklist (2016) have been adopted.

**Open-Access:** This article is an open-access article that was selected by an in-house editor and fully peer-reviewed by external reviewers. It is distributed in accordance with the Creative Commons Attribution Non Commercial (CC BY-NC 4.0) license, which permits others to distribute, remix, adapt, build upon this work non-commercially, and license their derivative works on different terms, provided the original work is properly cited and the use is non-commercial. See: <http://creativecommons.org/licenses/by-nc/4.0/>

**Manuscript source:** Unsolicited manuscript

**Received:** September 5, 2019

**Peer-review started:** September 5, 2019

**First decision:** October 24, 2019

**Nan Ge, Si-Yu Sun,** Endoscopy Center, Shengjing Hospital of China Medical University, Shenyang 110004, Liaoning Province, China

**Corresponding author:** Si-Yu Sun, MD, PhD, Chief Doctor, Director, Professor, Endoscopy Center, Shengjing Hospital of China Medical University, No. 36, Sanhao Street, Shenyang 110004, Liaoning Province, China. [sunsy@sj-hospital.org](mailto:sunsy@sj-hospital.org)

**Telephone:** +86-18940258105

**Fax:** +86-24-23892617

## Abstract

### BACKGROUND

Endoscopic ultrasound (EUS)-guided drainage is the optimal method for treatment of pancreatic fluid collections (PFCs), and is associated with ease, safety, and efficiency. Bleeding is one of the main procedure-related complications, and often requires surgery or radiologic interventions. Indeed, endoscopic management of this complication is limited.

### CASE SUMMARY

A 42-year-old man presented for evaluation of abdominal pain and distention for approximately 2 wk. Abdominal computed tomography revealed a pancreatic pseudocyst located in the tail of the pancreas. EUS-guided pancreatic pseudocyst was performed. After stent placement, massive bleeding was noted from the fistula. Finally, hemostasis was successfully achieved using hemostatic forceps within the fistula.

### CONCLUSION

Bleeding vessel grasp and coagulation may represent a successful treatment for a fistula hemorrhage during EUS-guided drainage for a PFC, which may be tried before application of balloon or stent compression.

**Key words:** Pancreatic fluid collections; Endoscopic ultrasound; Drainage; Hemorrhage; Case report

©The Author(s) 2019. Published by Baishideng Publishing Group Inc. All rights reserved.

**Core tip:** We report the successful management of massive fistula bleeding during endoscopic ultrasound-guided pancreatic pseudocyst drainage using hemostatic forceps



**Revised:** November 1, 2019

**Accepted:** November 14, 2019

**Article in press:** November 14, 2019

**Published online:** December 6, 2019

**P-Reviewer:** Castro-Fernandez M,  
Lowenberg M

**S-Editor:** Wang JL

**L-Editor:** Wang TQ

**E-Editor:** Xing YX



within the fistula, which proved the efficiency of this method.

**Citation:** Ge N, Sun SY. Management of massive fistula bleeding after endoscopic ultrasound-guided pancreatic pseudocyst drainage using hemostatic forceps: A case report. *World J Clin Cases* 2019; 7(23): 4157-4162

**URL:** <https://www.wjgnet.com/2307-8960/full/v7/i23/4157.htm>

**DOI:** <https://dx.doi.org/10.12998/wjcc.v7.i23.4157>

## INTRODUCTION

Endoscopic ultrasound (EUS)-guided drainage is the optimal method for the treatment of pancreatic fluid collections (PFCs), and is associated with ease, safety, and efficiency<sup>[1-5]</sup>. Bleeding is one of the main procedure-related complications; the incidence is low but difficult to manage and often requires surgery or radiologic-guided embolization<sup>[6]</sup>. Herein we report the successful management of massive fistula bleeding during EUS-guided pancreatic pseudocyst drainage using hemostatic forceps.

## CASE PRESENTATION

### Chief complains

A 42-year-old man presented for evaluation of abdominal pain and distention for approximately 2 wk.

### History of past illness

The patient has a long-term history of alcohol consumption.

### Imaging examinations

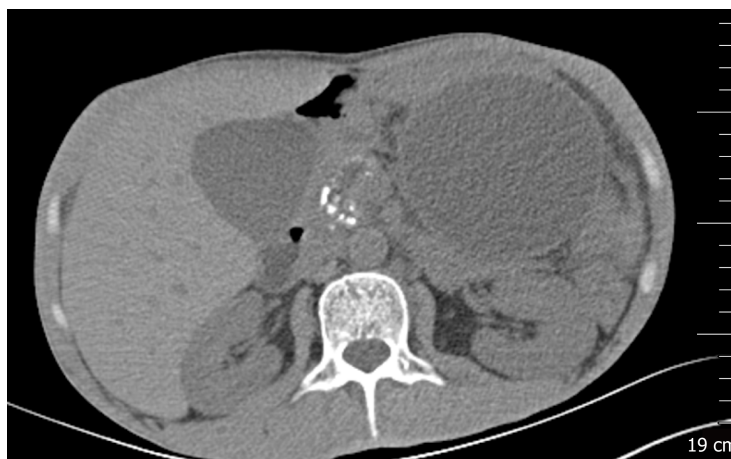
Abdominal computed tomography (CT) revealed atrophy of the pancreatic parenchyma and dilation of the main pancreatic duct with multiple stones. A pancreatic pseudocyst was located in the tail of the pancreas, measuring 9.8 cm × 8.0 cm. Varicose veins were also found around the fundus of the stomach (Figure 1).

## FINAL DIAGNOSIS

Pancreatic pseudocyst.

## TREATMENT

An EUS-guided cyst-gastrostomy was performed. A longitudinal echoendoscope (PENTAXEG3870UT; Pentax Corporation, Tokyo, Japan) with a 3.8-mm working channel accessible to a 10 Fr stent was used. Color Doppler was used to identify and avoid interposing vessels during puncture. An EchoTip Ultra endoscopic ultrasound needle (19-gauge; Boston Scientific Corp., United States) was introduced via the working channel of the echoendoscope, and the PFC was punctured under EUS guidance (Figure 2). A brown cystic fluid sample was aspirated and sent to determine the amylase level, as well as for other biochemical analyses. A guidewire (0.035 inch/480 mm; Boston Scientific, United States) was inserted into the cystic cavity. A cystotome (10 Fr; Wilson-Cook Medic, United States) was delivered to the dilated needle path and followed with a 10-mm balloon dilator. A 10-Fr plastic double-pigtail stent (Wilson-Cook Medic) was placed. After the stent placement, massive bleeding was noted from the fistula (Figure 3A). Under EUS, the site of bleeding was difficult to locate and blood began to fill the stomach cavity. We withdrew the EUS and introduced a gastrointestinal endoscope (3.2-mm working channel; Pentax Corporation) with a transparent cap attached. The bleeding vessel was viewed within the fistula (Figure 3B). Hemostatic forceps were introduced and the vessel was grasped until the bleeding stopped, then high-frequency electrocoagulation was performed. Hemostasis was successfully achieved (Figure 3C). A lumen-apposing



**Figure 1** Abdominal computed tomography image revealing atrophy of the pancreatic parenchyma and dilation of the main pancreatic duct with multiple stones. A pancreatic pseudocyst was located in the tail of the pancreas, measuring 9.8 cm × 8.0 cm.

metal stent (12 mm/25 mm, 16 mm/35 mm; Micro-Tech/Nan Jing Co., Ltd., China) was placed for the pancreatic pseudocyst drainage.

## OUTCOME AND FOLLOW-UP

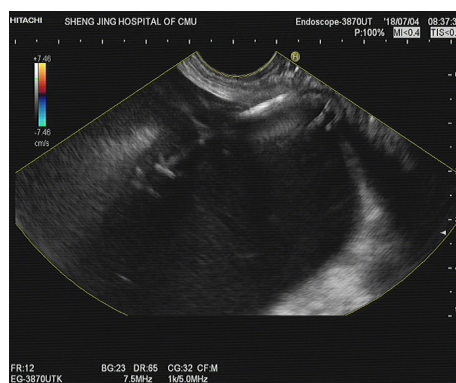
After the procedure, the patient remained hemodynamically stable, received standard care and antibiotics, and had no drop in hemoglobin during a 3-day hospital stay. A follow-up abdominal CT scan 1 month later showed almost complete resolution of the PFC (Figure 4), and the stent was removed (Figure 5).

## DISCUSSION

Ultrasound-guided drainage is the first-line modality for drainage of symptomatic PFCs. The overall clinical success rate is 90.5%-100%; the adverse effect rate is 98.0%-23.8%, mainly including hemorrhage, perforation, secondary infection, and stent migration<sup>[7-11]</sup>. Procedure-related bleeding reportedly occurs in 1%-2% of cases during EUS-guided drainage of PFCs. The use of EUS may help to reduce the risk of bleeding by visualizing intervened vessels. One prospective study reported a 13% bleeding rate with conventional endoscopic drainage, compared to no bleeding with EUS-guided interventions<sup>[12]</sup>; however, even with EUS guidance, bleeding remains an important adverse event<sup>[13]</sup>. Varadarajulu *et al*<sup>[7]</sup> also reported that bleeding occurred in a patient with underlying acquired factor VIII inhibitors. Also, straight biliary fully-covered self-expandable metal stent possibly increases the risk of delayed bleeding, in which case endoscopic intervention may be limited. Stent erosion of the gastric wall can occur during esophagogastroduodenoscopy. Collateral vessel bleeding can also occur during fistula creation and is often successfully managed conservatively. The bleeding caused by splenic artery pseudoaneurysms are often life-threatening<sup>[6]</sup>. In our case, the vessel injury during puncture, which was missed during EUS scanning, was the cause of bleeding.

As reported, there are three endoscopic interventions to manage bleeding during the procedure, as follows: (1) Fistula bleeding can be compressed by a balloon dilator, which is effective when the bleeding is not severe<sup>[14]</sup>; (2) A fully-covered self-expandable metal stent is delivered directly to continuously compress the fistula; and (3) Wang *et al*<sup>[14]</sup> reported using a bi-flanged self-expandable metal stent to stop bleeding in the needle path by external compression at the puncture site from stent expansion. In our case, the needle path was dilated using a 1-cm balloon, which permitted clear visualization of the needle path and identification of the bleeding vessel. If the needle path was not fully dilated, the bleeding vessel would not be detected and a fully covered metal stent may be considered. In our case, the bleeding vessel was ruptured and direct hemostasis was considered before balloon or stent compression.





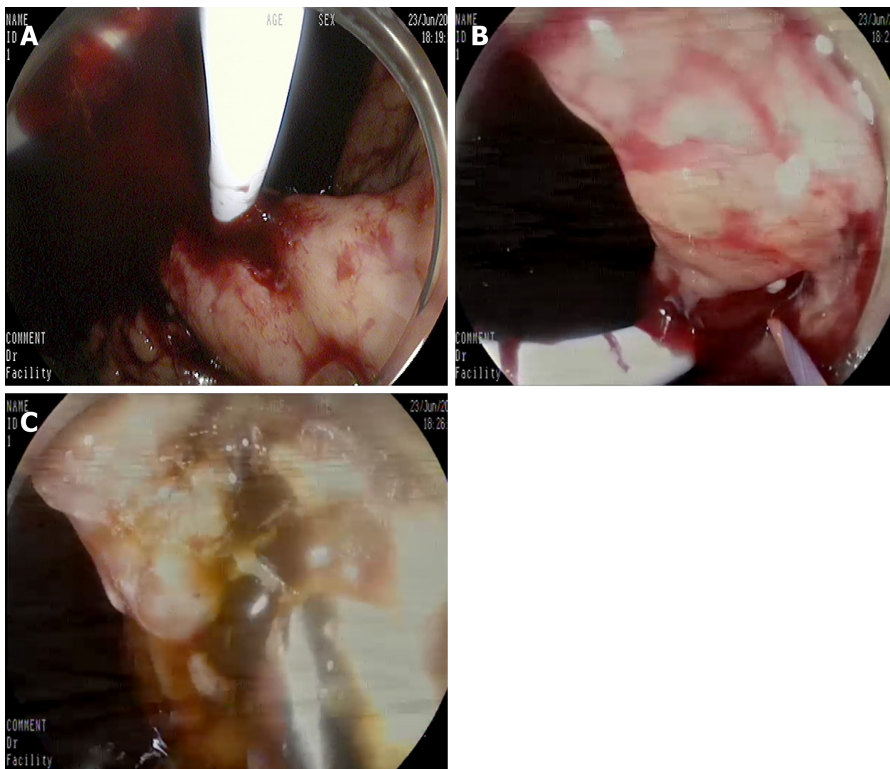
**Figure 2** The pancreatic fluid collection was punctured by fine-needle aspiration under endoscopic ultrasound guidance.

---

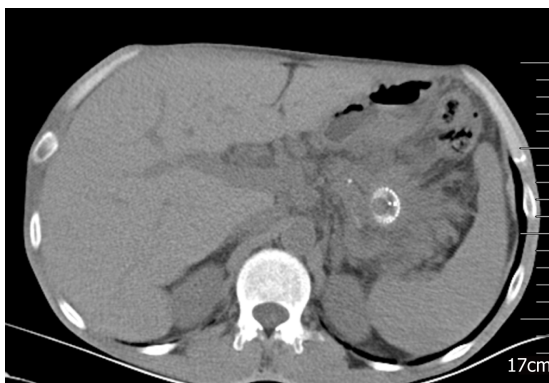## CONCLUSION

---

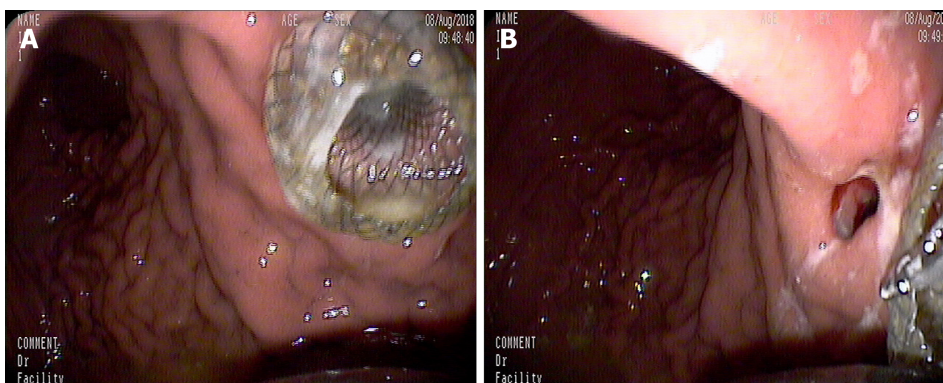
In conclusion, bleeding vessel grasp and coagulation may represent a successful treatment for a fistula hemorrhage during EUS-guided drainage for a PFC, which may be tried before application of balloon or stent compression.



**Figure 3** Endoscopic ultrasound images. A: After the stent placement, massive bleeding was noted from the fistula; B: The bleeding vessel was viewed within the fistula; C: Hemostasis was successfully achieved.



**Figure 4** A follow-up abdominal computed tomography scan 1 mo later showed almost complete resolution of the pancreatic fluid collection.



**Figure 5** The placed metal stent (A) and the stent was removed (B).

## REFERENCES

- 1 **Adler DG.** Single-operator experience with a 20-mm diameter lumen apposing metal stent to treat patients with large pancreatic fluid collections from pancreatic necrosis. *Endosc Ultrasound* 2018; **7**: 422-423 [PMID: [30531025](#) DOI: [10.4103/eus.eus\\_39\\_18](#)]
- 2 **Adler DG, Shah J, Nieto J, Binmoeller K, Bhat Y, Taylor LJ, Siddiqui AA.** Placement of lumen-apposing metal stents to drain pseudocysts and walled-off pancreatic necrosis can be safely performed on an outpatient basis: A multicenter study. *Endosc Ultrasound* 2019; **8**: 36-42 [PMID: [29770780](#) DOI: [10.4103/eus/eus\\_30-17](#)]
- 3 **Caillol F, Godat S, Turrini O, Zemmour C, Bories E, Pesenti C, Ratone JP, Ewald J, Delpero JR, Giovannini M.** Fluid collection after partial pancreatectomy: EUS drainage and long-term follow-up. *Endosc Ultrasound* 2019; **8**: 91-98 [PMID: [29600794](#) DOI: [10.4103/eus.eus\\_112\\_17](#)]
- 4 **Li L, Cristofaro S, Qu C, Liang S, Li X, Cai Q.** EUS-guided drainage of pancreatic fluid collection with a Hot AXIOS stent in a patient with pancreatitis following distal pancreatectomy (with video). *Endosc Ultrasound* 2018; **7**: 347-348 [PMID: [29848832](#) DOI: [10.4103/eus.eus\\_55\\_17](#)]
- 5 **Bang JY, Varadarajulu S.** Stent Tracker app: Novel method to track patients with indwelling lumen-apposing metal stents. *Endosc Ultrasound* 2018; **7**: 69-70 [PMID: [29451174](#) DOI: [10.4103/eus.eus\\_50\\_17](#)]
- 6 **Lang GD, Fritz C, Bhat T, Das KK, Murad FM, Early DS, Edmundowicz SA, Kushnir VM, Mullady DK.** EUS-guided drainage of peripancreatic fluid collections with lumen-apposing metal stents and plastic double-pigtail stents: comparison of efficacy and adverse event rates. *Gastrointest Endosc* 2018; **87**: 150-157 [PMID: [28713067](#) DOI: [10.1016/j.gie.2017.06.029](#)]
- 7 **Varadarajulu S, Christein JD, Wilcox CM.** Frequency of complications during EUS-guided drainage of pancreatic fluid collections in 148 consecutive patients. *J Gastroenterol Hepatol* 2011; **26**: 1504-1508 [PMID: [21575060](#) DOI: [10.1111/j.1440-1746.2011.06771.x](#)]
- 8 **Saul A, Ramirez Luna MA, Chan C, Uscanga L, Valdovinos Andraca F, Hernandez Calleros J, Elizondo J, Tellez Avila F.** EUS-guided drainage of pancreatic pseudocysts offers similar success and complications compared to surgical treatment but with a lower cost. *Surg Endosc* 2016; **30**: 1459-1465 [PMID: [26139498](#) DOI: [10.1007/s00464-015-4351-2](#)]
- 9 **Siddiqui AA, Adler DG, Nieto J, Shah JN, Binmoeller KF, Kane S, Yan L, Laique SN, Kowalski T, Loren DE, Taylor LJ, Munigala S, Bhat YM.** EUS-guided drainage of peripancreatic fluid collections and necrosis by using a novel lumen-apposing stent: a large retrospective, multicenter U.S. experience (with videos). *Gastrointest Endosc* 2016; **83**: 699-707 [PMID: [26515956](#) DOI: [10.1016/j.gie.2015.10.020](#)]
- 10 **Chen Y, Zhu H, Jin Z, Li Z, Du Y.** An unusual complication of cardia occlusion with lumen-apposing metal stent therapy for pancreatic pseudocyst. *Endosc Ultrasound* 2018; **7**: 61-63 [PMID: [29451171](#) DOI: [10.4103/eus.eus\\_99\\_17](#)]
- 11 **Rana SS, Gupta R, Kang M, Sharma V, Sharma R, Gorski U, Bhasin DK.** Percutaneous catheter drainage followed by endoscopic transluminal drainage/necrosectomy for treatment of infected pancreatic necrosis in early phase of illness. *Endosc Ultrasound* 2018; **7**: 41-47 [PMID: [29451168](#) DOI: [10.4103/eus.eus\\_94\\_17](#)]
- 12 **Varadarajulu S, Christein JD, Tamhane A, Drelichman ER, Wilcox CM.** Prospective randomized trial comparing EUS and EGD for transmural drainage of pancreatic pseudocysts (with videos). *Gastrointest Endosc* 2008; **68**: 1102-1111 [PMID: [18640677](#) DOI: [10.1016/j.gie.2008.04.028](#)]
- 13 **Siddiqui AA, Kowalski TE, Loren DE, Khalid A, Soomro A, Mazhar SM, Isby L, Kahaleh M, Karia K, Yoo J, Ofosu A, Ng B, Sharaiha RZ.** Fully covered self-expanding metal stents versus lumen-apposing fully covered self-expanding metal stent versus plastic stents for endoscopic drainage of pancreatic walled-off necrosis: clinical outcomes and success. *Gastrointest Endosc* 2017; **85**: 758-765 [PMID: [27566053](#) DOI: [10.1016/j.gie.2016.08.014](#)]
- 14 **Wang BH, Xie LT, Zhao QY, Ying HJ, Jiang TA.** Balloon dilator controls massive bleeding during endoscopic ultrasound-guided drainage for pancreatic pseudocyst: A case report and review of literature. *World J Clin Cases* 2018; **6**: 459-465 [PMID: [30294611](#) DOI: [10.12998/wjcc.v6.i11.459](#)]



Published By Baishideng Publishing Group Inc  
7041 Koll Center Parkway, Suite 160, Pleasanton, CA 94566, USA  
Telephone: +1-925-2238242  
E-mail: [bpgoffice@wjgnet.com](mailto:bpgoffice@wjgnet.com)  
Help Desk: <https://www.f6publishing.com/helpdesk>  
<https://www.wjgnet.com>

