

World Journal of *Clinical Cases*

World J Clin Cases 2019 December 26; 7(24): 4172-4425



**REVIEW**

- 4172** Polyunsaturated fatty acids and DNA methylation in colorectal cancer
Moradi Sarabi M, Mohammadrezaei Khorramabadi R, Zare Z, Eftekhari E

ORIGINAL ARTICLE**Retrospective Study**

- 4186** Impact of resection margins on long-term survival after pancreaticoduodenectomy for pancreatic head carcinoma
Li CG, Zhou ZP, Tan XL, Gao YX, Wang ZZ, Liu Q, Zhao ZM
- 4196** Arthroscopy combined with unicompartmental knee arthroplasty for treatment of isolated unicompartmental knee arthritis: A long-term comparison
Wang HR, Li ZL, Li J, Wang YX, Zhao ZD, Li W
- 4208** Intact, pie-crusting and repairing the posterior cruciate ligament in posterior cruciate ligament-retaining total knee arthroplasty: A 5-year follow-up
Ma DS, Wen L, Wang ZW, Zhang B, Ren SX, Lin Y
- 4218** Community-acquired pneumonia complicated by rhabdomyolysis: A clinical analysis of 11 cases
Zhao B, Zheng R

Clinical Trials Study

- 4226** Dissection and ligation of the lateral circumflex femoral artery is not necessary when using the direct anterior approach for total hip arthroplasty
Zhao GY, Wang YJ, Xu NW, Liu F

Observational Study

- 4234** Expression of interleukin-32 in bone marrow of patients with myeloma and its prognostic significance
Wang G, Ning FY, Wang JH, Yan HM, Kong HW, Zhang YT, Shen Q

Randomized Controlled Trial

- 4245** Effect of different types of laryngeal mask airway placement on the right internal jugular vein: A prospective randomized controlled trial
Zhang JJ, Qu ZY, Hua Z, Zuo MZ, Zhang HY

SYSTEMATIC REVIEW

- 4254** Chronic pain, posttraumatic stress disorder, and opioid intake: A systematic review
López-Martínez AE, Reyes-Pérez Á, Serrano-Ibáñez ER, Esteve R, Ramírez-Maestre C

CASE REPORT

- 4270 Acute appendicitis in a patient after a uterus transplant: A case report
Kristek J, Kudla M, Chlupac J, Novotny R, Mirejovsky T, Janousek L, Fronek J
- 4277 Pneumococcal infection transmission between family members with congenital asplenia: A case report
Shibata J, Hiramatsu K, Kenzaka T, Kato T
- 4285 Successful treatment of warfarin-induced skin necrosis using oral rivaroxaban: A case report
Kamada M, Kenzaka T
- 4292 Simultaneous *Paragonimus* infection involving the breast and lung: A case report
Oh MY, Chu A, Park JH, Lee JY, Roh EY, Chai YJ, Hwang KT
- 4299 Isolated peritoneal lymphomatosis defined as post-transplant lymphoproliferative disorder after a liver transplant: A case report
Kim HB, Hong R, Na YS, Choi WY, Park SG, Lee HJ
- 4307 Three-dimensional image simulation of primary diaphragmatic hemangioma: A case report
Chu PY, Lin KH, Kao HL, Peng YJ, Huang TW
- 4314 Natural orifice specimen extraction with laparoscopic radical gastrectomy for distal gastric cancer: A case report
Sun P, Wang XS, Liu Q, Luan YS, Tian YT
- 4321 Huge brown tumor of the rib in an unlocatable hyperparathyroidism patient with “self-recovered” serum calcium and parathyroid hormone: A case report
Wang WD, Zhang N, Qu Q, He XD
- 4327 Percutaneous management of atrium and lung perforation: A case report
Zhou X, Ze F, Li D, Li XB
- 4334 Epstein-Barr virus-positive post-transplant lymphoproliferative disorder presenting as hematochezia and enterobrosis in renal transplant recipients in China: A report of two cases
Sun ZJ, Hu XP, Fan BH, Wang W
- 4342 Postoperative multidrug-resistant *Acinetobacter baumannii* meningitis successfully treated with intravenous doxycycline and intraventricular gentamicin: A case report
Wu X, Wang L, Ye YZ, Yu H
- 4349 Reconstruction of massive skin avulsion of the scrota and penis by combined application of dermal regeneration template (Pelnac) and split-thickness skin graft with vacuum-assisted closure: A case report
Fang JJ, Li PF, Wu JJ, Zhou HY, Xie LP, Lu H

- 4355** Multisystem smooth muscle dysfunction syndrome in a Chinese girl: A case report and review of the literature
Chen SN, Wang YQ, Hao CL, Lu YH, Jiang WJ, Gao CY, Wu M
- 4366** Kidney inflammatory myofibroblastic tumor masquerading as metastatic malignancy: A case report and literature review
Zhang GH, Guo XY, Liang GZ, Wang Q
- 4377** Hydroxychloroquine-induced renal phospholipidosis resembling Fabry disease in undifferentiated connective tissue disease: A case report
Wu SZ, Liang X, Geng J, Zhang MB, Xie N, Su XY
- 4384** Spontaneous ovarian hyperstimulation syndrome: Report of two cases
Gui J, Zhang J, Xu WM, Ming L
- 4391** Castleman disease in the hepatic-gastric space: A case report
Xu XY, Liu XQ, Du HW, Liu JH
- 4398** KIT and platelet-derived growth factor receptor α wild-type gastrointestinal stromal tumor associated with neurofibromatosis type 1: Two case reports
Kou YW, Zhang Y, Fu YP, Wang Z
- 4414** Isolated elevated aspartate aminotransferase in an asymptomatic woman due to macro-aspartate aminotransferase: A case report
Zhan MR, Liu X, Zhang MY, Niu JQ
- 4420** Rehabilitation of anterior pituitary dysfunction combined with extrapontine myelinolysis: A case report
Yang MX, Chen XN

ABOUT COVER

Editorial Board Member of *World Journal of Clinical Cases*, Ashu Seith Bhalla, MD, Professor, Department of Radiodiagnosis, All India Institute of Medical Sciences, New Delhi 110029, India

AIMS AND SCOPE

The primary aim of *World Journal of Clinical Cases* (WJCC, *World J Clin Cases*) is to provide scholars and readers from various fields of clinical medicine with a platform to publish high-quality clinical research articles and communicate their research findings online.

WJCC mainly publishes articles reporting research results and findings obtained in the field of clinical medicine and covering a wide range of topics, including case control studies, retrospective cohort studies, retrospective studies, clinical trials studies, observational studies, prospective studies, randomized controlled trials, randomized clinical trials, systematic reviews, meta-analysis, and case reports.

INDEXING/ABSTRACTING

The WJCC is now indexed in PubMed, PubMed Central, Science Citation Index Expanded (also known as SciSearch®), and Journal Citation Reports/Science Edition. The 2019 Edition of Journal Citation Reports cites the 2018 impact factor for WJCC as 1.153 (5-year impact factor: N/A), ranking WJCC as 99 among 160 journals in Medicine, General and Internal (quartile in category Q3).

RESPONSIBLE EDITORS FOR THIS ISSUE

Responsible Electronic Editor: Ji-Hong Liu

Proofing Production Department Director: Yun-Xiaojuan Wu

NAME OF JOURNAL

World Journal of Clinical Cases

ISSN

ISSN 2307-8960 (online)

LAUNCH DATE

April 16, 2013

FREQUENCY

Semimonthly

EDITORS-IN-CHIEF

Dennis A Bloomfield, Bao-Gan Peng, Sandro Vento

EDITORIAL BOARD MEMBERS

<https://www.wjnet.com/2307-8960/editorialboard.htm>

EDITORIAL OFFICE

Jin-Lei Wang, Director

PUBLICATION DATE

December 26, 2019

COPYRIGHT

© 2019 Baishideng Publishing Group Inc

INSTRUCTIONS TO AUTHORS

<https://www.wjnet.com/bpg/gerinfo/204>

GUIDELINES FOR ETHICS DOCUMENTS

<https://www.wjnet.com/bpg/GerInfo/287>

GUIDELINES FOR NON-NATIVE SPEAKERS OF ENGLISH

<https://www.wjnet.com/bpg/gerinfo/240>

PUBLICATION MISCONDUCT

<https://www.wjnet.com/bpg/gerinfo/208>

ARTICLE PROCESSING CHARGE

<https://www.wjnet.com/bpg/gerinfo/242>

STEPS FOR SUBMITTING MANUSCRIPTS

<https://www.wjnet.com/bpg/GerInfo/239>

ONLINE SUBMISSION

<https://www.f6publishing.com>

Retrospective Study

Intact, pie-crusting and repairing the posterior cruciate ligament in posterior cruciate ligament-retaining total knee arthroplasty: A 5-year follow-up

De-Si Ma, Liang Wen, Zhi-Wei Wang, Bo Zhang, Shi-Xiang Ren, Yuan Lin

ORCID number: De-Si Ma (0000-0001-5711-236X); Liang Wen (0000-0002-3500-7451); Zhi-Wei Wang (0000-0002-5668-075X); Bo Zhang (0000-0003-3506-4314); Shi-Xiang Ren (0000-0002-7709-2244); Yuan Lin (0000-0003-2366-7732).

Author contributions: Ma DS analyzed the data and wrote the first draft of the manuscript; Wen L designed the research and provided guidance for the study; Wang ZW, Ren SX and Zhang B contributed to the acquisition of data and interpretation of data. Yuan Lin performed the surgeries.

Institutional review board

statement: The study was reviewed and approved by the Ethics Committee of Beijing Chaoyang Hospital, Capital Medical University (No. 12-70).

Informed consent statement: All study participants provided informed written consent prior to study enrollment.

Conflict-of-interest statement: The authors declare no conflict of interest.

Data sharing statement: Technical appendix, statistical code, and dataset available from the corresponding author. No additional data are available.

Open-Access: This article is an open-access article which was selected by an in-house editor and fully peer-reviewed by external reviewers. It is distributed in

De-Si Ma, Liang Wen, Zhi-Wei Wang, Bo Zhang, Shi-Xiang Ren, Yuan Lin, Department of Orthopedics, Beijing Chaoyang Hospital, Capital Medical University, Beijing 100020, China

Corresponding author: Liang Wen, MD, PhD, Associate Chief Physician, Doctor, Department of Orthopedics, Beijing Chaoyang Hospital, Capital Medical University, No 8 Gongren Tiyyuchang Nanlu, Chaoyang District, Beijing 100020, China. wenliang@ccmu.edu.cn
Telephone: +86-10-85231228

Abstract

BACKGROUND

The posterior cruciate ligament (PCL) is important for cruciate-retaining (CR) total knee arthroplasty (TKA). Whether the entire PCL should be retained during CR-TKA is controversial.

AIM

To evaluate the clinical outcomes of PCL preservation in CR-TKA and the methods used to deal with the PCL during surgery.

METHODS

A retrospective review of patients with osteoarthritis undergoing primary CR-TKA (176 patients, 205 knees) in our institution between March 2012 and March 2014 was performed. A PCL protector was used to preserve the intact PCL bone block. The status of the PCL was recorded during surgery. Intact PCL preserved, pie-crusting and repairing were used to balance the tension of the PCL. Range of motion (ROM) and the Knee Society Clinical Rating system (KSS) were evaluated preoperatively and at the endpoint of follow-up.

RESULTS

The mean ROM of the knee was $103.2 \pm 17.2^\circ$, KSS clinical score was 47.6 ± 9.5 and KSS functional score was 46.3 ± 11.9 before surgery. The mean ROM of the knee was $117.5 \pm 9.7^\circ$, KSS clinical score was 89.2 ± 3.6 and KSS functional score was 84.6 ± 9.8 at 5 years follow-up. ROM, KSS clinical scores and KSS functional scores were significantly improved after surgery ($P < 0.01$). Thirty-two (23.7%) TKAs involved PCL pie-crusting and 18 (13.3%) involved PCL repair. Eighty-five (63.0%) TKAs applied standard operating procedures and preserved intact PCL. At 5 years follow-up, in the intact PCL group, the mean ROM of the knee was $118.0 \pm 8.3^\circ$, KSS clinical score was 89.1 ± 3.7 and KSS functional score was 84.9 ± 9.6 . In the PCL pie-crusting group, mean ROM of the knee was $114.0 \pm 13.5^\circ$, KSS

accordance with the Creative Commons Attribution Non Commercial (CC BY-NC 4.0) license, which permits others to distribute, remix, adapt, build upon this work non-commercially, and license their derivative works on different terms, provided the original work is properly cited and the use is non-commercial. See: <http://creativecommons.org/licenses/by-nc/4.0/>

Manuscript source: Unsolicited manuscript

Received: September 29, 2019

Peer-review started: September 29, 2019

First decision: November 21, 2019

Revised: November 25, 2019

Accepted: November 30, 2019

Article in press: November 30, 2019

Published online: December 26, 2019

P-Reviewer: Tinsley A

S-Editor: Wang JL

L-Editor: Webster JR

E-Editor: Liu MY



clinical score was 88.8 ± 3.4 and KSS functional score was 83.8 ± 10.5 . In the PCL repair group, mean ROM of the knee was $120.3 \pm 7.0^\circ$, KSS clinical score was 89.0 ± 3.6 and KSS functional score was 89.4 ± 4.5 . There were no significant differences in ROM, KSS clinical scores and KSS functional scores among the three groups ($P > 0.05$).

CONCLUSION

The clinical outcomes of preserving the PCL in CR-TKA are encouraging. Pie-crusting and PCL repair do not affect the function. The PCL protector effectively protected the PCL bone block.

Key words: Knee; Total knee arthroplasty; Posterior cruciate ligament; Knee function; Range of motion

©The Author(s) 2019. Published by Baishideng Publishing Group Inc. All rights reserved.

Core tip: The number of cruciate-retaining total knee arthroplasty (CR-TKA) is increasing. Whether the entire posterior cruciate ligament (PCL) should be retained during CR-TKA is controversial. The PCL protector can effectively protect the PCL bone block. Application of the PCL protector is described in this study, and the methods used to balance the tension of the PCL (pie-crusting and repairing) are reported. The strategy for a tight PCL in CR-TKA is summarized. The clinical outcomes are evaluated by range of motion and Knee Society Clinical Rating system scores.

Citation: Ma DS, Wen L, Wang ZW, Zhang B, Ren SX, Lin Y. Intact, pie-crusting and repairing the posterior cruciate ligament in posterior cruciate ligament-retaining total knee arthroplasty: A 5-year follow-up. *World J Clin Cases* 2019; 7(24): 4208-4217

URL: <https://www.wjgnet.com/2307-8960/full/v7/i24/4208.htm>

DOI: <https://dx.doi.org/10.12998/wjcc.v7.i24.4208>

INTRODUCTION

Total knee arthroplasty (TKA) is successful in providing pain relief and normal knee function for patients with osteoarthritis. One of the most persistent issues in TKA is the role of retention or substitution of the posterior cruciate ligament (PCL). Numerous studies have reported on the kinematics, clinical efficacy and lifespan of cruciate-retaining (CR) and posterior-substitution (PS) TKA. The advantages and disadvantages of CR-TKA and PS-TKA are controversial^[1-7]. Due to the design of PS prostheses, wearing between the cam and post is inevitable during long-term survival. The cam-post mechanism may not fully restore the functional capacity of the intact PCL. As mentioned previously, a large number of surgeons would like to adopt CR-TKA as the first choice, especially in Europe^[4,8-13].

To reconstruct the mechanical axis of the knee through bone resection, soft tissue balance is the goal of TKA. The PCL is the main restraint against posterior translation of the tibia. The tension and intactness of the PCL are important factors for the success of CR-TKA. It has been demonstrated that CR-TKA increases knee range of motion (ROM) and preserves optimal knee stability during flexion and extension, especially during climbing stairs. The advocates of CR-TKA consider that retaining the PCL could maintain femoral rollback during flexion of the knee. Therefore, CR-TKA could achieve better flexion and muscle strength of the lower limbs^[3,8,14-16]. The PCL is composed of anterolateral and posteromedial bundles. The anterolateral bundle is the main functional part of the PCL and plays an important role in the stability of knee flexion^[9,14]. The anterolateral bundle of the PCL should not be sacrificed in CR-TKA, although it would be easier to balance the flexion gap by releasing or excising the anterolateral bundle^[15,17,18].

The purposes of the present study were: (1) To evaluate the clinical outcomes of intact PCL-retaining TKA in osteoarthritis; (2) To record the status of the PCL during CR-TKA; and (3) To discuss the technique for preserving the intact PCL and restoring its function.

MATERIALS AND METHODS

Patients

This retrospective review involved 176 patients (205 knees) with end-stage degenerative osteoarthritis undergoing primary TKA in Beijing Chaoyang Hospital, Capital Medical University between March 2012 and March 2014. Patients who met the following criteria, were included in the study: (1) A CR-prosthesis (Gemini Mark II, LINK, Germany) was implanted with a cementing technique; (2) At least 60 years old; (3) PCL status during surgery was recorded; and (4) Body mass index < 30 kg/m². Patients were excluded for any of the following reasons: (1) History of fractures around the knee or femoral and tibial shaft; (2) History of surgery around the knee; (3) Patients with valgus deformities of the knee; or (4) Patients with deficiency of PCL function.

Surgical technique

Patients were placed in the supine position under either general or spinal-epidural combined anesthesia and an air tourniquet was applied in all cases. The standard TKA procedure with conventional instrumentation was performed in this study. An anterior midline skin incision was made from the suprapatellar area extending to the medial side of the tibial tubercle, and a medial parapatellar approach was used.

A PCL protector was applied before the tibial cut (Figure 1 and Figure 2). Intraoperative photograph showing preserved bone block at the tibial attachment of the PCL (Figure 3A). The resected tibial plateau showed the shape of the intact PCL bone block at the tibial attachment (Figure 3B and C). Radiography after TKA showed the intact PCL bone block at the tibial attachment (Figure 4). Extramedullary instrumentation was used to achieve a target tibial cut of 90° relative to the mechanical axis in the coronal plane and of 5° relative to the posterior slope in the sagittal plane. The medial third of the tibial tubercle was the rotation landmark. A measured resection technique was used to balance the extension and flexion gap. A distal femoral cut was performed with an intramedullary instrumentation setting at 6° of the anatomic valgus. Referring to the externally rotated 3° of the posterior condyles, a femoral external rotation cut was performed. After appropriate soft-tissue release, trials of the tibial and femoral side were installed to test stability, equality of extension and flexion gap, ROM, patellar tracking, and alignment of the lower limbs. Next, the prosthesis was fixed with cement. No patellar resurfacing was performed in any of our cases. After appropriate soft-tissue release, especially at the medial side, the PCL was assessed at 90° of flexion with the trial implants. Excessive femoral rollback and anterior lift off of the tibial trial implant indicated that the knee was tight in flexion. Palpation and drawer test were used to test the tension of the PCL. If the PCL tension was too high and there were no other causes of a small flexion gap, pie-crusting was applied to obtain appropriate PCL tension. Sometimes high tension of the PCL led to detachment of the PCL bone block from the tibia, then a repairing procedure was performed (Figure 5). Figure 6 shows the strategy for a tight PCL in CR-TKA.

After TKA surgery, the patients walked with crutches or a walker as early as possible. Functional exercise and physical therapy were initiated on the first day after surgery. Patients require at least 1-wk rehabilitative exercise in hospital. Lower limb strengthening exercise and active and passive flexion-extension exercise of the knee was maintained at least 3 mo after surgery.

Clinical outcome evaluations

The patients were reviewed at 5 years follow-up by an independent surgeon. Clinical outcomes were evaluated using ROM and Knee Society Clinical Rating System scores (KSS). The KSS includes clinical and functional scores for the knee.

Statistical analysis

The measurement data, including age, ROM, KSS clinical scores and KSS functional scores were represented by the mean ± SD. The preoperative and postoperative values were statistically analyzed using independent *t* tests. The Kruskal-Wallis test was used to analyze the values among the groups. SPSS version 19.0 was used for statistical analysis. The level of significance was set at $P \leq 0.05$.

RESULTS

General information

During follow-up, three patients required secondary wound debridement due to poor wound healing. A second operation was needed for two patients due to a



Figure 1 Posterior cruciate ligament protectors applied during surgery.

periprosthetic fracture caused by falling down. Non-periprosthetic lower limb fractures occurred in three patients. Two patients developed paralysis due to nervous system dysfunction. Six patients died from non-surgical causes. Sixteen patients exited from the follow-up. Moreover, 51 patients were lost to follow-up due to a change of contact information. Of 176 patients, 109 (135 knees), 88 women and 21 men, completed the 5 years follow-up. The follow-up rate was 61.9%. The mean age of the 109 patients was 73.2 ± 4.1 years (range, 67–83 years).

Clinical outcomes

The results are shown in [Table 1](#). ROM, KSS clinical scores and KSS functional scores were significantly improved at 5 years follow-up, as compared to the preoperative values ($t = 7.57$, $P < 0.01$; $t = 42.71$, $P < 0.01$; and $t = 25.85$, $P < 0.01$, respectively). Of the 135 knees, there were no iatrogenic injuries to the PCL during the tibial cut with the PCL protector. Thirty-two TKAs (23.7%) involved PCL pie-crusting due to the tightness at 90° of flexion. Eighteen TKAs (13.3%) included PCL repair due to detachment of the PCL bone block from the tibia. Eighty-five operations (63.0%) applied standard operating procedures and preserved an intact PCL. There were no significant differences in ROM, KSS clinical scores and KSS functional scores among the three groups ([Table 2](#)).

DISCUSSION

The present study demonstrated that CR-TKA could achieve good outcomes in patients with end-stage knee osteoarthritis. The ROM, KSS clinical scores and functional scores significantly improved after surgery. The PCL pie-crusting and PCL repair groups showed the same clinical outcomes compared to the intact PCL group. This indicated that correct treatment of the PCL could achieve the same results as the intact PCL in CR-TKA. In addition to accurate bone resection, soft-tissue release is important for lower limb alignment, balance of extension and flexion gap, ROM, knee kinematics, and clinical efficacy^[11,19-22]. A large flexion gap rarely occurs in CR-TKA. If the flexion and extension gap is imbalanced, the flexion gap is smaller than the extension gap in most cases. At the same time, a small flexion gap is important to treat during the operation. Excessive femoral rollback and anterior lift off of the tibial trial implant is effective for indicating that the knee is tight in flexion^[9]. Numerous reasons could lead to a smaller flexion gap than extension gap in varus TKA, such as insufficient release of the anterior bundle of the medial collateral ligament, tightness of PCL, increasing the posterior condyles offset after femoral resection, and an insufficient posterior slope of the tibia. Release of the PCL should be the last step to obtain a satisfactory flexion gap. Excluding other reasons, if palpation and drawer test confirm tightness of the PCL, pie-crusting with a syringe needle can be applied to release the PCL. The anterolateral bundle of the PCL can bear more tension than the posteromedial bundle of the PCL. Therefore, pie-crusting should be applied at the anterolateral bundle of the PCL, close to the femoral insertion. The pie-crusting should be performed after the trial implants are set in order to obtain the appropriate PCL tension. After trial implants have been installed, during the assessment of stability, equality of extension and flexion gap, ROM, patellar tracking, and alignment of the lower limbs, high tension of the PCL can lead to detachment of the PCL bone block from the tibia. To restore PCL function, the tendon suture is used to surround the proximal side of the PCL bone block and anatomical reduction is not necessary.

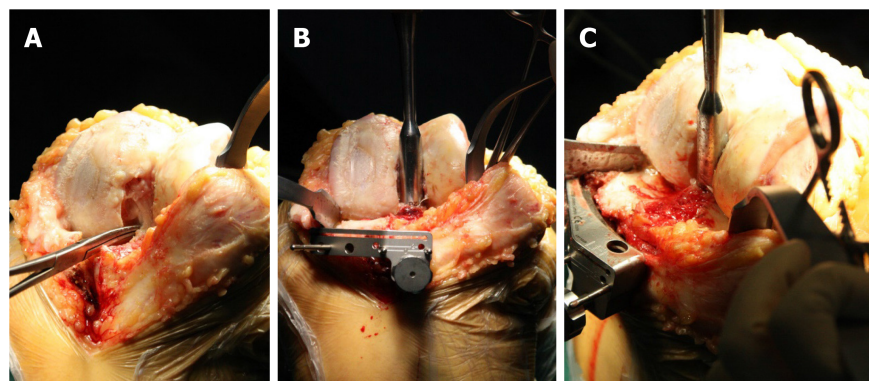


Figure 2 Insertion of the posterior cruciate ligament protector. A: Exposure of the posterior cruciate ligament (PCL); B: The protector was inserted around the PCL; C: Enough depth was necessary to protect the intact bone block of the PCL.

After cement is placed on the tibial plateau, the suture is placed under the tibial prosthesis. PCL tension can be adjusted by the tendon suture at 90° of flexion. Maintaining the appropriate tension of the tendon suture until the cement solidifies, ensures that the tendon suture is fixed between the tibial prosthesis and cement. This method allows easy tightening of the loosened PCL. Moreover, it is an effective way of restoring PCL function after CR-TKA, as described in the present study.

Intact or partially preserved PCL in CR-TKA is debatable. Dion *et al*^[23] reported that of 677 CR-TKAs, 540 retained intact PCL, 24 had partially recessed PCL at the femoral side, and 113 completely excised the PCL. There were no significant differences in clinical outcomes among the three groups. No cases converted CR implant to PS-TKA. In the PCL-excision group, one TKA failed due to instability. Dion *et al*^[23] considered that a tight PCL may cause excessive femoral rollback, restrictions in flexion, and increase contact stresses, leading to polyethylene wear and even posteromedial subluxation. Therefore, partial release and excision of the PCL should be applied to achieve adequate knee balancing. Other studies have made similar claims; that released and excised PCL does not require revision of the CR component to a PS component^[15,24-26]. However, our institution reported that the double-bundle PCL played an important role in maintaining knee stability^[3]. The mean maximum anteroposterior displacement of the knee at 90° of flexion was significantly greater in the partially released group than in the intact group in CR-TKA cases. KSS function scores were significantly higher in the intact group than in the partially released group 2 years after surgery. It would be easier to balance the flexion gap in CR-TKA after the PCL is released or excised. However, when a small flexion gap occurs, the reason should be established, as mentioned above. Excision of the PCL was the no-alternative way to finish CR-TKA. The anterolateral bundle is tense in flexion, limits the space for knee flexion, and induces posterior femoral translation. The anterolateral and posteromedial bundles of the PCL should be preserved intact in CR-TKA, especially the anterolateral bundle. Firstly, the anterolateral bundle is the major part of the PCL. It maintains tension at knee flexion and rollback of the femoral component. Yue *et al*^[27] reported that a deficiency in the function of the PCL in CR-TKA may compromise the function in controlling knee rotation, and is overstretched during late flexion. Poor function of the PCL does not maintain femoral rollback, and it accelerates wear of the polyethylene bearing and affects the degree of flexion. This leads to early failure if a non-elevated anterior lip of the bearing is used. Secondly, the anterolateral bundle of the PCL endures the major strength during knee flexion. Steinbrück *et al*^[28] reported that the anterolateral bundle of the PCL endured 200 N force and the posteromedial bundle only 50 N during knee movement. If the anterolateral bundle of the PCL was released > 75%, the force endured by the PCL decreased to around 70 N. Van Opstal *et al*^[18] reported mechanical measurements of TKA from fresh-frozen cadavers. The results showed that retaining the bone block in front of the anterolateral bundle of the PCL could endure greater tensile strength and reduce the risk of secondary surgical failure due to flexion instability of the primary TKA. Therefore, Van Opstal *et al*^[18] recommended leaving the posterior tibial cortex anterior to the PCL insertion intact when performing CR-TKA, which was the same as in our study. Excision of the anterolateral bundle of the PCL significantly impaired PCL function, especially at knee flexion. Lastly, mechanoreceptors are distributed in the PCL. The healthy PCL can provide more mechanoreceptor function. Zhang *et al*^[29] reported that mechanoreceptors appear to occupy similar areas before and after

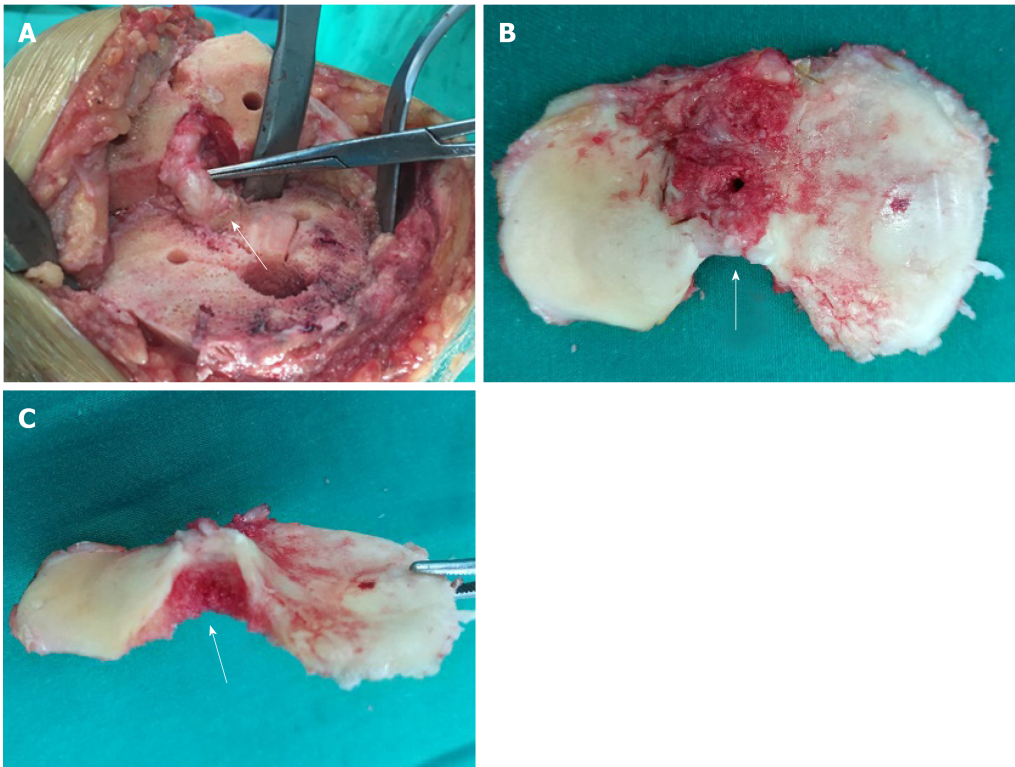


Figure 3 Intraoperative photographs. A: Preserved bone block at the tibial attachment of the posterior cruciate ligament (arrow); B, C: The resected tibial plateau showing the shape of the intact posterior cruciate ligament bone block at the tibial attachment (arrows).

implantation of a CR-TKA. This indicates that if mechanoreceptors continue to work after CR-TKA, then they may continue to participate in proprioception of the knee after CR-TKA. These results may explain why patients who undergo CR-TKA can climb stairs better than patients who undergo PS-TKA.

The intact PCL can be preserved using a PCL protector, which is easy to perform during surgery. Cinotti *et al*^[30] reported that, in order to spare the whole PCL insertion when CR implants are used, the maximum thickness of the tibial cut should be 4 mm when a 0° sagittal slope is used, and even less when a 3° or 5° posterior sagittal slope is used. Matziolis *et al*^[31] expressed a similar opinion. Obviously, 4-mm thickness is not enough to accommodate the tibial tray without changing the joint line. A mean surface area of 68.8% was removed after the tibial cut without protections, and would have seriously affected PCL function^[16]. Therefore, the protector is necessary to preserve the PCL attachment on the tibia during tibial resection. Non-iatrogenic injuries of the PCL occurred during the tibial cut in our study, which demonstrated the effectiveness of the PCL protector. It should be noted that the PCL protector should be at an appropriate depth in the tibia to obstruct the saw blade during the tibial cut. According to our experience, the depth should be 15–20 mm.

There were several limitations to this study. Firstly, it was a retrospective, non-randomized, single-center study, with all the limitations of such a study design. Secondly, the balance of flexion and extension gap was not measured by quantitative index, which could have been more objective. Lastly, a longer follow-up should be carried out to evaluate the clinical outcomes and survival rates.

In conclusion, this study presents evidence for preserving the PCL in CR-TKA to obtain good clinical outcomes. The PCL protector can effectively protect the PCL bone block and does not increase the difficulty of TKA. PCL pie-crusting and PCL repair have no impact on the clinical outcomes in CR-TKA.

Table 1 Range of motion and the Knee Society Clinical Rating system scores of the included patients

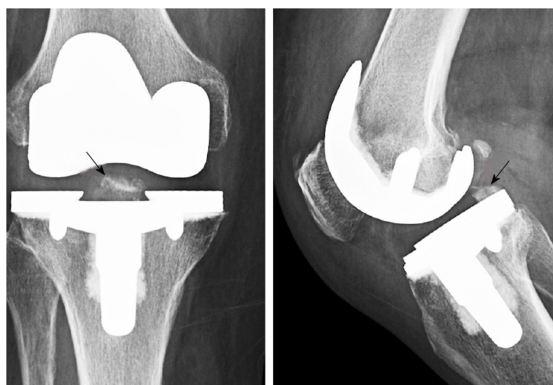	ROM (°)	KSS clinical scores	KSS functional scores
Before surgery	103.2 ± 17.2	47.6 ± 9.5	46.3 ± 11.9
Follow-up	117.5 ± 9.7	89.2 ± 3.6	84.6 ± 9.8
<i>P</i> value	0.00	0.00	0.00

The data are presented as mean ± SD. ROM: Range of motion; KSS: The Knee Society Clinical Rating system.

Table 2 Clinical outcomes according to the posterior cruciate ligament treatment group

	ROM (°)	KSS clinical scores	KSS functional scores
Intact PCL	118.0 ± 8.3	89.1 ± 3.7	84.9 ± 9.6
Pie-crusting	114.0 ± 13.5	88.8 ± 3.4	83.8 ± 10.5
Repairing	120.3 ± 7.0	89.0 ± 3.6	89.4 ± 4.5
<i>P</i> value	> 0.05	> 0.05	> 0.05

The data are presented as mean ± SD. PCL: Posterior cruciate ligament; ROM: Range of motion; KSS: The Knee Society Clinical Rating system.

**Figure 4** Radiograph after total knee arthroplasty showing the intact posterior cruciate ligament bone block at the tibial attachment (arrows).

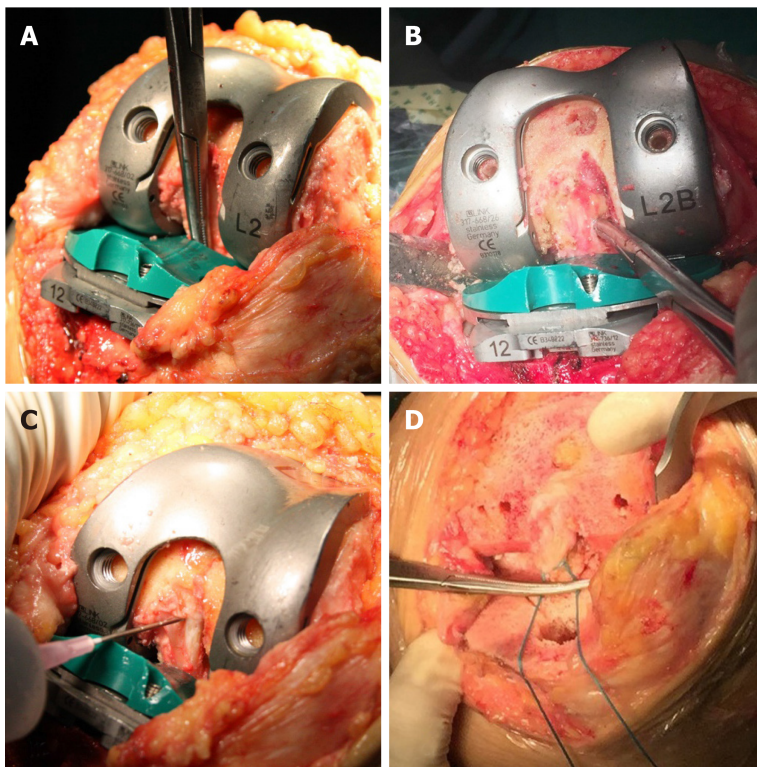


Figure 5 Intraoperative photographs showing the assessment of the posterior cruciate ligament. A: To check that the posterior cruciate ligament (PCL) was not entrapped by the trial implant; B: To check the tension of the PCL at 90° of flexion with the trial implant; C: Releasing the PCL with the pie-crusting technique to obtain an appropriate tension of the PCL, especially the anterolateral bundle at the femoral side; D: A tendon suture was used to repair the detachment of the PCL bone block from the tibia. The suture could be tightened to adjust the tension of the PCL. The suture was fixed under the tibial component by cement.

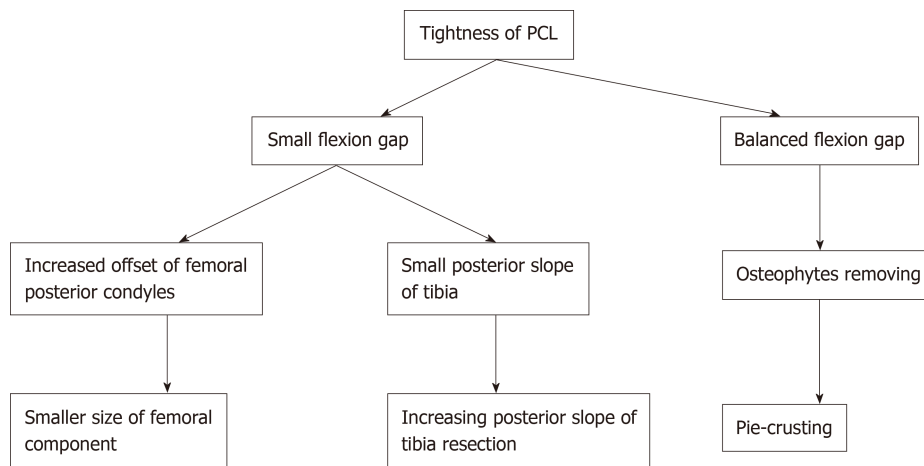


Figure 6 Strategy for a tight posterior cruciate ligament in cruciate-retaining total knee arthroplasty. PCL: Posterior cruciate ligament.

ARTICLE HIGHLIGHTS

Research background

One of the most persistent issues discussed in total knee arthroplasty (TKA) is the role of retention or substitution of the posterior cruciate ligament (PCL). Whether the entire PCL should be retained during cruciate-retaining (CR)-TKA is controversial. Maintaining the function of the PCL is the goal of CR-TKA.

Research motivation

The PCL is composed of anterolateral and posteromedial bundles. The anterolateral bundle is the main functional part of the PCL and plays an important role in the stability of knee flexion. The anterolateral bundle of the PCL should not be sacrificed in CR-TKA, although it would be easier to balance the flexion gap by releasing or excising the anterolateral bundle.

Research objectives

The aim of the study was to evaluate the clinical outcomes of PCL preservation in CR-TKA and the methods used to deal with the PCL during surgery.

Research methods

A total of 176 patients (205 knees) were involved in this study. A PCL protector was used to preserve the intact PCL bone block during the CR-TKA. The status of the PCL was recorded during surgery. Intact PCL preserved, pie-crusting and repairing were used to balance the tension of the PCL according to the strategy used for a tight PCL in CR-TKA. Range of motion (ROM) and the Knee Society Clinical Rating system (KSS) scores were evaluated as the clinical outcomes.

Research results

The intact PCL could be preserved in most CR-TKAs (63.0%). 23.7% of CR-TKAs required pie-crusting and 13.3% required PCL repair to balance the tension of the PCL. The ROM and KSS scores were significantly improved after surgery in all cases and there were no differences in the three groups.

Research conclusions

The PCL protector can effectively protect the PCL bone block and does not increase the difficulty of TKA. PCL pie-crusting and PCL repair have no impact on the clinical outcomes in CR-TKA and can be included during surgery to balance the tension of the PCL.

Research perspectives

Preservation of the intact PCL can be achieved by the PCL protector and the surgical technique used. Sometimes it can be difficult to balance the tension of the intact PCL. In future research, more attention should be paid to investigating the relationship between the intact PCL and balance of the PCL during CR-TKA.

REFERENCES

- 1 **Wünschel M**, Leasure JM, Dalheimer P, Kraft N, Wülker N, Müller O. Differences in knee joint kinematics and forces after posterior cruciate retaining and stabilized total knee arthroplasty. *Knee* 2013; **20**: 416-421 [PMID: 23578828 DOI: 10.1016/j.knee.2013.03.005]
- 2 **Ji SJ**, Zhou YX, Jiang X, Cheng ZY, Wang GZ, Ding H, Yang ML, Zhu ZL. Effect of Joint Line Elevation after Posterior-stabilized and Cruciate-retaining Total Knee Arthroplasty on Clinical Function and Kinematics. *Chin Med J (Engl)* 2015; **128**: 2866-2872 [PMID: 26521783 DOI: 10.4103/0366-6999.168043]
- 3 **Zhang B**, Cheng CK, Qu TB, Hai Y, Lin Y, Pan J, Wang ZW, Wen L. Partial versus Intact Posterior Cruciate Ligament-retaining Total Knee Arthroplasty: A Comparative Study of Early Clinical Outcomes. *Orthop Surg* 2016; **8**: 331-337 [PMID: 27627716 DOI: 10.1111/os.12269]
- 4 **Abdel MP**, Morrey ME, Jensen MR, Morrey BF. Increased long-term survival of posterior cruciate-retaining versus posterior cruciate-stabilizing total knee replacements. *J Bone Joint Surg Am* 2011; **93**: 2072-2078 [PMID: 22262378 DOI: 10.2106/JBJS.J.01143]
- 5 **Song SJ**, Park CH, Bae DK. What to Know for Selecting Cruciate-Retaining or Posterior-Stabilized Total Knee Arthroplasty. *Clin Orthop Surg* 2019; **11**: 142-150 [PMID: 31156764 DOI: 10.4055/cios.2019.11.2.142]
- 6 **Kang KT**, Koh YG, Son J, Kwon OR, Lee JS, Kwon SK. Comparison of Kinematics in Cruciate Retaining and Posterior Stabilized for Fixed and Rotating Platform Mobile-Bearing Total Knee Arthroplasty with respect to Different Posterior Tibial Slope. *Biomed Res Int* 2018; **2018**: 5139074 [PMID: 29992149 DOI: 10.1155/2018/5139074]
- 7 **Longo UG**, Ciuffreda M, Mannering N, D'Andrea V, Locher J, Salvatore G, Denaro V. Outcomes of Posterior-Stabilized Compared with Cruciate-Retaining Total Knee Arthroplasty. *J Knee Surg* 2018; **31**: 321-340 [PMID: 28666292 DOI: 10.1055/s-0037-1603902]
- 8 **Conditt MA**, Noble PC, Bertolusso R, Woody J, Parsley BS. The PCL significantly affects the functional outcome of total knee arthroplasty. *J Arthroplasty* 2004; **19**: 107-112 [PMID: 15457428 DOI: 10.1016/j.arth.2004.06.006]
- 9 **Foge DA**, Baldini TH, Hellwinkel JE, Hogan CA, Dayton MR. The Role of Complete Posterior Cruciate Ligament Release in Flexion Gap Balancing for Total Knee Arthroplasty. *J Arthroplasty* 2019; **34**: S361-S365 [PMID: 30948290 DOI: 10.1016/j.arth.2019.03.017]
- 10 **Girgis FG**, Marshall JL, Monajem A. The cruciate ligaments of the knee joint. Anatomical, functional and experimental analysis. *Clin Orthop Relat Res* 1975; **216**: 231 [PMID: 1126079 DOI: 10.1097/00003086-197501000-00033]
- 11 **Watanabe M**, Kuriyama S, Nakamura S, Nishitani K, Tanaka Y, Sekiguchi K, Ito H, Matsuda S. Impact of intraoperative adjustment method for increased flexion gap on knee kinematics after posterior cruciate ligament-sacrificing total knee arthroplasty. *Clin Biomech (Bristol, Avon)* 2019; **63**: 85-94 [PMID: 30851566 DOI: 10.1016/j.clinbiomech.2019.02.018]
- 12 **Price AJ**, Alvand A, Troelsen A, Katz JN, Hooper G, Gray A, Carr A, Beard D. Knee replacement. *Lancet* 2018; **392**: 1672-1682 [PMID: 30496082 DOI: 10.1016/S0140-6736(18)32344-4]
- 13 **Jiang C**, Liu Z, Wang Y, Bian Y, Feng B, Weng X. Posterior Cruciate Ligament Retention versus Posterior Stabilization for Total Knee Arthroplasty: A Meta-Analysis. *PLoS One* 2016; **11**: e0147865 [PMID: 26824368 DOI: 10.1371/journal.pone.0147865]
- 14 **Matthews J**, Chong A, McQueen D, O'Guinn J, Wooley P. Flexion-extension gap in cruciate-retaining versus posterior-stabilized total knee arthroplasty: a cadaveric study. *J Orthop Res* 2014; **32**: 627-632 [PMID: 24474152 DOI: 10.1002/jor.22587]
- 15 **Kim E**, Talmo CT, Anderson MC, Bono OJ, Bono JV. Incidence and Risk Factors for Posterior Cruciate

- Ligament Avulsion during Cruciate Retaining Total Knee Arthroplasty. *J Knee Surg* 2019; **32**: 1138-1142 [PMID: 30544272 DOI: 10.1055/s-0038-1676068]
- 16 **Feyen H**, Van Opstal N, Bellemans J. Partial resection of the PCL insertion site during tibial preparation in cruciate-retaining TKA. *Knee Surg Sports Traumatol Arthrosc* 2013; **21**: 2674-2679 [PMID: 22527413 DOI: 10.1007/s00167-012-1997-3]
 - 17 **Lombardi AV**, Berend KR, Aziz-Jacobo J, Davis MB. Balancing the flexion gap: relationship between tibial slope and posterior cruciate ligament release and correlation with range of motion. *J Bone Joint Surg Am* 2008; **90** Suppl 4: 121-132 [PMID: 18984725 DOI: 10.2106/JBJS.H.00685]
 - 18 **Van Opstal N**, Feyen H, Luyckx JP, Bellemans J. Mean tensile strength of the PCL in TKA depends on the preservation of the tibial insertion site. *Knee Surg Sports Traumatol Arthrosc* 2016; **24**: 273-278 [PMID: 25308158 DOI: 10.1007/s00167-014-3377-7]
 - 19 **Mannan A**, Vun J, Lodge C, Eyre-Brook A, Jones S. Increased precision of coronal plane outcomes in robotic-assisted total knee arthroplasty: A systematic review and meta-analysis. *Surgeon* 2018; **16**: 237-244 [PMID: 29439922 DOI: 10.1016/j.surge.2017.12.003]
 - 20 **Mine T**, Hoshi K, Gamada K, Ihara K, Kawamura H, Kuriyama R, Date R. Kinematic analysis of posterior-stabilized total knee arthroplasty during standing up from and sitting down on a chair. *J Orthop Surg Res* 2016; **11**: 142 [PMID: 27855716 DOI: 10.1186/s13018-016-0482-y]
 - 21 **Salzmänn M**, Fennema P, Becker R, Hommel H. Does Postoperative Mechanical Axis Alignment Have an Effect on Clinical Outcome of Primary Total Knee Arthroplasty? A Retrospective Cohort Study. *Open Orthop J* 2017; **11**: 1330-1336 [PMID: 29290871 DOI: 10.2174/1874325001711011330]
 - 22 **Ha CW**, Park YB, Lee CH, Awe SI, Park YG. Selective Medial Release Technique Using the Pie-Crusting Method for Medial Tightness During Primary Total Knee Arthroplasty. *J Arthroplasty* 2016; **31**: 1005-1010 [PMID: 26753607 DOI: 10.1016/j.arth.2015.11.019]
 - 23 **Dion CB**, Howard JL, Lanting BA, McAuley JP. Does Recession of the Posterior Cruciate Ligament Influence Outcome in Total Knee Arthroplasty? *J Arthroplasty* 2019; **34**: 2383-2387 [PMID: 31326243 DOI: 10.1016/j.arth.2019.05.052]
 - 24 **Straw R**, Kulkarni S, Attfield S, Wilton TJ. Posterior cruciate ligament at total knee replacement. Essential, beneficial or a hindrance? *J Bone Joint Surg Br* 2003; **85**: 671-674 [PMID: 12892188]
 - 25 **Ritter MA**, Davis KE, Meding JB, Farris A. The role of the posterior cruciate ligament in total knee replacement. *Bone Joint Res* 2012; **1**: 64-70 [PMID: 23610673 DOI: 10.1302/2046-3758.14.2000024]
 - 26 **Meneghini RM**, Stefl MD, Hodge WA, Banks SA. A Cam-Post Mechanism Is No Longer Necessary in Modern Primary Total Knee Arthroplasty. *J Knee Surg* 2019; **32**: 710-713 [PMID: 30822791 DOI: 10.1055/s-0039-1681030]
 - 27 **Yue B**, Varadarajan KM, Rubash HE, Li G. In vivo function of posterior cruciate ligament before and after posterior cruciate ligament-retaining total knee arthroplasty. *Int Orthop* 2012; **36**: 1387-1392 [PMID: 22270863 DOI: 10.1007/s00264-011-1481-6]
 - 28 **Steinbrück A**, Woiczinski M, Weber P, Müller PE, Jansson V, Schröder C. Posterior cruciate ligament balancing in total knee arthroplasty: a numerical study with a dynamic force controlled knee model. *Biomed Eng Online* 2014; **13**: 91 [PMID: 24990257 DOI: 10.1186/1475-925X-13-91]
 - 29 **Zhang K**, Mihalko WM. Posterior cruciate mechanoreceptors in osteoarthritic and cruciate-retaining TKA retrievals: a pilot study. *Clin Orthop Relat Res* 2012; **470**: 1855-1859 [PMID: 21993951 DOI: 10.1007/s11999-011-2120-7]
 - 30 **Cinotti G**, Sessa P, Amato M, Ripani FR, Giannicola G. Preserving the PCL during the tibial cut in total knee arthroplasty. *Knee Surg Sports Traumatol Arthrosc* 2017; **25**: 2594-2601 [PMID: 26537596 DOI: 10.1007/s00167-015-3842-y]
 - 31 **Matziolis G**, Mehlhorn S, Schattat N, Diederichs G, Hube R, Perka C, Matziolis D. How much of the PCL is really preserved during the tibial cut? *Knee Surg Sports Traumatol Arthrosc* 2012; **20**: 1083-1086 [PMID: 21987364 DOI: 10.1007/s00167-011-1696-5]



Published By Baishideng Publishing Group Inc
7041 Koll Center Parkway, Suite 160, Pleasanton, CA 94566, USA
Telephone: +1-925-2238242
E-mail: bpgoffice@wjgnet.com
Help Desk: <https://www.f6publishing.com/helpdesk>
<https://www.wjgnet.com>

