

# World Journal of *Clinical Cases*

*World J Clin Cases* 2019 December 26; 7(24): 4172-4425



**REVIEW**

- 4172** Polyunsaturated fatty acids and DNA methylation in colorectal cancer  
*Moradi Sarabi M, Mohammadrezaei Khorramabadi R, Zare Z, Eftekhari E*

**ORIGINAL ARTICLE****Retrospective Study**

- 4186** Impact of resection margins on long-term survival after pancreaticoduodenectomy for pancreatic head carcinoma  
*Li CG, Zhou ZP, Tan XL, Gao YX, Wang ZZ, Liu Q, Zhao ZM*
- 4196** Arthroscopy combined with unicompartmental knee arthroplasty for treatment of isolated unicompartmental knee arthritis: A long-term comparison  
*Wang HR, Li ZL, Li J, Wang YX, Zhao ZD, Li W*
- 4208** Intact, pie-crusting and repairing the posterior cruciate ligament in posterior cruciate ligament-retaining total knee arthroplasty: A 5-year follow-up  
*Ma DS, Wen L, Wang ZW, Zhang B, Ren SX, Lin Y*
- 4218** Community-acquired pneumonia complicated by rhabdomyolysis: A clinical analysis of 11 cases  
*Zhao B, Zheng R*

**Clinical Trials Study**

- 4226** Dissection and ligation of the lateral circumflex femoral artery is not necessary when using the direct anterior approach for total hip arthroplasty  
*Zhao GY, Wang YJ, Xu NW, Liu F*

**Observational Study**

- 4234** Expression of interleukin-32 in bone marrow of patients with myeloma and its prognostic significance  
*Wang G, Ning FY, Wang JH, Yan HM, Kong HW, Zhang YT, Shen Q*

**Randomized Controlled Trial**

- 4245** Effect of different types of laryngeal mask airway placement on the right internal jugular vein: A prospective randomized controlled trial  
*Zhang JJ, Qu ZY, Hua Z, Zuo MZ, Zhang HY*

**SYSTEMATIC REVIEW**

- 4254** Chronic pain, posttraumatic stress disorder, and opioid intake: A systematic review  
*López-Martínez AE, Reyes-Pérez Á, Serrano-Ibáñez ER, Esteve R, Ramírez-Maestre C*

## CASE REPORT

- 4270 Acute appendicitis in a patient after a uterus transplant: A case report  
*Kristek J, Kudla M, Chlupac J, Novotny R, Mirejovsky T, Janousek L, Fronek J*
- 4277 Pneumococcal infection transmission between family members with congenital asplenia: A case report  
*Shibata J, Hiramatsu K, Kenzaka T, Kato T*
- 4285 Successful treatment of warfarin-induced skin necrosis using oral rivaroxaban: A case report  
*Kamada M, Kenzaka T*
- 4292 Simultaneous *Paragonimus* infection involving the breast and lung: A case report  
*Oh MY, Chu A, Park JH, Lee JY, Roh EY, Chai YJ, Hwang KT*
- 4299 Isolated peritoneal lymphomatosis defined as post-transplant lymphoproliferative disorder after a liver transplant: A case report  
*Kim HB, Hong R, Na YS, Choi WY, Park SG, Lee HJ*
- 4307 Three-dimensional image simulation of primary diaphragmatic hemangioma: A case report  
*Chu PY, Lin KH, Kao HL, Peng YJ, Huang TW*
- 4314 Natural orifice specimen extraction with laparoscopic radical gastrectomy for distal gastric cancer: A case report  
*Sun P, Wang XS, Liu Q, Luan YS, Tian YT*
- 4321 Huge brown tumor of the rib in an unlocatable hyperparathyroidism patient with “self-recovered” serum calcium and parathyroid hormone: A case report  
*Wang WD, Zhang N, Qu Q, He XD*
- 4327 Percutaneous management of atrium and lung perforation: A case report  
*Zhou X, Ze F, Li D, Li XB*
- 4334 Epstein-Barr virus-positive post-transplant lymphoproliferative disorder presenting as hematochezia and enterobrosis in renal transplant recipients in China: A report of two cases  
*Sun ZJ, Hu XP, Fan BH, Wang W*
- 4342 Postoperative multidrug-resistant *Acinetobacter baumannii* meningitis successfully treated with intravenous doxycycline and intraventricular gentamicin: A case report  
*Wu X, Wang L, Ye YZ, Yu H*
- 4349 Reconstruction of massive skin avulsion of the scrota and penis by combined application of dermal regeneration template (Pelnac) and split-thickness skin graft with vacuum-assisted closure: A case report  
*Fang JJ, Li PF, Wu JJ, Zhou HY, Xie LP, Lu H*

- 4355** Multisystem smooth muscle dysfunction syndrome in a Chinese girl: A case report and review of the literature  
*Chen SN, Wang YQ, Hao CL, Lu YH, Jiang WJ, Gao CY, Wu M*
- 4366** Kidney inflammatory myofibroblastic tumor masquerading as metastatic malignancy: A case report and literature review  
*Zhang GH, Guo XY, Liang GZ, Wang Q*
- 4377** Hydroxychloroquine-induced renal phospholipidosis resembling Fabry disease in undifferentiated connective tissue disease: A case report  
*Wu SZ, Liang X, Geng J, Zhang MB, Xie N, Su XY*
- 4384** Spontaneous ovarian hyperstimulation syndrome: Report of two cases  
*Gui J, Zhang J, Xu WM, Ming L*
- 4391** Castleman disease in the hepatic-gastric space: A case report  
*Xu XY, Liu XQ, Du HW, Liu JH*
- 4398** KIT and platelet-derived growth factor receptor  $\alpha$  wild-type gastrointestinal stromal tumor associated with neurofibromatosis type 1: Two case reports  
*Kou YW, Zhang Y, Fu YP, Wang Z*
- 4407** Treatment of severe upper gastrointestinal bleeding caused by Mallory-Weiss syndrome after primary coronary intervention for acute inferior wall myocardial infarction: A case report  
*Du BB, Wang XT, Li XD, Li PP, Chen WW, Li SM, Yang P*
- 4414** Isolated elevated aspartate aminotransferase in an asymptomatic woman due to macro-aspartate aminotransferase: A case report  
*Zhan MR, Liu X, Zhang MY, Niu JQ*
- 4420** Rehabilitation of anterior pituitary dysfunction combined with extrapontine myelinolysis: A case report  
*Yang MX, Chen XN*

**ABOUT COVER**

Editorial Board Member of *World Journal of Clinical Cases*, Ashu Seith Bhalla, MD, Professor, Department of Radiodiagnosis, All India Institute of Medical Sciences, New Delhi 110029, India

**AIMS AND SCOPE**

The primary aim of *World Journal of Clinical Cases* (WJCC, *World J Clin Cases*) is to provide scholars and readers from various fields of clinical medicine with a platform to publish high-quality clinical research articles and communicate their research findings online.

WJCC mainly publishes articles reporting research results and findings obtained in the field of clinical medicine and covering a wide range of topics, including case control studies, retrospective cohort studies, retrospective studies, clinical trials studies, observational studies, prospective studies, randomized controlled trials, randomized clinical trials, systematic reviews, meta-analysis, and case reports.

**INDEXING/ABSTRACTING**

The WJCC is now indexed in PubMed, PubMed Central, Science Citation Index Expanded (also known as SciSearch®), and Journal Citation Reports/Science Edition. The 2019 Edition of Journal Citation Reports cites the 2018 impact factor for WJCC as 1.153 (5-year impact factor: N/A), ranking WJCC as 99 among 160 journals in Medicine, General and Internal (quartile in category Q3).

**RESPONSIBLE EDITORS FOR THIS ISSUE**

Responsible Electronic Editor: Ji-Hong Liu

Proofing Production Department Director: Yun-Xiaojuan Wu

**NAME OF JOURNAL**

*World Journal of Clinical Cases*

**ISSN**

ISSN 2307-8960 (online)

**LAUNCH DATE**

April 16, 2013

**FREQUENCY**

Semimonthly

**EDITORS-IN-CHIEF**

Dennis A Bloomfield, Bao-Gan Peng, Sandro Vento

**EDITORIAL BOARD MEMBERS**

<https://www.wjgnet.com/2307-8960/editorialboard.htm>

**EDITORIAL OFFICE**

Jin-Lei Wang, Director

**PUBLICATION DATE**

December 26, 2019

**COPYRIGHT**

© 2020 Baishideng Publishing Group Inc

**INSTRUCTIONS TO AUTHORS**

<https://www.wjgnet.com/bpg/gerinfo/204>

**GUIDELINES FOR ETHICS DOCUMENTS**

<https://www.wjgnet.com/bpg/GerInfo/287>

**GUIDELINES FOR NON-NATIVE SPEAKERS OF ENGLISH**

<https://www.wjgnet.com/bpg/gerinfo/240>

**PUBLICATION MISCONDUCT**

<https://www.wjgnet.com/bpg/gerinfo/208>

**ARTICLE PROCESSING CHARGE**

<https://www.wjgnet.com/bpg/gerinfo/242>

**STEPS FOR SUBMITTING MANUSCRIPTS**

<https://www.wjgnet.com/bpg/GerInfo/239>

**ONLINE SUBMISSION**

<https://www.f6publishing.com>



## Pneumococcal infection transmission between family members with congenital asplenia: A case report

Jumpei Shibata, Kazuhiro Hiramatsu, Tsuneaki Kenzaka, Takehito Kato

**ORCID number:** Jumpei Shibata (0000-0002-7817-1614); Kazuhiro Hiramatsu (0000-0002-5176-0734); Tsuneaki Kenzaka (0000-0002-3120-6605); Takehito Kato (0000-0003-2449-5645).

**Author contributions:** Shibata J was responsible for the clinical management of the patient, drafting and editing of the manuscript; Hiramatsu K participated in critical revision of the manuscript for intellectual content; Kenzaka T is a major contributor in revise the manuscript and select data; Kato T is a contributor in checking whether the final manuscripts were adequate for submitting; all authors read and approved the final manuscript.

**Informed consent statement:** Informed written consent was obtained from the patients' family.

**Conflict-of-interest statement:** The authors declare that they have no conflict of interest.

**CARE Checklist (2016) statement:** The manuscript was prepared and revised according to the CARE Checklist (2016).

**Open-Access:** This article is an open-access article which was selected by an in-house editor and fully peer-reviewed by external reviewers. It is distributed in accordance with the Creative Commons Attribution Non Commercial (CC BY-NC 4.0) license, which permits others to distribute, remix, adapt, build upon this work non-commercially, and license their derivative works

**Jumpei Shibata, Kazuhiro Hiramatsu, Takehito Kato,** Department of General Surgery, Toyohashi Municipal Hospital, 50 Aza Hachiken Nishi, Aotake-Cho, Aichi 4418570, Toyohashi, Japan

**Tsuneaki Kenzaka,** Division of Community Medicine and Career Development, Kobe University Graduate School of Medicine, Hyogo 6520032, Kobe, Japan

**Corresponding author:** Jumpei Shibata, MD, Doctor, Department of General Surgery, Toyohashi Municipal Hospital, 50 Aza Hachiken Nishi, Aotake-Cho, Aichi 4418570, Toyohashi, Japan. [shibata-jumpei@toyohashi-mh.jp](mailto:shibata-jumpei@toyohashi-mh.jp)  
**Telephone:** +81-532-336111  
**Fax:** +81-532-336177

### Abstract

#### BACKGROUND

Asplenia, the lack of a spleen, can be congenital and increases susceptibility to severe infections caused by encapsulated bacteria, such as *Streptococcus pneumoniae* (*S. pneumoniae*). We report two cases of severe pneumococcal infection in two asplenic family members living in the same household.

#### CASE SUMMARY

Patient 1, a 38-year-old man with a history of congenital hepatitis B infection and hypospadias, was brought to our emergency department with complaints of cyanosis, cough, and edema of his limbs. He was clinically diagnosed as hyposplenic with overwhelming pneumococcal sepsis. He was admitted to the intensive care unit and was administered antibiotics and catecholaminergic therapy but died 2 h after admission. Patient 2, a 63-year-old woman with a history of type 2 diabetes, was brought to our emergency department one month after admission of Patient 1. She was diagnosed as asplenic with overwhelming pneumococcal sepsis. History-taking revealed that she was the mother of Patient 1 and the two had lived in the same household. She was admitted to the intensive care unit and was rapidly provided antibiotics and catecholaminergic intervention but died one day after admission.

#### CONCLUSION

Pneumococcal bacteremia caused by virulent *S. pneumoniae* may be transmitted within households. All residents of households where individuals with pneumococcal bacteremia are living should be educated about the risk of transmissibility. Family members of patients with congenital asplenia/hyposplenia, all family members should be examined to assess their splenic function.

on different terms, provided the original work is properly cited and the use is non-commercial. See: <http://creativecommons.org/licenses/by-nc/4.0/>

**Manuscript source:** Unsolicited manuscript

**Received:** September 28, 2019

**Peer-review started:** September 28, 2019

**First decision:** November 11, 2019

**Revised:** November 22, 2019

**Accepted:** November 27, 2019

**Article in press:** November 27, 2019

**Published online:** December 26, 2019

**P-Reviewer:** Anis S, Jun C

**S-Editor:** Zhang L

**L-Editor:** A

**E-Editor:** Qi LL



**Key words:** *Streptococcus pneumoniae*; Pneumococcal infection; Asplenia; Hyposplenia; Isolated congenital asplenia; Septic shock; Case report

©The Author(s) 2019. Published by Baishideng Publishing Group Inc. All rights reserved.

**Core tip:** We present two cases of severe pneumococcal infection transmitted between family members with congenital asplenia. *Streptococcus pneumoniae* infection may be transmitted within a household, so all household members should be warned when there is an infection in the house. In addition, asplenia/hyposplenia is sometimes congenital, so family members should be screened for these conditions.

**Citation:** Shibata J, Hiramatsu K, Kenzaka T, Kato T. Pneumococcal infection transmission between family members with congenital asplenia: A case report. *World J Clin Cases* 2019; 7(24): 4277-4284

**URL:** <https://www.wjnet.com/2307-8960/full/v7/i24/4277.htm>

**DOI:** <https://dx.doi.org/10.12998/wjcc.v7.i24.4277>

## INTRODUCTION

The spleen is a lymphoid organ housing splenic macrophages that eliminate infected cells and bacteria from the body *via* phagocytosis<sup>[1]</sup>. It is also a major site of early immunoglobulin M production, which helps to clear pathogens from the bloodstream<sup>[2]</sup>. Asplenia or hyposplenia may occur as a congenital anomaly or as a result of splenectomy following hematologic disease or trauma<sup>[3]</sup>. Asplenic individuals are at increased risk of invasive infections caused by encapsulated organisms, such as *Streptococcus pneumoniae* (*S. pneumoniae*), which can progress to fulminant sepsis within a short period. Since these infections have high mortality rates even with aggressive treatment, preventive education and vaccination of asplenic individuals are of the utmost importance<sup>[4]</sup>.

Pneumococcal pneumonia infections can be transmitted among people living in close contact with each other, such as those within a single household<sup>[5]</sup>. Here we report two cases of fulminant *S. pneumoniae* infection transmitted between two asplenic family members living in a single household. Through this report we aim to make readers aware of the familial nature of some asplenic and of the need to screen family members of individuals with congenital asplenicism.

## CASE PRESENTATION

### Chief complaints

**Case 1:** Patient 1, a 38-year-old male with a medical history of congenital hepatitis B infection and hypospadias was brought to our emergency department complaining of cyanosis, cough, and edema of his limbs.

**Case 2:** Patient 2, a 63-year-old female with a history of type 2 diabetes, was brought to our emergency department one month after admission of Patient 1. Her chief complaint was vomiting and general malaise that had lasted for four hours. Although she had been well earlier that morning, she was in a lethargic state by noon.

### History of past illness

**Case 1:** The patient had a medical history of congenital hepatitis B infection and hypospadias.

**Case 2:** The female with a history of type 2 diabetes.

### Personal and family history

**Case 1:** His family history contained nothing of note; specifically, there was no family history of any immunodeficiency disorder or other congenital anomalies.

**Case 2:** History-taking revealed that she was the mother of Patient 1 and the two had lived in the same household.

**Physical examination upon admission**

**Case 1:** His vital signs were markedly abnormal with a respiratory rate of 40 /min, body temperature of 35.9 °C, a heart rate of 144 beats/min, and oxygen saturation of 82% with oxygen 5 L/min. His blood pressure was 52/38 mmHg. He was oriented in time, place and person. On physical examination he was found to have cyanosis of the limbs.

**Case 2:** Her vital signs were markedly abnormal with a respiratory rate of 30 /min, body temperature of 40.1 °C, heart rate of 135 beats/min, oxygen saturation of 96% in ambient air, and blood pressure of 137/84 mmHg; her Glasgow coma scale score was 10 (E2V3M5) points. Nothing abnormal was detected upon physical examination.

**Laboratory examinations**

**Case 1:** Laboratory test results revealed a neutrophilia with normal white blood cell count (6400 cells/ $\mu$ L, with 90.2% neutrophils), and a platelet count of 34000 cells/ $\mu$ L. Liver and kidney function test results were grossly abnormal, and coagulation times were severely prolonged. The results of the blood test taken at this stage are presented in [Table 1](#). A urinary sample could not be obtained because the patient had anuria.

**Case 2:** The results of the blood test taken at this stage are presented in [Table 2](#).

**Imaging examinations**

**Case 1:** His chest X-ray was unremarkable.

**Case 2:** A computed tomography scan revealed that she had no spleen ([Figure 1](#)) and a urinary rapid test for *S. pneumoniae*-antigen was positive.

---

**FINAL DIAGNOSIS**

---

**Case 1**

He was clinically diagnosed as having overwhelming pneumococcal sepsis secondary to hyposplenia.

**Case 2**

She was diagnosed as having overwhelming pneumococcal sepsis secondary to asplenia.

---

**TREATMENT**

---

**Case 1**

In spite of rapid initiation of antimicrobial therapy, catecholaminergic therapy, fluid resuscitation, and intubation, the patient's organ function deteriorated and he died two hours after admission.

**Case 2**

Intravenous antibiotics, comprising 2 g ceftriaxone daily, 0.75 g vancomycin 12-hourly, and 2 g ampicillin 6-hourly, were initiated two hours after her arrival. She was transferred to the ICU where, despite the antimicrobial therapy, catecholaminergic therapy and intubation, her condition deteriorated and she died within 24 h.

---

**OUTCOME AND FOLLOW-UP**

---

**Case 1**

An autopsy revealed that he had an extremely small spleen ([Figure 2](#)), and *S. pneumoniae* was isolated from his blood, muscles, lungs, and spleen on culture.

**Case 2**

After her death, *S. pneumoniae* bacteria were obtained from her blood culture.

Although bacterial strain analysis did not match with the samples from both patients, antibiotic sensitivity tests revealed that both sets of isolates had a similar antibiotic sensitivity profile ([Table 3](#)).

After encountering these two familial cases, we examined the child of the Patient 1 to assess whether she had any immune system abnormalities. According to the echocardiogram, abdominal ultrasound including splenic morphology, and blood



**Table 1** Laboratory data of Patient 1 upon admission

Parameter	Recorded value	Standard value
White blood cell count	6400 / $\mu$ L	3590-9640 / $\mu$ L
Neutrophils	90.2%	41.2%-74.7%
Lymphocytes	8.4%	21.2%-51.0%
Hemoglobin	16.1 g/dL	13.2-17.2 g/dL
Hematocrit	47.3%	40.4%-51.1%
Platelets	$3.4 \times 10^4$ / $\mu$ L	$(14.8-33.9) \times 10^4$ / $\mu$ L
C-reactive protein	18.2 mg/dL	$\leq 0.30$ mg/dL
Total protein	5.5 g/dL	6.7-8.3 g/dL
Albumin	2.9 g/dL	3.9-4.9 g/dL
Aspartate aminotransferase	232 U/L	13-33 U/L
Alanine aminotransferase	154 U/L	6-30 U/L
Lactate dehydrogenase	700 U/L	119-229 U/L
Creatine phosphokinase	356 U/L	62-287 U/L
Blood nitrogen urea	35 mg/dL	8-22 mg/dL
Creatinine	4.72 mg/dL	0.60-1.10 mg/dL
Sodium	136 mEq/L	138-146 mEq/L
Potassium	4.4 mEq/L	3.6-4.9 mEq/L
Glucose	118 mg/dL	60-160 mg/dL
Hemoglobin A1c	6.7%	4.6%-6.2%
Prothrombin time	24.8 s	9.4-12.5 s
Activated partial thromboplastin time	97.8 s	25.1-36.5 s
Fibrinogen	131 mg/dL	155-415 mg/dL
Fibrin/Fibrinogen degradation products	68.6 $\mu$ g/mL	0-4.9 $\mu$ g/mL

examination with immunoglobulin and complement, the child had a normal spleen and no evidence of any immunodeficiency disorder. Since she had received only the heptavalent pneumococcal vaccine, we gave her an additional 13-valent vaccine to prevent recurrence of the infection identified in Patients 1 and 2.

## DISCUSSION

We encountered two first-degree relatives with septic shock caused by *S. pneumoniae*. To the best of our knowledge this is the first report of possible household transmission of *S. pneumoniae* infection among family members with congenital hyposplenia/asplenia. Moreover, there has only been one previous report of *S. pneumoniae* bacteremia acquired by household transmission<sup>[6]</sup>. The two cases presented in our report provide the following lessons: (1) *S. pneumoniae* infection may be transmitted within a household, so other household members should be warned if another person in the household develops a *S. pneumoniae* infection; and (2) Asplenia/hyposplenia is sometimes congenital, so the family members of patients found to have asplenia/hyposplenia should be screened for these conditions.

The most common cause of anatomic asplenia is surgical splenectomy due to trauma or for therapeutic intervention; congenital asplenia is rare. By contrast, hyposplenism refers to the partial loss of splenic function and is often caused by medical disorders that lead to atrophy, infarction, engorgement, or infiltration of the spleen. These disorders include thalassemia, chronic liver disease, human immunodeficiency virus infection, immune disorders, and malignancies<sup>[7]</sup>.

Our two patients had no evidence of acquired asplenia or hyposplenism, and are likely to have had congenital asplenia/hyposplenia. Encapsulated bacteria are particularly resistant to phagocytosis and frequently cause severe infection in patients with impaired splenic function. The most important pathogen for such individuals is *S. pneumoniae*, which accounts for 40%-60% of cases of overwhelming sepsis in splenectomized patients<sup>[8,9]</sup>. Encapsulated organisms proliferate in the absence of opsonization and phagocytosis by splenic macrophages. In a prospective cohort study evaluating invasive pneumococcal infection, asplenic patients were found to have a higher risk of pneumococcal meningitis, and more frequently required intensive care

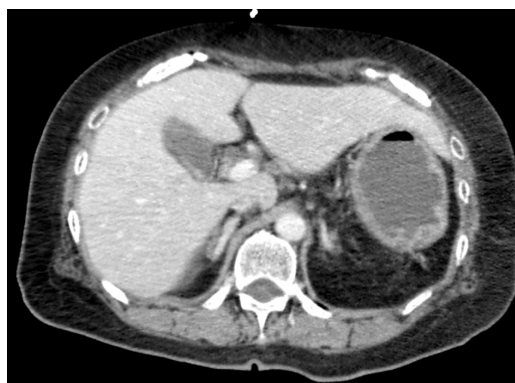**Table 2** Laboratory data of Patient 2 upon admission

Parameter	Recorded value	Standard value
White blood cell count	2260 / $\mu$ L	3040-8540 / $\mu$ L
Neutrophils	61.1%	38.3%-71.1%
Lymphocytes	37.5%	21.3%-50.2%
Hemoglobin	10.9 g/dL	10.8-14.9 g/dL
Hematocrit	32.8%	35.6%-45.4%
Platelets	$15.6 \times 10^4$ / $\mu$ L	$(15.0-36.1) \times 10^4$ / $\mu$ L
C-reactive protein	0.34 mg/dL	$\leq 0.30$ mg/dL
Total protein	6.5 g/dL	6.7-8.3 g/dL
Albumin	3.9 g/dL	3.9-4.9 g/dL
Aspartate aminotransferase	23 U/L	13-33 U/L
Alanine aminotransferase	11 U/L	6-27 U/L
Lactate dehydrogenase	276 U/L	119-229 U/L
Creatine phosphokinase	200 U/L	45-163 U/L
Blood nitrogen urea	20 mg/dL	8-22 mg/dL
Creatinine	1.32 mg/dL	0.40-0.70 mg/dL
Sodium	144 mEq/L	138-146 mEq/L
Potassium	3.4 mEq/L	3.6-4.9 mEq/L
Glucose	191 mg/dL	60-160 mg/dL
Hemoglobin A1c	6.8%	4.6%-6.2%
Prothrombin time	12.8 s	9.4-12.5 s
Activated partial thromboplastin time	22.1 s	25.1-36.5 s
Fibrinogen	131 mg/dL	155-415 mg/dL
Fibrin/Fibrinogen degradation products	24.6 $\mu$ g/mL	0-4.9 $\mu$ g/mL

unit admission and intubation<sup>[10]</sup>. The clinical symptoms of *S. pneumoniae* infection in patients with impaired splenic function can be nonspecific, but purpura fulminans, as occurred in Patient 1 in the current report, appears to be more common in asplenic patients with pneumococcal infections<sup>[9]</sup>. Immediate empiric antibiotic administration and aggressive supportive care are essential for the management of sepsis in patients with impaired splenic function because progression to septic shock can be rapid<sup>[7]</sup>. When *S. pneumoniae* infection is suspected in an individual with asplenia or hyposplenia, a course of empiric intravenous broad-spectrum antibiotics should be immediately initiated. Administration of antibiotics should not be delayed even if necessary diagnostic studies, including lumbar puncture, have not been performed.

*S. pneumoniae* is frequently found in the nasopharynx of infants and can cause pneumonia, sepsis, and meningitis in susceptible individuals<sup>[11]</sup>. Pneumococcal infection is known to be transmitted by adults in communal and family settings<sup>[12,13]</sup>. Also, pneumococcal pneumonia infection may occur within a family<sup>[5]</sup> or, more rarely, among nursing home residents<sup>[11]</sup>. In our case, it is likely that the bacteria were transmitted from Patient 1 to Patient 2 and that she became a carrier before developing symptoms because of her asplenia. Patient 2 may also have become infected *via* a child, who was a carrier and was living with the family.

In cases of intrafamilial household transmission, a diagnosis of a congenital asplenic syndrome should be considered. Various syndromes are associated with asplenia, including autoimmune polyendocrinopathy-candidiasis-ectodermal dystrophy syndrome, isolated congenital asplenia (ICA), Ivemark syndrome, and Stormorken syndrome<sup>[7,14,15]</sup>. Given that our two patients had no other abnormalities, ICA, a rare condition in which affected individuals are missing their spleen but have no other developmental abnormalities, is the most likely diagnosis. The incidence of ICA is unclear because no comprehensive surveys have been performed; to our knowledge, the only such report estimated the frequency of ICA in the French population to be 0.51 per million births<sup>[16]</sup>. Although most individuals with ICA have no spleen at all, some people have a very small, nonfunctional spleen, such as that of Patient 1. ICA differs from asplenia that is associated with other complex visceral defects<sup>[16]</sup>, as it is caused by a gene mutation that affects the production of ribosomal protein SA (RPSA). The mutation occurs on the short arm of chromosome 3 at position 22.1<sup>[17]</sup>. RPSA gene mutations are thought to reduce the amount of functional



**Figure 1 Computed tomography of the abdomen in Patient 2.** Computed tomography of the abdomen revealed the absence of a spleen.

RPSA and expression of key spleen patterning genes<sup>[18]</sup>. The *RPSA* gene is inherited in an autosomal dominant pattern. However, since some of the mutations have incomplete penetrance<sup>[19]</sup>, we were unable to determine whether the children of Patient 1 had not inherited the faulty gene, or had inherited the gene, but were unaffected due to incomplete penetrance. We assume the difference of splenic expression between Patients 1 and 2 was due to variable penetrance.

Since the progression of *S. pneumoniae* infection in individuals with asplenia or impaired splenic function is so rapid and may be overwhelming, prevention of infection is essential, and may be life-saving. Individuals with nonsurgical asplenia or hyposplenism, should be vaccinated with the pneumococcal vaccine as soon as impaired splenic function is recognized. In addition, educating these individuals about their lifelong increased risk of infection and strategies to minimize the risk is critical. Individuals who are knowledgeable about their susceptibility to infection and strategies to minimize infection risk have lower rates of severe infection compared to those without such knowledge<sup>[4]</sup>. Hence, the most important messages to stress to individuals with asplenia or hyposplenism are that they have an increased risk of infection, and that there are steps they can take to minimize their risk of infections, including vaccination, use of prophylactic antibiotics, and knowing when to seek medical care.

Of two patients in this report, we should have suspected that Patient 1 had congenital asplenia after discovering that he had hyposplenism on biopsy. Other members of his family should have been screened members and educated about their possible vulnerability to pneumococcal infections.

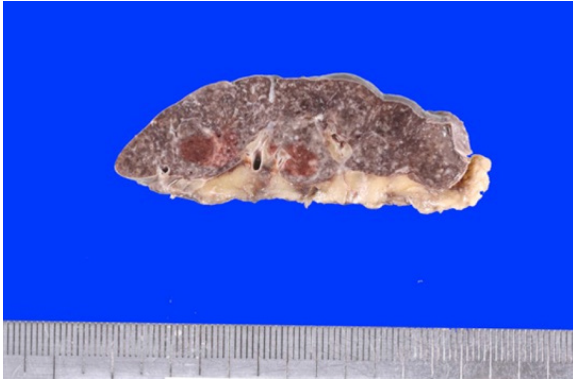
## CONCLUSION

In conclusion, we encountered a case of septic shock syndrome associated with pneumococcal bacteremia in a man with hyposplenism and a similar case in his mother who had asplenia. Pneumococcal bacteremia caused by virulent *S. pneumoniae* may be transmitted within a household, and educating family members is essential. When individuals are diagnosed as having congenital asplenia/hyposplenism, other family members should be screened.

**Table 3** Results of antibiotic sensitivity testing (g/mL)

Strain	PCG	ABPC	CTRX	CFPM	CCL	MEPM	CAM	AZM	CLDM	VCM	LVFX
Patient 1	≤ 0.06	≤ 0.12	≤ 0.06	≤ 0.06	≤ 0.5	≤ 0.015	1	> 4	0.12	0.25	1
Patient 2	≤ 0.06	≤ 0.12	≤ 0.06	≤ 0.06	≤ 0.5	≤ 0.015	1	> 4	0.5	0.25	1

ABPC: Ampicillin; CTRX: Ceftriaxone; CFPM: Cefepime; MEPM: Meropenem; AZM: Azithromycin; LVFX: Levofloxacin.

**Figure 2** Small spleen in patient 1. Autopsy indicated an extremely small spleen with a weight of 30 g.

## ACKNOWLEDGEMENTS

The authors are grateful to Matsuyoshi Maeda for explaining the pathology data.

## REFERENCES

- Borges da Silva H**, Fonseca R, Pereira RM, Cassado Ados A, Álvarez JM, D'Império Lima MR. Splenic Macrophage Subsets and Their Function during Blood-Borne Infections. *Front Immunol* 2015; **6**: 480 [PMID: 26441984 DOI: 10.3389/fimmu.2015.00480]
- Sawmiller CJ**, Dudrick SJ, Hamzi M. Postsplenectomy Capnocytophaga canimorsus sepsis presenting as an acute abdomen. *Arch Surg* 1998; **133**: 1362-1365 [PMID: 9865657 DOI: 10.1001/archsurg.133.12.1362]
- Waghorn DJ**. Overwhelming infection in asplenic patients: current best practice preventive measures are not being followed. *J Clin Pathol* 2001; **54**: 214-218 [PMID: 11253134 DOI: 10.1136/jcp.54.3.214]
- El-Alfy MS**, El-Sayed MH. Overwhelming postsplenectomy infection: is quality of patient knowledge enough for prevention? *Hematol J* 2004; **5**: 77-80 [PMID: 14745434 DOI: 10.1038/sj.thj.6200328]
- Kellner JD**, Gibb AP, Zhang J, Rabin HR. Household transmission of Streptococcus pneumoniae, Alberta, Canada. *Emerg Infect Dis* 1999; **5**: 154-158 [PMID: 10081685 DOI: 10.3201/eid0501.990120]
- Goda K**, Kenzaka T, Chang B, Akita H. Two cases of pneumococcal spondylitis in the same household: a case report. *BMC Infect Dis* 2018; **18**: 666 [PMID: 30558540 DOI: 10.1186/s12879-018-3588-5]
- Di Sabatino A**, Carsetti R, Corazza GR. Post-splenectomy and hyposplenic states. *Lancet* 2011; **378**: 86 [DOI: 10.1016/S0140-6736(10)61493-6]
- Holdsworth RJ**, Irving AD, Cuschieri A. Postsplenectomy sepsis and its mortality rate: actual versus perceived risks. *Br J Surg* 1991; **78**: 1031-1038 [PMID: 1933181 DOI: 10.1002/bjs.1800780904]
- Theilacker C**, Ludewig K, Serr A, Schimpf J, Held J, Bögelein M, Bahr V, Rusch S, Pohl A, Kogelmann K, Friesseke S, Bogdanski R, Brunkhorst FM, Kern WV. Overwhelming Postsplenectomy Infection: A Prospective Multicenter Cohort Study. *Clin Infect Dis* 2016; **62**: 871-878 [PMID: 26703862 DOI: 10.1093/cid/civ1195]
- Marrie TJ**, Tyrrell GJ, Majumdar SR, Eurich DT. Asplenic patients and invasive pneumococcal disease-how bad is it these days? *Int J Infect Dis* 2016; **51**: 27-30 [PMID: 27590561 DOI: 10.1016/j.ijid.2016.08.022]
- Nuorti JP**, Butler JC, Crutcher JM, Guevara R, Welch D, Holder P, Elliott JA. An outbreak of multidrug-resistant pneumococcal pneumonia and bacteremia among unvaccinated nursing home residents. *N Engl J Med* 1998; **338**: 1861-1868 [PMID: 9637804 DOI: 10.1056/nejm199806253382601]
- Regev-Yochay G**, Raz M, Dagan R, Porat N, Shainberg B, Pinco E, Keller N, Rubinstein E. Nasopharyngeal carriage of Streptococcus pneumoniae by adults and children in community and family settings. *Clin Infect Dis* 2004; **38**: 632-639 [PMID: 14986245 DOI: 10.1086/381547]
- Goldblatt D**, Hussain M, Andrews N, Ashton L, Virta C, Melegaro A, Pebody R, George R, Soininen A, Edmunds J, Gay N, Kayhty H, Miller E. Antibody responses to nasopharyngeal carriage of Streptococcus pneumoniae in adults: a longitudinal household study. *J Infect Dis* 2005; **192**: 387-393 [PMID: 15995951 DOI: 10.1086/431524]
- Kirkineska L**, Perifanis V, Vasiliadis T. Functional hyposplenism. *Hippokratia* 2014; **18**: 7-11 [PMID: 25125944]

- 15 **Rubin LG**, Schaffner W. Clinical practice. Care of the asplenic patient. *N Engl J Med* 2014; **371**: 349-356 [PMID: 25054718 DOI: 10.1056/NEJMcpl314291]
- 16 **Mahlaoui N**, Minard-Colin V, Picard C, Bolze A, Ku CL, Tournilhac O, Gilbert-Dussardier B, Pautard B, Durand P, Devictor D, Lachassinne E, Guillois B, Morin M, Gouraud F, Valensi F, Fischer A, Puel A, Abel L, Bonnet D, Casanova JL. Isolated congenital asplenia: a French nationwide retrospective survey of 20 cases. *J Pediatr* 2011; **158**: 142-148, 148.e1 [PMID: 20846672 DOI: 10.1016/j.jpeds.2010.07.027]
- 17 **HUGO Gene Nomenclature Committee**. Symbol report for RPSA; 18 Jul 2019. United Kingdom: Cambridge. Available from: [https://www.genenames.org/data/gene-symbol-report/#!/hgnc\\_id/6502](https://www.genenames.org/data/gene-symbol-report/#!/hgnc_id/6502)
- 18 **Griffin JN**, Sondalle SB, Robson A, Mis EK, Griffin G, Kulkarni SS, Deniz E, Baserga SJ, Khokha MK. *RPSA*, a candidate gene for isolated congenital asplenia, is required for pre-rRNA processing and spleen formation in *Xenopus*. *Development* 2018; **145** [PMID: 30337486 DOI: 10.1242/dev.166181]
- 19 **Bolze A**, Boisson B, Bosch B, Antipenko A, Bouaziz M, Sackstein P, Chaker-Margot M, Barlogis V, Briggs T, Colino E, Elmore AC, Fischer A, Genel F, Hewlett A, Jedidi M, Kelecic J, Krüger R, Ku CL, Kumararatne D, Lefevre-Utile A, Loughlin S, Mahlaoui N, Markus S, Garcia JM, Nizon M, Oleastro M, Pac M, Picard C, Pollard AJ, Rodriguez-Gallego C, Thomas C, Von Bernuth H, Worth A, Meyts I, Risolino M, Selleri L, Puel A, Klinge S, Abel L, Casanova JL. Incomplete penetrance for isolated congenital asplenia in humans with mutations in translated and untranslated *RPSA* exons. *Proc Natl Acad Sci USA* 2018; **115**: E8007-E8016 [PMID: 30072435 DOI: 10.1073/pnas.1805437115]





Published By Baishideng Publishing Group Inc  
7041 Koll Center Parkway, Suite 160, Pleasanton, CA 94566, USA  
Telephone: +1-925-3991568  
E-mail: [bpgoffice@wjgnet.com](mailto:bpgoffice@wjgnet.com)  
Help Desk: <https://www.f6publishing.com/helpdesk>  
<https://www.wjgnet.com>

