

World Journal of *Clinical Cases*

World J Clin Cases 2019 December 26; 7(24): 4172-4425



**REVIEW**

- 4172** Polyunsaturated fatty acids and DNA methylation in colorectal cancer
Moradi Sarabi M, Mohammadrezaei Khorramabadi R, Zare Z, Eftekhari E

ORIGINAL ARTICLE**Retrospective Study**

- 4186** Impact of resection margins on long-term survival after pancreaticoduodenectomy for pancreatic head carcinoma
Li CG, Zhou ZP, Tan XL, Gao YX, Wang ZZ, Liu Q, Zhao ZM
- 4196** Arthroscopy combined with unicompartmental knee arthroplasty for treatment of isolated unicompartmental knee arthritis: A long-term comparison
Wang HR, Li ZL, Li J, Wang YX, Zhao ZD, Li W
- 4208** Intact, pie-crusting and repairing the posterior cruciate ligament in posterior cruciate ligament-retaining total knee arthroplasty: A 5-year follow-up
Ma DS, Wen L, Wang ZW, Zhang B, Ren SX, Lin Y
- 4218** Community-acquired pneumonia complicated by rhabdomyolysis: A clinical analysis of 11 cases
Zhao B, Zheng R

Clinical Trials Study

- 4226** Dissection and ligation of the lateral circumflex femoral artery is not necessary when using the direct anterior approach for total hip arthroplasty
Zhao GY, Wang YJ, Xu NW, Liu F

Observational Study

- 4234** Expression of interleukin-32 in bone marrow of patients with myeloma and its prognostic significance
Wang G, Ning FY, Wang JH, Yan HM, Kong HW, Zhang YT, Shen Q

Randomized Controlled Trial

- 4245** Effect of different types of laryngeal mask airway placement on the right internal jugular vein: A prospective randomized controlled trial
Zhang JJ, Qu ZY, Hua Z, Zuo MZ, Zhang HY

SYSTEMATIC REVIEW

- 4254** Chronic pain, posttraumatic stress disorder, and opioid intake: A systematic review
López-Martínez AE, Reyes-Pérez Á, Serrano-Ibáñez ER, Esteve R, Ramírez-Maestre C

CASE REPORT

- 4270 Acute appendicitis in a patient after a uterus transplant: A case report
Kristek J, Kudla M, Chlupac J, Novotny R, Mirejovsky T, Janousek L, Fronek J
- 4277 Pneumococcal infection transmission between family members with congenital asplenia: A case report
Shibata J, Hiramatsu K, Kenzaka T, Kato T
- 4285 Successful treatment of warfarin-induced skin necrosis using oral rivaroxaban: A case report
Kamada M, Kenzaka T
- 4292 Simultaneous *Paragonimus* infection involving the breast and lung: A case report
Oh MY, Chu A, Park JH, Lee JY, Roh EY, Chai YJ, Hwang KT
- 4299 Isolated peritoneal lymphomatosis defined as post-transplant lymphoproliferative disorder after a liver transplant: A case report
Kim HB, Hong R, Na YS, Choi WY, Park SG, Lee HJ
- 4307 Three-dimensional image simulation of primary diaphragmatic hemangioma: A case report
Chu PY, Lin KH, Kao HL, Peng YJ, Huang TW
- 4314 Natural orifice specimen extraction with laparoscopic radical gastrectomy for distal gastric cancer: A case report
Sun P, Wang XS, Liu Q, Luan YS, Tian YT
- 4321 Huge brown tumor of the rib in an unlocatable hyperparathyroidism patient with “self-recovered” serum calcium and parathyroid hormone: A case report
Wang WD, Zhang N, Qu Q, He XD
- 4327 Percutaneous management of atrium and lung perforation: A case report
Zhou X, Ze F, Li D, Li XB
- 4334 Epstein-Barr virus-positive post-transplant lymphoproliferative disorder presenting as hematochezia and enterobrosis in renal transplant recipients in China: A report of two cases
Sun ZJ, Hu XP, Fan BH, Wang W
- 4342 Postoperative multidrug-resistant *Acinetobacter baumannii* meningitis successfully treated with intravenous doxycycline and intraventricular gentamicin: A case report
Wu X, Wang L, Ye YZ, Yu H
- 4349 Reconstruction of massive skin avulsion of the scrota and penis by combined application of dermal regeneration template (Pelnac) and split-thickness skin graft with vacuum-assisted closure: A case report
Fang JJ, Li PF, Wu JJ, Zhou HY, Xie LP, Lu H

- 4355** Multisystem smooth muscle dysfunction syndrome in a Chinese girl: A case report and review of the literature
Chen SN, Wang YQ, Hao CL, Lu YH, Jiang WJ, Gao CY, Wu M
- 4366** Kidney inflammatory myofibroblastic tumor masquerading as metastatic malignancy: A case report and literature review
Zhang GH, Guo XY, Liang GZ, Wang Q
- 4377** Hydroxychloroquine-induced renal phospholipidosis resembling Fabry disease in undifferentiated connective tissue disease: A case report
Wu SZ, Liang X, Geng J, Zhang MB, Xie N, Su XY
- 4384** Spontaneous ovarian hyperstimulation syndrome: Report of two cases
Gui J, Zhang J, Xu WM, Ming L
- 4391** Castleman disease in the hepatic-gastric space: A case report
Xu XY, Liu XQ, Du HW, Liu JH
- 4398** KIT and platelet-derived growth factor receptor α wild-type gastrointestinal stromal tumor associated with neurofibromatosis type 1: Two case reports
Kou YW, Zhang Y, Fu YP, Wang Z
- 4414** Isolated elevated aspartate aminotransferase in an asymptomatic woman due to macro-aspartate aminotransferase: A case report
Zhan MR, Liu X, Zhang MY, Niu JQ
- 4420** Rehabilitation of anterior pituitary dysfunction combined with extrapontine myelinolysis: A case report
Yang MX, Chen XN

ABOUT COVER

Editorial Board Member of *World Journal of Clinical Cases*, Ashu Seith Bhalla, MD, Professor, Department of Radiodiagnosis, All India Institute of Medical Sciences, New Delhi 110029, India

AIMS AND SCOPE

The primary aim of *World Journal of Clinical Cases* (WJCC, *World J Clin Cases*) is to provide scholars and readers from various fields of clinical medicine with a platform to publish high-quality clinical research articles and communicate their research findings online.

WJCC mainly publishes articles reporting research results and findings obtained in the field of clinical medicine and covering a wide range of topics, including case control studies, retrospective cohort studies, retrospective studies, clinical trials studies, observational studies, prospective studies, randomized controlled trials, randomized clinical trials, systematic reviews, meta-analysis, and case reports.

INDEXING/ABSTRACTING

The WJCC is now indexed in PubMed, PubMed Central, Science Citation Index Expanded (also known as SciSearch®), and Journal Citation Reports/Science Edition. The 2019 Edition of Journal Citation Reports cites the 2018 impact factor for WJCC as 1.153 (5-year impact factor: N/A), ranking WJCC as 99 among 160 journals in Medicine, General and Internal (quartile in category Q3).

RESPONSIBLE EDITORS FOR THIS ISSUE

Responsible Electronic Editor: Ji-Hong Liu

Proofing Production Department Director: Yun-Xiaojuan Wu

NAME OF JOURNAL

World Journal of Clinical Cases

ISSN

ISSN 2307-8960 (online)

LAUNCH DATE

April 16, 2013

FREQUENCY

Semimonthly

EDITORS-IN-CHIEF

Dennis A Bloomfield, Bao-Gan Peng, Sandro Vento

EDITORIAL BOARD MEMBERS

<https://www.wjnet.com/2307-8960/editorialboard.htm>

EDITORIAL OFFICE

Jin-Lei Wang, Director

PUBLICATION DATE

December 26, 2019

COPYRIGHT

© 2019 Baishideng Publishing Group Inc

INSTRUCTIONS TO AUTHORS

<https://www.wjnet.com/bpg/gerinfo/204>

GUIDELINES FOR ETHICS DOCUMENTS

<https://www.wjnet.com/bpg/GerInfo/287>

GUIDELINES FOR NON-NATIVE SPEAKERS OF ENGLISH

<https://www.wjnet.com/bpg/gerinfo/240>

PUBLICATION MISCONDUCT

<https://www.wjnet.com/bpg/gerinfo/208>

ARTICLE PROCESSING CHARGE

<https://www.wjnet.com/bpg/gerinfo/242>

STEPS FOR SUBMITTING MANUSCRIPTS

<https://www.wjnet.com/bpg/GerInfo/239>

ONLINE SUBMISSION

<https://www.f6publishing.com>

Three-dimensional image simulation of primary diaphragmatic hemangioma: A case report

Pei-Yi Chu, Kuan-Hsun Lin, Hao-Lun Kao, Yi-Jen Peng, Tsai-Wang Huang

ORCID number: Pei-yi Chu (0000-0002-6905-7895); Kuan-Hsun Lin (0000-0002-3371-5489); Hao-Lun Kao (0000-0002-2148-8397); Yi-jen Peng (0000-0003-4630-2103); Tsai-Wang Huang (0000-0001-8741-9223).

Author contributions: Chu PY is the first author of this case report, and she wrote the case report and completed literature review; Lin KH was the assistant surgeon, and he made the 3D image constructor; Kao HL was the attending radiologist; Peng YJ was the attending pathologist; Huang TW was the attending surgeon; Huang TW made final editing and reconstruction of the paper for approval; all authors read and approved the final manuscript.

Informed consent statement: Written informed consent was obtained from the patient for publication of this case report and any accompanying images.

Conflict-of-interest statement: The authors declare that they have no conflict of interest.

CARE Checklist (2016) statement: The manuscript was prepared and revised according to the CARE Checklist (2016).

Open-Access: This article is an open-access article which was selected by an in-house editor and fully peer-reviewed by external reviewers. It is distributed in accordance with the Creative Commons Attribution Non Commercial (CC BY-NC 4.0) license, which permits others to distribute, remix, adapt, build upon this work non-commercially,

Pei-Yi Chu, Kuan-Hsun Lin, Tsai-Wang Huang, Division of Thoracic Surgery, Department of Surgery, Tri-Service General Hospital, National Defense Medical Center, Taipei 114, Taiwan

Hao-Lun Kao, Department of Radiology, Tri-Service General Hospital, National Defense Medical Center, Taipei 114, Taiwan

Yi-Jen Peng, Department of Pathology, Tri-Service General Hospital, National Defense Medical Center, Taipei 114, Taiwan

Corresponding author: Tsai-Wang Huang, MD, PhD, Chief Doctor, Surgeon, Division of Thoracic Surgery, Department of Surgery, Tri-Service General Hospital, National Defense Medical Center, 325, Section 2, Cheng-Kung Road, Neihu District, Taipei 114, Taiwan.

chi-wang@yahoo.com.tw

Telephone: +886-2-87927167

Fax: +886-2-87927403

Abstract

BACKGROUND

Fewer than 200 cases of diaphragmatic tumors have been reported in the past century. Diaphragmatic hemangiomas are extremely rare. Only nine cases have been reported in English literature to date. We report a case of cavernous hemangioma arising from the diaphragm. Pre-operative three-dimensional (3D) simulation and minimal invasive thoracoscopic excision were performed successfully, and we describe the radiologic findings and the surgical procedure in the following article.

CASE SUMMARY

A 40-year-old man was referred for further examination of a mass over the right basal lung without specific symptoms. Contrast-enhanced computed tomography revealed a poorly-enhanced lesion in the right basal lung, abutting to the diaphragm, measuring 3.1 cm × 1.5 cm in size. The mediastinum showed a clear appearance without evidence of abnormal mass or lymphadenopathy. A preoperative 3D image was reconstructed, which revealed a diaphragmatic lesion. Video-assisted thoracic surgery was performed, and a red papillary tumor was found, originating from the right diaphragm. The tumor was resected, and the pathological diagnosis was cavernous hemangioma.

CONCLUSION

In this rare case of diaphragmatic hemangioma, 3D image simulation was helpful for the preoperative evaluation and surgical decision making.

and license their derivative works on different terms, provided the original work is properly cited and the use is non-commercial. See: <http://creativecommons.org/licenses/by-nc/4.0/>

Manuscript source: Unsolicited manuscript

Received: September 13, 2019

Peer-review started: September 13, 2019

First decision: October 24, 2019

Revised: November 8, 2019

Accepted: November 15, 2019

Article in press: November 15, 2019

Published online: December 26, 2019

P-Reviewer: Anand A, Pandey A

S-Editor: Dou Y

L-Editor: Wang TQ

E-Editor: Xing YX



Key words: Diaphragmatic tumor; Hemangioma; Case report; Three-dimensional image simulation; Video-assisted thoracic surgery; Thoracoscopy

©The Author(s) 2019. Published by Baishideng Publishing Group Inc. All rights reserved.

Core tip: Diaphragmatic hemangioma is rare, and its diagnosis is challenging. We present the case of a 40-year-old man with incidental abnormal findings in chest imaging studies. Contrast-enhanced computed tomography revealed a poorly-enhanced lesion in the right basal lung, abutting to the diaphragm. Three-dimensional (3D) image simulation revealed a supra-diaphragmatic tumor. Successful tumor resection followed by primary repair of diaphragm was performed *via* minimally invasive thoracoscopic surgery. The pathological findings confirmed a primary cavernous hemangioma of the diaphragm. In this rare case of diaphragmatic hemangioma, 3D image simulation was helpful for the preoperative evaluation and surgical decision making.

Citation: Chu PY, Lin KH, Kao HL, Peng YJ, Huang TW. Three-dimensional image simulation of primary diaphragmatic hemangioma: A case report. *World J Clin Cases* 2019; 7(24): 4307-4313

URL: <https://www.wjgnet.com/2307-8960/full/v7/i24/4307.htm>

DOI: <https://dx.doi.org/10.12998/wjcc.v7.i24.4307>

INTRODUCTION

Diaphragmatic tumors are very rare. Fewer than 200 cases have been reported in the past century^[1]. Most diaphragmatic tumors are benign, including bronchogenic cyst, lipoma, and hemangioma. Diaphragmatic hemangiomas are extremely rare, and only nine cases have been reported in the English literature to date^[2-10]. We report a rare case of cavernous hemangioma arising from the diaphragm. Pre-operative three-dimensional (3D) simulation and minimally invasive thoracoscopic excision were performed successfully, and we describe the radiologic findings and the surgical procedure in the following article.

CASE PRESENTATION

Chief complaints

A mass over the right basal lung field was found incidentally.

History of present illness

A 40-year-old man presented to our hospital with a one-day history of hematuria that was diagnosed due to a ureteral stone after examination. Computed tomography (CT) of the abdomen revealed a mass over the right basal lung field found incidentally. He was referred to a chest surgeon. Contrast-enhanced CT of the chest was arranged for further evaluation.

History of past illness

The patient denied a history of hypertension, diabetes mellitus, or coronary artery disease. He had no known drug or food allergies. He also denied a history of operation, trauma, or blood transfusion.

Personal and family history

The patient had no significant personal or family history.

Physical examination upon admission

The patient's vital signs upon arrival were as follows: Body temperature 36.5°C, heart rate 74 beats/min, respiratory rate 18 times/min, blood pressure 156/84 mmHg, and oxygen saturation 98% on room air. He was alerted and oriented. The physical examination disclosed clean breathing sounds bilaterally, no chest tenderness, and no chest wall deformity. There was no specific finding of other systems.

Laboratory examinations

A complete blood count was obtained showing a white blood cell count of $8.75 \times 10^6/L$, hemoglobin level of 15.7 g/dL, and platelet count of $222 \times 10^9/L$. Electrolyte, blood biochemistry, and coagulation tests were all in normal range.

Imaging examinations

Contrast-enhanced CT of the chest revealed a poorly-enhanced lesion in the right basal lung, abutting the right diaphragm, measuring 3.1 cm \times 1.5 cm in size (Figure 1). The mediastinum showed a clear appearance without evidence of abnormal mass or lymphadenopathy.

FINAL DIAGNOSIS

The resected tumor was sent for pathology examination after the operation. Grossly, the tumor was 3.5 cm \times 1.5 cm \times 1.3 cm in size and brown in color, with a soft consistency. Microscopically, the section showed a vascular lesion composed of dilated cavernous vascular spaces separated by irregular vascular walls (Figure 2). The pathological findings were compatible with those of cavernous hemangioma.

TREATMENT

It was difficult to differentiate its origin from that of lung parenchyma or diaphragm tumor. A preoperative 3D image was reconstructed, which revealed a diaphragmatic lesion (Figure 3). The patient underwent video-assisted surgery. A thoracoscope was inserted into the thoracic cavity *via* an incision in the 8th intercostal space. Intraoperative findings revealed a lobulated reddish tumor located at the lateral aspect of the right diaphragm with a wide-based pedicle (Figure 4). The patient underwent a thoracoscopic procedure with tumor resection, followed by primary repair of the diaphragm. An energy device (LigaSure™ vessel sealing technology, Medtronic) was used because of the presence of an abundant feeding vessel which bled easily on touch.

OUTCOME AND FOLLOW-UP

The patient's postoperative course was uneventful, and he was found to be tumor free during the 2-year follow-up.

DISCUSSION

Primary diaphragmatic tumors are very rare. In the past century, fewer than 200 cases have been reported^[1]. Most diaphragmatic tumors are benign, including cystic mass (bronchogenic cyst, for example), lipoma, hemangioma, angiofibroma, neurofibroma, schwannoma, leiomyoma, teratoma, and endometrioma. Malignant diaphragmatic tumors include rhabdomyosarcoma, fibrosarcoma, sarcoma, hemangiopericytoma, germ cell tumors, pheochromocytoma, and leiomyosarcoma. Diaphragmatic hemangiomas are extremely rare, and only nine cases have been reported in the English literature to date^[2-10] (Table 1).

Most diaphragmatic tumors are asymptomatic and, therefore, often incidentally found. Associated symptoms are often related to the compression effect of huge tumors, including chest pain, shortness of breath, or abdominal pain. CT discloses more information about these tumors, such as size, location, and relationship with other structures. Using CT, we can also distinguish whether a diaphragmatic tumor is cystic or solid in nature. Magnetic resonance imaging (MRI) with contrast could help evaluate the internal components of the tumor without any concern of radiation dosage.

It is common to diagnose hepatic hemangioma by abdominal dynamic three-phase CT. Kono *et al*^[5] reported a case of diaphragmatic hemangioma using dynamic imaging findings. On contrast-enhanced dynamic MRI images of T1-weighted imaging, the lesion showed a gradual enhancement pattern, which was maintained in the late phase. It describes the possibility of differentiating diaphragmatic hemangioma from other diaphragm tumors. In our case, two-phase contrast-enhanced CT of the chest disclosed a poorly-enhanced lobulated soft-tissue lesion, measuring 3.1 cm \times 1.5 cm in size, in the right basal lung. Dynamic three-phase CT might provide more information. However, other vascular-rich tumors, such as

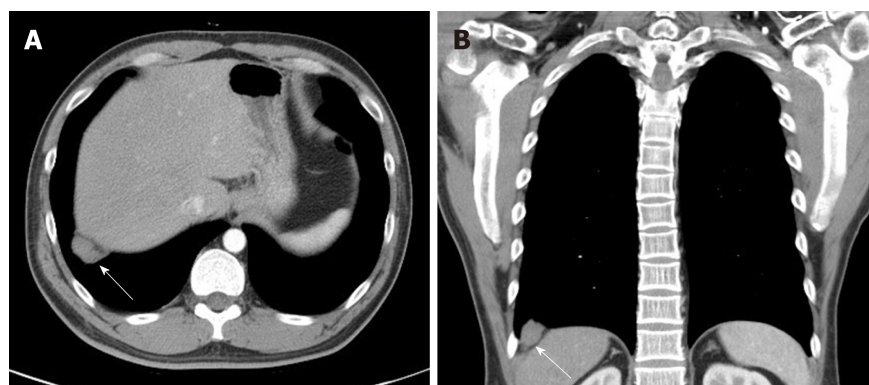


Figure 1 Contrast-enhanced chest computed tomography images illustrating a poorly-enhanced lesion (arrow) in the right basal lung, abutting the right diaphragm. A: Axial view; B: Coronal view.

hemangiopericytoma and angiofibroma, should be included in the differential diagnosis as well. Pathological examination is still required to confirm the diagnosis.

Benign diaphragmatic tumors could be observed. Image-guided needle biopsy is considered only for some patients because of limitations imposed by tumor size, diaphragm motion during inspiration and expiration, and risk of bleeding. Surgical treatment of a diaphragmatic tumor is indicated for patients with a symptomatic benign tumor or a resectable malignant tumor, or for patients requiring a definitive diagnosis. However, due to the small size of the tumor and risk of bleeding, we performed surgical intervention for our patient instead of biopsy.

Sometimes, it is difficult to distinguish between tumors originating from the lung, diaphragm, or intraabdominal organs using two-dimensional imaging. Their origin determines the surgical approach, which is either laparoscopy or thoracoscopy. Thapar *et al*^[11] described a case of a diaphragmatic tumor that was thought to be an atypical hepatic mass preoperatively. 3D image simulation might be of help in such a situation.

The usefulness of 3D angiography using multiple detector CT in thoracic surgery was first reported by Watanabe *et al*^[12] in 2003. Over the past decade, advanced software provides high-quality 3D models of the pulmonary vessels and the tracheobronchial tree. The clinical applications of 3D lung modeling in surgical simulation and navigation systems are safe and useful^[13]. In this case, we built a 3D image simulation (Mimics Innovation Suite 21.0, Materialise) that clarified the relationship of the tumor and neighboring organs. The simulation revealed that it was a diaphragmatic tumor abutting the right basal lung, without any obvious extra blood supply. Thoracoscopic tumor resection was deemed suitable for this patient and it was performed smoothly.

CONCLUSION

3D image simulation clarified the relationship of the tumor and neighboring organs. In this rare case of diaphragmatic hemangioma, 3D image simulation was helpful for the preoperative evaluation of the tumor and surgical decision making.

Table 1 Nine cases of diaphragmatic hemangiomas reported in the English literature to date

| Ref. | Gender | Age (yr) | Clinical magnification | Diagnostic modality | Tumor location | Treatment | Outcome |
|---|---------|----------|---|---|-----------------------------------|--|---------|
| Kaniklides <i>et al</i> ^[2] , 1999 | Male | 4 | Large numbers of subcutaneous vessels over left upper abdominal wall | CT, MRI, angiography | Supraphrenic, left | Surgical resection with laparotomy plus thoracotomy | Good |
| Ohsaki <i>et al</i> ^[3] , 2000 | Female | 31 | Chest pain on the deep inspirations | CT, MRI, bone scintigraphy (99mTc-hydroxymethylene diphosphonate) | Supraphrenic, right | Surgical resection <i>via</i> thoracic approach | Good |
| Cacciaguerra <i>et al</i> ^[4] , 2001 | Female | 0 | Neonatal respiratory failure and hydrops fetalis | Cardiac sonography, CT | Supraphrenic, right | Surgical resection with median sternotomy | Good |
| Kono <i>et al</i> ^[5] , 2006 | Female | 75 | No specific discomfort | CT, MRI | Supraphrenic, right | Surgical resection <i>via</i> thoracoscopic approach | good |
| Ino <i>et al</i> ^[6] , 2010 | Male | 64 | No specific discomfort | CT, PET scan | Subphrenic, left | Surgical resection <i>via</i> laparoscopic approach | Good |
| Tsang <i>et al</i> ^[9] , 2011 | Male | 0 | Massive pleural effusion, pericardial effusion with cardiac tamponade | Chest X ray, cardioechography | Supraphrenic and subphrenic, left | Surgical resection with median sternotomy, extended to upper abdomen | Good |
| Ueno <i>et al</i> ^[7] , 2013 | Male | 51 | No specific discomfort | CT, PET scan | Supraphrenic, right | Surgical resection <i>via</i> thoracic approach | Good |
| Yao <i>et al</i> ^[8] , 2013 | Unknown | 0 | Dyspnea | CT, MR | Supraphrenic, right | Interventional vascular embolization | Good |
| Wu <i>et al</i> ^[10] , 2015 | Female | 0 | Progressive respiratory distress and massive right hydrothorax | Sonography, CT, MRI | Supraphrenic, right | Interventional vascular embolization | Good |

CT: Computed tomography; MRI: Magnetic resonance imaging; PET: Positron emission tomography.

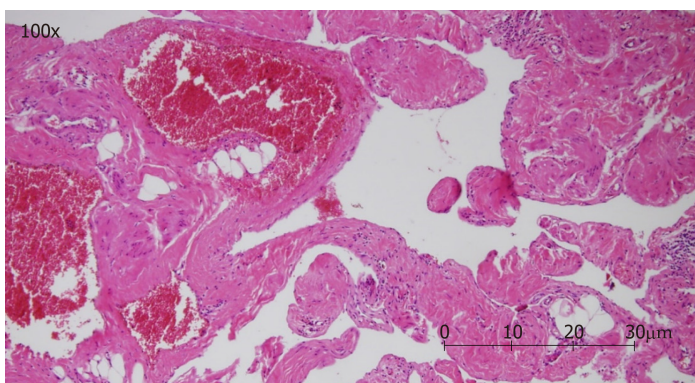


Figure 2 Pathologic image showing a vascular lesion composed of dilated cavernous vascular spaces separated by irregular vascular walls microscopically. The pathologic findings (hematoxylin and eosin staining; magnification, 100×) are compatible with those of cavernous hemangioma.

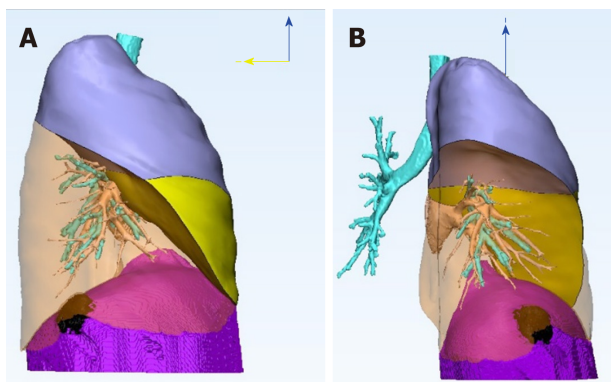


Figure 3 Three-dimension reconstruction image illustrating the relationship of the tumor and neighboring organs. We mark the right upper lobe in lavender color, the right middle lobe in yellow, and the diaphragm in purple. The right lower lobe is transparent to see the black lesion clearly. The three-dimension reconstruction image reveals a diaphragmatic lesion, without lung parenchyma involvement. A: Right lateral view of the right lung; B: Posterior view of the right lung.

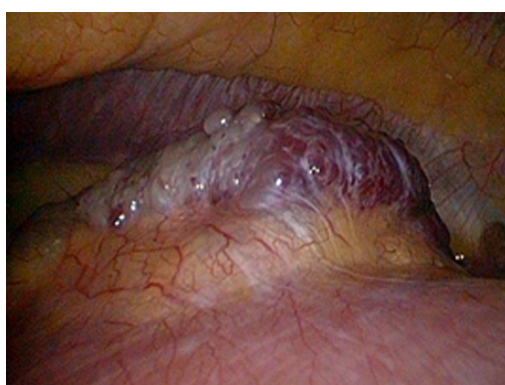

Figure 4 Intraoperative image of a red papillary tumor arising from the right diaphragm. The resected tumor measured 3.5 cm × 1.5 cm × 1.3 cm in size, was brown in color, and had a soft consistency.

REFERENCES

- 1 Kim MP, Hofstetter WL. Tumors of the diaphragm. *Thorac Surg Clin* 2009; **19**: 521-529 [PMID: 20112635 DOI: 10.1016/j.thorsurg.2009.08.007]
- 2 Kaniklides C, Dimopoulos PA. Diaphragmatic haemangioma. A case report. *Acta Radiol* 1999; **40**: 329-332 [PMID: 10335974 DOI: 10.3109/02841859909175563]
- 3 Ohsaki Y, Morimoto H, Osanai S, Nishigaki Y, Akiba Y, Hasebe C, Hirata S, Aburano T, Miyokawa N, Kikuchi K. Extensively calcified hemangioma of the diaphragm with increased 99mTc-hydroxymethylene diphosphonate uptake. *Intern Med* 2000; **39**: 576-578 [PMID: 10888215 DOI: 10.2169/internalmedicine.39.576]
- 4 Cacciaguerra S, Vasta G, Benedetto AG, Bagnara V, Guarnera S, Bartoloni G, Patanè L. Neonatal diaphragmatic hemangioma. *J Pediatr Surg* 2001; **36**: E21 [PMID: 11528638 DOI: 10.1053/jpsu.2001.26403]
- 5 Kono R, Terasaki H, Fujimoto K, Sadohara J, Oshita Y, Yano H, Hayabuchi N. Venous hemangioma arising from the diaphragm: a case report of computed tomography and magnetic resonance imaging findings. *J Thorac Imaging* 2006; **21**: 231-234 [PMID: 16915071 DOI: 10.1097/01.rti.0000209820.35755.e9]
- 6 Ino H, Naitou M, Hato S, Tomiyama K, Mandai Y, Hayashi T, Okada M, Doihara H. A rare primary diaphragmatic hemangioma successfully treated by laparoscopic surgery: report of a case. *Surg Today* 2010; **40**: 654-657 [PMID: 20582518 DOI: 10.1007/s00595-009-4117-3]
- 7 Ueno K, Takeuchi E, Hino H, Kawashima M. Cavernous hemangioma arising from the diaphragm. *Asian Cardiovasc Thorac Ann* 2013; **21**: 735-738 [PMID: 24569338 DOI: 10.1177/0218492312469361]
- 8 Yao Q, Hu X, Huang G, Pa M. A case of diaphragmatic infantile hemangioma. *J Perinatol* 2013; **33**: 576-577 [PMID: 23803680 DOI: 10.1038/jp.2012.162]
- 9 Tsang FH, Lun KS, Cheng LC. Hemangioma of the diaphragm presenting with cardiac tamponade. *J Card Surg* 2011; **26**: 620-623 [PMID: 22004551 DOI: 10.1111/j.1540-8191.2011.01334.x]
- 10 Wu L, Wang JM, Qiao ZW, Yan YL, Wang LS. Successful embolization and long-term follow-up of a rare neonatal diaphragmatic hemangioma. *SAGE Open Med Case Rep* 2015; **3**: 2050313X15615471 [PMID: 27489702 DOI: 10.1177/2050313X15615471]
- 11 Thapar S, Ahuja A, Rastogi A. Rare diaphragmatic tumor mimicking liver mass. *World J Gastrointest Surg* 2014; **6**: 33-37 [PMID: 24600509 DOI: 10.4240/wjgs.v6.i2.33]
- 12 Watanabe S, Arai K, Watanabe T, Koda W, Urayama H. Use of three-dimensional computed tomographic angiography of pulmonary vessels for lung resections. *Ann Thorac Surg* 2003; **75**: 388-92; discussion 392

- [PMID: 12607645 DOI: 10.1016/S0003-4975(02)04375-8]
- 13 **Ikeeda N**, Yoshimura A, Hagiwara M, Akata S, Saji H. Three dimensional computed tomography lung modeling is useful in simulation and navigation of lung cancer surgery. *Ann Thorac Cardiovasc Surg* 2013; **19**: 1-5 [PMID: 23364234 DOI: 10.5761/atcs.ra.12.02174]



Published By Baishideng Publishing Group Inc
7041 Koll Center Parkway, Suite 160, Pleasanton, CA 94566, USA
Telephone: +1-925-2238242
E-mail: bpgoffice@wjgnet.com
Help Desk: <https://www.f6publishing.com/helpdesk>
<https://www.wjgnet.com>

