

World Journal of *Clinical Cases*

World J Clin Cases 2019 December 26; 7(24): 4172-4425



**REVIEW**

- 4172** Polyunsaturated fatty acids and DNA methylation in colorectal cancer
Moradi Sarabi M, Mohammadrezaei Khorramabadi R, Zare Z, Eftekhari E

ORIGINAL ARTICLE**Retrospective Study**

- 4186** Impact of resection margins on long-term survival after pancreaticoduodenectomy for pancreatic head carcinoma
Li CG, Zhou ZP, Tan XL, Gao YX, Wang ZZ, Liu Q, Zhao ZM
- 4196** Arthroscopy combined with unicompartmental knee arthroplasty for treatment of isolated unicompartmental knee arthritis: A long-term comparison
Wang HR, Li ZL, Li J, Wang YX, Zhao ZD, Li W
- 4208** Intact, pie-crusting and repairing the posterior cruciate ligament in posterior cruciate ligament-retaining total knee arthroplasty: A 5-year follow-up
Ma DS, Wen L, Wang ZW, Zhang B, Ren SX, Lin Y
- 4218** Community-acquired pneumonia complicated by rhabdomyolysis: A clinical analysis of 11 cases
Zhao B, Zheng R

Clinical Trials Study

- 4226** Dissection and ligation of the lateral circumflex femoral artery is not necessary when using the direct anterior approach for total hip arthroplasty
Zhao GY, Wang YJ, Xu NW, Liu F

Observational Study

- 4234** Expression of interleukin-32 in bone marrow of patients with myeloma and its prognostic significance
Wang G, Ning FY, Wang JH, Yan HM, Kong HW, Zhang YT, Shen Q

Randomized Controlled Trial

- 4245** Effect of different types of laryngeal mask airway placement on the right internal jugular vein: A prospective randomized controlled trial
Zhang JJ, Qu ZY, Hua Z, Zuo MZ, Zhang HY

SYSTEMATIC REVIEW

- 4254** Chronic pain, posttraumatic stress disorder, and opioid intake: A systematic review
López-Martínez AE, Reyes-Pérez Á, Serrano-Ibáñez ER, Esteve R, Ramírez-Maestre C

CASE REPORT

- 4270 Acute appendicitis in a patient after a uterus transplant: A case report
Kristek J, Kudla M, Chlupac J, Novotny R, Mirejovsky T, Janousek L, Fronek J
- 4277 Pneumococcal infection transmission between family members with congenital asplenia: A case report
Shibata J, Hiramatsu K, Kenzaka T, Kato T
- 4285 Successful treatment of warfarin-induced skin necrosis using oral rivaroxaban: A case report
Kamada M, Kenzaka T
- 4292 Simultaneous *Paragonimus* infection involving the breast and lung: A case report
Oh MY, Chu A, Park JH, Lee JY, Roh EY, Chai YJ, Hwang KT
- 4299 Isolated peritoneal lymphomatosis defined as post-transplant lymphoproliferative disorder after a liver transplant: A case report
Kim HB, Hong R, Na YS, Choi WY, Park SG, Lee HJ
- 4307 Three-dimensional image simulation of primary diaphragmatic hemangioma: A case report
Chu PY, Lin KH, Kao HL, Peng YJ, Huang TW
- 4314 Natural orifice specimen extraction with laparoscopic radical gastrectomy for distal gastric cancer: A case report
Sun P, Wang XS, Liu Q, Luan YS, Tian YT
- 4321 Huge brown tumor of the rib in an unlocatable hyperparathyroidism patient with “self-recovered” serum calcium and parathyroid hormone: A case report
Wang WD, Zhang N, Qu Q, He XD
- 4327 Percutaneous management of atrium and lung perforation: A case report
Zhou X, Ze F, Li D, Li XB
- 4334 Epstein-Barr virus-positive post-transplant lymphoproliferative disorder presenting as hematochezia and enterobrosis in renal transplant recipients in China: A report of two cases
Sun ZJ, Hu XP, Fan BH, Wang W
- 4342 Postoperative multidrug-resistant *Acinetobacter baumannii* meningitis successfully treated with intravenous doxycycline and intraventricular gentamicin: A case report
Wu X, Wang L, Ye YZ, Yu H
- 4349 Reconstruction of massive skin avulsion of the scrota and penis by combined application of dermal regeneration template (Pelnac) and split-thickness skin graft with vacuum-assisted closure: A case report
Fang JJ, Li PF, Wu JJ, Zhou HY, Xie LP, Lu H

- 4355** Multisystem smooth muscle dysfunction syndrome in a Chinese girl: A case report and review of the literature
Chen SN, Wang YQ, Hao CL, Lu YH, Jiang WJ, Gao CY, Wu M
- 4366** Kidney inflammatory myofibroblastic tumor masquerading as metastatic malignancy: A case report and literature review
Zhang GH, Guo XY, Liang GZ, Wang Q
- 4377** Hydroxychloroquine-induced renal phospholipidosis resembling Fabry disease in undifferentiated connective tissue disease: A case report
Wu SZ, Liang X, Geng J, Zhang MB, Xie N, Su XY
- 4384** Spontaneous ovarian hyperstimulation syndrome: Report of two cases
Gui J, Zhang J, Xu WM, Ming L
- 4391** Castleman disease in the hepatic-gastric space: A case report
Xu XY, Liu XQ, Du HW, Liu JH
- 4398** KIT and platelet-derived growth factor receptor α wild-type gastrointestinal stromal tumor associated with neurofibromatosis type 1: Two case reports
Kou YW, Zhang Y, Fu YP, Wang Z
- 4414** Isolated elevated aspartate aminotransferase in an asymptomatic woman due to macro-aspartate aminotransferase: A case report
Zhan MR, Liu X, Zhang MY, Niu JQ
- 4420** Rehabilitation of anterior pituitary dysfunction combined with extrapontine myelinolysis: A case report
Yang MX, Chen XN

ABOUT COVER

Editorial Board Member of *World Journal of Clinical Cases*, Ashu Seith Bhalla, MD, Professor, Department of Radiodiagnosis, All India Institute of Medical Sciences, New Delhi 110029, India

AIMS AND SCOPE

The primary aim of *World Journal of Clinical Cases* (WJCC, *World J Clin Cases*) is to provide scholars and readers from various fields of clinical medicine with a platform to publish high-quality clinical research articles and communicate their research findings online.

WJCC mainly publishes articles reporting research results and findings obtained in the field of clinical medicine and covering a wide range of topics, including case control studies, retrospective cohort studies, retrospective studies, clinical trials studies, observational studies, prospective studies, randomized controlled trials, randomized clinical trials, systematic reviews, meta-analysis, and case reports.

INDEXING/ABSTRACTING

The WJCC is now indexed in PubMed, PubMed Central, Science Citation Index Expanded (also known as SciSearch®), and Journal Citation Reports/Science Edition. The 2019 Edition of Journal Citation Reports cites the 2018 impact factor for WJCC as 1.153 (5-year impact factor: N/A), ranking WJCC as 99 among 160 journals in Medicine, General and Internal (quartile in category Q3).

RESPONSIBLE EDITORS FOR THIS ISSUE

Responsible Electronic Editor: Ji-Hong Liu

Proofing Production Department Director: Yun-Xiaojuan Wu

NAME OF JOURNAL

World Journal of Clinical Cases

ISSN

ISSN 2307-8960 (online)

LAUNCH DATE

April 16, 2013

FREQUENCY

Semimonthly

EDITORS-IN-CHIEF

Dennis A Bloomfield, Bao-Gan Peng, Sandro Vento

EDITORIAL BOARD MEMBERS

<https://www.wjnet.com/2307-8960/editorialboard.htm>

EDITORIAL OFFICE

Jin-Lei Wang, Director

PUBLICATION DATE

December 26, 2019

COPYRIGHT

© 2019 Baishideng Publishing Group Inc

INSTRUCTIONS TO AUTHORS

<https://www.wjnet.com/bpg/gerinfo/204>

GUIDELINES FOR ETHICS DOCUMENTS

<https://www.wjnet.com/bpg/GerInfo/287>

GUIDELINES FOR NON-NATIVE SPEAKERS OF ENGLISH

<https://www.wjnet.com/bpg/gerinfo/240>

PUBLICATION MISCONDUCT

<https://www.wjnet.com/bpg/gerinfo/208>

ARTICLE PROCESSING CHARGE

<https://www.wjnet.com/bpg/gerinfo/242>

STEPS FOR SUBMITTING MANUSCRIPTS

<https://www.wjnet.com/bpg/GerInfo/239>

ONLINE SUBMISSION

<https://www.f6publishing.com>

Natural orifice specimen extraction with laparoscopic radical gastrectomy for distal gastric cancer: A case report

Peng Sun, Xi-Shan Wang, Qi Liu, Yu-Song Luan, Yan-Tao Tian

ORCID number: Peng Sun (0000-0002-0446-203X); Xi-Shan Wang (0000-0002-7337-9635); Qi Liu (0000-0001-6101-6549); Yu-Song Luan (0000-0002-5645-1332); Yan-Tao Tian (0000-0001-6479-7547).

Author contributions: Tian YT and Wang XS designed the report; Sun P, Liu Q, and Luan YS collected the patient's clinical data; Sun P analyzed the data and wrote the paper. Sun P and Wang XS contribute equally to this article.

Supported by National Natural Science Foundation of China, No. 81772642. Beijing science and technology plan, No.D171100002617004.

Informed consent statement:

Consent was obtained from relatives of the patient for publication of this report and any accompanying images.

Conflict-of-interest statement: The authors declare that there are no conflicts of interest.

CARE Checklist (2016) statement:

The authors have read the CARE Checklist (2016), and the manuscript was prepared and revised according to the CARE Checklist (2016).

Open-Access: This article is an open-access article which was selected by an in-house editor and fully peer-reviewed by external reviewers. It is distributed in accordance with the Creative Commons Attribution Non Commercial (CC BY-NC 4.0) license, which permits others to distribute, remix, adapt, build

Peng Sun, Xi-Shan Wang, Qi Liu, Yu-Song Luan, Department of Colorectal Surgery, National Cancer Center/Cancer Hospital, Chinese Academy of Medical Sciences and Peking Union Medical College, Beijing 100021, China

Peng Sun, Xi-Shan Wang, Department of General Surgery, The Second Affiliated Hospital of Harbin Medical University, Harbin 150081, Heilongjiang Province, China

Yan-Tao Tian, Department of Pancreatic and Gastric Surgery, National Cancer Center, National Clinical Research Center for Cancer, Cancer Hospital, Chinese Academy of Medical Sciences and Peking Union Medical College, Beijing 100021, China

Corresponding author: Yan-Tao Tian, MD, Professor, Department of Pancreatic and Gastric Surgery, National Cancer Center/Cancer Hospital, Chinese Academy of Medical Sciences and Peking Union Medical College, No. 17, Panjiayuan Nanli, Chaoyang District, Beijing 100021, China. tyt67@163.com

Telephone: +86-10-87787120

Fax: +86-10-87787120

Abstract

BACKGROUND

This article introduces the surgical method and early experience in performing totally laparoscopic radical gastrectomy with transrectal specimen extraction for gastric cancer, and we evaluate the short-term effects and feasibility of this new procedure for gastric cancer in a 64-year-old male patient. This approach may provide new possibilities for gastric natural orifice specimen extraction (NOSE) surgery. In addition, we believe that this new procedure may further relieve pain, speed up recovery, and cause minimal physiological and psychological impact.

CASE SUMMARY

We performed NOSE gastrectomy in a male patient. Tumor resection, digestive tract reconstruction, and lymph node dissection were performed totally laparoscopically; the specimen was extracted from the natural orifice of the rectum-anus. This procedure reduced damage to the abdominal wall and decreased postoperative pain. We successfully performed radical gastrectomy without conversion and complications. Total operative time and blood loss were 176 min and 50 mL, respectively. The patient resumed normal activities of daily living on day 1 without pain, and passed flatus within 48 h. Postoperative hospital stay was 10 d. The number of resected lymph nodes was 0/43. During the follow-up, no stricture or anastomotic leakage was detected. Three months postoperatively, colonoscopy showed full recovery of the rectum without stricture or scar contracture. Computed tomography and laboratory test results

upon this work non-commercially, and license their derivative works on different terms, provided the original work is properly cited and the use is non-commercial. See: <http://creativecommons.org/licenses/by-nc/4.0/>

Manuscript source: Unsolicited manuscript

Received: September 15, 2019

Peer-review started: September 15, 2019

First decision: October 14, 2019

Revised: November 11, 2019

Accepted: November 20, 2019

Article in press: November 20, 2019

Published online: December 26, 2019

P-Reviewer: Espinel J, Muguruma N

S-Editor: Dou Y

L-Editor: Wang TQ

E-Editor: Xing YX



showed no signs of tumor recurrence. There was no visible scar on the abdominal wall.

CONCLUSION

It is safe and reliable to perform totally laparoscopic radical gastrectomy with transrectal specimen extraction for distal gastric cancer patients.

Key words: Gastric cancer; Totally laparoscopic surgery; Transrectal; Natural orifice specimen extraction; Postoperative pain; No visible incision; Case report

©The Author(s) 2019. Published by Baishideng Publishing Group Inc. All rights reserved.

Core tip: We successfully performed transrectal specimen extraction gastrectomy in a male patient without conversion and complications. This procedure significantly reduced damage to the abdominal wall and decreased postoperative pain. There was no visible scar on the abdominal wall. Total operative time and blood loss were 176 min and 50 mL, respectively. The patient resumed normal activities on day 1 without pain, and passed flatus within 48 h. Postoperative hospital stay was 10 d. The number of resected lymph nodes was 0/43. During the follow-up, no complications were detected, and computed tomography and laboratory test results showed no signs of tumor recurrence.

Citation: Sun P, Wang XS, Liu Q, Luan YS, Tian YT. Natural orifice specimen extraction with laparoscopic radical gastrectomy for distal gastric cancer: A case report. *World J Clin Cases* 2019; 7(24): 4314-4320

URL: <https://www.wjnet.com/2307-8960/full/v7/i24/4314.htm>

DOI: <https://dx.doi.org/10.12998/wjcc.v7.i24.4314>

INTRODUCTION

Gastric cancer is a high-incidence tumor, and surgery is the common treatment^[1]. Scarring and pain were traditionally thought to be the inevitable outcome of stomach cancer surgery for the past century. However, with the development of technology and the concept of minimally invasive surgery, the natural orifice specimen extraction (NOSE) surgery concept has been widely recognized because it has good application in the field of colorectal cancer, and it could be gradually applied in the treatment of stomach, urological, and gynecological tumors^[2,3].

The use of transvaginal NOSE gastrectomy has been reported frequently^[4,5], but cases of transrectal specimen extraction are rare. Transrectal specimen extraction surgery is one kind of NOSE surgery that is completely performed laparoscopically, and the specimen is removed from the natural lumen without an extra abdominal incision. In this case, the specimen was removed from the anus through the anterior wall of the rectum. This approach is particularly suitable for gastric cancer patients with small tumors. Details of laparoscopic radical gastrectomy with transrectal specimen extraction in the male patient are described as follows.

CASE PRESENTATION

Chief complaints

A 64-year-old male patient was admitted to the hospital because of upper abdominal pain lasting for 1 year.

History of present illness

The patient had upper abdominal distension and discomfort for more than 1 year, accompanied by poor appetite. After eating, the patient felt upper abdominal fullness and painful discomfort, which could be relieved slightly by resting or taking acid-inhibiting drugs orally. The symptoms were slightly aggravated 3 mo ago, accompanied by weight loss.

History of past illness

The patient denied any history of hypertension, diabetes, and coronary heart disease;

hepatitis, tuberculosis, typhoid fever, malaria, and other infectious diseases; and major trauma, surgery, and drug or food allergies. Vaccination history is unknown. He had a history of smoking and drinking for more than 40 years.

Family history

No significant family history.

Physical examination upon admission

The patient's weight was 56 kg and his height was 170 cm, with a calculated body mass index of 19.3 kg/cm². His Karnofsky Performance Scale score was 100. No enlarged superficial lymph nodes were palpable. His abdomen was flat, and there was no gastrointestinal or peristaltic waves. There was mild tenderness in the upper abdomen, but there was no rebound pain. The shifting dullness was negative, and the frequency of borborygmus sounds was 4 times/min.

Laboratory examinations

Tumor marker levels [carcinoembryonic antigen, cancer antigen (CA)-199, and CA125] and routine laboratory blood test results were within normal ranges.

Imaging examinations

Computer tomography examination showed thickening of the gastric angle. Gastroscopic examination was performed, and an ulcer at the gastric horn was found. Then pathological biopsy findings confirmed that the ulcer was a gastric adenocarcinoma (clinical stage: cT1bN0M0).

FINAL DIAGNOSIS

Distal gastric adenocarcinoma.

TREATMENT

Laparoscopic radical gastrectomy for distal gastric cancer was performed, and the surgical procedures are described as follows.

Positioning and settlement of the trocars

After general anesthesia was induced, the patient was placed in the functional lithotomy position. After routine disinfection was performed, the V glyph 5-port method was used to set the trocars (Figure 1A). A 12-mm trocar was inserted into the abdomen through the subumbilical area as the observation port (Figure 1A-1), the surgeon's main operating port was located in the patient's hypochondriac region (Figure 1A-3), and the intersection of the left mid-clavicular line and umbilical horizontal line was the location of the auxiliary operating port (Figure 1A-2). The operating ports of the assistant were located in the midline of the right clavicle and the right hypochondriac region (Figure 1A-4 and 1A-5).

Surgical procedure

First, the abdominal cavity was inspected for tumor seeding or metastasis. No ascites was detected, no metastasis was observed on the liver surface, and no implant nodule was observed in the omentum, abdominal cavity, or pelvic cavity.

Then the gastric colon ligament was incised, and the anterior transverse mesenteric and pancreatic capsules were exfoliated. At the first portion of the duodenum, the right gastroepiploic vein was double-ligated with hemolock clips and divided. After resecting the sixth group of lymph nodes along the pylorus, the duodenal bulb was dissociated from the pancreatic head.

The nonvascular area of the lesser omentum was incised with an ultrasonic scalpel. Then the serosal layer of the hepatoduodenal ligament on the right side was sharply cut, and the twelfth group of lymph nodes was dissected. Next, the right gastric artery was ligated with hemolock clips and divided from the root, and the fifth group of lymph nodes was dissected.

The stomach was turned up. The truncus coeliacus, common hepatic artery, proper hepatic artery, and splenic artery were all isolated in the upper margin of the pancreas, respectively. The seventh, eighth, and ninth groups of lymph nodes were dissected, and the left gastric artery was ligated and divided from the root.

Subsequently, we opened the posterior leaf of the lesser omentum to the esophageal hiatus, the right ligament tissue of the cardia was divided with an ultrasonic scalpel, and the first group of lymph nodes was dissected. Along the

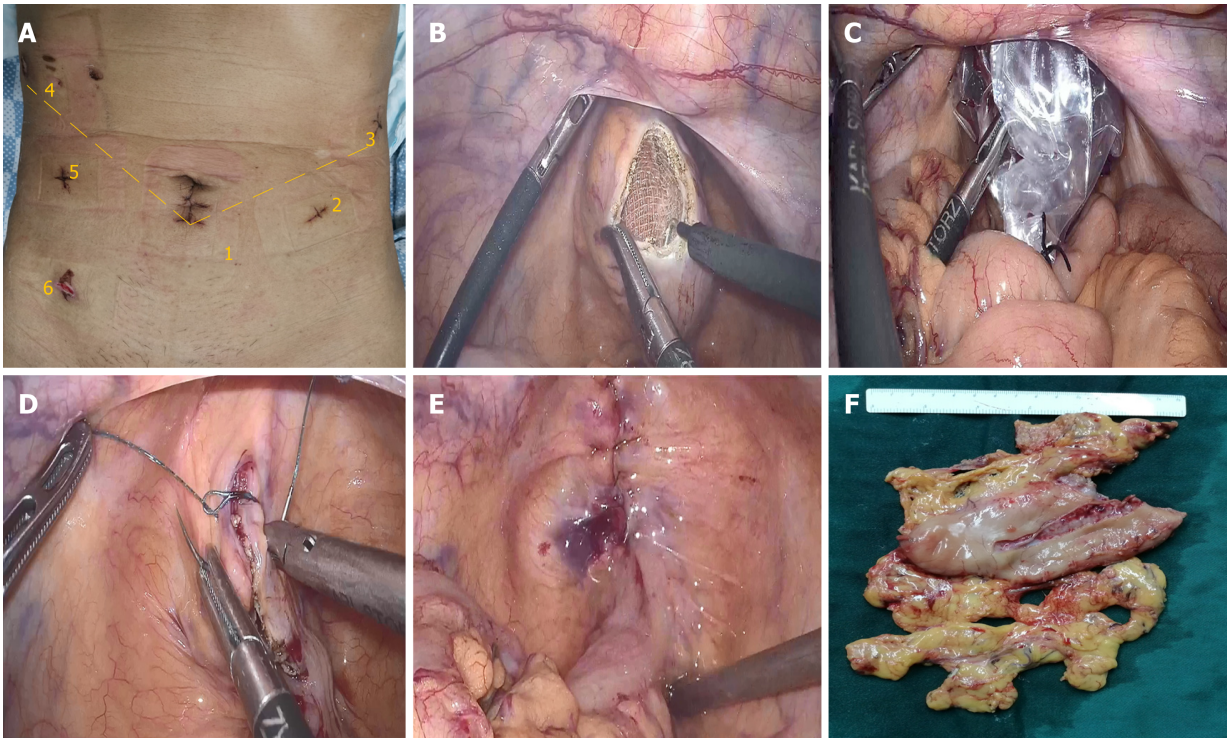


Figure 1 One more trocar was placed into the right lower abdomen to assist with specimen extraction. A: Position of the trocars; B: The anterior wall of the upper rectum was cut using electrocautery; C: The specimen bag was gently pulled out of the body; D: Barbed wire sutures were used to close the incision; E: The rectal incision was completely closed; F: The specimen of distal gastric cancer.

direction of the lesser gastric curvature to the pylorus, the adipose lymphoid tissue was divided with the ultrasonic scalpel, and the lymph nodes of the third group were dissected until the scheduled pre-cut point on the lesser gastric curvature.

The splenic colonic ligament was divided, and the left gastric omentum blood vessel was ligated with a hemolock clip. The duodenal bulb was cut and closed with a linear stapler. Then the distal stomach was cut at the gastric body. The specimen was completely removed. We transferred the specimen into a specimen bag and moved the bag to the pelvic cavity for extraction later.

Reconstruction

The ultrasonic scalpel was used to cut small 1-cm holes in the large curved side of the proximal stomach and duodenal stump, respectively. The two arms of the linear stapler were separately inserted into the holes, and anastomosis was performed on the posterior wall of the stomach and the posterior wall of the duodenum. We closed the joint opening with another stapler to complete the modified triangular anastomosis.

Specimen extraction

Another trocar was placed into the right lower abdomen to assist with specimen extraction (Figure 1). The anus was sufficiently dilated, the rectum was repeatedly rinsed with iodine water, and a roll of iodophor gauze was placed into the rectum to support the intestinal wall. Electrocautery was used to cut the anterior wall of the upper rectum by about 4 cm in length (Figure 1B). An oval clamp was inserted through the anus-rectum, and the specimen bag was grasped and slowly pulled out of the patient's body (Figure 1C). The rectal incision was repeatedly disinfected with iodophor gauze, and then barbed wire sutures were used for full-thickness closure of the incision (Figure 1D). The water injection and air inflation methods were used to check if the rectal incision was completely closed (Figure 1E). Trocar ports were then closed, and the operation was completed (Figure 1F).

OUTCOME AND FOLLOW-UP

The total operative time was 176 min, intraoperative bleeding was 50 mL, and the patient's vital signs were stable during the surgery. On the first day after the operation, the patient resumed normal activities of daily living (*e.g.*, ambulation and independent transfer from bed) without pain and passed flatus within 48 h. The

Numeric Rating Scale score^[6,7] was merely 3 on the first day after surgery and 1 on the third day. A liquid diet was restarted on the third day. The pelvic drainage tube was removed on the fourth day, subhepatic drainage was removed on the ninth day, and the patient was discharged on the tenth day.

The patient recovered well after surgery, with normal flatus, normal anal sensation, and no tumor recurrence. Colonoscopy was performed 3 mo later, and the colonoscope passed through the rectum smoothly. Only streaks of mucosal hyperemia and edema were observed; no stenosis or scar contracture was present in the intestinal cavity (Figure 2).

DISCUSSION

Gastric cancer is the third most common tumor, and its mortality rate remains high, which seriously threatens the health and lifetime of patients^[8]. With the popularity of screening evaluations such as gastroscopy and the continuous advancement of technology, the early diagnosis rate of gastric cancer has improved. Data show that early gastric cancer accounts for a large proportion of the total number of patients^[9]. Even in patients with early gastric cancer, traditional open surgery always require a longitudinal incision from the xiphoid to the periumbilical, which causes significant injury to the abdominal wall. Although open surgery may achieve the purpose of radical cure, patients often experience tremendous trauma and pain^[10].

In 1994, Kitano *et al*^[11] reported the first case of laparoscopic-assisted distal gastrectomy. Additionally, in 2002, Kanaya *et al*^[12] proposed complete intracorporeal gastroduodenostomy for distal gastric cancer by using triangular anastomosis technology, and created a new era of totally laparoscopic radical gastrectomy. Then Kanaya *et al*^[13] reviewed 100 patients with early gastric cancer and compared totally laparoscopic radical gastrectomy with open surgery. The clinical data showed that totally laparoscopic gastrectomy is conducive to early eating after surgery, and it promoted rapid recovery after surgery. Kim *et al*^[14] also compared totally laparoscopy distal gastrectomy with laparoscopy-assisted distal gastrectomy, and the short-term effects showed results similar to those of Dr. Kanaya. Although totally laparoscopic surgery has achieved better short-term results, a mini-laparotomy is still required to remove the specimen. The postoperative scar not only means that the integrity and aesthetics of the abdominal wall are destroyed, but it may also result in long-term dysfunction and activity-related pain, which may affect patients' normal work and life in severe cases.

Recently, NOSE surgery has been considered to represent the next revolution in surgery^[15], and it was developed as an extension of natural orifice transluminal endoscopic surgery. It was further improved based on totally laparoscopic techniques. In NOSE surgery, complete laparoscopic resections are performed through only five-12-mm trocar ports in the abdominal wall without any visible incisions or extensions. The key technology of NOSE surgery can be divided into two parts: Intracorporeal anastomosis and transluminal specimen extraction.

There are four potential natural orifices for specimen extraction: The mouth, urethra, rectum/anus, and vagina^[16]. It has been reported that surgical specimens of early gastric cancer can be removed transorally, but the specimens need to be segmented into pieces instead of whole, which disturbs the integrity of the tumor pathology^[17]. Considering the malleability of the natural passage and the size of specimen, the rectal and vaginal methods are adopted. Several studies^[18,19] have reported transvaginal specimen extraction in gastric cancer surgery, but transrectal surgery was barely mentioned. Especially for male patients, who lack the natural orifice of the vagina, the extraction lumen is very limited, and transrectal removal should be considered. The abdominal wall is innervated by somatic nerves and sensitive to painful stimuli; however, internal organs, such as the vagina and rectum, are not.

The operation described herein was performed by the cooperation of a gastric specialist team and colorectal specialist team. Before this operation, we have accumulated considerable experience in transrectal specimen extraction surgery. According to evaluation, our new procedure showed inspiring results compared with traditional laparoscopic surgery. In a previous randomized controlled trial of 1200 patients^[20], the mean surgical time of the conventional laparoscopic group was 217.3 min, mean number of retrieved lymph nodes was 36.1, mean length of the incision was 8.0 cm, mean time to ambulation was 50 h, mean time to first flatus was 3.5 d, mean time to first liquid intake was 5.5 d, and mean duration of the postoperative hospital stay was 10.8 d. Our data (176 min, 43, 1 cm, 12 h, 2 d, 3 d, and 10 d, respectively) are superior to data of the conventional laparoscopic group. In our patient, there was no additional abdominal extension, no increase in the operative

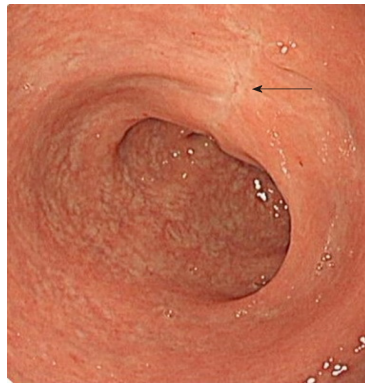


Figure 2 Colonoscopy showed no stenosis in the rectal cavity at 3 mo after surgery (arrow).

time, although there was a rectal incision, and no extra recovery time. During the operation, we demonstrated that the rectum-anus has the similar ductility as the vagina. The process of specimen extraction was smooth without any complications and lasted less than 3 min. The function of the rectum and anus was completely restored postoperatively without stenosis or dysfunction.

In previous studies, transrectal specimen extraction was more common in patients with rectal cancer and sigmoid colon cancer^[21,22]. Transrectal specimen extraction in gastric cancer is particularly suitable for male patients or female patients who have undergone vaginal surgery or have vaginal stenosis. We summarize the advantages are as follows: (1) NOSE surgery causes mild postoperative pain, improves surgical experience, and avoids excessive use of analgesic drugs; (2) It shortens the patient's postoperative activity and flatus time; (3) The procedure reduces the psychological burden on patients and increases the patient's postoperative confidence, which is conducive to better outcomes^[23,24]; (4) It has a good cosmetic result for the abdominal wall, which is important for specific occupations and particular patients (*e.g.*, actors, dancers, models, and unmarried people); and (5) Finally, the procedure causes less dysfunction of the abdominal wall, so patients' normal work and life are not affected. Improving the psychosocial state of patients is conducive to returning to normal social life.

This innovation in transrectal specimen extraction provides patients with early gastric cancer with a new NOSE approach, and it is stable and reliable. To make a more accurate evaluation about the outcomes of this new technique for early gastric cancer, a randomized comparison study and long-term follow-up are still necessary.

CONCLUSION

Transrectal specimen extraction with laparoscopic radical gastrectomy requires no additional abdominal incision, and therefore, results in less trauma, better cosmetic appearance, and quick postoperative recovery. It also conforms to the concept of minimal invasiveness and rapid recovery. This innovative technique provides a new approach to the treatment of gastric cancer by the laparoscopic NOSE method.

REFERENCES

- 1 **Van Cutsem E**, Sagaert X, Topal B, Haustermans K, Prenen H. Gastric cancer. *Lancet* 2016; **388**: 2654-2664 [PMID: 27156933 DOI: 10.1016/S0140-6736(16)30354-3]
- 2 **Hüscher CG**, Lirici MM, Ponzano C. NOSE laparoscopic gastrectomies for early gastric cancer may reduce morbidity and hospital stay: early results from a prospective nonrandomized study. *Minim Invasive Ther Allied Technol* 2017; **26**: 71-77 [PMID: 27802070 DOI: 10.1080/13645706.2016.1254094]
- 3 **Guan X**, Liu Z, Longo A, Cai JC, Tzu-Liang Chen W, Chen LC, Chun HK, Manuel da Costa Pereira J, Efetov S, Escalante R, He QS, Hu JH, Kayaalp C, Kim SH, Khan JS, Kuo LJ, Nishimura A, Nogueira F, Okuda J, Saklani A, Shafik AA, Shen MY, Son JT, Song JM, Sun DH, Uehara K, Wang GY, Wei Y, Xiong ZG, Yao HL, Yu G, Yu SJ, Zhou HT, Lee SH, Tsarkov PV, Fu CG, Wang XS, International Alliance of NOSES. International consensus on natural orifice specimen extraction surgery (NOSES) for colorectal cancer. *Gastroenterol Rep (Oxf)* 2019; **7**: 24-31 [PMID: 30792863 DOI: 10.1093/gastro/goy055]
- 4 **Zhang S**, Jiang ZW, Wang G, Feng XB, Liu J, Zhao J, Li JS. Robotic gastrectomy with transvaginal specimen extraction for female gastric cancer patients. *World J Gastroenterol* 2015; **21**: 13332-13338 [PMID: 26715817 DOI: 10.3748/wjg.v21.i47.13332]
- 5 **Kayaalp C**, Yagci MA. Laparoscopic Right Colon Resection With Transvaginal Extraction: A Systematic

- Review of 90 Cases. *Surg Laparosc Endosc Percutan Tech* 2015; **25**: 384-391 [PMID: [25730741](#) DOI: [10.1097/SLE.0000000000000124](#)]
- 6 **Hartrick CT**, Kovan JP, Shapiro S. The numeric rating scale for clinical pain measurement: a ratio measure? *Pain Pract* 2003; **3**: 310-316 [PMID: [17166126](#) DOI: [10.1111/j.1530-7085.2003.03034.x](#)]
 - 7 **Breivik EK**, Björnsson GA, Skovlund E. A comparison of pain rating scales by sampling from clinical trial data. *Clin J Pain* 2000; **16**: 22-28 [PMID: [10741815](#) DOI: [10.1097/00002508-200003000-00005](#)]
 - 8 **Deguli M**, De Manzoni G, Di Leo A, D'Ugo D, Galasso E, Marrelli D, Petrioli R, Polom K, Roviello F, Santullo F, Morino M. Gastric cancer: Current status of lymph node dissection. *World J Gastroenterol* 2016; **22**: 2875-2893 [PMID: [26973384](#) DOI: [10.3748/wjg.v22.i10.2875](#)]
 - 9 **Chen XZ**, Li YY, Hu JK, Yang K, Liu J, Zhang B, Chen ZX, Chen JP, Zhou ZG. Spread and development of laparoscopic surgery for gastric tumors in mainland China: initial experiences. *Hepatogastroenterology* 2012; **59**: 654-658 [PMID: [22328265](#) DOI: [10.5754/hgel1902](#)]
 - 10 **Son T**, Hyung WJ. Laparoscopic gastric cancer surgery: Current evidence and future perspectives. *World J Gastroenterol* 2016; **22**: 727-735 [PMID: [26811620](#) DOI: [10.3748/wjg.v22.i2.727](#)]
 - 11 **Kitano S**, Iso Y, Moriyama M, Sugimachi K. Laparoscopy-assisted Billroth I gastrectomy. *Surg Laparosc Endosc* 1994; **4**: 146-148 [PMID: [8180768](#) DOI: [10.1007/BF00590967](#)]
 - 12 **Kanaya S**, Gomi T, Momoi H, Tamaki N, Isobe H, Katayama T, Wada Y, Ohtoshi M. Delta-shaped anastomosis in totally laparoscopic Billroth I gastrectomy: new technique of intraabdominal gastroduodenostomy. *J Am Coll Surg* 2002; **195**: 284-287 [PMID: [12168979](#) DOI: [10.1016/s1072-7515\(02\)01239-5](#)]
 - 13 **Kanaya S**, Kawamura Y, Kawada H, Iwasaki H, Gomi T, Satoh S, Uyama I. The delta-shaped anastomosis in laparoscopic distal gastrectomy: analysis of the initial 100 consecutive procedures of intracorporeal gastroduodenostomy. *Gastric Cancer* 2011; **14**: 365-371 [PMID: [21573920](#) DOI: [10.1007/s10120-011-0054-0](#)]
 - 14 **Kim HH**, Han SU, Kim MC, Hyung WJ, Kim W, Lee HJ, Ryu SW, Cho GS, Song KY, Ryu SY. Long-term results of laparoscopic gastrectomy for gastric cancer: a large-scale case-control and case-matched Korean multicenter study. *J Clin Oncol* 2014; **32**: 627-633 [PMID: [24470012](#) DOI: [10.1200/JCO.2013.48.8551](#)]
 - 15 **Asakuma M**, Cahill RA, Lee SW, Nomura E, Tanigawa N. NOTES: The question for minimal resection and sentinel node in early gastric cancer. *World J Gastrointest Surg* 2010; **2**: 203-206 [PMID: [21160875](#) DOI: [10.4240/wjgs.v2.i6.203](#)]
 - 16 **Swain P**. Nephrectomy and natural orifice transluminal endoscopy (NOTES): transvaginal, transgastric, transrectal, and transvesical approaches. *J Endourol* 2008; **22**: 811-818 [PMID: [18419222](#) DOI: [10.1089/end.2007.9831](#)]
 - 17 **Dostalík J**, Gunkova P, Gunka I, Mazur M, Mrazek T. Laparoscopic gastric resection with natural orifice specimen extraction for postulcer pyloric stenosis. *Wideochir Inne Tech Maloinwazyjne* 2014; **9**: 282-285 [PMID: [25097701](#) DOI: [10.5114/wiitm.2014.41622](#)]
 - 18 **Sumer F**, Kayaalp C, Karagul S. Laparoscopic Gastrectomy and Transvaginal Specimen Extraction in a Morbidly Obese Patient with Gastric Cancer. *J Gastric Cancer* 2016; **16**: 51-53 [PMID: [27104027](#) DOI: [10.5230/jgc.2016.16.1.51](#)]
 - 19 **Jeong SH**, Lee YJ, Choi WJ, Paik WY, Jeong CY, Park ST, Choi SK, Hong SC, Jung EJ, Joo YT, Ha WS. Trans-vaginal specimen extraction following totally laparoscopic subtotal gastrectomy in early gastric cancer. *Gastric Cancer* 2011; **14**: 91-96 [PMID: [21264485](#) DOI: [10.1007/s10120-011-0006-8](#)]
 - 20 **Hu Y**, Huang C, Sun Y, Su X, Cao H, Hu J, Xue Y, Suo J, Tao K, He X, Wei H, Ying M, Hu W, Du X, Chen P, Liu H, Zheng C, Liu F, Yu J, Li Z, Zhao G, Chen X, Wang K, Li P, Xing J, Li G. Morbidity and Mortality of Laparoscopic Versus Open D2 Distal Gastrectomy for Advanced Gastric Cancer: A Randomized Controlled Trial. *J Clin Oncol* 2016; **34**: 1350-1357 [PMID: [26903580](#) DOI: [10.1200/JCO.2015.63.7215](#)]
 - 21 **Liu Z**, Efetov S, Guan X, Zhou H, Tulina I, Wang G, Tsarkov P, Wang X; International Alliance of Natural Orifice Specimen Extraction Surgery (IANOSSES). A Multicenter Study Evaluating Natural Orifice Specimen Extraction Surgery for Rectal Cancer. *J Surg Res* 2019; **243**: 236-241 [PMID: [31229790](#) DOI: [10.1016/j.jss.2019.05.034](#)]
 - 22 **Efetov SK**, Tulina IA, Kim VD, Kitsenko Y, Picciariello A, Tsarkov PV. Natural orifice specimen extraction (NOSE) surgery with rectal eversion and total extra-abdominal resection. *Tech Coloproctol* 2019; **23**: 899-902 [PMID: [31482393](#) DOI: [10.1007/s10151-019-02058-y](#)]
 - 23 **Russ TC**, Stamatakis E, Hamer M, Starr JM, Kivimäki M, Batty GD. Association between psychological distress and mortality: individual participant pooled analysis of 10 prospective cohort studies. *BMJ* 2012; **345**: e4933 [PMID: [22849956](#) DOI: [10.1136/bmj.e4933](#)]
 - 24 **Batty GD**, Russ TC, Stamatakis E, Kivimäki M. Psychological distress in relation to site specific cancer mortality: pooling of unpublished data from 16 prospective cohort studies. *BMJ* 2017; **356**: j108 [PMID: [28122812](#) DOI: [10.1136/bmj.j108](#)]



Published By Baishideng Publishing Group Inc
7041 Koll Center Parkway, Suite 160, Pleasanton, CA 94566, USA
Telephone: +1-925-2238242
E-mail: bpgoffice@wjgnet.com
Help Desk: <https://www.f6publishing.com/helpdesk>
<https://www.wjgnet.com>

