


World Journal of *Clinical Cases*

World J Clin Cases 2019 February 26; 7(4): 405-547



**MINIREVIEWS**

- 405** Immune checkpoint inhibitor-induced colitis: A comprehensive review
Som A, Mandaliya R, Alsaadi D, Farshidpour M, Charabaty A, Malhotra N, Mattar MC

ORIGINAL ARTICLE**Basic Study**

- 419** Formalin fixation on HER-2 and PD-L1 expression in gastric cancer: A pilot analysis using the same surgical specimens with different fixation times
Kai K, Yoda Y, Kawaguchi A, Minesaki A, Iwasaki H, Aishima S, Noshiro H

Case Control Study

- 431** Nested case-control study of multiple serological indexes and Brighton pediatric early warning score in predicting death of children with sepsis
Xie X, Li M, Xiong TT, Wang R, Xiao L

Retrospective Study

- 441** Intestinal endometriosis: Diagnostic ambiguities and surgical outcomes
Bong JW, Yu CS, Lee JL, Kim CW, Yoon YS, Park IJ, Lim SB, Kim JC

Randomized Controlled Trial

- 452** Efficacy of 1.2 L polyethylene glycol plus ascorbic acid for bowel preparations
Tamaki H, Noda T, Morita M, Omura A, Kubo A, Ogawa C, Matsunaka T, Shibato M

CASE REPORT

- 466** Congenital analbuminemia in a patient affected by hypercholesterolemia: A case report
Suppressa P, Carbonara C, Lugani F, Campagnoli M, Troiano T, Minchiotti L, Sabbà C
- 473** Primary leiomyosarcoma of the thyroid gland with prior malignancy and radiotherapy: A case report and review of literature
Vujosevic S, Krnjevic D, Bogojevic M, Vuckovic L, Filipovic A, Dunđerović D, Sopta J
- 482** Endoscopic resection for residual lesion of metastatic gastric cancer: A case report
Hayashi K, Suzuki S, Ikehara H, Okuno H, Irie A, Esaki M, Kusano C, Gotoda T, Moriyama M
- 489** Peritoneal cavernous hemangiomatosis: A case report
Fu LY, Chen HY, Diao XL, Wang ZJ
- 494** Recurrent acute liver failure associated with novel SCYL1 mutation: A case report
Li JQ, Gong JY, Knisely AS, Zhang MH, Wang JS

- 500** Therapeutic plasma exchange and continuous renal replacement therapy for severe hyperthyroidism and multi-organ failure: A case report
Ba JH, Wu BQ, Wang YH, Shi YF
- 508** Hydrochloric acid enhanced radiofrequency ablation for treatment of large hepatocellular carcinoma in the caudate lobe: Report of three cases
Deng HX, Huang JH, Lau WY, Ai F, Chen MS, Huang ZM, Zhang TQ, Zuo MX
- 516** Long-term follow-up of a patient with venlafaxine-induced diurnal bruxism treated with an occlusal splint: A case report
Chen JM, Yan Y
- 525** Primary hepatic leiomyosarcoma successfully treated by transcatheter arterial chemoembolization: A case report
Zhu KL, Cai XJ
- 532** Anterior cervical corpectomy decompression and fusion for cervical kyphosis in a girl with Ehlers-Danlos syndrome: A case report
Fang H, Liu PF, Ge C, Zhang WZ, Shang XF, Shen CL, He R
- 538** Rhombencephalitis caused by *Listeria monocytogenes* with hydrocephalus and intracranial hemorrhage: A case report and review of the literature
Liang JJ, He XY, Ye H

ABOUT COVER

Editorial Board Member of *World Journal of Clinical Cases*, Xi Jin, PhD, Associate Professor, Doctor, Department of Gastroenterology, Institution of Gastroenterology, the First Affiliated Hospital, School of Medicine Zhejiang University, Zhejiang Province, Hangzhou 310003, China

AIMS AND SCOPE

World Journal of Clinical Cases (*World J Clin Cases*, *WJCC*, online ISSN 2307-8960, DOI: 10.12998) is a peer-reviewed open access academic journal that aims to guide clinical practice and improve diagnostic and therapeutic skills of clinicians.

The primary task of *WJCC* is to rapidly publish high-quality Case Report, Clinical Management, Editorial, Field of Vision, Frontier, Medical Ethics, Original Articles, Meta-Analysis, Minireviews, and Review, in the fields of allergy, anesthesiology, cardiac medicine, clinical genetics, clinical neurology, critical care, dentistry, dermatology, emergency medicine, endocrinology, family medicine, gastroenterology and hepatology, *etc.*

INDEXING/ABSTRACTING

The *WJCC* is now indexed in PubMed, PubMed Central, Science Citation Index Expanded (also known as SciSearch®), and Journal Citation Reports/Science Edition. The 2018 Edition of Journal Citation Reports cites the 2017 impact factor for *WJCC* as 1.931 (5-year impact factor: N/A), ranking *WJCC* as 60 among 154 journals in Medicine, General and Internal (quartile in category Q2).

RESPONSIBLE EDITORS FOR THIS ISSUE

Responsible Electronic Editor: *Wen-Wen Tan*

Proofing Editorial Office Director: *Jin-Lai Wang*

NAME OF JOURNAL

World Journal of Clinical Cases

ISSN

ISSN 2307-8960 (online)

LAUNCH DATE

April 16, 2013

FREQUENCY

Semimonthly

EDITORS-IN-CHIEF

Dennis A Bloomfield, Sandro Vento

EDITORIAL BOARD MEMBERS

<https://www.wjgnet.com/2307-8960/editorialboard.htm>

EDITORIAL OFFICE

Jin-Lai Wang, Director

PUBLICATION DATE

February 26, 2019

COPYRIGHT

© 2019 Baishideng Publishing Group Inc

INSTRUCTIONS TO AUTHORS

<https://www.wjgnet.com/bpg/gerinfo/204>

GUIDELINES FOR ETHICS DOCUMENTS

<https://www.wjgnet.com/bpg/GerInfo/287>

GUIDELINES FOR NON-NATIVE SPEAKERS OF ENGLISH

<https://www.wjgnet.com/bpg/gerinfo/240>

PUBLICATION MISCONDUCT

<https://www.wjgnet.com/bpg/gerinfo/208>

ARTICLE PROCESSING CHARGE

<https://www.wjgnet.com/bpg/gerinfo/242>

STEPS FOR SUBMITTING MANUSCRIPTS

<https://www.wjgnet.com/bpg/GerInfo/239>

ONLINE SUBMISSION

<https://www.f6publishing.com>

Hydrochloric acid enhanced radiofrequency ablation for treatment of large hepatocellular carcinoma in the caudate lobe: Report of three cases

Han-Xia Deng, Jin-Hua Huang, Wan Yee Lau, Fei Ai, Min-Shan Chen, Zhi-Mei Huang, Tian-Qi Zhang, Meng-Xuan Zuo

ORCID number: Han-Xia Deng (0000-0002-1250-3444); Jin-Hua Huang (0000-0003-2960-6148); Wan Yee Lau (0000-0002-9802-6537); Fei Ai (0000-0003-2336-6315); Min-Shan Chen (0000-0002-7442-4637); Zhi-Mei Huang (0000-0002-4136-5896); Tian-Qi Zhang (0000-0002-1528-5323); Meng-Xuan Zuo (0000-0003-3589-7316).

Author contributions: Huang JH made the study concept and designed the study; Huang JH, Deng HX, and Ai F drafted the manuscript; Lau WY, Chen MS, and Fan YF made critical revision of the manuscript for important intellectual content; Huang ZM and Zhang TQ provided the technical support.

Supported by the National Natural Science Foundation of China, No. 81771955.

Informed consent statement: Written informed consent was obtained from the patients.

Conflict-of-interest statement: The authors declare no conflict of interest.

CARE Checklist (2016) statement: The authors have read the CARE Checklist (2016), and the manuscript was prepared and revised according to the CARE Checklist (2016).

Open-Access: This article is an open-access article which was selected by an in-house editor and

Han-Xia Deng, Jin-Hua Huang, Fei Ai, Zhi-Mei Huang, Tian-Qi Zhang, Meng-Xuan Zuo, Department of Minimally Invasive Interventional Therapy, Cancer Centre of Sun Yat-sen University, Guangzhou 510060, Guangdong Province, China

Han-Xia Deng, Jin-Hua Huang, Fei Ai, Min-Shan Chen, Zhi-Mei Huang, Tian-Qi Zhang, Meng-Xuan Zuo, State Key Laboratory of Oncology in Southern China, Guangzhou 510060, Guangdong Province, China

Wan Yee Lau, Min-Shan Chen, Department of Hepatobiliary Surgery, Cancer Centre of Sun Yat-sen University, Guangzhou 510060, Guangdong Province, China

Wan Yee Lau, Faculty of Medicine, The Chinese University of Hong Kong, Prince of Wales Hospital, Shatin, New Territories, Hong Kong, China

Corresponding author: Jin-Hua Huang, MD, Professor, Department of Minimally Invasive Interventional Radiology, Sun Yat-sen University Cancer Center, State Key Laboratory of Oncology in South China, Collaborative Innovation Center for Cancer Medicine, 651 Dongfeng Road East, Guangzhou 510000, Guangdong Province, China.

huangjh@sysucc.org.cn

Telephone: +86-020-87343447

Abstract

BACKGROUND

To report on the use of percutaneous hydrochloric acid (HCl) enhanced radiofrequency ablation (HRFA) for the treatment of large (maximum diameter ≥ 5 cm) hepatocellular carcinoma (HCC) in the caudate lobe.

CASE SUMMARY

Between August 2013 and June 2016, three patients with a large HCC (maximum diameter: 5.0, 5.7, and 8.1 cm) in the caudate lobe were treated by transarterial chemoembolization followed by computer tomography (CT) guided RFA using a monopolar perfusion RF electrode, which was enhanced by local infusion of 10% HCl at 0.2 mL/min (total volume, 3 to 12 mL). The output power of HRFA reached 100 W, and the average ablation time was 39 min (range, 15 to 60 min). Two patients each underwent one session of HRFA and one patient two sessions. After treatment, CT/magnetic resonance imaging showed that all the three lesions were completely ablated. There was no major complication. Two patients had asymptomatic bile duct dilatation. One patient died of tongue cancer 24 mo

fully peer-reviewed by external reviewers. It is distributed in accordance with the Creative Commons Attribution Non Commercial (CC BY-NC 4.0) license, which permits others to distribute, remix, adapt, build upon this work non-commercially, and license their derivative works on different terms, provided the original work is properly cited and the use is non-commercial. See: <http://creativecommons.org/licenses/by-nc/4.0/>

<http://creativecommons.org/licenses/by-nc/4.0/>

Manuscript source: Unsolicited manuscript

Received: November 7, 2018

Peer-review started: November 12, 2018

First decision: November 27, 2018

Revised: December 23, 2018

Accepted: January 3, 2019

Article in press: January 3, 2019

Published online: February 26, 2019

after ablation. The remaining two patients were alive and no area of enhancement is detected in the caudate lobe at 28 and 60 mo after ablation, respectively.

CONCLUSION

Percutaneous CT-guided HRFA is safe and efficacious in treating large HCC in the caudate lobe.

Key words: Hydrochloric acid; Radiofrequency ablation; Hydrochloric acid enhanced radiofrequency ablation; Caudate lobe; Large hepatocellular carcinoma; Case report

©The Author(s) 2019. Published by Baishideng Publishing Group Inc. All rights reserved.

Core tip: Caudate lobe hepatocellular carcinoma (HCC) was considered highly technically difficult by surgeons and the outcome of interventional therapies, including transarterial chemoembolization and conventional radiofrequency ablation (RFA), according to previous studies was unsatisfied. Hydrochloric acid enhanced RFA, an innovative technique, can create an ablation zone larger than 5 cm by a single perfusate electrode without major complications, which is promising to treat large caudate lobe HCC patient.

Citation: Deng HX, Huang JH, Lau WY, Ai F, Chen MS, Huang ZM, Zhang TQ, Zuo MX. Hydrochloric acid enhanced radiofrequency ablation for treatment of large hepatocellular carcinoma in the caudate lobe: Report of three cases. *World J Clin Cases* 2019; 7(4): 508-515
URL: <https://www.wjgnet.com/2307-8960/full/v7/i4/508.htm>
DOI: <https://dx.doi.org/10.12998/wjcc.v7.i4.508>

INTRODUCTION

Hepatocellular carcinoma (HCC) arising from the caudate lobe is rare^[1]. The caudate lobe is situated deep between the hepatic hilum and the inferior vena cava. Caudate lobectomy is considered to be technically difficult even for small tumors, with high risks of local recurrence and poor overall survival^[2,3]. For large tumors in the caudate lobe, resection is challenging even in the hands of experienced liver surgeons^[4,5]. Interventional therapies, including various intravascular and extravascular procedures, have been reported to treat caudate lobe HCC^[6-14]. However, most of those focused on treating small HCC (maximum diameter < 5 cm). This is a retrospective study on three patients with HCC ≥ 5 cm in the caudate lobe treated by hydrochloric acid (HCl) enhanced radiofrequency ablation (HRFA).

CASE PRESENTATION

Case 1

A 61-year-old woman was found to have a caudate lobe lesion (55 mm × 57 mm × 63 mm) on magnetic resonance imaging (MRI). The patient had a history of chronic hepatic B virus (HBV) infection, with Child-Pugh A liver function and a negative serum alpha-fetoprotein (AFP) concentration (0.71 ng/mL). A biopsy confirmed HCC. Transarterial chemoembolization (TACE) using an emulsion of tetrahydropalmatine (THP) 50 mg, lobaplatin 50 mg, and lipiodol 10 mL was performed in August 2013. One month later, computed tomography (CT) showed that the tumor had enlarged (72 mm × 75 mm × 81 mm), and was separated into the superior and inferior parts by a fibrous septum.

Since the tumor enlarged after TACE, the patient was suggested to undergo ablation therapy. Conventional RFA was insufficient to ablate such a huge tumor. Thus, the patient received two sessions of HRFA in September and December 2013, respectively, to ablate the superior and inferior parts of the tumor. HRFA was applied for 60 min in the first and 30 min in the second session. No discomfort during ablation and no complications such as fever, pain, or hemorrhage after HRFA were observed.

One month after the first HRFA, a peripheral hyper-metabolic nodule was detected by PET-CT. Thus, the patient underwent two more sessions of COOL-TIP RFA in December 2013 and March 2014, respectively. After that, the hypermetabolic lesion

was no longer visible. The last follow-up CT in July 2018 showed that the tumor had decreased to an inactive fibrous tissue mass of about 2 cm in diameter. During the course of treatment and follow-up, there were no major complications. A minor complication was asymptomatic slight dilation (total bilirubin concentration once elevated to 72 $\mu\text{mol/L}$ 18 mo after HRFA and returned normal without any treatment) of bile ducts (Figure 1).

Case 2

A 69-year-old man was found on health checkup to have a caudate lobe tumor, 17 mm \times 25 mm on PET-CT in June 2013. He had a history of chronic HBV infection. The AFP concentration was negative, and he had Child-Pugh A liver function. A biopsy confirmed the diagnosis of HCC. The patient received two sessions of TACE in August and November 2013, respectively. CT performed in March 2014 showed that the lesion had enlarged to 47 mm \times 57 mm, with poor lipiodol deposition. Besides, the patient had a history of tongue cancer and received radiotherapy 4 years ago.

In March 2014, HRFA through an anterior approach was applied for 60 min. There was no acute adverse effect occurring in the peri-ablation and post-ablation periods, and an MRI scan one month later showed no areas of enhancement.

Ten months after HRFA, in January 2015, MRI showed the margin of the lesion to be suspiciously enhanced by contrast. He underwent one session of COOL-TIP RFA. No visible active lesion was detected in the next MRI scan. The last MRI scan in December 2015 found no active lesion in the liver. Twenty-four months after HRFA, the patient died of recurrent tongue cancer (Figure 2).

Case 3

A 73-year-old man presented with chest and abdomen pain in February 2016. CT showed a mass in the pancreatic neck and a low density lesion, 35 \times 50 mm, in the caudate lobe. The patient had a history of chronic HBV infection, Child-Pugh A disease, and a negative serum AFP concentration. The PIVKA level was 20.266 AU/m. An exploratory laparotomy showed a primary tumor in the caudate lobe and that the lesion in pancreatic neck was a spontaneous hematoma. Frozen section analysis of an enlarged portal lymph node showed metastatic HCC. TACE was performed in April 2016, with an emulsion of THP 30 mg, lobaplatin 30 mg, and lipiodol 10 mL. CT after TACE showed good lipiodol deposition.

Three days later, HRFA was applied for 15 min through an anterior approach. No major complications occurred. One month later, the PIVKA concentration dropped to 2.566 AU/mL and no visible contrast enhanced areas on MRI. Follow-up at 28 mo after HRFA showed no signs of relapse or metastasis. (Figure 3)

The summary of the three patients is shown in Table 1.

DISCUSSION

Surgical resection of a caudate lobe tumor is technically challenging as the caudate lobe is situated deep between the hepatic hilum and the inferior vena cava^[1]. In a report on 12 patients, the median operative time was 568 min, the median intraoperative blood loss was 550 mL, and five patients developed postoperative bile leak with problems in renal function^[4]. Caudate lobectomy is commonly combined with major or extended hepatectomy with sacrifice of a large amount of non-tumorous liver parenchyma which increases the risk of postoperative liver failure.

Compared to surgery, interventional therapies such as TACE or RFA have a lower risk of treatment morbidities. In 1986, Takayasu *et al*^[6] reported five patients who underwent transcatheter arterial infusion (TAI) or transcatheter arterial embolization (TAE) for treating advanced-stage caudate lobe HCC. Unfortunately, four of these patients died during a mean of 5.5 mo. With advances in interventional technology and a better understanding of arterial blood supply of caudate lobe HCC^[8,15,16], the success rate of selective subsegmental TACE in treating caudate lobe HCC has been greatly improved. However, long-term survival after treatment remains a problem. Kim *et al*^[9] performed selective TACE to treat 34 patients with caudate lobe HCC with a diameter of less than 3 cm. The 5-year overall survival and progression-free rates were 72% and 21%, respectively. TACE cannot completely block the feeding arteries and gain a complete tumor necrosis, which causes recurrence^[10]. For a large caudate lobe HCC, the results of TACE are even worse.

Percutaneous ablation therapies, including percutaneous ethanol injection (PEI), RFA, and MWA, are well-established and widely used treatments for HCC. In 2002, Shibata *et al*^[11] first introduced PEI with or without TAE to treat 25 patients with caudate lobe HCC (average diameter, 27 mm). Peng *et al*^[13] reported on 17 patients who underwent RFA treatment for caudate lobe HCC (average diameter, 31 mm).

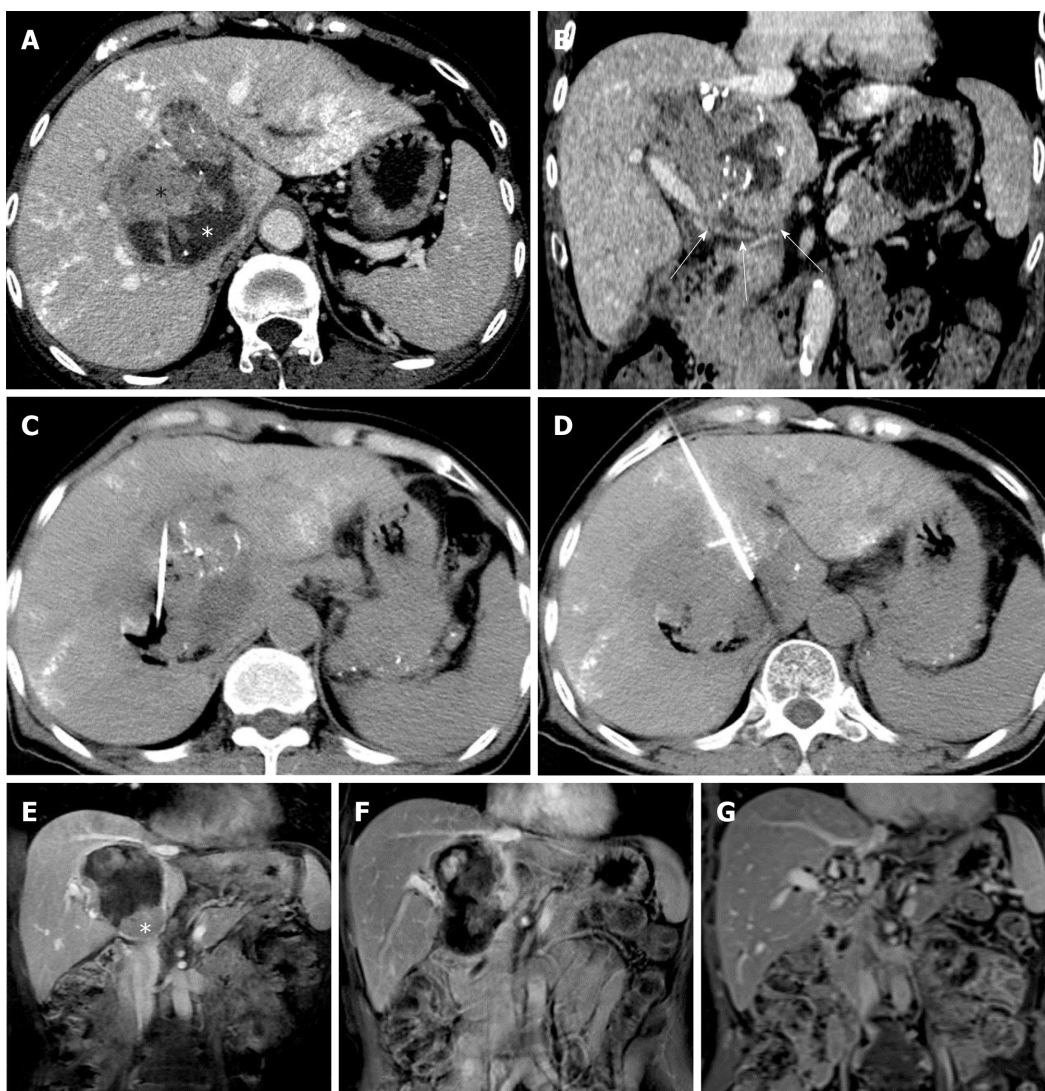


Figure 1 Arterial-phase computed tomography images showing a large caudate lobe tumor enhanced after transarterial chemoembolization in a 61-year-old woman with confirmed hepatocellular carcinoma. A: The tumor with poor lipiodol deposition was predominantly composed by isodense tissue (black asterisk), representing the contrast enhanced active part of the tumor and the hypodense necrotic region without enhancement (white asterisk). The hyperdensity in the hepatic parenchyma represents lipiodol deposition after TACE; B: The caudate lobe and porta hepatis were involved (white arrows); C and D: Computed tomography images taken during the ablation show precise placement of the RF electrode into the active regions of the tumor, and the area of destruction can be seen easily; E: The coronal magnetic resonance image (MRI) shows an enhanced inferior residual tumor after the first session of HRFA (white asterisk); F: No active tissue was detected after the second session of HRFA; G: The latest coronal post-contrast T1-weighted image shows focal atrophy and fibrosis formation, resulting in an irregular, non-active region in the caudate lobe about 20 mm in diameter. The bile ducts were slightly dilated on the latest follow-up MRI.

However, most of these studies focused on treating small caudate lobe tumors. Nevertheless, incomplete ablation and recurrence still happened. Nishigaki *et al*^[14] compared the recurrence rates in patients with caudate lobe HCC or HCC located in other liver segments. They found that the caudate lobe patients had a higher risk of developing tumor recurrence. Caudate lobe HCCs are more difficult to be completely ablated than those in other liver segments due to the restricted approach through which an RFA electrode can be introduced, and the heat sink effect of the inferior vena cava.

In the last decade, several new techniques, such as normal saline perfused radiofrequency ablation (NSRFA) and multi-electrode applications had been developed, aiming to create a large ablative zone^[17]. Our previous experiments showed that infusing diluted HCl instead of normal saline during RFA could enlarge the diameter of ablation zone from a mean (SD) of 3.52 cm (0.07) to 6.85 cm (0.32) at 30 W-30 min^[18]. This is because the conductivity of HCl is about three times higher than that of saline, greatly increasing the conductivity around the RF electrode^[19]. In *in vivo* experiments, HRFA also exhibited a larger ablative zone with favorable safety^[21-22]. Based on these studies, we have reported performing HRFA on a patient with spontaneously ruptured HCC, which successfully controlled bleeding and achieved complete necrosis after ablation without any complications^[19]. In a word, HRFA, a

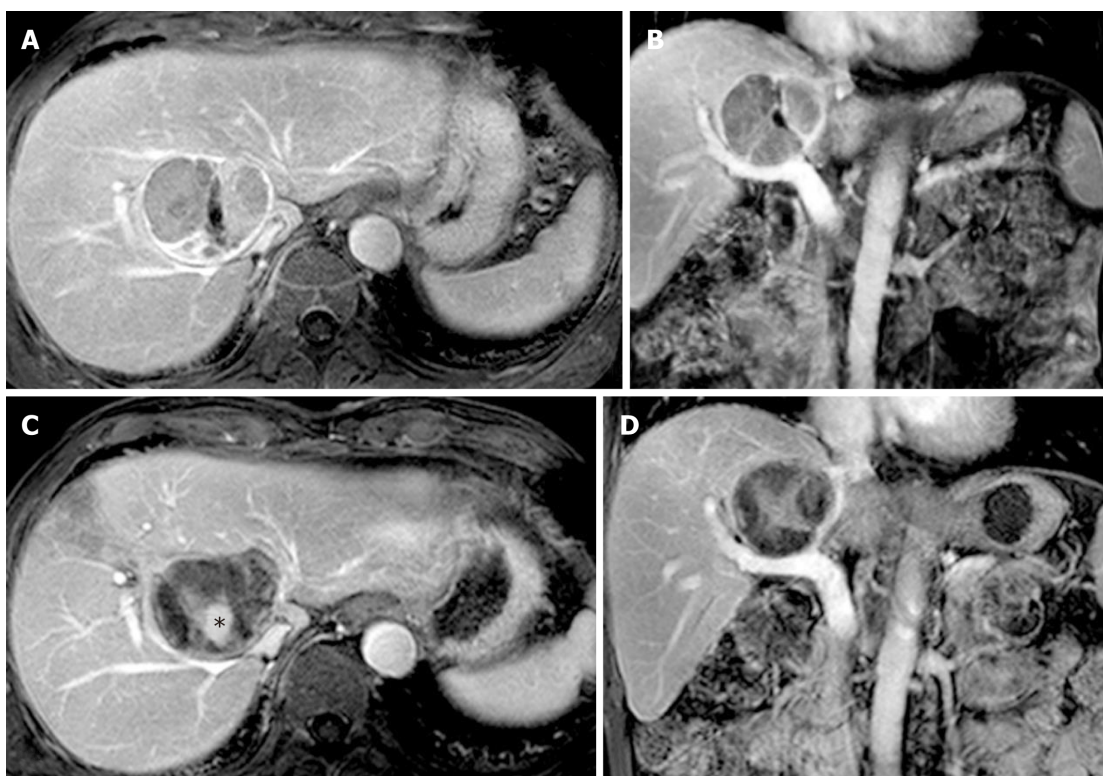


Figure 2 A well-defined active caudate lobe tumor adjacent to the right hepatic vein in a 69-year-old man with a history of tongue cancer after two sessions of TACE. A and B: The enhanced part was predominant and had poor lipiodol deposition consistent with active tumor tissues; C and D: Post-contrast magnetic resonance imaging (MRI) images after HRFA therapy show a non-enhanced mass with hypointensity. The central irregular hyperintensity (black asterisk, C) was caused by the hemorrhagic content of the necrotic cavity, rather than by contrast enhancement. Relapse was not detected in the most recent MRI examination (data not shown).

technique that can create a large ablation volume by using a monopolar electrode, is promising in treating large caudate lobe HCCs. In the present study, all three patients had unresectable large caudate lobe HCC. One patient underwent two sessions of HRFA and the other two patients underwent one session each. After HRFA and followed complementary COOL-TIP RFA, all the three caudate lobe tumors showed complete necrosis.

Among four sessions of HRFA, three were performed through an anterior approach and the remaining one was through a lateral approach (case 1, the 2nd session) in order to protect peripheral vessels and the biliary system. HRFA also avoids repeated punctures because one session of HRFA is sufficient to achieve complete necrosis. Besides, the electrode in HRFA could be placed at the center of the lesion whereas in other RFA techniques, it must reach the tumor margin, which would induce damage to the structure nearby. There was no major complication and asymptomatic bile duct dilatation as a minor complication occurred in patient 1 18 mo after HRFA. It was hypothesized that the non-active lesion, which had shrunk from 7 cm to less than 3 cm, stretched its peripheral liver tissue and induced bile duct dilatation.

CONCLUSION

HRFA can be an efficacious and safe choice for patients with a large caudate lobe HCC. However, further research is necessary to determine the appropriate role of HRFA in treating caudate lobe HCCs. Combination of HRFA with TACE or other systemic therapies is expected to further improve the prognosis of patients.

Table 1 The summary of all three patients

	Case 1	Case 2	Case 3
Sex	Female	Male	Male
Age	61	69	73
Tumor size	75 × 81	47 × 57	35 × 50
Session(s) of HRFA	2	1	1
Complementary RFA	Yes	Yes	None
Survival (mo)	60	48	28
Complications	Asymptomatic bile duct dilatation	None	None
Alive	Alive	Died of tongue cancer recurrence	Alive

HRFA: Hydrochloric acid enhanced radiofrequency ablation.

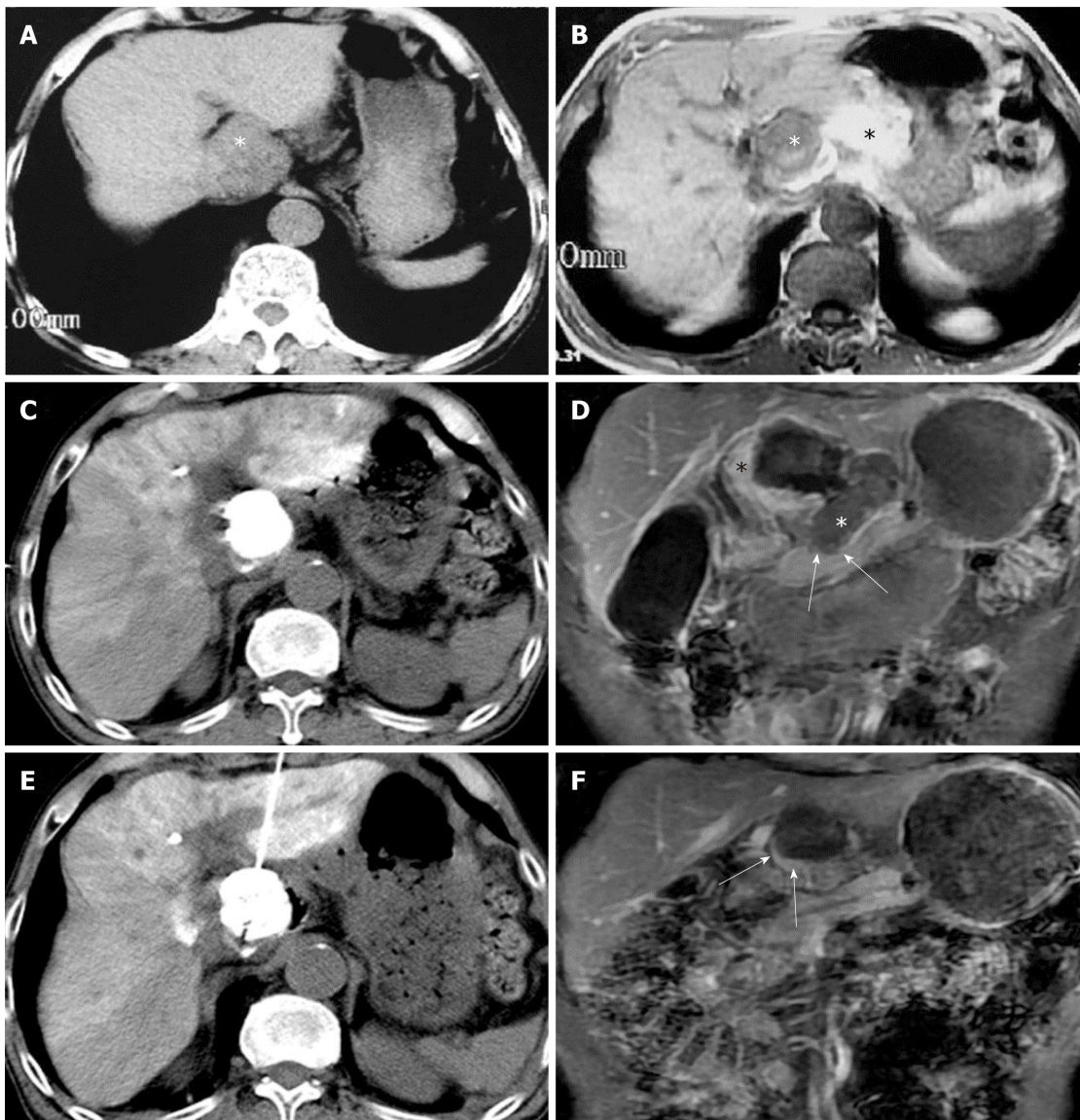


Figure 3 Preoperative computed tomography and magnetic resonance imaging images of a 73-year-old male showing a large intrahepatic tumor in the caudate lobe. A and B: A large intrahepatic tumor in the caudate lobe was confirmed as hepatocellular carcinoma by histopathology. A hyperintense mass was noted in the pancreatic neck region on T1-weighted imaging (black asterisk, B). This was shown to be a hematoma on subsequent exploratory laparotomy; C: CT images showing that lipiodol deposition involved almost the entire area of the lesion in the caudate lobe after TACE; D: Peripheral residual tumor medial to the necrotic cavity was demonstrated in a coronal post-contrast T1-weighted image (black asterisk). The non-enhancing soft tissue in the porta hepatis region inferior to the intrahepatic lesion and adjacent to the neck of pancreas (white arrows) is consistent with the shrunken hematoma after exploratory laparotomy (white asterisk). E: CT image showing the needle in the tumor during HRFA; F: A thin enhancing rim-like tissue inferior to the necrotic cavity (white arrows) is evident on the post-contrast T1-weighted image after HRFA therapy. The necrotic region does not show enhancement. No relapse was detected during follow-up MRI examinations. This enhancing

rim probably represents reactive granulation tissues, rather than residual tumor.

REFERENCES

- 1 **Kumon M.** Anatomy of the caudate lobe with special reference to portal vein and bile duct. *Acta Hepatol Jpn* 1985; **26**: 1193-1199 [DOI: [10.2957/kanzo.26.1193](https://doi.org/10.2957/kanzo.26.1193)]
- 2 **Tanaka S, Shimada M, Shirabe K, Maehara S, Tsujita E, Taketomi A, Maehara Y.** Surgical outcome of patients with hepatocellular carcinoma originating in the caudate lobe. *Am J Surg* 2005; **190**: 451-455 [PMID: [16105535](https://pubmed.ncbi.nlm.nih.gov/16105535/) DOI: [10.1016/j.amjsurg.2004.12.005](https://doi.org/10.1016/j.amjsurg.2004.12.005)]
- 3 **Kumon M.** Anatomical Study of the Caudate Lobe with Special Reference to Portal Venous and Biliary Branches Using Corrosion Liver Casts and Clinical Application. *Liver Cancer* 2017; **6**: 161-170 [PMID: [28275582](https://pubmed.ncbi.nlm.nih.gov/28275582/) DOI: [10.1159/000454682](https://doi.org/10.1159/000454682)]
- 4 **Viganò L, Costa G, Procopio F, Donadon M, Cimino M, Del Fabbro D, Gatti A, Torzilli G.** Parenchyma-Sparing Liver Surgery for Large Segment 1 Tumors: Ultrasound-Guided Lateral and Superior Approaches as Safe Alternatives to Major Hepatectomy. *J Am Coll Surg* 2015; **221**: e65-e73 [PMID: [26272013](https://pubmed.ncbi.nlm.nih.gov/26272013/) DOI: [10.1016/j.jamcollsurg.2015.07.008](https://doi.org/10.1016/j.jamcollsurg.2015.07.008)]
- 5 **Wang ZG, Lau W, Fu SY, Liu H, Pan ZY, Yang Y, Zhang J, Wu MC, Zhou WP.** Anterior hepatic parenchymal transection for complete caudate lobectomy to treat liver cancer situated in or involving the paracaval portion of the caudate lobe. *J Gastrointest Surg* 2015; **19**: 880-886 [PMID: [25759077](https://pubmed.ncbi.nlm.nih.gov/25759077/) DOI: [10.1007/s11605-015-2793-4](https://doi.org/10.1007/s11605-015-2793-4)]
- 6 **Takayasu K, Muramatsu Y, Shima Y, Goto H, Moriyama N, Yamada T, Makuuchi M, Kaneko A, Itabashi M, Shimamura Y.** Clinical and radiologic features of hepatocellular carcinoma originating in the caudate lobe. *Cancer* 1986; **58**: 1557-1562 [PMID: [3017540](https://pubmed.ncbi.nlm.nih.gov/3017540/)]
- 7 **Terayama N, Miyayama S, Tatsu H, Yamamoto T, Toya D, Tanaka N, Mitsui T, Miura S, Fujisawa M, Kifune K, Matsui O, Takashima T.** Subsegmental transcatheter arterial embolization for hepatocellular carcinoma in the caudate lobe. *J Vasc Interv Radiol* 1998; **9**: 501-508 [PMID: [9618113](https://pubmed.ncbi.nlm.nih.gov/9618113/)]
- 8 **Woo S, Kim HC, Chung JW, Jung HS, Hur S, Lee M, Jae HJ.** Chemoembolization of extrahepatic collateral arteries for treatment of hepatocellular carcinoma in the caudate lobe of the liver. *Cardiovasc Interv Radiol* 2015; **38**: 389-396 [PMID: [24934735](https://pubmed.ncbi.nlm.nih.gov/24934735/) DOI: [10.1007/s00270-014-0929-7](https://doi.org/10.1007/s00270-014-0929-7)]
- 9 **Kim HC, Chung JW, Jae HJ, Yoon JH, Lee JH, Kim YJ, Lee HS, Yoon CJ, Park JH.** Caudate lobe hepatocellular carcinoma treated with selective chemoembolization. *Radiology* 2010; **257**: 278-287 [PMID: [20697120](https://pubmed.ncbi.nlm.nih.gov/20697120/) DOI: [10.1148/radiol.10100105](https://doi.org/10.1148/radiol.10100105)]
- 10 **Goldberg SN, Ahmed M.** Minimally invasive image-guided therapies for hepatocellular carcinoma. *J Clin Gastroenterol* 2002; **35**: S115-S129 [PMID: [12394215](https://pubmed.ncbi.nlm.nih.gov/12394215/) DOI: [10.1097/00004836-200211002-00008](https://doi.org/10.1097/00004836-200211002-00008)]
- 11 **Shibata T, Maetani Y, Ametani F, Kubo T, Itoh K, Konishi J.** Efficacy of nonsurgical treatments for hepatocellular carcinoma in the caudate lobe. *Cardiovasc Interv Radiol* 2002; **25**: 186-192 [PMID: [12058213](https://pubmed.ncbi.nlm.nih.gov/12058213/) DOI: [10.1007/s00270-001-0111-x](https://doi.org/10.1007/s00270-001-0111-x)]
- 12 **Yamakado K, Nakatsuka A, Akeboshi M, Takaki H, Takeda K.** Percutaneous radiofrequency ablation for the treatment of liver neoplasms in the caudate lobe left of the vena cava: electrode placement through the left lobe of the liver under CT-fluoroscopic guidance. *Cardiovasc Interv Radiol* 2005; **28**: 638-640 [PMID: [16132396](https://pubmed.ncbi.nlm.nih.gov/16132396/) DOI: [10.1007/s00270-004-0104-7](https://doi.org/10.1007/s00270-004-0104-7)]
- 13 **Peng ZW, Liang HH, Chen MS, Zhang YJ, Li JQ, Zhang YQ, Lau WY.** Percutaneous radiofrequency ablation for the treatment of hepatocellular carcinoma in the caudate lobe. *Eur J Surg Oncol* 2008; **34**: 166-172 [PMID: [17851020](https://pubmed.ncbi.nlm.nih.gov/17851020/) DOI: [10.1016/j.ejso.2007.08.004](https://doi.org/10.1016/j.ejso.2007.08.004)]
- 14 **Nishigaki Y, Tomita E, Hayashi H, Suzuki Y, Iritani S, Kato T, Yamada T.** Efficacy and safety of radiofrequency ablation for hepatocellular carcinoma in the caudate lobe of the liver. *Hepatol Res* 2013; **43**: 467-474 [PMID: [23072582](https://pubmed.ncbi.nlm.nih.gov/23072582/) DOI: [10.1111/j.1872-034X.2012.01095.x](https://doi.org/10.1111/j.1872-034X.2012.01095.x)]
- 15 **Yoon CJ, Chung JW, Cho BH, Jae HJ, Kang SG, Kim HC, Choi YH, Jeon UB, Park JH.** Hepatocellular carcinoma in the caudate lobe of the liver: angiographic analysis of tumor-feeding arteries according to subsegmental location. *J Vasc Interv Radiol* 2008; **19**: 1543-50; quiz 1550 [PMID: [18755606](https://pubmed.ncbi.nlm.nih.gov/18755606/) DOI: [10.1016/j.jvir.2008.07.008](https://doi.org/10.1016/j.jvir.2008.07.008)]
- 16 **Miyayama S, Yamashiro M, Yoshie Y, Nakashima Y, Ikeno H, Orito N, Yoshida M, Matsui O.** Hepatocellular carcinoma in the caudate lobe of the liver: variations of its feeding branches on arteriography. *Jpn J Radiol* 2010; **28**: 555-562 [PMID: [20972854](https://pubmed.ncbi.nlm.nih.gov/20972854/) DOI: [10.1007/s11604-010-0471-8](https://doi.org/10.1007/s11604-010-0471-8)]
- 17 **Kang TW, Rhim H.** Recent Advances in Tumor Ablation for Hepatocellular Carcinoma. *Liver Cancer* 2015; **4**: 176-187 [PMID: [26674766](https://pubmed.ncbi.nlm.nih.gov/26674766/) DOI: [10.1159/000367740](https://doi.org/10.1159/000367740)]
- 18 **Jiang XY, Gu YK, Huang JH, Gao F, Zou RH, Zhang TQ.** Ex Vivo Liver Experiment of Hydrochloric Acid-Infused and Saline-Infused Monopolar Radiofrequency Ablation: Better Outcomes in Temperature, Energy, and Coagulation. *Cardiovasc Interv Radiol* 2016; **39**: 600-605 [PMID: [26486153](https://pubmed.ncbi.nlm.nih.gov/26486153/) DOI: [10.1007/s00270-015-1218-9](https://doi.org/10.1007/s00270-015-1218-9)]
- 19 **Huang JH, Morelli JN, Ai F, Zou RH, Gu YK, Gao F, Zhang TQ, Yao W, Jiang XY, Zhang YY.** Hydrochloric acid-enhanced radiofrequency ablation for treating a large hepatocellular carcinoma with spontaneous rupture: a case report. *Chin J Cancer* 2017; **36**: 1 [PMID: [28061892](https://pubmed.ncbi.nlm.nih.gov/28061892/) DOI: [10.1186/s40880-016-0161-8](https://doi.org/10.1186/s40880-016-0161-8)]
- 20 **Weijian F, Zan L, Suhong H, Hongmei Z, Lei Z, Yanjie Z, Yi C, Ni J.** Destructive effect of percutaneous hydrochloric acid injection therapy for liver cancer--a preliminary experimental and clinical study. *Gan To Kagaku Ryoho* 2006; **33**: 1852-1856 [PMID: [17212126](https://pubmed.ncbi.nlm.nih.gov/17212126/)]
- 21 **Yao W, Gu YK, Wang J, Gao F, Liu WL, Huang JH.** Safety evaluation of a potential ablation agent-hydrochloric acid in the rabbits' model. *Ann Palliat Med* 2014; **3**: 250-262 [PMID: [25841905](https://pubmed.ncbi.nlm.nih.gov/25841905/) DOI: [10.3978/j.issn.2224-5820.2014.02.01](https://doi.org/10.3978/j.issn.2224-5820.2014.02.01)]
- 22 **Zhang TQ, Huang SM, Gu YK, Gao F, Huang ZM, Jiang XY, Liu DX, Huang JH.** Safety and effect on ablation size of hydrochloric acid-perfused radiofrequency ablation in animal livers. *Int J Hyperthermia* 2018; **34**: 925-933 [PMID: [29457524](https://pubmed.ncbi.nlm.nih.gov/29457524/) DOI: [10.1080/02656736.2018.1442588](https://doi.org/10.1080/02656736.2018.1442588)]

P- Reviewer: Bramhall S, Jani K, Ekpenyong CE

S- Editor: Dou Y **L- Editor:** Wang TQ **E- Editor:** Tan WW





Published By Baishideng Publishing Group Inc
7901 Stoneridge Drive, Suite 501, Pleasanton, CA 94588, USA
Telephone: +1-925-2238242
Fax: +1-925-2238243
E-mail: bpgoffice@wjgnet.com
Help Desk: <https://www.f6publishing.com/helpdesk>
<https://www.wjgnet.com>

