


World Journal of *Clinical Cases*

World J Clin Cases 2019 February 26; 7(4): 405-547



**MINIREVIEWS**

- 405** Immune checkpoint inhibitor-induced colitis: A comprehensive review
Som A, Mandaliya R, Alsaadi D, Farshidpour M, Charabaty A, Malhotra N, Mattar MC

ORIGINAL ARTICLE**Basic Study**

- 419** Formalin fixation on HER-2 and PD-L1 expression in gastric cancer: A pilot analysis using the same surgical specimens with different fixation times
Kai K, Yoda Y, Kawaguchi A, Minesaki A, Iwasaki H, Aishima S, Noshiro H

Case Control Study

- 431** Nested case-control study of multiple serological indexes and Brighton pediatric early warning score in predicting death of children with sepsis
Xie X, Li M, Xiong TT, Wang R, Xiao L

Retrospective Study

- 441** Intestinal endometriosis: Diagnostic ambiguities and surgical outcomes
Bong JW, Yu CS, Lee JL, Kim CW, Yoon YS, Park IJ, Lim SB, Kim JC

Randomized Controlled Trial

- 452** Efficacy of 1.2 L polyethylene glycol plus ascorbic acid for bowel preparations
Tamaki H, Noda T, Morita M, Omura A, Kubo A, Ogawa C, Matsunaka T, Shibato M

CASE REPORT

- 466** Congenital analbuminemia in a patient affected by hypercholesterolemia: A case report
Suppressa P, Carbonara C, Lugani F, Campagnoli M, Troiano T, Minchiotti L, Sabbà C
- 473** Primary leiomyosarcoma of the thyroid gland with prior malignancy and radiotherapy: A case report and review of literature
Vujosevic S, Krnjecic D, Bogojevic M, Vuckovic L, Filipovic A, Dunđerović D, Sopta J
- 482** Endoscopic resection for residual lesion of metastatic gastric cancer: A case report
Hayashi K, Suzuki S, Ikehara H, Okuno H, Irie A, Esaki M, Kusano C, Gotoda T, Moriyama M
- 489** Peritoneal cavernous hemangiomas: A case report
Fu LY, Chen HY, Diao XL, Wang ZJ
- 494** Recurrent acute liver failure associated with novel SCYL1 mutation: A case report
Li JQ, Gong JY, Knisely AS, Zhang MH, Wang JS

- 500** Therapeutic plasma exchange and continuous renal replacement therapy for severe hyperthyroidism and multi-organ failure: A case report
Ba JH, Wu BQ, Wang YH, Shi YF
- 508** Hydrochloric acid enhanced radiofrequency ablation for treatment of large hepatocellular carcinoma in the caudate lobe: Report of three cases
Deng HX, Huang JH, Lau WY, Ai F, Chen MS, Huang ZM, Zhang TQ, Zuo MX
- 516** Long-term follow-up of a patient with venlafaxine-induced diurnal bruxism treated with an occlusal splint: A case report
Chen JM, Yan Y
- 525** Primary hepatic leiomyosarcoma successfully treated by transcatheter arterial chemoembolization: A case report
Zhu KL, Cai XJ
- 532** Anterior cervical corpectomy decompression and fusion for cervical kyphosis in a girl with Ehlers-Danlos syndrome: A case report
Fang H, Liu PF, Ge C, Zhang WZ, Shang XF, Shen CL, He R
- 538** Rhombencephalitis caused by *Listeria monocytogenes* with hydrocephalus and intracranial hemorrhage: A case report and review of the literature
Liang JJ, He XY, Ye H

ABOUT COVER

Editorial Board Member of *World Journal of Clinical Cases*, Xi Jin, PhD, Associate Professor, Doctor, Department of Gastroenterology, Institution of Gastroenterology, the First Affiliated Hospital, School of Medicine Zhejiang University, Zhejiang Province, Hangzhou 310003, China

AIMS AND SCOPE

World Journal of Clinical Cases (*World J Clin Cases*, *WJCC*, online ISSN 2307-8960, DOI: 10.12998) is a peer-reviewed open access academic journal that aims to guide clinical practice and improve diagnostic and therapeutic skills of clinicians.

The primary task of *WJCC* is to rapidly publish high-quality Case Report, Clinical Management, Editorial, Field of Vision, Frontier, Medical Ethics, Original Articles, Meta-Analysis, Minireviews, and Review, in the fields of allergy, anesthesiology, cardiac medicine, clinical genetics, clinical neurology, critical care, dentistry, dermatology, emergency medicine, endocrinology, family medicine, gastroenterology and hepatology, etc.

INDEXING/ABSTRACTING

The *WJCC* is now indexed in PubMed, PubMed Central, Science Citation Index Expanded (also known as SciSearch®), and Journal Citation Reports/Science Edition. The 2018 Edition of Journal Citation Reports cites the 2017 impact factor for *WJCC* as 1.931 (5-year impact factor: N/A), ranking *WJCC* as 60 among 154 journals in Medicine, General and Internal (quartile in category Q2).

RESPONSIBLE EDITORS FOR THIS ISSUE

Responsible Electronic Editor: *Wen-Wen Tan*

Proofing Editorial Office Director: *Jin-Lai Wang*

NAME OF JOURNAL

World Journal of Clinical Cases

ISSN

ISSN 2307-8960 (online)

LAUNCH DATE

April 16, 2013

FREQUENCY

Semimonthly

EDITORS-IN-CHIEF

Dennis A Bloomfield, Sandro Vento

EDITORIAL BOARD MEMBERS

<https://www.wjgnet.com/2307-8960/editorialboard.htm>

EDITORIAL OFFICE

Jin-Lai Wang, Director

PUBLICATION DATE

February 26, 2019

COPYRIGHT

© 2019 Baishideng Publishing Group Inc

INSTRUCTIONS TO AUTHORS

<https://www.wjgnet.com/bpg/gerinfo/204>

GUIDELINES FOR ETHICS DOCUMENTS

<https://www.wjgnet.com/bpg/GerInfo/287>

GUIDELINES FOR NON-NATIVE SPEAKERS OF ENGLISH

<https://www.wjgnet.com/bpg/gerinfo/240>

PUBLICATION MISCONDUCT

<https://www.wjgnet.com/bpg/gerinfo/208>

ARTICLE PROCESSING CHARGE

<https://www.wjgnet.com/bpg/gerinfo/242>

STEPS FOR SUBMITTING MANUSCRIPTS

<https://www.wjgnet.com/bpg/GerInfo/239>

ONLINE SUBMISSION

<https://www.f6publishing.com>

Primary hepatic leiomyosarcoma successfully treated by transcatheter arterial chemoembolization: A case report

Ke-Lei Zhu, Xiu-Jun Cai

ORCID number: Ke-Lei Zhu (0000000164973379); Xiu-Jun Cai (0000000236154680).

Author contributions: Zhu KL and Cai XJ solely contributed to this paper.

Supported by Yinzhou Young Investigator Award, NO. Yin Ren She 2017-133; and Ministry of Science of Yinzhou District, No. Yin Ke 2017-110.

Institutional review board statement: The study was reviewed and approved by the Institutional Review Board of Sir Run Run Shaw Hospital, Hangzhou, China.

Informed consent statement: The patient described in the case report gave verbal consent for anonymous description of the case.

Conflict-of-interest statement: None of the authors have any conflict of interest to declare.

CARE Checklist (2016) statement: The authors have read the CARE Checklist (2016), and the manuscript was prepared and revised according to the CARE Checklist (2016).

Open-Access: This article is an open-access article which was selected by an in-house editor and fully peer-reviewed by external reviewers. It is distributed in accordance with the Creative Commons Attribution Non Commercial (CC BY-NC 4.0) license, which permits others to distribute, remix, adapt, build upon this work non-commercially,

Ke-Lei Zhu, Xiu-Jun Cai, Department of General Surgery, Sir Run Run Shaw Hospital, Zhejiang University, Hangzhou 310016, Zhejiang Province, China

Ke-Lei Zhu, Department of Hepatobiliary Surgery, Yinzhou People's Hospital, Ningbo 315040, Zhejiang Province, China

Corresponding author: Xiu-Jun Cai, FRSC, PhD, Professor, Surgeon, Department of General Surgery, Sir Run Run Shaw Hospital, Zhejiang University, No. 3, Qingchun East Road, Hangzhou 310016, Zhejiang Province, China. cxjzu@zju.edu.cn

Telephone: +86-571-86006605

Abstract

BACKGROUND

Primary hepatic leiomyosarcoma is rare and reported sporadically, with less than 40 such cases have been reported in the English-language literature. Although it is reported to be associated with acquired immune deficiency syndrome, Epstein-Barr virus infection, Hodgkin's lymphoma, immunosuppression after organ transplantation, and hepatitis C virus-related liver cirrhosis, the precise steps leading to leiomyosarcoma have not been fully identified. Therapeutic strategies include liver wedge resection or lobectomy, chemotherapy, radiotherapy and liver transplantation; however, the prognosis of primary hepatic leiomyosarcoma is dismal.

CASE SUMMARY

We describe here the first case of primary hepatic leiomyosarcoma successfully treated by transcatheter arterial chemoembolization (TACE). The patient was a 68-year-old woman who presented with right upper quadrant pain and weight loss over the past 5 wk before admission. Abdominal computed tomography (commonly known as CT) and ultrasonography showed a mixed echoic mass measuring about 10 cm × 7 cm occupying the right lobe of the liver. Exploratory laparotomy was performed 1 wk after admission. The tumor was unresectable and biopsy was performed. Based on rapid frozen-section and histopathological examination, a final diagnosis of primary hepatic leiomyosarcoma was established. TACE was performed 2 wk later. The postoperative course was uneventful and the patient was discharged on day 7 after the operation. Contrast-enhanced CT showed that the tumor significantly shrunk with satisfactory lipiodol deposition. The patient has been followed up for 82 mo until now, and no progressive enlargement of the tumor or distal metastasis was observed.

CONCLUSION

and license their derivative works on different terms, provided the original work is properly cited and the use is non-commercial. See: <http://creativecommons.org/licenses/by-nc/4.0/>

Manuscript source: Unsolicited manuscript

Received: October 10, 2018

Peer-review started: October 10, 2018

First decision: November 27, 2018

Revised: December 22, 2018

Accepted: December 29, 2018

Article in press: December 30, 2018

Published online: February 26, 2019

TACE is a safe and effective treatment for primary hepatic leiomyosarcoma. The therapeutic effect of TACE combined with surgical resection should be further assessed.

Key words: Treatment; Prognosis; Transcatheter arterial chemoembolization; Primary hepatic leiomyosarcoma; Case report

©The Author(s) 2019. Published by Baishideng Publishing Group Inc. All rights reserved.

Core tip: Primary hepatic leiomyosarcoma is rare and reported sporadically. We here describe the first case of primary hepatic leiomyosarcoma successfully treated with transcatheter arterial chemoembolization (commonly known as TACE). The postoperative course was uneventful and the patient was discharged on day 7 after the operation. Contrast-enhanced computed tomography showed that the tumor significantly shrunk with satisfactory lipiodol deposition. The patient has been followed up for 82 mo until now, and no progressive enlargement of the tumor or distal metastasis was observed. This case indicates that TACE is a safe and effective treatment for primary hepatic leiomyosarcoma.

Citation: Zhu KL, Cai XJ. Primary hepatic leiomyosarcoma successfully treated by transcatheter arterial chemoembolization: A case report. *World J Clin Cases* 2019; 7(4): 525-531

URL: <https://www.wjgnet.com/2307-8960/full/v7/i4/525.htm>

DOI: <https://dx.doi.org/10.12998/wjcc.v7.i4.525>

INTRODUCTION

Primary hepatic leiomyosarcoma is rare and only reported sporadically^[1], with less than 40 cases having been reported to date. It appears to be associated with acquired immune deficiency syndrome (commonly known as AIDS)^[2], Epstein-Barr virus^[3], Hodgkin's lymphoma^[4], immunosuppression after organ transplantation^[5], and hepatitis C virus (commonly known as HCV)-related liver cirrhosis^[6], the precise mechanisms leading to leiomyosarcoma have yet been fully identified. Surgical resection is recommended for a curative treatment, while diagnosis of primary hepatic leiomyosarcoma is challenging and often delayed until it reaches a size that results in dismal prognosis.

We herein describe the first case of primary hepatic leiomyosarcoma successfully treated by transcatheter arterial chemoembolization (TACE). The patient has survived for 82 mo with no tumor enlargement and distant metastasis detected at postoperative follow-up.

CASE PRESENTATION

Chief complaints

A 68-year-old woman was referred to our hospital on December 2011, due to right upper quadrant pain and a 5-pound weight loss.

Personal and family history

Other symptoms were not presented and she did not drink alcohol, smoke or have a history of surgery.

Physical examination upon admission

Physical examination revealed a soft abdomen, no tenderness, no rebound tenderness, and no palpable lymph nodes or abdominal mass.

Laboratory examinations

The following laboratory data were recorded: hemoglobin of 125 g/L; white cell count of $5.5 \times 10^9/L$, with 72.5% neutrophils; platelet count of $234 \times 10^9/L$; alanine aminotransferase of 25 U/L; serum total protein of 75 g/L; albumin of 37.2 g/L; total bilirubin of 11 $\mu\text{mol/L}$; direct bilirubin of 9.5 $\mu\text{mol/L}$; α -fetoprotein of 5.23 ng/mL;

and carcinoembryonic antigen of 4.5 ng/L. Serological markers for hepatitis B virus and HCV were negative. The indocyanine green retention rate at 15 min was 2.2%.

Imaging examinations

Abdominal ultrasonography showed there was a mixed echoic mass measuring around 10 cm × 7 cm in the right hepatic lobe. Abdominal computed tomography (CT) showed a similar finding, that the tumor was inhomogeneous density, with mild delayed enhancement, and had central necrosis (Figure 1A). Gastrointestinal endoscopy and colonoscopy showed negative findings. Chest CT showed no mass over the lung.

Preoperative diagnosis was unconfirmed, exploratory laparotomy was performed 1 wk after admission, and no obvious effusion was found in the abdominal cavity. The entire liver VIII was occupied by a creamy white, firm mass measuring about 10 cm × 7 cm, which protruded into the abdominal cavity and appeared to invade the diaphragm and middle hepatic vein, making the tumor unresectable (Figure 1); thus, a biopsy was performed. Rapid frozen-section biopsy analysis considered the diagnosis of leiomyosarcoma. Histopathological examination showed a hepatic mass that consisted of spindle-shaped cells with mitotic figures and nuclear atypia (Figure 2). Immunohistochemical staining showed that spindle-shaped cells were positive for anti-smooth muscle actin (Figure 3) and desmin (Figure 4) but negative for keratin, S-100, CD34 and CD117. No obvious lesions were observed in the bilateral adnexa and uterus, and no palpable mass was detected in the superficial body.

FINAL DIAGNOSIS

Taken together, a final diagnosis of primary hepatic leiomyosarcoma was established.

TREATMENT

TACE was performed 2 wk postoperatively. Superior mesenteric angiography showed no significant abnormality. Common hepatic angiography demonstrated a single mass with hypervascularity, tumor staining and dilated feeding arteries in the anterior segment of the right liver lobe (Figure 1B). A catheter was inserted into the feeding artery of the tumor, and the emulsion containing 50 mg epirubicin and Lipiodol (Lipiodol Ultra-Fluid; Guerbet Japan, Tokyo, Japan) was injected, followed by embolization with gelatin sponge particles (Gelpart; Nihonkayaku, Tokyo, Japan). The postoperative course was uneventful and the patient was discharged on day 7 after the operation. The patient underwent three courses of TACE, and the latest treatment was performed in October 2016. There were no newly emerging lesions observed in the liver (Figure 5B).

OUTCOME AND FOLLOW-UP

Routine follow-up was continued in the hepatobiliary clinic. Contrast-enhanced CT in 2018 showed that the tumor had shrunk significantly and was associated with satisfactory lipiodol deposition (Figure 5A). The patient was followed up for 82 mo until now, and no progressive enlargement of the tumor or distal metastasis was observed.

DISCUSSION

Primary hepatic leiomyosarcoma is extremely rare, and less than 40 such cases have been reported in the English-language literature. Primary hepatic sarcoma comprises only 1%-2% of all malignant hepatic tumors^[7], and leiomyosarcoma is particularly rare. Hepatic leiomyosarcoma may arise from intrahepatic vascular structures^[8], bile ducts^[9] or ligamentum teres^[10], and is reported to be associated with AIDS^[2], Epstein-Barr virus^[3], Hodgkin's lymphoma^[3], immunosuppression after organ transplantation^[4], and HCV-related liver cirrhosis^[5]. However, the precise steps leading to leiomyosarcoma have not been fully identified.

Leiomyosarcoma has no specific clinical manifestations. It is often asymptomatic until it becomes large and produces nonspecific symptoms, or is unexpectedly found during physical examination. Some patients may have a wide spectrum of symptoms, including abdominal pain, abdominal mass, weight loss, nausea, vomiting, anorexia,

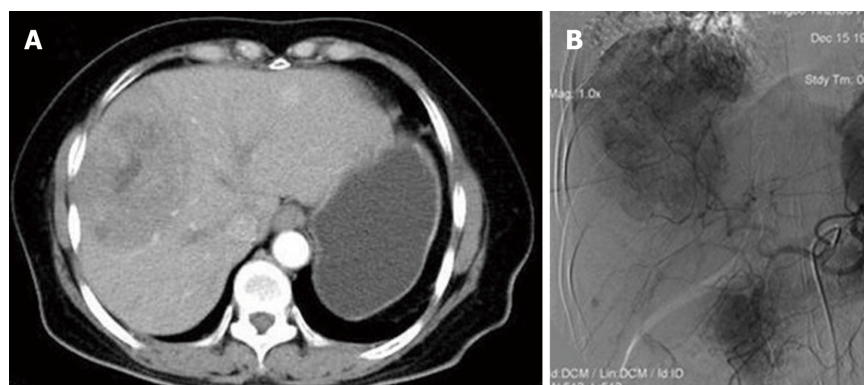


Figure 1 Imaging features before treatment. A: Computed tomography showed a mass with inhomogeneous density, mild delayed enhancement and central necrosis; B: Hepatic angiography demonstrated a single mass with hypervascular tumor staining and dilated feeding arteries.

abdominal distension, jaundice, and, rarely, acute intra-abdominal bleeding secondary to tumor rupture.

CT findings of primary hepatic leiomyosarcoma have been described as an enlarged, heterogeneous, hypodense mass with peripheral enhancement and evidence of central necrosis, whereas magnetic resonance imaging usually displays the homogeneous or heterogeneous hypointensity tumor on T1-weighted images and hyperintensity on T2-weighted images. Diagnosis of primary hepatic leiomyosarcoma is challenging due to the nonspecific nature of symptoms and lack of serological markers. The clinical manifestations and laboratory and imaging examinations have limited value for diagnosis and differential diagnosis. The definitive diagnosis of leiomyosarcoma mainly depends on pathological and immunohistochemical examinations. The pathological features of leiomyosarcoma include spindle-shaped cells, abundant cytoplasm, nuclear atypia, and presence of mitotic figures. Immunohistochemical staining of tumors is positive for vimentin, desmin and actin, and negative for α -fetoprotein, CD34, CD117, cytokeratin, and hepatocytes.

Surgical resection is considered to be the only potentially curative treatment. Patients with primary hepatic leiomyosarcoma mostly have no history of hepatitis B and cirrhosis. Therefore, complete resection of the tumor, such as regular hepatic lobectomy, hemihepatectomy and trisegmentectomy, may achieve a satisfactory therapeutic outcome. Matthaei *et al*^[11] reported three cases with > 10 yr survival after hepatectomy. Liver transplantation for primary hepatic leiomyosarcoma has remained controversial until now. The outcome for liver transplantation has varied among cases. Liang *et al*^[12] described a patient with primary hepatic leiomyosarcoma who survived for 34 mo after undergoing liver transplantation. In contrast, Saintpaul *et al*^[13] reported a case with only 15 d survival after surgery. The efficacy of chemotherapy and radiotherapy for primary hepatic leiomyosarcoma has not been confirmed. Adjuvant chemotherapy using doxorubicin and ifosfamide seems to slow progression and help to prolong survival after complete resection^[14].

Currently, no effective treatments for unresectable primary hepatic leiomyosarcoma have been reported. Fujita *et al*^[5] reported a patient with metastatic leiomyosarcoma who just received palliative and conservative therapy and only survived for 3 mo after diagnosis. For our case, the patient underwent three courses of TACE with emulsion of epirubicin and Lipiodol, followed by embolization with gelatin sponge particles. Postoperative contrast-enhanced CT showed significant tumor shrinkage associated with satisfactory lipiodol deposition. Routine follow-up was continued in the hepatobiliary clinic and there were no newly emerging lesions observed in the liver. The case has been followed up for 82 mo until now, and no progressive enlargement of the tumor or distal metastasis has been observed. Primary hepatic leiomyosarcoma is a tumor with rich blood supply, and tumor cells are intolerant to ischemia. The embolic agents injected into the hepatic artery induced ischemic tumor necrosis. This may be the main mechanism underlying the effectiveness of drug-eluting bead TACE (commonly known as DEB-TACE). Otherwise, the epirubicin was used to suppress tumor progression^[15].

CONCLUSION

We have described the first case of primary hepatic leiomyosarcoma successfully

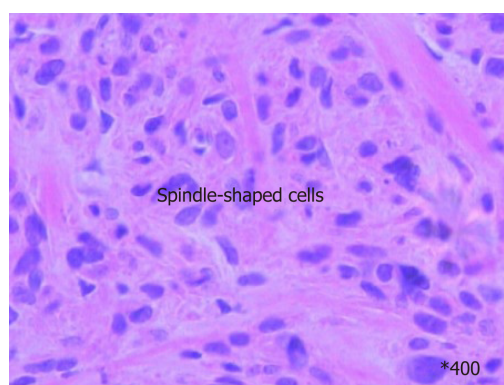


Figure 2 Histological examination showed a hepatic mass that consisted of spindle-shaped cells with mitotic figures and nuclear atypia.

treated by TACE, and demonstrated that TACE is safe and effective. Further studies are required to assess the therapeutic effect of TACE in combination with surgical resection in primary hepatic leiomyosarcoma.

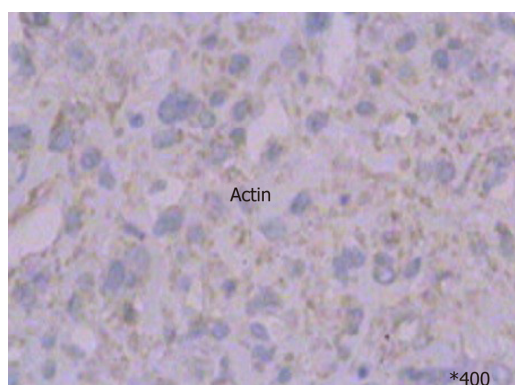


Figure 3 Immunohistochemical staining was positive for anti-smooth muscle actin.

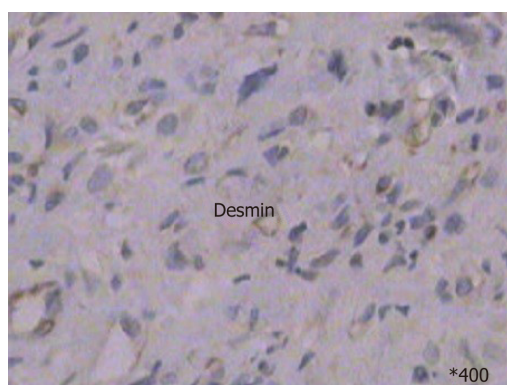


Figure 4 Immunohistochemical staining was positive for desmin.

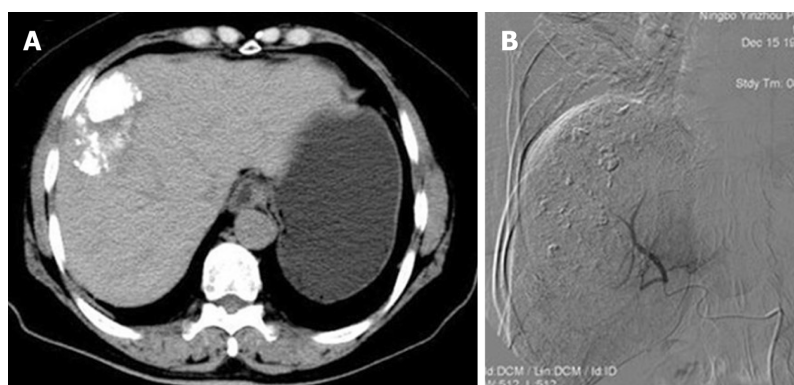


Figure 5 Imaging changes after treatment. A: Computed tomography showed significant tumor shrinkage associated with satisfactory lipiodol deposition; B: No newly emerging lesions and successful embolization of feeding arteries.

REFERENCES

- 1 **Metta H**, Corti M, Trione N, Masini D, Monestes J, Rizzolo M, Carballido M. Primary hepatic leiomyosarcoma--a rare neoplasm in an adult patient with AIDS: second case report and literature review. *J Gastrointest Cancer* 2014; **45** Suppl 1: 36-39 [PMID: 23921603 DOI: 10.1007/s12029-013-9525-3]
- 2 **Ross JS**, Del Rosario A, Bui HX, Sonbati H, Solis O. Primary hepatic leiomyosarcoma in a child with the acquired immunodeficiency syndrome. *Hum Pathol* 1992; **23**: 69-72 [PMID: 1544673 DOI: 10.1016/0046-8177(92)90014-T]
- 3 **Brichard B**, Smets F, Sokal E, Clapuyt P, Vermeylen C, Cornu G, Rahier J, Otte JB. Unusual evolution of an Epstein-Barr virus-associated leiomyosarcoma occurring after liver transplantation. *Pediatr Transplant* 2001; **5**: 365-369 [PMID: 11560757 DOI: 10.1034/j.1399-3046.2001.00022.x]
- 4 **Giuliente F**, Sarno G, Ardito F, Pierconti F. Primary hepatic leiomyosarcoma in a young man after Hodgkin's disease: diagnostic pitfalls and therapeutic challenge. *Tumori* 2009; **95**: 374-377 [PMID: 19688980 DOI: 10.1177/030089160909500318]

- 5 **Fujita H**, Kiriya M, Kawamura T, Ii T, Takegawa S, Dohba S, Kojima Y, Yoshimura M, Kobayashi A, Ozaki S, Watanabe K. Primary hepatic leiomyosarcoma in a woman after renal transplantation: report of a case. *Surg Today* 2002; **32**: 446-449 [PMID: [12061699](#) DOI: [10.1007/s005950200073](#)]
- 6 **Tsuji M**, Takenaka R, Kashihara T, Hadama T, Terada N, Mori H. Primary hepatic leiomyosarcoma in a patient with hepatitis C virus-related liver cirrhosis. *Pathol Int* 2000; **50**: 41-47 [PMID: [10692176](#) DOI: [10.1046/j.1440-1827.2000.00999.x](#)]
- 7 **Maki HS**, Hubert BC, Sajjad SM, Kirchner JP, Kuehner ME. Primary hepatic leiomyosarcoma. *Arch Surg* 1987; **122**: 1193-1196 [PMID: [3310964](#) DOI: [10.1001/archsurg.1987.01400220103020](#)]
- 8 **Civardi G**, Cavanna L, Iovine E, Buscarini E, Vallisa D, Buscarini L. Diagnostic imaging of primary hepatic leiomyosarcoma: a case report. *Ital J Gastroenterol* 1996; **28**: 98-101 [PMID: [8782003](#)]
- 9 **Holloway H**, Walsh CB, Thomas R, Fielding J. Primary hepatic leiomyosarcoma. *J Clin Gastroenterol* 1996; **23**: 131-133 [PMID: [8877642](#) DOI: [10.1097/00004836-199609000-00014](#)]
- 10 **Yamaguchi J**, Azuma T, Fujioka H, Tanaka K, Furui J, Tomioka T, Kanematsu T. Leiomyosarcoma occurring in the ligamentum teres of the liver: a case report and a review of seven reported cases. *Hepatogastroenterology* 1996; **43**: 1051-1056 [PMID: [8884338](#) DOI: [10.1002/\(SICI\)1097-0347\(199607/08\)43:0.CO;2-V](#)]
- 11 **Matthaei H**, Krieg A, Schmelzle M, Boelke E, Poremba C, Rogiers X, Knoefel WT, Peiper M. Long-term survival after surgery for primary hepatic sarcoma in adults. *Arch Surg* 2009; **144**: 339-44; discussion 344 [PMID: [19380647](#) DOI: [10.1001/archsurg.2009.30](#)]
- 12 **Liang X**, Xiao-Min S, Jiang-Ping X, Jie-Yu Y, Xiao-Jun Z, Zhi-Ren F, Guo-Shan D, Rui-Dong L. Liver transplantation for primary hepatic leiomyosarcoma: a case report and review of the literatures. *Med Oncol* 2010; **27**: 1269-1272 [PMID: [19997990](#) DOI: [10.1007/s12032-009-9372-z](#)]
- 13 **Saint-Paul MC**, Gugenheim J, Hofman P, Arpurt JP, Fabiani P, Michiels JF, Fujita N, Goubeaux B, Loubière R, Delmont J. [Leiomyosarcoma of the liver: a case treated by transplantation]. *Gastroenterol Clin Biol* 1993; **17**: 218-222 [PMID: [8330697](#)]
- 14 **Shivathirthan N**, Kita J, Iso Y, Hachiya H, Kyunghwa P, Sawada T, Kubota K. Primary hepatic leiomyosarcoma: Case report and literature review. *World J Gastrointest Oncol* 2011; **3**: 148-152 [PMID: [22046492](#) DOI: [10.4251/wjgo.v3.i10.148](#)]
- 15 **Pasquali S**, Gronchi A. Neoadjuvant chemotherapy in soft tissue sarcomas: latest evidence and clinical implications. *Ther Adv Med Oncol* 2017; **9**: 415-429 [PMID: [28607580](#) DOI: [10.1177/1758834017705588](#)]

P- Reviewer: Farshadpour F, Hann HW, Pallav K, Tajiri K, Vaudo G

S- Editor: Yan JP **L- Editor:** Filipodia **E- Editor:** Tan WW





Published By Baishideng Publishing Group Inc
7901 Stoneridge Drive, Suite 501, Pleasanton, CA 94588, USA
Telephone: +1-925-2238242
Fax: +1-925-2238243
E-mail: bpgoffice@wjgnet.com
Help Desk: <https://www.f6publishing.com/helpdesk>
<https://www.wjgnet.com>

