


# World Journal of *Clinical Cases*

*World J Clin Cases* 2019 March 6; 7(5): 548-690



**ORIGINAL ARTICLE****Retrospective Study**

- 548** Clinical presentation and early predictors for poor outcomes in pediatric myocarditis: A retrospective study  
*Rodriguez-Gonzalez M, Sanchez-Codez MI, Lubian-Gutierrez M, Castellano-Martinez A*

**Observational Study**

- 562** Safety of an improved patent ductus arteriosus occluder for transcatheter closure of perimembranous ventricular septal defects with abnormally attached tricuspid chordae tendineae  
*He L, Du YJ, Cheng GS, Zhang YS*

**META-ANALYSIS**

- 572** Adiponectin gene polymorphisms and risk of gestational diabetes mellitus: A meta-analysis  
*Huang LT, Wu SL, Liao X, Ma SJ, Tan HZ*
- 585** Maternal serum level of resistin is associated with risk for gestational diabetes mellitus: A meta-analysis  
*Hu SM, Chen MS, Tan HZ*
- 600** Docetaxel, cisplatin, and 5-fluorouracil compared with epirubicin, cisplatin, and 5-fluorouracil regimen for advanced gastric cancer: A systematic review and meta-analysis  
*Li B, Chen L, Luo HL, Yi FM, Wei YP, Zhang WX*

**CASE REPORT**

- 616** Sustained complete response to erlotinib in squamous cell carcinoma of the head and neck: A case report  
*Thinn MM, Hsueh CT, Hsueh CT*
- 623** Exercise-induced anaphylaxis with an Ayurvedic drug as cofactor: A case report  
*Losa F, Deidda M, Firinu D, Martino MLD, Barca MP, Giacco SD*
- 628** Diagnostic detection with cardiac tomography and resonance of extremely rare coronary anomaly: A case report and review of literature  
*Schicchi N, Fogante M, Giuseppetti GM, Giovagnoni A*
- 636** Fatal meningococcal meningitis in a 2-year-old child: A case report  
*Mularski A, Žaba C*
- 642** Perioperative topical ascorbic acid for the prevention of phacoemulsification-related corneal endothelial damage: Two case reports and review of literature  
*Lee CY, Chen HT, Hsueh YJ, Chen HC, Huang CC, Meir YJJ, Cheng CM, Wu WC*

- 650** Application of computer-assisted navigation in treating congenital maxillomandibular syngnathia: A case report  
*Lin LQ, Bai SS, Wei M*
- 656** Concomitant paraganglioma and thyroid carcinoma: A case report  
*Lin B, Yang HY, Yang HJ, Shen SY*
- 663** Rare empty sella syndrome found after postoperative hypotension and respiratory failure: A case report  
*Guo P, Xu ZJ, Hu CE, Zheng YY, Xu DF*
- 668** Use of tunnel endoscopy for diagnosis of obscure submucosal esophageal adenocarcinoma: A case report and review of the literature with emphasis on causes of esophageal stenosis  
*Liu S, Wang N, Yang J, Yang JY, Shi ZH*
- 676** Intrauterine cystic adenomyosis: Report of two cases  
*Fan YY, Liu YN, Li J, Fu Y*
- 684** Melanotic Xp11-associated tumor of the sigmoid colon: A case report  
*Wang G, Li GG, Zhu SM, Cai BJ, Yu PJ, Zhang CW*

**ABOUT COVER**

Editorial Board Member of *World Journal of Clinical Cases*, Manel Sabate, MD, PhD, Associate Professor, Interventional Cardiology Department, Clinic University Hospital, Barcelona 08036, Spain

**AIMS AND SCOPE**

*World Journal of Clinical Cases* (*World J Clin Cases*, *WJCC*, online ISSN 2307-8960, DOI: 10.12998) is a peer-reviewed open access academic journal that aims to guide clinical practice and improve diagnostic and therapeutic skills of clinicians.

The primary task of *WJCC* is to rapidly publish high-quality Case Report, Clinical Management, Editorial, Field of Vision, Frontier, Medical Ethics, Original Articles, Meta-Analysis, Minireviews, and Review, in the fields of allergy, anesthesiology, cardiac medicine, clinical genetics, clinical neurology, critical care, dentistry, dermatology, emergency medicine, endocrinology, family medicine, gastroenterology and hepatology, etc.

**INDEXING/ABSTRACTING**

The *WJCC* is now indexed in PubMed, PubMed Central, Science Citation Index Expanded (also known as SciSearch®), and Journal Citation Reports/Science Edition. The 2018 Edition of Journal Citation Reports cites the 2017 impact factor for *WJCC* as 1.931 (5-year impact factor: N/A), ranking *WJCC* as 60 among 154 journals in Medicine, General and Internal (quartile in category Q2).

**RESPONSIBLE EDITORS  
FOR THIS ISSUE**

Responsible Electronic Editor: Ying-Na Bian      Proofing Editorial Office Director: Jin-Lei Wang

**NAME OF JOURNAL**

*World Journal of Clinical Cases*

**ISSN**

ISSN 2307-8960 (online)

**LAUNCH DATE**

April 16, 2013

**FREQUENCY**

Semimonthly

**EDITORS-IN-CHIEF**

Dennis A Bloomfield, Sandro Vento

**EDITORIAL BOARD MEMBERS**

<https://www.wjnet.com/2307-8960/editorialboard.htm>

**EDITORIAL OFFICE**

Jin-Lei Wang, Director

**PUBLICATION DATE**

March 6, 2019

**COPYRIGHT**

© 2019 Baishideng Publishing Group Inc

**INSTRUCTIONS TO AUTHORS**

<https://www.wjnet.com/bpg/gerinfo/204>

**GUIDELINES FOR ETHICS DOCUMENTS**

<https://www.wjnet.com/bpg/GerInfo/287>

**GUIDELINES FOR NON-NATIVE SPEAKERS OF ENGLISH**

<https://www.wjnet.com/bpg/gerinfo/240>

**PUBLICATION MISCONDUCT**

<https://www.wjnet.com/bpg/gerinfo/208>

**ARTICLE PROCESSING CHARGE**

<https://www.wjnet.com/bpg/gerinfo/242>

**STEPS FOR SUBMITTING MANUSCRIPTS**

<https://www.wjnet.com/bpg/GerInfo/239>

**ONLINE SUBMISSION**

<https://www.f6publishing.com>

## Fatal meningococcal meningitis in a 2-year-old child: A case report

Aleksander Mularski, Czesław Żaba

**ORCID number:** Aleksander Mularski (0000-0002-3392-1813); Czesław Żaba (0000-0001-7522-4568).

**Author contributions:** Mularski A and Żaba C performed the postmortem examination, reviewed the literature and contributed to manuscript drafting.

**Informed consent statement:** No informed written consent was needed as the medicolegal autopsy was carried out at a prosecutor's request.

**Conflict-of-interest statement:** The authors declare that they have no conflict of interest.

**CARE Checklist (2016) statement:** The authors have read the CARE Checklist (2016), and the manuscript was prepared and revised according to the CARE Checklist (2016).

**Open-Access:** This article is an open-access article which was selected by an in-house editor and fully peer-reviewed by external reviewers. It is distributed in accordance with the Creative Commons Attribution Non Commercial (CC BY-NC 4.0) license, which permits others to distribute, remix, adapt, build upon this work non-commercially, and license their derivative works on different terms, provided the original work is properly cited and the use is non-commercial. See: <http://creativecommons.org/licenses/by-nc/4.0/>

**Manuscript source:** Unsolicited manuscript

**Received:** December 20, 2018

**Peer-review started:** December 20, 2018

**Aleksander Mularski**, Department of Legal and Forensic Medicine, Poznan University of Medical Sciences, Poznan 60-781, Poland

**Czesław Żaba**, Institute of Forensic Research, Cracow 31-033, Poland

**Corresponding author:** Aleksander Mularski, MD, Academic Fellow, Medical Assistant, Department of Legal and Forensic Medicine, Poznan University of Medical Sciences, Święcickiego 6, Poznan 60-781, Poland. [aleksander.mularski@gmail.com](mailto:aleksander.mularski@gmail.com)

**Telephone:** +48-61-8546410

**Fax:** +48-61-8546410

### Abstract

#### BACKGROUND

In fatal cases of meningococcal septicemia, bacteriological diagnosis may not be straightforward due to postmortem replication and relocation of endogenic microflora. In medicolegal practice, aside from routine autopsy and histopathology, also other diagnostic methods, such as microbiological tests, immunohistochemistry and polymerase chain reaction (PCR), are used to examine body fluids and tissues.

#### CASE SUMMARY

We present the case of sudden death in a 2-year-old child. The patient died approximately 30 min after hospital admission before any routine diagnostic procedures were undertaken. Presence of whole-body rash and fulminant course of the disease raised suspicion of meningococcal septicemia. An autopsy was performed seven days after death when the body showed the signs of late postmortem decomposition. No etiological factor of septicemia could be identified based on macro- and microscopic findings. However, PCR demonstrated the presence of genetic material of group W *Neisseria meningitidis* in patient's cerebrospinal fluid and blood.

#### CONCLUSION

Microbiological PCR should be conducted postmortem whenever a specific etiological factor could not be identified with conventional methods.

**Key words:** Meningococcal infection; Molecular microbiology; Waterhouse-Friderichsen syndrome; *Neisseria meningitidis*; Autopsy; Cerebrospinal fluid; Case report

©The Author(s) 2019. Published by Baishideng Publishing Group Inc. All rights reserved.

**Core tip:** We present the case of a 2-year-old patient who died suddenly with the signs of meningococcal septicemia. No etiological factor of the septicemia could be identified

**First decision:** January 5, 2019  
**Revised:** January 14, 2019  
**Accepted:** January 29, 2019  
**Article in press:** January 30, 2019  
**Published online:** March 6, 2019

based on macro- and microscopic findings during an autopsy carried out seven days postmortem. However, the genetic material of group W *Neisseria meningitidis* was detected in cerebrospinal fluid samples based on polymerase chain reaction (PCR). Our observations imply that microbiological PCR can be helpful in medicolegal practice, especially when an autopsy is delayed and the results of conventional bacteriological examination are unavailable or seem controversial.

**Citation:** Mularski A, Žaba C. Fatal meningococcal meningitis in a 2-year-old child: A case report. *World J Clin Cases* 2019; 7(5): 636-641

**URL:** <https://www.wjgnet.com/2307-8960/full/v7/i5/636.htm>

**DOI:** <https://dx.doi.org/10.12998/wjcc.v7.i5.636>

## INTRODUCTION

Acute infections of the central nervous system still constitute a diagnostic and therapeutic challenge. Their course is severe, they usually co-exist with systemic infections, and are associated with high mortality. *Neisseria meningitidis* (*N. meningitidis*) infections are a particular threat since they may occur epidemically or pandemically, rather than sporadically or endemically. Although up to 12 serological groups have been identified among *N. meningitidis* strains, more than 90% of infections are caused by A, B, C, Y and W group isolates. Identification of *N. meningitidis* serogroups that predominate in a given country is vital for the development of local vaccination strategies.

Clinical presentation of *N. meningitidis* infections is similar like in the case of other bacterial neuroinfections. A common, albeit not pathognomonic symptom of meningococcal septicemia is purpuric rash, present in 10%-50% of cases. Aside from the rash, adrenal hemorrhages (Waterhouse-Friderichsen syndrome, WFS) can be observed in fulminant infections, especially in children. In fatal cases, bacteriological diagnosis may not be straightforward due to postmortem replication and relocation of endogenous microflora. In medicolegal practice, aside from routine autopsy and histopathology, also other diagnostic methods, such as microbiological tests, immunohistochemistry and polymerase chain reaction (PCR), are used to examine body fluids and tissues<sup>[1-5]</sup>.

## CASE PRESENTATION

### Clinical summary

A 2-year-old boy was admitted to the Pediatric Emergency Room in an extremely poor general condition, with apnea, asystole, immeasurable oxygen saturation and the signs of severe brain injury (Glasgow Coma Scale 3). Based on the information from his father, the boy had a fever and adipsia for several hours and vomited twice. The symptoms appeared in the afternoon a day before the hospital admission; based on this presentation, a non-specific upper respiratory infection had been diagnosed by a family physician in an outpatient setting.

The patient passed away 30 min post-admission despite a resuscitation attempt undertaken at the Emergency Room. Examination of blood samples obtained at admission revealed normal leukocyte count with a decrease in neutrophil fraction and an increase in lymphocyte, monocyte and basophile percentages, elevated concentrations of urea, creatinine and C-reactive protein, considerable hypoglycemia, increased activity of aspartate aminotransferase with normal activity of alanine aminotransferase, a significant rise in lactate dehydrogenase, and procalcitonin above the upper detection limit.

Based on medical history, clinical and laboratory findings, patient's death was attributed to septic shock. However, a medicolegal autopsy was requested by the prosecutor to establish the cause of death ultimately and to evaluate the correctness of outpatient medical treatment.

### Pathological findings

The autopsy was performed seven days after the patient's death. External examination of the body revealed purpuric rash, more pronounced on the face, arms and chest, along with the signs of early decomposition (Figure 1). Cerebrospinal fluid



(CSF) and blood samples were obtained aseptically before opening the body cavities. CSF was collected by means of suboccipital puncture, and blood by transthoracic puncture of the heart. Moreover, brain, lung, liver, spleen, heart and kidney samples were obtained, as aseptically as possible. Internal examination revealed massive hemorrhages in both adrenal glands (Figure 2), and petechiae in esophageal mucosa, thymus, subepicardial and subpleural tissue (Figure 3). No evidence of meningitis was found on macroscopic examination.

### **Histological findings**

The macroscopic findings were confirmed on microscopic examination. The evidence of unspecific passive congestion was found in the brain, thymus, lungs, liver and spleen, along with fiber waviness in the heart. Moreover, massive hemorrhages at the corticomedullary junction were identified in both adrenal glands (Figure 4).

### **Microbiological studies and PCR**

Since the autopsy was carried out seven days after the patient's death, no microbiological studies were performed. However, the genetic material of group W *N. meningitidis* was detected in CSF samples using PCR. Due to the positive result of the test, other samples (skin, brain, lungs, liver, spleen, heart and kidneys) were not subjected to PCR examination.

---

## **FINAL DIAGNOSIS**

---

Based on the results of autopsy, microscopic and genetic examination it was concluded that the boy died due to septic shock associated with a severe meningococcal disease with concomitant WFS, caused by group W *N. meningitidis*.

---

## **TREATMENT**

---

Not applicable.

---

## **OUTCOME AND FOLLOW-UP**

---

Not applicable.

---

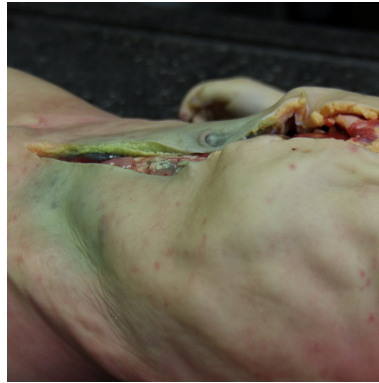## **DISCUSSION**

---

*N. meningitidis* is a fastidious, encapsulated, aerobic Gram-negative diplococcus being a leading cause of fatal sepsis and meningitis worldwide. Each case of suspected bacterial meningitis should be considered a medical emergency, since in untreated cases, mortality due to this condition may approximate 100%. The epidemiological profile of *N. meningitidis* varies from population to population and may change over time. This pathogen may be an etiological factor of meningococcal sepsis and WFS, a rare, life-threatening condition. In meningococcal WFS, initially macular rash progresses to large purpuric lesions penetrating deep into the skin and eventually causing subcutaneous necrosis. While WFS is usually associated with meningococcal infection, it may sporadically have different etiology, which puts particular emphasis on the correctness of causal factor identification<sup>[3-7]</sup>.

Mortality due to meningococcal infections, especially WFS, can be decreased if these conditions are diagnosed early. Still some patients die despite medical treatment, especially if meningococcal disease is initially misdiagnosed as a common viral infection (cold, influenza, gastritis); in virtually all such cases, the correctness of medical intervention needs to be verified postmortem. Without adequate knowledge of basic clinical aspects of sepsis, patient's history, symptoms and course of the disease, and circumstances of death, postmortem diagnostic findings can be easily misinterpreted. This, in turn, may result in erroneous medicolegal opinion about the cause of death and/or correctness of medical treatment<sup>[8]</sup>. Postmortem diagnosis of fulminant meningococcal sepsis is particularly challenging if no CSF samples were obtained from a living patient. The evaluation can be further compromised due to the incompleteness of medical documentation or complete lack thereof, sudden death, and a serious delay in the autopsy.

During the medicolegal autopsy, the pathologist should carefully examine the cadaver for all potential abnormalities and signs of inflammation present on external



**Figure 1** Purpuric rash on the chest and arms. Early decomposition.

and internal examination. Although sepsis does not produce any pathognomonic lesions that can be identified by microscopic examination, the latter should be a vital component of each postmortem evaluation<sup>[9]</sup>.

Examination of the CSF is of paramount importance for the diagnosis of all forms of meningitis. Other materials that can be examined microbiologically postmortem include blood (especially from the heart), urine, nasal discharge, throat and skin swabs. However, several *Neisseria* species, among them *N. meningitidis*, can colonize nasopharynx and skin in healthy humans, and thus, their isolation from these locations should be interpreted with care<sup>[10]</sup>.

Early administration of antibiotics may hinder microbiological confirmation of meningococcal disease. Further, isolation of the bacteria from the blood or CSF obtained postmortem may not necessarily correspond to a true positive result but may be associated with the agonal spread, translocation after death or contamination. Most of the above seem to be unrelated to the cause of death<sup>[11-13]</sup>.

Postmortem detection of meningococcemia based on the presence of specific meningococcal capsular polysaccharides in the blood is a well-established diagnostic option. The results of the test are rarely false positive, even when conducted long after death, on blood samples with heavy bacterial load and/or deep hemolysis, stored for a long time at 40°C, and containing anticoagulant<sup>[14]</sup>.

Both laboratory and clinical studies demonstrated that PCR, especially real-time PCR, are sensitive and specific enough to detect meningococcal disease. Also other new diagnostic tests, *e.g.*, fluorescence in situ hybridization and mass spectrometry, are suitable for this purpose. Nevertheless, none of these methods has been validated as a postmortem test. Only a few previously published reports documented the accuracy of late postmortem molecular identification of *N. meningitidis* in the CSF and other body fluids, such as blood from the heart and vitreous humor<sup>[2,11,15,16]</sup>. Our hereby presented experiences add to this sparse evidence, demonstrating that detection of *N. meningitidis* in the CSF obtained up to 7 days after death is still possible.

## CONCLUSION

Postmortem isolation of *N. meningitidis* from the CSF of the patient who died seven days earlier is an important finding from both medical and medicolegal perspective. Our observations imply that PCR can be helpful in medicolegal practice, especially when an autopsy is delayed and the results of conventional bacteriological examination seem controversial. Postmortem PCR is a valuable instrument to determine the etiology of WFS diagnosed with conventional tests. Plausibly, suboccipital puncture, although more technically demanding, is a more appropriate route of CSF collection than traditional sampling from the cavities, due to a lower risk of secondary bacterial contamination. However, this hypothesis needs to be verified in future prospective studies. To summarize, our hereby presented findings imply that molecular microbiology should be accepted wider as a technique for postmortem evaluation.



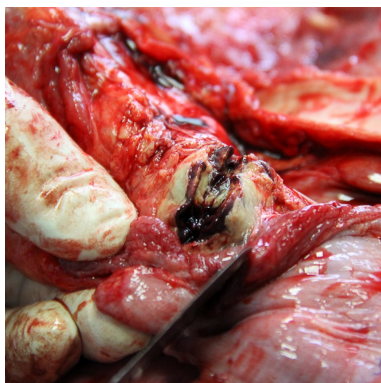

Figure 2 Hemorrhages in the adrenal gland.

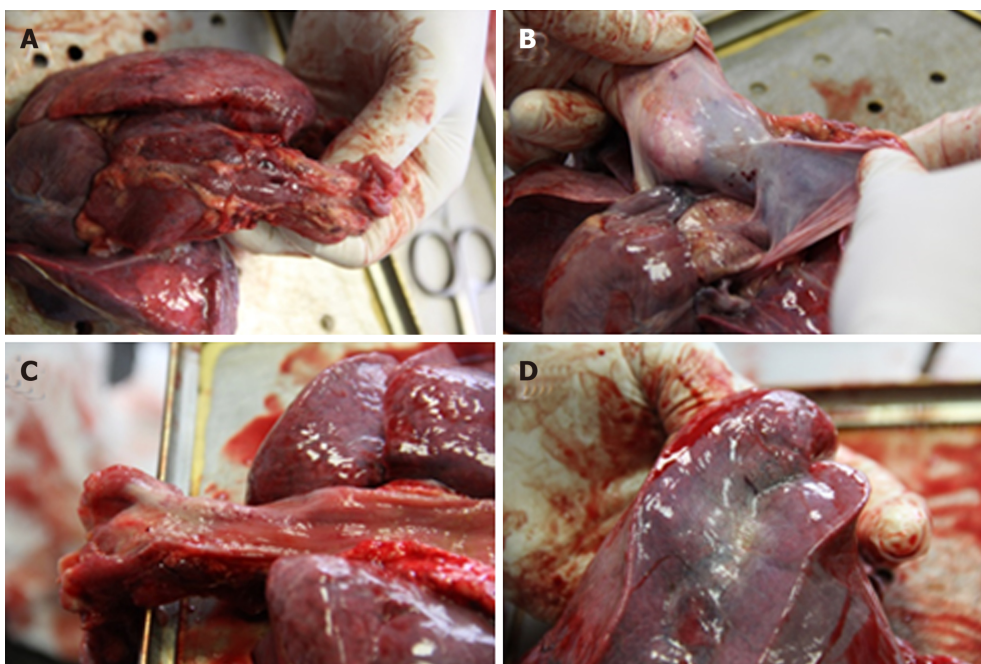


Figure 3 Petechiae. A: Thymus; B: Pericardial sack; C: Esophageal mucosa; D: Subpleural.

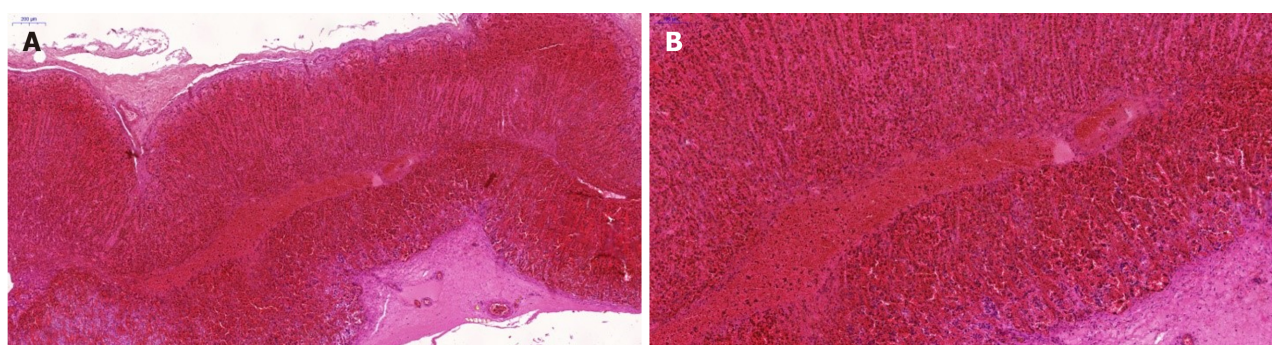


Figure 4 Adrenal gland, hematoxylin and eosin. A: 50 ×; B: 100 ×.

## REFERENCES

- 1 Albrecht A, Hryniewicz W, Kuch A, Przyjalkowski W, Skoczyńska A, Szenborn L. Rekomendacje postępowania w zakażeniach bakteryjnych ośrodkowego układu nerwowego [Recommendations for the management of bacterial infections within the central nervous system]. Warsaw: National Medicines Institute 2012; Available from: URL: <http://antybiotyki.edu.pl/wp-content/uploads/Rekomendacje/reko->

- [mendacje-ukl-nerwowo\\_2011.pdf](#)
- 2 **Ridpath AD**, Halse TA, Musser KA, Wroblewski D, Paddock CD, Shieh WJ, Pasquale-Styles M, Scordi-Bello I, Del Rosso PE, Weiss D. Postmortem diagnosis of invasive meningococcal disease. *Emerg Infect Dis* 2014; **20**: 453-455 [PMID: [24565379](#) DOI: [10.3201/eid2003.131245](#)]
  - 3 **Hamilton D**, Harris MD, Foweraker J, Gresham GA. Waterhouse-Friderichsen syndrome as a result of non-meningococcal infection. *J Clin Pathol* 2004; **57**: 208-209 [PMID: [14747454](#) DOI: [10.1036/JCP.2003.9936](#)]
  - 4 **Kim KS**. Acute bacterial meningitis in infants and children. *Lancet Infect Dis* 2010; **10**: 32-42 [PMID: [20129147](#) DOI: [10.1016/S1473-3099\(09\)70306-8](#)]
  - 5 **Tattoli L**, Marzullo A, Di Vella G, Solarino B. Postmortem detection of Neisseria meningitidis in case of Waterhouse-Friderichsen syndrome from fulminant meningococcal disease in an adult patient. *Rom J Leg Med* 2015; **23**: 29-32 [DOI: [10.4323/rjlm.2015.29](#)]
  - 6 **Bollero D**, Stella M, Gangemi EN, Spaziante L, Nuzzo J, Sigauco G, Enrichens F. Purpura fulminans in meningococcal septicaemia in an adult: a case report. *Ann Burns Fire Disasters* 2010; **23**: 43-47 [PMID: [21991197](#)]
  - 7 **Rouphael NG**, Stephens DS. Neisseria meningitidis: biology, microbiology, and epidemiology. *Methods Mol Biol* 2012; **799**: 1-20 [PMID: [21993636](#) DOI: [10.1007/978-1-61779-346-2\\_1](#)]
  - 8 **Rorat M**, Jurek T, Simon K. Post-mortem diagnostics in cases of sepsis. Part 1. Aetiology, epidemiology and microbiological tests. *Arch Med Sadowej Kryminol* 2014; **64**: 280-294 [PMID: [25909922](#) DOI: [10.5114/amsik.2014.50532](#)]
  - 9 **Rorat M**, Jurek T, Simon K. Post-mortem diagnostics in cases of sepsis. Part 2. Biochemical and morphological examinations. *Arch Med Sadowej Kryminol* 2015; **65**: 55-66 [PMID: [26007162](#)]
  - 10 **Ploy MC**, Garnier F, Languelin J, Fermeaux V, Martin C, Denis F. Interest of postmortem-collected specimens in the diagnosis of fulminant meningococcal sepsis. *Diagn Microbiol Infect Dis* 2005; **52**: 65-66 [PMID: [15878445](#) DOI: [10.1016/j.diagmicrobio.2004.12.012](#)]
  - 11 **Bryant PA**, Li HY, Zaia A, Griffith J, Hogg G, Curtis N, Carapetis JR. Prospective study of a real-time PCR that is highly sensitive, specific, and clinically useful for diagnosis of meningococcal disease in children. *J Clin Microbiol* 2004; **42**: 2919-2925 [PMID: [15243039](#) DOI: [10.1128/JCM.42.7.2919-2925.2004](#)]
  - 12 **Weber MA**, Klein NJ, Hartley JC, Lock PE, Malone M, Sebire NJ. Infection and sudden unexpected death in infancy: a systematic retrospective case review. *Lancet* 2008; **371**: 1848-1853 [PMID: [18514728](#) DOI: [10.1016/S0140-6736\(08\)60798-9](#)]
  - 13 **Morris J**, Harrison L, Partridge S. Practical and theoretical aspects of postmortem bacteriology. *Curr Diagn Pathol* 2007; **13**: 65-74 [DOI: [10.1016/j.cdip.2006.07.005](#)]
  - 14 **Challener RC**, Morrissey AM, Jacobs MR. Postmortem diagnosis of meningococemia by detection of capsular polysaccharides. *J Forensic Sci* 1988; **33**: 336-346 [PMID: [3131479](#) DOI: [10.1016/0379-0738\(88\)90108-9](#)]
  - 15 **Palmiere C**, Vanhaebost J, Ventura F, Bonsignore A, Bonetti LR. Cerebrospinal fluid PCR analysis and biochemistry in bodies with severe decomposition. *J Forensic Leg Med* 2015; **30**: 21-24 [PMID: [25623190](#) DOI: [10.1016/j.jflm.2014.12.012](#)]
  - 16 **Maujean G**, Guinet T, Fanton L, Malicier D. The interest of postmortem bacteriology in putrefied bodies. *J Forensic Sci* 2013; **58**: 1069-1070 [PMID: [23551205](#) DOI: [10.1111/1556-4029.12155](#)]

**P- Reviewer:** Fiore M, Krishnan T, Pourshafie MR

**S- Editor:** Ji FF **L- Editor:** A **E- Editor:** Bian YN





Published By Baishideng Publishing Group Inc  
7041 Koll Center Parkway, Suite 160, Pleasanton, CA 94566, USA  
Telephone: +1-925-2238242  
Fax: +1-925-2238243  
E-mail: [bpgoffice@wjgnet.com](mailto:bpgoffice@wjgnet.com)  
Help Desk: <https://www.f6publishing.com/helpdesk>  
<https://www.wjgnet.com>

