


World Journal of *Clinical Cases*

World J Clin Cases 2019 March 26; 7(6): 691-808



**REVIEW**

- 691 Effects of apoptosis on liver aging
Hu SJ, Jiang SS, Zhang J, Luo D, Yu B, Yang LY, Zhong HH, Yang MW, Liu LY, Hong FF, Yang SL

MINIREVIEWS

- 705 Liver involvement in the drug reaction, eosinophilia, and systemic symptoms syndrome
Martinez-Cabriaes SA, Shear NH, Gonzalez-Moreno EI

ORIGINAL ARTICLE**Retrospective Cohort Study**

- 717 Surgical method choice and coincidence rate of pathological diagnoses in transduodenal ampullectomy: A retrospective case series study and review of the literature
Liu F, Cheng JL, Cui J, Xu ZZ, Fu Z, Liu J, Tian H

Retrospective Study

- 727 Individualized minimally invasive treatment for adult testicular hydrocele: A pilot study
Lin L, Hong HS, Gao YL, Yang JR, Li T, Zhu QG, Ye LF, Wei YB

Observational Study

- 734 Successful totally transthoracic echocardiography guided transcatheter device closure of atrial septal defect in pregnant women
Chen Q, Cao H, Zhang GC, Chen LW, Xu F

CASE REPORT

- 742 Cardiac amyloidosis: A case report and review of literature
Taiwo AA, Alapati L, Movahed A
- 753 Successful treatment with hysteroscopy for infertility due to isthmocele and hydrometra secondary to cesarean section: A case report
López Rivero LP, Jaimes M, Camargo F, López-Bayghen E
- 759 *Aeromonas veronii* biovar *veronii* and sepsis-infrequent complication of biliary drainage placement: A case report
Monti M, Torri A, Amadori E, Rossi A, Bartolini G, Casadei C, Frassinetti GL

- 765** Induction chemotherapy with docetaxel, cisplatin and fluorouracil followed by concurrent chemoradiotherapy for unresectable sinonasal undifferentiated carcinoma: Two cases of report
Watanabe S, Honma Y, Murakami N, Igaki H, Mori T, Hirano H, Okita N, Shoji H, Iwasa S, Takashima A, Kato K, Kobayashi K, Matsumoto F, Yoshimoto S, Itami J, Boku N
- 773** Lump type crossed fused renal ectopia with bilateral vesicoureteral reflux: A case report
Choi T, Yoo KH, Song R, Lee DG
- 778** Multiple gastric angiolipomas: A case report
Lou XH, Chen WG, Ning LG, Chen HT, Xu GQ
- 785** Primary hepatic follicular dendritic cell sarcoma: A case report
Chen HM, Shen YL, Liu M
- 792** Effective chemotherapy for submandibular gland carcinoma ex pleomorphic adenoma with lung metastasis after radiotherapy: A case report
Chen ZY, Zhang Y, Tu Y, Zhao W, Li M
- 798** Photodynamic therapy as salvage therapy for residual microscopic cancer after ultra-low anterior resection: A case report
Zhang SQ, Liu KJ, Yao HL, Lei SL, Lei ZD, Yi WJ, Xiong L, Zhao H
- 805** Unexplained abdominal pain due to a fish bone penetrating the gastric antrum and migrating into the neck of the pancreas: A case report
Xie R, Tuo BG, Wu HC

ABOUT COVER

Editorial Board Member of *World Journal of Clinical Cases*, Edison I O Vidal, MD, PhD, Associate Professor, Internal Medicine Department, Sao Paulo State University (UNESP), Botucatu 18618-687, SP, Brazil

AIMS AND SCOPE

World Journal of Clinical Cases (*World J Clin Cases*, *WJCC*, online ISSN 2307-8960, DOI: 10.12998) is a peer-reviewed open access academic journal that aims to guide clinical practice and improve diagnostic and therapeutic skills of clinicians.

The primary task of *WJCC* is to rapidly publish high-quality Case Report, Clinical Management, Editorial, Field of Vision, Frontier, Medical Ethics, Original Articles, Meta-Analysis, Minireviews, and Review, in the fields of allergy, anesthesiology, cardiac medicine, clinical genetics, clinical neurology, critical care, dentistry, dermatology, emergency medicine, endocrinology, family medicine, gastroenterology and hepatology, etc.

INDEXING/ABSTRACTING

The *WJCC* is now indexed in PubMed, PubMed Central, Science Citation Index Expanded (also known as SciSearch®), and Journal Citation Reports/Science Edition. The 2018 Edition of Journal Citation Reports cites the 2017 impact factor for *WJCC* as 1.931 (5-year impact factor: N/A), ranking *WJCC* as 60 among 154 journals in Medicine, General and Internal (quartile in category Q2).

RESPONSIBLE EDITORS FOR THIS ISSUE

Responsible Electronic Editor: Yun-Xiaojian Wu Proofing Editorial Office Director: Jin-Lei Wang

NAME OF JOURNAL

World Journal of Clinical Cases

ISSN

ISSN 2307-8960 (online)

LAUNCH DATE

April 16, 2013

FREQUENCY

Semimonthly

EDITORS-IN-CHIEF

Dennis A Bloomfield, Sandro Vento

EDITORIAL BOARD MEMBERS

<https://www.wjnet.com/2307-8960/editorialboard.htm>

EDITORIAL OFFICE

Jin-Lei Wang, Director

PUBLICATION DATE

March 26, 2019

COPYRIGHT

© 2019 Baishideng Publishing Group Inc

INSTRUCTIONS TO AUTHORS

<https://www.wjnet.com/bpg/gerinfo/204>

GUIDELINES FOR ETHICS DOCUMENTS

<https://www.wjnet.com/bpg/GerInfo/287>

GUIDELINES FOR NON-NATIVE SPEAKERS OF ENGLISH

<https://www.wjnet.com/bpg/gerinfo/240>

PUBLICATION MISCONDUCT

<https://www.wjnet.com/bpg/gerinfo/208>

ARTICLE PROCESSING CHARGE

<https://www.wjnet.com/bpg/gerinfo/242>

STEPS FOR SUBMITTING MANUSCRIPTS

<https://www.wjnet.com/bpg/GerInfo/239>

ONLINE SUBMISSION

<https://www.f6publishing.com>

***Aeromonas veronii* biovar *veronii* and sepsis-infrequent complication of biliary drainage placement: A case report**

Manlio Monti, Arianna Torri, Elena Amadori, Alice Rossi, Giulia Bartolini, Chiara Casadei, Giovanni Luca Frassinetti

ORCID number: Manlio Monti (0000-0003-2982-1382); Arianna Torri (0000-0003-2354-9090); Elena Amadori (0000-0002-5279-0193); Alice Rossi (0000-0002-9126-9229); Giulia Bartolini (0000-0001-6190-0350); Chiara Casadei (0000-0003-2467-749X); Giovanni Luca Frassinetti (0000-0002-0277-5622).

Author contributions: Monti M conceived and designed the study; Amadori E, Rossi A and Bartolini G, Casadei C and Frassinetti GL carried out the literature search; Torri A performed the blood cultures and carried out the antibiotic susceptibility test; Monti M wrote the first draft of the manuscript and the other authors contributed to finalizing the present version of the paper; all authors approved the manuscript for publication.

Informed consent statement: The study was carried out in accordance with the principles laid down in the Declaration of Helsinki. Ethics approval was not necessary for this work due to its design (Case Report). Written informed consent was obtained from the patient.

Conflict-of-interest statement: None of the authors has conflict of interest with this submission.

CARE Checklist (2016) statement: The authors have read the CARE Checklist (2016), and the manuscript was prepared and revised according to the CARE Checklist (2016).

Manlio Monti, Giulia Bartolini, Chiara Casadei, Giovanni Luca Frassinetti, Department of Medical Oncology, Istituto Scientifico Romagnolo per lo Studio e la Cura dei Tumori (IRST) IRCCS, Meldola 47014, Italy

Arianna Torri, Unit of Microbiology, Wide Catchment Area of Romagna Laboratory, Cesena 47522, Italy

Elena Amadori, Alice Rossi, Radiology Unit, Istituto Scientifico Romagnolo per lo Studio e la Cura dei Tumori (IRST) IRCCS, Meldola 47014, Italy

Corresponding author: Manlio Monti, MD, Doctor, Department of Medical Oncology, Istituto Scientifico Romagnolo per lo Studio e la Cura dei Tumori (IRST) IRCCS, Via P. Maroncelli 40, Meldola 47014, Italy. manlio.monti@irst.emr.it

Telephone: +39-54-3739100

Fax: +39-54-3739151

Abstract

BACKGROUND

Aeromonas species are uncommon pathogens in biliary sepsis and cause substantial mortality in patients with impaired hepatobiliary function. Asia has the highest incidence of infection from *Aeromonas*, whereas cases in the west are rare.

CASE SUMMARY

We report the case of a 64-year-old woman with advanced pancreatic cancer and jaundice who manifested fever, abdominal pain, severe thrombocytopenia, anemia and kidney failure following the insertion of a percutaneous transhepatic biliary drainage. Blood culture results revealed the presence of *Aeromonas veronii* biovar *veronii* (*A. veronii* biovar *veronii*). After antibiotic therapy and transfusions, the life-threatening clinical conditions of the patient improved and she was discharged.

CONCLUSION

This was a rare case of infection, probably the first to be reported in West countries, caused by *A. veronii* biovar *veronii* following biliary drainage. A finding of *Aeromonas* must alert clinician to the possibility of severe sepsis.

Key words: *Aeromonas veronii* biovar *veronii*; *Aeromonas*; Pancreatic cancer; Cholangitis; Sepsis; Biliary tract infection; Case report

Open-Access: This article is an open-access article which was selected by an in-house editor and fully peer-reviewed by external reviewers. It is distributed in accordance with the Creative Commons Attribution Non Commercial (CC BY-NC 4.0) license, which permits others to distribute, remix, adapt, build upon this work non-commercially, and license their derivative works on different terms, provided the original work is properly cited and the use is non-commercial. See: <http://creativecommons.org/licenses/by-nc/4.0/>

Manuscript source: Unsolicited manuscript

Received: December 12, 2018

Peer-review started: December 12, 2018

First decision: January 5, 2019

Revised: January 21, 2019

Accepted: January 29, 2019

Article in press: January 30, 2019

Published online: March 26, 2019

P-Reviewer: Kai K, Rong GH, Sergi C

S-Editor: Yan JP

L-Editor: A

E-Editor: Wu YXJ



©The Author(s) 2019. Published by Baishideng Publishing Group Inc. All rights reserved.

Core tip: *Aeromonas* infection is fairly infrequent, and cholangitis caused by this species represents around 3% of all cases of bile duct infection. The bacterium appears to have high incidence in Asia. The infection may have a dramatic presentation. Our case report describes one of the few cases of cholangitis by *Aeromonas* to be reported in Western countries and, in particular, the first to be attributed to *Aeromonas veronii biovar veronii* after the positioning of biliary drainage. Antibiotic prophylaxis should be considered a priori. The finding of an infection from *Aeromonas* should alert the clinician to the possibility of severe sepsis.

Citation: Monti M, Torri A, Amadori E, Rossi A, Bartolini G, Casadei C, Frassinetti GL. *Aeromonas veronii biovar veronii* and sepsis-infrequent complication of biliary drainage placement: A case report. *World J Clin Cases* 2019; 7(6): 759-764
URL: <https://www.wjnet.com/2307-8960/full/v7/i6/759.htm>
DOI: <https://dx.doi.org/10.12998/wjcc.v7.i6.759>

INTRODUCTION

Aeromonas species are small, ubiquitous gram-negative bacilli isolated from a variety of environmental sources including water, seafood, meat and vegetables, and occasionally from the feces of healthy individuals. A review by Janda and Abbot^[1] listed 21 published *Aeromonas* species. This bacterium is a potential pathogen in gastroenteritis and in a wide spectrum of extraintestinal infections, including wound infection pneumonia, hemolytic uremic syndrome (HUS), peritonitis, biliary sepsis and septicemia^[2]. *Aeromonas* plays an important role in biliary duct infection in South East Asia because recurrent pyogenic cholangitis is prevalent in this region. The condition is characterized by multiple intrahepatic bile duct stones, strictures and dilations and recurrent attacks of septicemia. The consumption of raw seafood contaminated by the *Aeromonas* species may also contribute to the development of septicemia. *Aeromonas*, although not a common pathogen in biliary sepsis, has an overall mortality rate of 25% to 75%^[3]. According to some case reports, this species causes around 3% of all cases of cholangitis in Asia^[4] and even fewer cases in the Western world. We describe a case of severe sepsis from *Aeromonas veronii biovar veronii* (*A. veronii biovar veronii*) following biliary drainage in an Italian patient with advanced pancreatic cancer.

CASE PRESENTATION

Chief complaints

In August 2017 a 64-year-old Caucasian woman was urgently admitted to the Oncology Ward of our institute with jaundice. She had also been suffering from increasing dyspepsia and asthenia for the previous few weeks.

History of past illness

In August 2013 the patient had undergone pancreaticoduodenectomy and cholecystectomy for pancreatic adenocarcinoma with positive surgical margins. Between May 2014 and July 2017, she underwent three lines of palliative chemotherapy.

Personal and family history

Her personal and family history did not reveal anything significant.

Physical examination upon admission

Physical examination upon admission was unremarkable except for jaundice.

Laboratory examinations

Laboratory exams showed a white blood cell count of $8.51 \times 10^9/L$ (reference range 4.0-10.0) with 74.3% neutrophils, 17.4% lymphocytes and 7.6% monocytes. Hemoglobin was 11.9 g/dL (12-15.5) and platelets $374 \times 10^9/L$ (140-400). The prothrombin time (international normalized ratio, INR) was 1.31 (0.80-1.20) and the

activated partial thromboplastin time ratio was 0.94 (0.8-1.2). Electrolyte and renal function tests were normal. In particular, creatinine was 0.73 mg/dL (0.5-1.0) and velocity of glomerular filtration (eGFR) was 87 mL/min/1.73m², while protein C reaction (PCR) was 509 mg/dL (< 5.0). Conversely, total bilirubin was 16.39 mg/dL (< 1.20), direct bilirubin 13.61 mg/dL (< 0.30), aspartate transaminase 183 U/L (< 32), alanine transaminase 169 U/L (< 33), alkaline phosphatase 543 U/L (35-104), gammaGT 1019 (5-36) and lactate dehydrogenase 247 U/L (135-214). Tests for hepatitis B and C were negative, as was rectal screening for multiresistant gram-negative bacteria performed as a precautionary measure when the patient was admitted.

Imaging examinations

A total body computed tomography (CT) scan confirmed the metastases in the lungs, chest, abdominal lymph nodes, liver and hepatic hilar area (Figure 1). There was also marked ectasia of the intrahepatic bile ducts of both hemisystems. Six d after admission the patient underwent difficult placement of a percutaneous transhepatic external biliary catheter in the left hemisystem. A week later the catheter was checked for leakage because total bilirubin had not fallen below 11.8 mg/dL and was found to have become dislodged from the liver. The procedure was repeated and a new internal-external device was inserted. The following day the patient experienced severe abdominal pain, in particular in the upper right quadrant, with negative Blumberg's and positive Murphy's signs. An abdominal CT scan excluded acute radiological or surgical complications. The patient also had an isolated episode of fever (38.2 °C), and complained of left chest pain. She felt restless but fatigued at the same time, and there was an evident worsening of her clinical conditions. Blood cultures were performed on blood drawn from the peripheral and central venous catheters. The patient was immediately given paracetamol 1000 mg and started empiric intravenous antibiotic therapy with levofloxacin 500 mg/d for five d. Intravenous fluids were increased to 1500 mL/d. The following day oral steroid therapy with prednisone 25 mg was substituted with intravenous dexamethasone 8 mg. Two d after the insertion of the new catheter, hemoglobin was 10.5 g/dL, white blood cell count $13.65 \times 10^9/L$, platelets $29 \times 10^9/L$, creatinine 1.93 mg/dL and eGFR 27 mL/min/1.73/m². The clinical chemistry laboratory noted that the creatinine value of 1.93 mg/dL was probably underestimated because of the presence of jaundice. The next day hemoglobin was 10.6 g/dL, white blood cell count $9.13 \times 10^9/L$, platelets $14 \times 10^9/L$, creatinine 1.11 mg/dL and eGFR 52 mL/min/1.73m². Given the worsening thrombocytopenia, the patient received a pool of platelets and, when the blood culture results revealed the presence of *A. veronii biovar veronii* [sensitive to amikacin, minimal inhibitory concentration (MIC) ≤ 2 ; cefotaxime, MIC ≤ 1 ; ceftazidime, MIC ≤ 1 ; gentamycin, MIC ≤ 1 ; and ciprofloxacin, MIC ≤ 0.25], moderately sensitive to imipenem and piperacillin/tazobactam, and resistant to amoxicillin/clavulanic acid], levofloxacin was replaced with ceftazidime 2 g three times/d. We excluded disseminated intravascular coagulation (DIC) because the INR was 1.21 (0.8-1.2), fibrinogen 846 mg/dL (150-400), D-dimer 536 µg/L (cut-off for thrombosis 200 µg/L) and antithrombin 91% (70-150) while PCR was 84 mg/dL. A cytomegalovirus blood test was < 120 IU/mL and thus considered negative, while second-level hematochemical exams revealed anisocytosis, poikilocytosis, slight erythrocyte fragmentation and some myelocytes. Frequent blood tests were performed to exclude DIC. The number of platelets progressively increased but hemoglobin decreased to 7.7 g/dL and Coombs test was negative. The patient thus received a blood transfusion. Total bilirubin decreased to 7.61 mg/dL and the patient's performance status gradually improved.

FINAL DIAGNOSIS

The patient with advanced pancreatic cancer and biliary obstruction developed sepsis caused by *A. veronii biovar veronii*.

TREATMENT

The patient with sepsis was treated with antibiotic therapy, first with levofloxacin then with ceftazidime and platelet and blood transfusions.

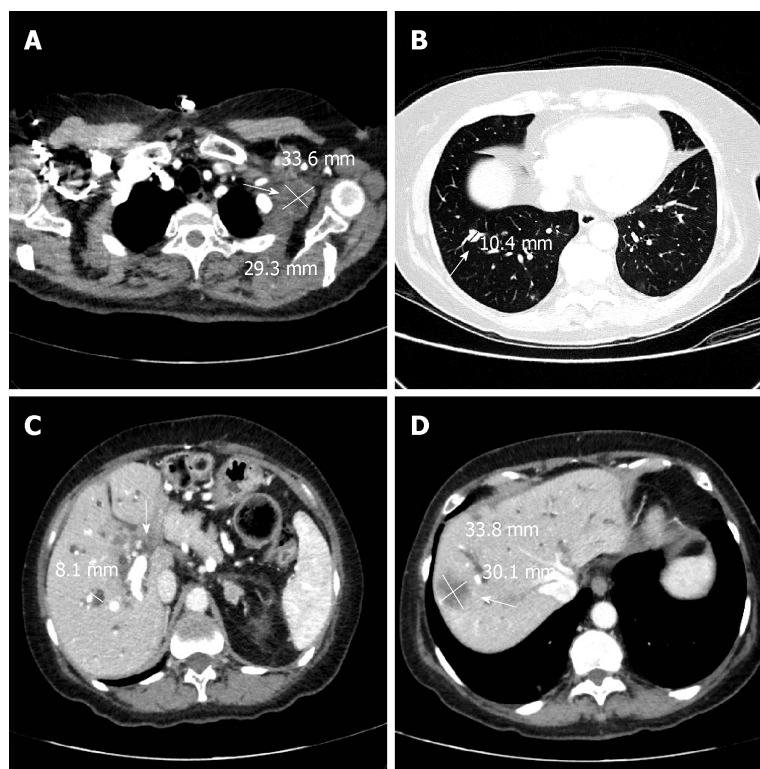


Figure 1 A total body computed tomography scan confirmed the metastases in the lungs, chest, abdominal lymph nodes, liver and hepatic hilar area. A: Arrow showing pathological lymphadenopathy in the left axilla (34 mm × 29 mm); B: Arrow showing secondary lesion of the pulmonary parenchyma in the lower right lobe (10 mm); C: Arrow showing pathological tissue enveloping the hepatic hilum; dilated intrahepatic bile ducts in right lobe (8 mm); D: Arrow showing secondary lesion to the VIII segment of the liver.

OUTCOME AND FOLLOW-UP

The patient was discharged in stable conditions after 10 d of ceftazidime to continue the best supportive care at home, including a further 4 d of the antibiotic therapy. The patient was alive at a distance of one mo from discharge but then was lost to follow-up.

DISCUSSION

Of the numerous *Aeromonas* species, few have been related unquestionably to human extraintestinal infections^[5] by virtue of their isolation in pure culture from sterile sites. Sepsis is perhaps the most relevant *Aeromonas* infection in terms of severity and frequency and is associated predominantly with several underlying diseases. Individuals with hepatobiliary diseases are particularly susceptible to the infections^[6,7]. In patients with hematologic diseases or solid tumors, antineoplastic drugs may induce alteration of gastrointestinal mucosa and allow transmigration of colonized *Aeromonas* species from the bowel into the circulatory system^[8]. The role of *A. veronii* biovar *veronii* in human sepsis has been described very rarely. Abbott *et al*^[9] reported the first case of *A. veronii* biovar *veronii* sepsis in an elderly man with advanced colorectal cancer who developed jaundice. The patient had multisystem organ failure two d after admission and died. In a subsequent report^[10], *A. veronii* biovar *veronii* was responsible for bacteraemia and necrotizing fasciitis in a diabetic patient also affected by a *Aeromonas veronii* biovar *sobria* urinary tract infection. The potential portals of entry for *Aeromonas* bacteria are the gastrointestinal tract, skin lesions, previous surgery or local trauma in an aqueous environment. The pathogenic mechanism of *Aeromonas* is multifactorial because many virulence factors are involved, including the production of cytotoxins. These toxins can cause diarrhea^[11] or hemorrhagic colitis, and may play a role in HUS^[12]. In our patient, the *A. veronii* biovar *veronii* infection was responsible for monomicrobial cholangitis and was probably caused by the insertion of a percutaneous transhepatic biliary catheter. Few cases of sepsis from *Aeromonas* have been described in Western countries. Dryden and

Munro^[13] described 13 cases of *Aeromonas*-related septicemia (10 from *Aeromonas sobria* and 3 from *Aeromonas hydrophila*), some of which had biliary tract as the primary site of infection. In the United States, Clark and Chenoweth^[14] reported 15 cases of *Aeromonas* infection of the hepatobiliary system but none were related to *A. veronii biovar veronii*. In France, Doudier et al^[15] described 2 cases of septicemia caused by *Aeromonas caviae* and *Aeromonas hydrophila* following the placement of transhepatic biliary drainage.

Of note, the routine prophylaxis with ampicillin-sulbactam (or clindamycin and gentamycin for penicillin-allergic patients) before the percutaneous biliary drainage procedure was not done in our patient, an oversight on our part. The patient did not recall having had any contact with potentially contaminated water or food products before admission to hospital, she had not traveled abroad in the recent past, and there were no other cases of this infection in the hospital. The rapid manifestation of symptoms after the second drainage would thus seem to indicate a correlation with the invasive procedure.

The abdominal pain, fever and laboratory alterations in our patient were attributable to sepsis. Although highly improbable, we also considered HUS in the differential diagnosis. Only a few cases of HUS from *Aeromonas* have been described worldwide, with diarrhea as the common feature and sometimes the need for dialysis or hemofiltration. We were unable to confirm or refute HUS because specific laboratory tests for the condition such as polymerase chain reaction assay for shiga-like toxin genes and verotoxin test were not routinely performed.

Patients with *Aeromonas* are susceptible to aminoglycosides, quinolones, cotrimoxazole and aztreonam, but are resistant to broad-spectrum cephalosporins because *Aeromonas* has a propensity to produce at least 3 β -lactamases^[1]. We initially used levofloxacin because the patient recalled having had a positive allergic reaction to an antibiotic in the past but could not remember its name. However, she had previously taken levofloxacin without problems. In our case *Aeromonas veronii* was resistant to amoxicillin/clavulanic acid and moderately sensitive to imipenem. Of note, Sánchez-Céspedes^[16] reported a resistance to imipenem in case of *Aeromonas veronii biovar sobria*, which should alert clinicians to the possible emergence of multidrug-resistance.

We describe a case of monomicrobial infection, cholangitis and sepsis caused by *A. veronii biovar veronii*, a rare event in humans. In fact, as far as we know, this is the first reported case of sepsis from *A. veronii biovar veronii* following biliary drainage in Western countries. It seems logical to hypothesize that the *Aeromonas* infection in our patient was related to the invasive biliary tract procedure which may have facilitated an ascending infection from intestinal bacteria. Our findings confirm the sensitivity of the bacterium to third-generation cephalosporins, aminoglycosides, quinolones, but the moderate sensitivity to imipenem and piperacillin/tazobactam is potentially indicative of future resistance to these antibiotics.

CONCLUSION

Our study highlights that *Aeromonas* infection can lead to life-threatening clinical conditions and significant laboratory alterations. Biliary drainage can cause cholangitis and antibiotic prophylaxis is recommended a priori for this surgical maneuver. The presence of an infection from *Aeromonas* should also alert clinicians to the possibility of severe sepsis.

ACKNOWLEDGEMENTS

The authors thank Gráinne Tierney and Cristiano Verna editorial assistance.

REFERENCES

- 1 Janda JM, Abbott SL. The genus *Aeromonas*: Taxonomy, pathogenicity, and infection. *Clin Microbiol Rev* 2010; **23**: 35-73 [PMID: 20065325 DOI: 10.1128/CMR.00039-09]
- 2 Janda JM, Guthertz LS, Kokka RP, Shimada T. *Aeromonas* species in septicemia: Laboratory characteristics and clinical observations. *Clin Infect Dis* 1994; **19**: 77-83 [PMID: 7948561 DOI: 10.1093/clinids/19.1.77]
- 3 Ko WC, Chuang YC. *Aeromonas* bacteremia: Review of 59 episodes. *Clin Infect Dis* 1995; **20**: 1298-1304 [PMID: 7620014 DOI: 10.1093/clinids/20.5.1298]
- 4 Chan FK, Ching JY, Ling TK, Chung SC, Sung JJ. *Aeromonas* infection in acute suppurative cholangitis: Review of 30 cases. *J Infect* 2000; **40**: 69-73 [PMID: 10762115 DOI: 10.1053/jinf.1999.0594]

- 5 **Janda JM**, Abbott SL. Evolving concepts regarding the genus *Aeromonas*: An expanding Panorama of species, disease presentations, and unanswered questions. *Clin Infect Dis* 1998; **27**: 332-344 [PMID: 9709884 DOI: 10.1086/514652]
- 6 **Serra N**, Di Carlo P, Gulotta G, d' Arpa F, Giammanco A, Colomba C, Melfa G, Fasciana T, Sergi C. Bactibilia in women affected with diseases of the biliary tract and pancreas. A STROBE guidelines-adherent cross-sectional study in Southern Italy. *J Med Microbiol* 2018; **67**: 1090-1095 [PMID: 29975626 DOI: 10.1099/jmm.0.000787]
- 7 **Igbinsola IH**, Igumbor EU, Aghdasi F, Tom M, Okoh AI. Emerging *Aeromonas* species infections and their significance in public health. *ScientificWorldJournal* 2012; **2012**: 625023 [PMID: 22701365 DOI: 10.1100/2012/625023]
- 8 **Ko WC**, Lee HC, Chuang YC, Liu CC, Wu JJ. Clinical features and therapeutic implications of 104 episodes of monomicrobial *Aeromonas* bacteraemia. *J Infect* 2000; **40**: 267-273 [PMID: 10908022 DOI: 10.1053/jinf.2000.0654]
- 9 **Abbott SL**, Serve H, Janda JM. Case of *Aeromonas veronii* (DNA group 10) bacteremia. *J Clin Microbiol* 1994; **32**: 3091-3092 [PMID: 7883912 DOI: 10.1002/jctb.280610415]
- 10 **Hsueh PR**, Teng LJ, Lee LN, Yang PC, Chen YC, Ho SW, Luh KT. Indwelling device-related and recurrent infections due to *Aeromonas* species. *Clin Infect Dis* 1998; **26**: 651-658 [PMID: 9524839 DOI: 10.1086/514587]
- 11 **Sha J**, Kozlova EV, Chopra AK. Role of various enterotoxins in *Aeromonas hydrophila*-induced gastroenteritis: Generation of enterotoxin gene-deficient mutants and evaluation of their enterotoxigenic activity. *Infect Immun* 2002; **70**: 1924-1935 [PMID: 11895956 DOI: 10.1128/IAI.70.4.1924-1935.2002]
- 12 **Palma-Martínez I**, Guerrero-Mandujano A, Ruiz-Ruiz MJ, Hernández-Cortez C, Molina-López J, Bocanegra-García V, Castro-Escarpulli G. Active Shiga-Like Toxin Produced by Some *Aeromonas* spp., Isolated in Mexico City. *Front Microbiol* 2016; **7**: 1522 [PMID: 27725813 DOI: 10.3389/fmicb.2016.01552]
- 13 **Dryden M**, Munro R. *Aeromonas* septicemia: Relationship of species and clinical features. *Pathology* 1989; **21**: 111-114 [PMID: 2812870 DOI: 10.3109/00313028909059546]
- 14 **Clark NM**, Chenoweth CE. *Aeromonas* infection of the hepatobiliary system: Report of 15 cases and review of the literature. *Clin Infect Dis* 2003; **37**: 506-513 [PMID: 12905134 DOI: 10.1086/376629]
- 15 **Doudier B**, Imbert G, Vitton V, Kahn M, La Scola B. *Aeromonas* septicemia: An uncommon complication following placement of transhepatic biliary drainage devices in Europe. *J Hosp Infect* 2006; **62**: 115-116 [PMID: 16099547 DOI: 10.1016/j.jhin.2005.05.004]
- 16 **Sánchez-Céspedes J**, Figueras MJ, Aspiroz C, Aldea MJ, Toledo M, Alperí A, Marco F, Vila J. Development of imipenem resistance in an *Aeromonas veronii* biovar *sobria* clinical isolate recovered from a patient with cholangitis. *J Med Microbiol* 2009; **58**: 451-455 [PMID: 19273640 DOI: 10.1099/jmm.0.47804-0]



Published By Baishideng Publishing Group Inc
7041 Koll Center Parkway, Suite 160, Pleasanton, CA 94566, USA
Telephone: +1-925-2238242
Fax: +1-925-2238243
E-mail: bpgoffice@wjgnet.com
Help Desk: <https://www.f6publishing.com/helpdesk>
<https://www.wjgnet.com>

