


World Journal of *Clinical Cases*

World J Clin Cases 2019 March 26; 7(6): 691-808





REVIEW

- 691 Effects of apoptosis on liver aging
Hu SJ, Jiang SS, Zhang J, Luo D, Yu B, Yang LY, Zhong HH, Yang MW, Liu LY, Hong FF, Yang SL

MINIREVIEWS

- 705 Liver involvement in the drug reaction, eosinophilia, and systemic symptoms syndrome
Martinez-Cabriaes SA, Shear NH, Gonzalez-Moreno EI

ORIGINAL ARTICLE

Retrospective Cohort Study

- 717 Surgical method choice and coincidence rate of pathological diagnoses in transduodenal ampullectomy: A retrospective case series study and review of the literature
Liu F, Cheng JL, Cui J, Xu ZZ, Fu Z, Liu J, Tian H

Retrospective Study

- 727 Individualized minimally invasive treatment for adult testicular hydrocele: A pilot study
Lin L, Hong HS, Gao YL, Yang JR, Li T, Zhu QG, Ye LF, Wei YB

Observational Study

- 734 Successful totally transthoracic echocardiography guided transcatheter device closure of atrial septal defect in pregnant women
Chen Q, Cao H, Zhang GC, Chen LW, Xu F

CASE REPORT

- 742 Cardiac amyloidosis: A case report and review of literature
Taiwo AA, Alapati L, Movahed A
- 753 Successful treatment with hysteroscopy for infertility due to isthmocele and hydrometra secondary to cesarean section: A case report
López Rivero LP, Jaimes M, Camargo F, López-Bayghen E
- 759 *Aeromonas veronii* biovar *veronii* and sepsis-infrequent complication of biliary drainage placement: A case report
Monti M, Torri A, Amadori E, Rossi A, Bartolini G, Casadei C, Frassinetti GL

- 765** Induction chemotherapy with docetaxel, cisplatin and fluorouracil followed by concurrent chemoradiotherapy for unresectable sinonasal undifferentiated carcinoma: Two cases of report
Watanabe S, Honma Y, Murakami N, Igaki H, Mori T, Hirano H, Okita N, Shoji H, Iwasa S, Takashima A, Kato K, Kobayashi K, Matsumoto F, Yoshimoto S, Itami J, Boku N
- 773** Lump type crossed fused renal ectopia with bilateral vesicoureteral reflux: A case report
Choi T, Yoo KH, Song R, Lee DG
- 778** Multiple gastric angiolipomas: A case report
Lou XH, Chen WG, Ning LG, Chen HT, Xu GQ
- 785** Primary hepatic follicular dendritic cell sarcoma: A case report
Chen HM, Shen YL, Liu M
- 792** Effective chemotherapy for submandibular gland carcinoma ex pleomorphic adenoma with lung metastasis after radiotherapy: A case report
Chen ZY, Zhang Y, Tu Y, Zhao W, Li M
- 798** Photodynamic therapy as salvage therapy for residual microscopic cancer after ultra-low anterior resection: A case report
Zhang SQ, Liu KJ, Yao HL, Lei SL, Lei ZD, Yi WJ, Xiong L, Zhao H
- 805** Unexplained abdominal pain due to a fish bone penetrating the gastric antrum and migrating into the neck of the pancreas: A case report
Xie R, Tuo BG, Wu HC

ABOUT COVER

Editorial Board Member of *World Journal of Clinical Cases*, Edison I O Vidal, MD, PhD, Associate Professor, Internal Medicine Department, Sao Paulo State University (UNESP), Botucatu 18618-687, SP, Brazil

AIMS AND SCOPE

World Journal of Clinical Cases (*World J Clin Cases*, *WJCC*, online ISSN 2307-8960, DOI: 10.12998) is a peer-reviewed open access academic journal that aims to guide clinical practice and improve diagnostic and therapeutic skills of clinicians.

The primary task of *WJCC* is to rapidly publish high-quality Case Report, Clinical Management, Editorial, Field of Vision, Frontier, Medical Ethics, Original Articles, Meta-Analysis, Minireviews, and Review, in the fields of allergy, anesthesiology, cardiac medicine, clinical genetics, clinical neurology, critical care, dentistry, dermatology, emergency medicine, endocrinology, family medicine, gastroenterology and hepatology, etc.

INDEXING/ABSTRACTING

The *WJCC* is now indexed in PubMed, PubMed Central, Science Citation Index Expanded (also known as SciSearch®), and Journal Citation Reports/Science Edition. The 2018 Edition of Journal Citation Reports cites the 2017 impact factor for *WJCC* as 1.931 (5-year impact factor: N/A), ranking *WJCC* as 60 among 154 journals in Medicine, General and Internal (quartile in category Q2).

**RESPONSIBLE EDITORS
FOR THIS ISSUE**

Responsible Electronic Editor: Yun-Xiaojian Wu Proofing Editorial Office Director: Jin-Lei Wang

NAME OF JOURNAL

World Journal of Clinical Cases

ISSN

ISSN 2307-8960 (online)

LAUNCH DATE

April 16, 2013

FREQUENCY

Semimonthly

EDITORS-IN-CHIEF

Dennis A Bloomfield, Sandro Vento

EDITORIAL BOARD MEMBERS

<https://www.wjnet.com/2307-8960/editorialboard.htm>

EDITORIAL OFFICE

Jin-Lei Wang, Director

PUBLICATION DATE

March 26, 2019

COPYRIGHT

© 2019 Baishideng Publishing Group Inc

INSTRUCTIONS TO AUTHORS

<https://www.wjnet.com/bpg/gerinfo/204>

GUIDELINES FOR ETHICS DOCUMENTS

<https://www.wjnet.com/bpg/GerInfo/287>

GUIDELINES FOR NON-NATIVE SPEAKERS OF ENGLISH

<https://www.wjnet.com/bpg/gerinfo/240>

PUBLICATION MISCONDUCT

<https://www.wjnet.com/bpg/gerinfo/208>

ARTICLE PROCESSING CHARGE

<https://www.wjnet.com/bpg/gerinfo/242>

STEPS FOR SUBMITTING MANUSCRIPTS

<https://www.wjnet.com/bpg/GerInfo/239>

ONLINE SUBMISSION

<https://www.f6publishing.com>

Unexplained abdominal pain due to a fish bone penetrating the gastric antrum and migrating into the neck of the pancreas: A case report

Rui Xie, Bi-Guang Tuo, Hui-Chao Wu

ORCID number: Rui Xie (0000-0001-7970-5916); Bi-Guang Tuo (0000-0003-3147-3487); Hui-Chao Wu (0000-0003-0740-5273).

Author contributions: Tuo BG and Wu HC are the co-corresponding authors; Xie R managed the patient and collected the data; Tuo BG and Wu HC were responsible for case report design and writing.

Informed consent statement: Written informed consent was obtained.

Conflict-of-interest statement: The authors declare no conflicts of interest.

CARE Checklist (2016) statement: The authors have read the CARE Checklist (2016), and the manuscript was prepared and revised according to the CARE Checklist (2016).

Open-Access: This article is an open-access article which was selected by an in-house editor and fully peer-reviewed by external reviewers. It is distributed in accordance with the Creative Commons Attribution Non Commercial (CC BY-NC 4.0) license, which permits others to distribute, remix, adapt, build upon this work non-commercially, and license their derivative works on different terms, provided the original work is properly cited and the use is non-commercial. See: <http://creativecommons.org/licenses/by-nc/4.0/>

Manuscript source: Unsolicited

Rui Xie, Bi-Guang Tuo, Hui-Chao Wu, Department of Gastroenterology, Affiliated Hospital to Zunyi Medical College, Zunyi 563003, Guizhou Province, China

Corresponding author: Hui-Chao Wu, PhD, Full Professor, Department of Gastroenterology, Affiliated Hospital to Zunyi Medical College, 149 Dalian Road, Zunyi 563003, Guizhou Province, China. wuhuichao_gzzy@aliyun.com
Telephone: +86-851-28609206

Abstract

BACKGROUND

Ingestion of foreign bodies results in gastrointestinal perforation in approximately 1% of patients, and fish bones are the objects that most commonly lead to bowel perforation. When it does occur, the terminal ileum is the most common site of perforation, followed by the duodenal C-loop. However, involvement of the pancreas is very rare. Because clinical symptoms are nonspecific and gastrointestinal perforation may present as only odynophagia or abdominal pain, a definite preoperative diagnosis and clinical intervention may be delayed.

CASE SUMMARY

We report the case of a 32-year-old man who presented to our hospital because of abdominal pain that had worsened over 5 d. He had no significant past history except that he had eaten fish 1 wk previously. Upper endoscopy revealed an irregular submucosal tumor on the front wall of the gastric antrum. Endoscopic ultrasonography and computed tomography showed a fish bone penetrating the gastric antrum and migrating into the neck of the pancreas. The patient underwent laparoscopic surgery and had no complications one week after the operation.

CONCLUSION

A recent history of foreign body ingestion and imaging examinations are helpful for diagnosis of unexplained abdominal pain caused by foreign bodies.

Key words: Unexplained abdominal pain; Fish bone; Gastrointestinal perforation; Pancreas; Case report

©The Author(s) 2019. Published by Baishideng Publishing Group Inc. All rights reserved.

manuscript

Received: December 19, 2018

Peer-review started: December 19, 2018

First decision: January 6, 2019

Revised: January 21, 2019

Accepted: February 26, 2019

Article in press: February 26, 2019

Published online: March 26, 2019

P-Reviewer: Kang KM, Mattar MC

S-Editor: Wang JL

L-Editor: Wang TQ

E-Editor: Wu YXJ


Core tip: Only rare cases of fish bone migration to the pancreas have been described in the literature. We report the case of a 32-year-old man who presented with unexplained abdominal pain due to a fish bone penetrating the gastric antrum and migrating into the neck of the pancreas. Clinical symptoms are nonspecific so that correct diagnosis may be delayed, and imaging examination and endoscopic ultrasonography are reported to be the main diagnostic tools. Laparoscopy is an effective method for identifying and removing the fish bone.

Citation: Xie R, Tuo BG, Wu HC. Unexplained abdominal pain due to a fish bone penetrating the gastric antrum and migrating into the neck of the pancreas: A case report. *World J Clin Cases* 2019; 7(6): 805-808

URL: <https://www.wjgnet.com/2307-8960/full/v7/i6/805.htm>

DOI: <https://dx.doi.org/10.12998/wjcc.v7.i6.805>

INTRODUCTION

Foreign body ingestion is not an uncommon problem in clinical practice, and most ingested foreign bodies (80%-90%) pass spontaneously. Approximately 10%-20% of foreign bodies require an endoscopic procedure, and less than 1% require surgery^[1-3]. Fish bones are the most commonly observed foreign objects; they may cause gastrointestinal perforation due to their sharp edges, and perforation generally occurs at the ileum^[4]. The fish bone may also penetrate the digestive tract and pierce the liver or intra-abdominal area, leading to abscess formation^[5]. In such cases, unexplained abdominal pain is the most frequent clinical symptom. We present the case of a 32-year-old man who was successfully treated by laparoscopic surgery to identify and remove a fish bone that had penetrated the gastric antrum and migrated into the neck of the pancreas, causing abdominal pain.

CASE PRESENTATION

Chief complaints

A 32-year-old male presented to our hospital because of abdominal pain that had worsened over 5 d on March 5, 2018.

Personal and family history and physical examination upon admission

He had rebound tenderness in the upper abdominal quadrant, without hematemesis or black stool, and the patient had no significant past history or family history.

Laboratory examinations

Laboratory tests revealed a white blood cell count of 11.50/mm³ and occult blood in the stool, with no other main abnormalities, including amylase.

Imaging examinations

Upper endoscopy performed on March 6, 2018 revealed an irregular submucosal tumor on the front wall of the gastric antrum with an area of 1.5 cm × 1.7 cm and a depressed appearance of the mucosal surface. Endoscopic ultrasonography showed abnormal and irregular thickening of the stomach wall characterized by a hypoechoic area, and an approximately 3.5-cm linear and hyperechoic lesion protruding through the thickened stomach wall and the neck of the pancreas. Computed tomography (CT) revealed that the thickened front wall of the stomach abutted against the pancreatic body, with a laterally oriented radiopaque foreign body inside (Figure 1). Considering the suspicion of foreign body ingestion, the patient was questioned, and he remembered that he had eaten fish 1 wk previously.

FINAL DIAGNOSIS

Abdominal pain resulting from a fish bone penetration of the stomach and migrating into the pancreas.

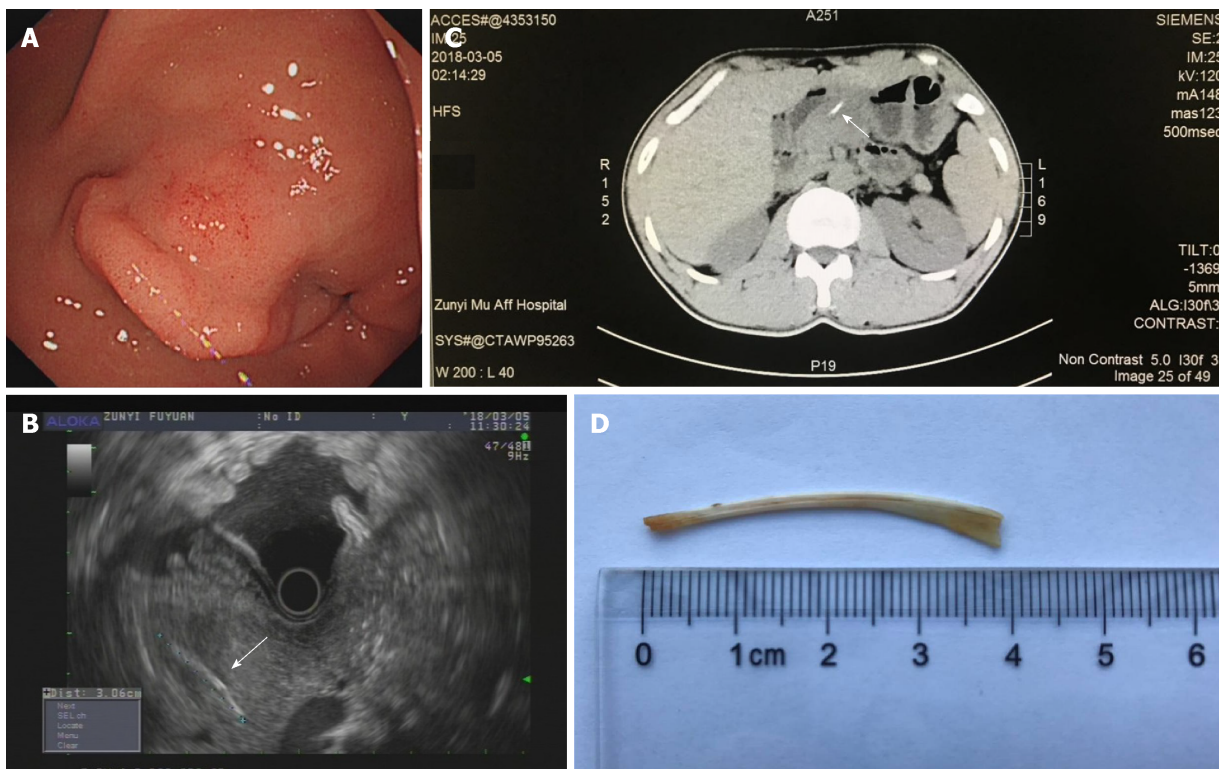


Figure 1 Images of the patient. A: Upper endoscopy revealed an irregular submucosal tumor on the front wall of the gastric antrum; B: Endoscopic ultrasonography showed abnormal and irregular thickening of the stomach wall and an approximately 3.5-cm linear and hyperechoic lesion protruding through the thickened stomach wall and the pancreatic body (arrow); C: Computed tomography image showing a thin, linear, hyperdense structure (arrow) along the stomach wall and pancreatic body; D: Photograph of the fish bone after removal.

TREATMENT

We wanted to cut the mucosa and remove the embedded fish bone by endoscopic submucosal dissection on March 8, 2018, but endoscopic ultrasonography showed that the fish bone was too deep to be easily removed. Finally, the patient underwent laparoscopic surgery seven days after hospital admission (March 12, 2018), which revealed a thickened peritoneum and adhesion between the gastric wall and the pancreatic neck. We carefully separated the stomach wall and the pancreas, and after identifying a penetration of the serosa of the stomach wall, we found a fish bone of approximately 3.5 cm in length pinned in the neck of the pancreas. The fish bone was successfully removed, and a proton-pump inhibitor was routinely used for five days after surgery.

OUTCOME AND FOLLOW-UP

The patient was discharged without any complications and was in good clinical condition one week after the operation, and endoscopic reexamination had not found obvious abnormality one month after the surgery.

DISCUSSION

Unintentional, unconscious ingestion of foreign bodies in adults is usually dietary. Nearly two-thirds of foreign bodies are fish bones, and 75% of ingested foreign bodies become impacted in the oral cavity and laryngopharynx. If impaction does not occur in the upper gastrointestinal tract, the majority of foreign bodies pass asymptotically within a week^[6]. Perforation of the digestive tract by an ingested fish bone is extremely rare (< 1%); when it does occur, the terminal ileum is the most common site of perforation, followed by the duodenal C-loop^[4]. Because patients usually cannot recall any recent history of foreign body ingestion and because clinical symptoms are nonspecific, gastrointestinal perforation may present as only odynophagia or abdominal pain. If the injury is not observed, a definite preoperative

diagnosis is uncertain, and clinical intervention may be delayed.

Numerous reports of ingested fish bones penetrating the digestive tract and migrating to various parts of the chest, liver, or abdominal cavity can be found in the literature. These bones may be responsible for various complications, such as abscess, abdominal cavity infection, mediastinitis, and empyema^[7]. However, to date, only rare cases of fish bone migration to the pancreas have been described in the literature, and this injury may present as a pancreatic mass or suppurative infection of the pancreas^[8,9]. Laboratory analyses are nonspecific, and leukocytosis or increased blood amylase levels are observed. In our case, because of the inflammatory response and the adhesion of the surrounding tissue, perforation occurred in the stomach, where the thicker gut wall and the proximity of the omentum may have sealed the perforation; consequently, the patient did not present the classic symptoms of digestive tract perforation, and immediate correct preoperative diagnosis was very difficult. CT and endoscopic ultrasonography may be helpful for revealing the nature of foreign bodies, the location of migrated foreign bodies, and the relationship with surrounding tissues^[10,11]; therefore, imaging examinations can provide key information for delayed diagnosis of unexplained abdominal pain caused by foreign bodies. Laparoscopy was successfully used to identify the fish bone and extract it. In this case, the patient recovered without any postoperative complications.

CONCLUSION

Ingestion of foreign bodies is a common clinical problem, of which the fish bone is one of the most common; however, involvement of the pancreas is very rare. Perforation occurs in the stomach where a thicker gut wall and proximity of the omentum may seal the perforation, and clinical symptoms are nonspecific. Thus, a definite preoperative diagnosis and clinical intervention may be delayed. CT and endoscopic ultrasonography may be helpful for revealing the nature of foreign bodies, the location of migrated foreign bodies, and the relationship with surrounding tissues. Acute perforations usually require emergency surgery when the diagnosis becomes apparent. Laparoscopic surgery is the most effective option, and disease outcome is generally good after treatment.

REFERENCES

- 1 **Webb WA.** Management of foreign bodies of the upper gastrointestinal tract: update. *Gastrointest Endosc* 1995; **41**: 39-51 [PMID: [7698623](#) DOI: [10.1016/S0016-5107\(95\)70274-1](#)]
- 2 **Ginsberg GG.** Management of ingested foreign objects and food bolus impactions. *Gastrointest Endosc* 1995; **41**: 33-38 [PMID: [7698622](#) DOI: [10.1016/S0016-5107\(95\)70273-3](#)]
- 3 **Schwartz GF, Polsky HS.** Ingested foreign bodies of the gastrointestinal tract. *Am Surg* 1976; **42**: 236-238 [PMID: [1267274](#) DOI: [10.1007/s002689900152](#)]
- 4 **Law WL, Lo CY.** Fishbone perforation of the small bowel: laparoscopic diagnosis and laparoscopically assisted management. *Surg Laparosc Endosc Percutan Tech* 2003; **13**: 392-393 [PMID: [14712103](#) DOI: [10.1097/00129689-200312000-00010](#)]
- 5 **Jimenez-Fuertes M, Moreno-Posadas A, Ruiz-Tovar Polo J, Durán-Poveda M.** Liver abscess secondary to duodenal perforation by fishbone: Report of a case. *Rev Esp Enferm Dig* 2016; **108**: 42 [PMID: [26765235](#)]
- 6 **McCanse DE, Kurchin A, Hinshaw JR.** Gastrointestinal foreign bodies. *Am J Surg* 1981; **142**: 335-337 [PMID: [7283022](#) DOI: [10.1016/0002-9610\(81\)90342-1](#)]
- 7 **Devanesan J, Pisani A, Sharma P, Kazarian KK, Mersheimer WL.** Metallic foreign bodies in the stomach. *Arch Surg* 1977; **112**: 664-665 [PMID: [857769](#) DOI: [10.1001/archsurg.1977.01370050124025](#)]
- 8 **Wang WL, Liu KL, Wang HP.** Clinical challenges and images in GI. Pancreatic abscess resulting from a fish bone penetration of the stomach. *Gastroenterology* 2008; **135**: 1865, 2160 [PMID: [19007782](#) DOI: [10.1053/j.gastro.2008.10.067](#)]
- 9 **Goh BK, Jeyaraj PR, Chan HS, Ong HS, Agasthian T, Chang KT, Wong WK.** A case of fish bone perforation of the stomach mimicking a locally advanced pancreatic carcinoma. *Dig Dis Sci* 2004; **49**: 1935-1937 [PMID: [15628728](#) DOI: [10.1007/s10620-004-9595-y](#)]
- 10 **Akazawa Y, Watanabe S, Nobukiyo S, Iwatake H, Seki Y, Umehara T, Tsutsumi K, Koizuka I.** The management of possible fishbone ingestion. *Auris Nasus Larynx* 2004; **31**: 413-416 [PMID: [15571916](#) DOI: [10.1016/j.anl.2004.09.007](#)]
- 11 **Eliashar R, Dano I, Dangoor E, Braverman I, Sichel JY.** Computed tomography diagnosis of esophageal bone impaction: a prospective study. *Ann Otol Rhinol Laryngol* 1999; **108**: 708-710 [PMID: [10435934](#) DOI: [10.1177/000348949910800717](#)]



Published By Baishideng Publishing Group Inc
7041 Koll Center Parkway, Suite 160, Pleasanton, CA 94566, USA
Telephone: +1-925-2238242
Fax: +1-925-2238243
E-mail: bpgoffice@wjgnet.com
Help Desk: <https://www.f6publishing.com/helpdesk>
<https://www.wjgnet.com>

