

World Journal of *Clinical Cases*

World J Clin Cases 2020 January 6; 8(1): 1-244





REVIEW

- 1 Role of oxysterol-binding protein-related proteins in malignant human tumours
Liu H, Huang S

ORIGINAL ARTICLE

Case Control Study

- 11 Oncogenic role of Tc17 cells in cervical cancer development
Zhang ZS, Gu Y, Liu BG, Tang H, Hua Y, Wang J

Retrospective Study

- 20 Acute distal common bile duct angle is risk factor for post-endoscopic retrograde cholangiopancreatography pancreatitis in beginner endoscopist
Han SY, Kim DU, Lee MW, Park YJ, Baek DH, Kim GH, Song GA
- 29 Three-dimensional computed tomography mapping of posterior malleolar fractures
Su QH, Liu J, Zhang Y, Tan J, Yan MJ, Zhu K, Zhang J, Li C
- 38 Application of a modified surgical position in anterior approach for total cervical artificial disc replacement
Hou WX, Zhang HX, Wang X, Yang HL, Luan XR
- 46 Potential role of the compound Eucommia bone tonic granules in patients with osteoarthritis and osteonecrosis: A retrospective study
Hu CX, Hu KY, Wang JF
- 54 Prognostic factors for overall survival in prostate cancer patients with different site-specific visceral metastases: A study of 1358 patients
Cui PF, Cong XF, Gao F, Yin JX, Niu ZR, Zhao SC, Liu ZL
- 68 Application of multiple Roux-en-Y hepaticojejunostomy reconstruction by formation of bile hilar duct lake in the operation of hilar cholangiocarcinoma
Yang XJ, Dong XH, Chen SY, Wu B, He Y, Dong BL, Ma BQ, Gao P

Observational Study

- 76 Relationship between β -amyloid protein 1-42, thyroid hormone levels and the risk of cognitive impairment after ischemic stroke
Mao L, Chen XH, Zhuang JH, Li P, Xu YX, Zhao YC, Ma YJ, He B, Yin Y

Prospective Study

- 88 Can the wet suction technique change the efficacy of endoscopic ultrasound-guided fine-needle aspiration for diagnosing autoimmune pancreatitis type 1? A prospective single-arm study
Sugimoto M, Takagi T, Suzuki R, Konno N, Asama H, Sato Y, Irie H, Watanabe K, Nakamura J, Kikuchi H, Takasumi M, Hashimoto M, Kato T, Hikichi T, Notohara K, Ohira H

CASE REPORT

- 97 Pembrolizumab - emerging treatment of pulmonary sarcomatoid carcinoma: A case report
Cimpeanu E, Ahmed J, Zafar W, DeMarinis A, Bardarov SS, Salman S, Bloomfield D
- 103 Sclerosing angiomatoid nodular transformation of the spleen, a rare cause for splenectomy: Two case reports
Chikhladze S, Lederer AK, Fichtner-Feigl S, Wittel UA, Werner M, Aumann K
- 110 Postpartum pubic symphysis diastasis-conservative and surgical treatment methods, incidence of complications: Two case reports and a review of the literature
Norvilaite K, Kezeviciute M, Ramasauskaite D, Arlauskienė A, Bartkeviciene D, Uvarovas V
- 120 Use of omental patch and endoscopic closure technique as an alternative to surgery after endoscopic full thickness resection of gastric intestinal stromal tumors: A series of cases
Sachdev AH, Iqbal S, Ribeiro IB, de Moura DTH
- 126 Primary maxillary chondrosarcoma: A case report
Cuevas-González JC, Reyes-Escalera JO, González JL, Sánchez-Romero C, Espinosa-Cristóbal LF, Reyes-López SY, Tovar Carrillo KL, Donohue Cornejo A
- 133 Hyalinizing clear cell carcinoma-a rare entity in the oral cavity: A case report
Donohue-Cornejo A, Paes de Almeida O, Sánchez-Romero C, Espinosa-Cristóbal LF, Reyes-López SY, Cuevas-González JC
- 140 Jejunal cavernous lymphangioma manifested as gastrointestinal bleeding with hypogammaglobulinemia in adult: A case report and literature review
Tan B, Zhang SY, Wang YN, Li Y, Shi XH, Qian JM
- 149 Large pelvic mass arising from the cervical stump: A case report
Zhang K, Jiang JH, Hu JL, Liu YL, Zhang XH, Wang YM, Xue FX
- 157 Mechanical intestinal obstruction due to isolated diffuse venous malformations in the gastrointestinal tract: A case report and review of literature
Li HB, Lv JF, Lu N, Lv ZS
- 168 Two-level percutaneous endoscopic lumbar discectomy for highly migrated upper lumbar disc herniation: A case report
Wu XB, Li ZH, Yang YF, Gu X

- 175 Successful treatment of congenital palate perforation: A case report
Zhang JF, Zhang WB
- 179 Calcitonin-negative neuroendocrine tumor of the thyroid with metastasis to liver-rare presentation of an unusual tumor: A case report and review of literature
Cai HJ, Wang H, Cao N, Huang B, Kong FL, Lu LR, Huang YY, Wang W
- 188 Giant exophytic cystic adenomyosis with a levonorgestrel containing intrauterine device out of the uterine cavity after uterine myomectomy: A case report
Zhou Y, Chen ZY, Zhang XM
- 194 Unusual presentation of bladder neuroblastoma in a child: A case report
Cai JB, Wang JH, He M, Wang FL, Xiong JN, Mao JQ, Li MJ, Zhu K, Liang JW
- 200 Value of dynamic plasma cell-free DNA monitoring in septic shock syndrome: A case report
Liu JP, Zhang SC, Pan SY
- 208 Sarcomatoid intrahepatic cholangiocarcinoma mimicking liver abscess: A case report
Wang Y, Ming JL, Ren XY, Qiu L, Zhou LJ, Yang SD, Fang XM
- 217 Clinical characteristics on manifestation and gene mutation of a transient neonatal cyanosis: A case report
Yuan J, Zhu XP
- 222 Six families with balanced chromosome translocation associated with reproductive risks in Hainan Province: Case reports and review of the literature
Chen YC, Huang XN, Kong CY, Hu JD
- 234 Primary intestinal extranodal natural killer/T-cell lymphoma, nasal type: A case report
Dong BL, Dong XH, Zhao HQ, Gao P, Yang XJ

LETTER TO THE EDITOR

- 242 Cluster headache as a manifestation of a stroke-like episode in a carrier of the MT-ND3 variant m.10158T>C
Finsterer J

ABOUT COVER

Editorial Board Member of *World Journal of Clinical Cases*, Maddalena Zippi, MD, PhD, Doctor, Unit of Gastroenterology and Digestive Endoscopy, Sandro Pertini Hospital, Rome 00157, Italy

AIMS AND SCOPE

The primary aim of *World Journal of Clinical Cases* (WJCC, *World J Clin Cases*) is to provide scholars and readers from various fields of clinical medicine with a platform to publish high-quality clinical research articles and communicate their research findings online.

WJCC mainly publishes articles reporting research results and findings obtained in the field of clinical medicine and covering a wide range of topics, including case control studies, retrospective cohort studies, retrospective studies, clinical trials studies, observational studies, prospective studies, randomized controlled trials, randomized clinical trials, systematic reviews, meta-analysis, and case reports.

INDEXING/ABSTRACTING

The WJCC is now indexed in PubMed, PubMed Central, Science Citation Index Expanded (also known as SciSearch®), and Journal Citation Reports/Science Edition. The 2019 Edition of Journal Citation Reports cites the 2018 impact factor for WJCC as 1.153 (5-year impact factor: N/A), ranking WJCC as 99 among 160 journals in Medicine, General and Internal (quartile in category Q3).

RESPONSIBLE EDITORS FOR THIS ISSUE

Responsible Electronic Editor: *Yan-Xia Xing*

Proofing Production Department Director: *Yun-Xiaojuan Wu*

NAME OF JOURNAL

World Journal of Clinical Cases

ISSN

ISSN 2307-8960 (online)

LAUNCH DATE

April 16, 2013

FREQUENCY

Semimonthly

EDITORS-IN-CHIEF

Dennis A Bloomfield, Bao-Gan Peng, Sandro Vento

EDITORIAL BOARD MEMBERS

<https://www.wjnet.com/2307-8960/editorialboard.htm>

EDITORIAL OFFICE

Jin-Lei Wang, Director

PUBLICATION DATE

January 6, 2020

COPYRIGHT

© 2020 Baishideng Publishing Group Inc

INSTRUCTIONS TO AUTHORS

<https://www.wjnet.com/bpg/gerinfo/204>

GUIDELINES FOR ETHICS DOCUMENTS

<https://www.wjnet.com/bpg/GerInfo/287>

GUIDELINES FOR NON-NATIVE SPEAKERS OF ENGLISH

<https://www.wjnet.com/bpg/gerinfo/240>

PUBLICATION MISCONDUCT

<https://www.wjnet.com/bpg/gerinfo/208>

ARTICLE PROCESSING CHARGE

<https://www.wjnet.com/bpg/gerinfo/242>

STEPS FOR SUBMITTING MANUSCRIPTS

<https://www.wjnet.com/bpg/GerInfo/239>

ONLINE SUBMISSION

<https://www.f6publishing.com>

Retrospective Study

Three-dimensional computed tomography mapping of posterior malleolar fractures

Qi-Hang Su, Juan Liu, Yan Zhang, Jun Tan, Mei-Jun Yan, Kai Zhu, Jin Zhang, Cong Li

ORCID number: Qi-Hang Su (0000-0001-7944-4664); Juan Liu (0000-0002-3944-2477); Yan Zhang (0000-0001-6030-3685); Jun Tan (0000-0001-7617-3256); Mei-Jun Yan (0000-0002-7006-8452); Kai Zhu (0000-0003-2723-3843); Jin Zhang (0000-0002-0281-1654); Cong Li (0000-0002-1552-8284).

Author contributions: Su QH and Liu J contributed equally to this work; Su QH, Liu J, Li C and Tan J designed the research; Su QH, Liu J, Zhang Y, Yan MJ and Zhu K performed the research; Zhang J and Li C contributed new analytic tools; Su QH and Juan Liu analyzed data; and Su QH and Liu J wrote the paper.

Supported by Multicenter Clinical Trial of hUC-MSCs in the Treatment of Late Chronic Spinal Cord Injury, No. 2017YFA0105404; and Key Discipline Construction Project of Pudong Health Bureau of Shanghai, No. PWZxk2017-08.

Institutional review board

statement: Shanghai East Hospital (East Hospital Affiliated to Tongji University) Medical Ethics Committee approved the study protocol, which met the relevant guidelines and regulations of Shanghai Medical Ethics Committee. All included volunteers had signed an informed consent form.

Informed consent statement:

Informed written consent was obtained from the patients for publication of this manuscript and any accompanying images.

Conflict-of-interest statement: The

Qi-Hang Su, Yan Zhang, Jun Tan, Mei-Jun Yan, Kai Zhu, Jin Zhang, Department of Orthopedics, Shanghai East Hospital, Tongji University School of Medicine, Shanghai 200120, China

Juan Liu, Department of the First Clinical Medical School, Shanxi Medical University, Taiyuan 030000, Shanxi Province, China

Jun Tan, Department of Orthopedics, Pinghu Second People's Hospital, Pinghu 314200, Zhejiang Province, China

Cong Li, Department of Trauma Surgery, Shanghai East Hospital, Tongji University School of Medicine, Shanghai 200120, China

Corresponding author: Cong Li, MD, Doctor, Department of Trauma Surgery, Shanghai East Hospital, Tongji University School of Medicine, No. 150, Jimo Road, Pudong New Area, Shanghai 200120, China. 15900549514@163.com

Abstract

BACKGROUND

Posterior malleolar fractures have been reported to occur in < 40% of ankle fractures.

AIM

To reveal the recurrent patterns and characteristics of posterior malleolar fractures by creating fracture maps of the posterior malleolar fractures through the use of computed tomography mapping.

METHODS

A consecutive series of posterior malleolar fractures was used to create three-dimensional reconstruction images, which were oriented and superimposed to fit an ankle model template by both aligning specific biolandmarks and reducing reconstructed fracture fragments. Fracture lines were found and traced in order to generate an ankle fracture map.

RESULTS

This study involved 112 patients with a mean age of 49, comprising 32 pronation-external rotation grade IV fractures and 80 supination-external rotation grade IV fractures according to the Lauge-Hansen classification system. Three-dimensional maps showed that the posterior ankle fracture fragments in the supination-external rotation grade IV group were relatively smaller than those in the pronation-external rotation grade IV group after posterior malleolus fracture. In addition, the distribution analyses on posterior malleolus fracture lines indicated

authors declare that they have no financial or other conflicts of interest in relation to this research and its publication.

Open-Access: This article is an open-access article which was selected by an in-house editor and fully peer-reviewed by external reviewers. It is distributed in accordance with the Creative Commons Attribution Non Commercial (CC BY-NC 4.0) license, which permits others to distribute, remix, adapt, build upon this work non-commercially, and license their derivative works on different terms, provided the original work is properly cited and the use is non-commercial. See: <http://creativecommons.org/licenses/by-nc/4.0/>

Manuscript source: Unsolicited manuscript

Received: October 9, 2019

Peer-review started: October 9, 2019

First decision: November 13, 2019

Revised: November 28, 2019

Accepted: November 30, 2019

Article in press: November 30, 2019

Published online: January 6, 2020

P-Reviewer: Emara KM, Spertalis E

S-Editor: Ma YJ

L-Editor: Filipodia

E-Editor: Qi LL



that the supination-external rotation grade IV group tended to have higher linear density but more concentrated and orderly distribution fractures compared to the pronation-external rotation grade IV group.

CONCLUSION

Fracture maps revealed the fracture characteristics and recurrent patterns of posterior malleolar fractures, which might help to improve the understanding of ankle fracture as well as increase opportunities for follow-up research and aid clinical decision-making.

Key words: Three-dimensional imaging; Maps; Ankle fractures; Computed tomography

©The Author(s) 2020. Published by Baishideng Publishing Group Inc. All rights reserved.

Core tip: With increasing concern over the big data analytics, the distribution map of fracture lines (named fracture mapping) based on three dimensional computed tomography has also been widely used in the orthopedic field to characterize fractures. By creating fracture maps of the posterior malleolar fractures, the study revealed the fracture characteristics and recurrent patterns of posterior malleolar fractures.

Citation: Su QH, Liu J, Zhang Y, Tan J, Yan MJ, Zhu K, Zhang J, Li C. Three-dimensional computed tomography mapping of posterior malleolar fractures. *World J Clin Cases* 2020; 8(1): 29-37

URL: <https://www.wjgnet.com/2307-8960/full/v8/i1/29.htm>

DOI: <https://dx.doi.org/10.12998/wjcc.v8.i1.29>

INTRODUCTION

Ankle fractures account for roughly 10% of all fracture cases, indicating that they are one of the most common injuries in clinical practice and often require surgical intervention^[1]. Posterior malleolar fractures have been reported to occur in < 40% of ankle fractures^[2]. Numerous research findings have demonstrated that the presence of posterior malleolar fragment (PMF) is widely regarded as a critical prognostic factor or outcome indicator following ankle fracture treatment^[2-5]. As previously reported, patients with PMF ankle fractures exhibit poor clinical outcomes in comparison with uni- or bi-malleolar ankle fractures^[2].

Despite this, the optimal treatment procedures for posterior malleolar fractures remain controversial. The first treatment proposed by Regan *et al*^[6] has been applied for decades, in which the fixation of coronoid fractures is based on size and articular involvement. More recently, it has been suggested that the patterns of coronoid fracture, especially their morphological features, are superior compared to the height of coronoid fracture^[7-9]. Similarly, through the use of computed tomography (CT)-based PMF mapping in a subset of patients ($n = 45$), Mangnus *et al*^[10] found that the morphology of PMF can be more crucial than fragment size alone for clinical decision making. Specifically, Haraguchi type II can be considered as an individual fracture pattern. Recently, there has been increasing interest in the morphological characterization of such fractures and reaching a consensus on surgical treatment.

To examine the pathoanatomical or morphological features of PMF, various studies have utilized plain radiograph^[11], CT scan^[12] and three-dimensional (3D) reconstruction CT^[13]. Typically, the lateral view of plain radiograph can be used to assess PMF in ankle fractures. However, the plain radiographic assessment of PMF may be unreliable and inaccurate, even though the estimation of PMF size, including tibial articular surface, is feasible^[14]. Given the rising concerns toward big data analytics, 3D CT-based fracture mapping has been commonly applied in orthopedic fields such as the characterization of scapular and thoracolumbar fractures^[15,16], as initially described by Cole *et al*^[17].

In the present study, our aims were to divide the position and prevalence of fracture lines of a series of posterior malleolar fractures into two groups: supination-external rotation grade IV (SER4) and pronation-external rotation grade IV (PER4) groups, as per the Lauge-Hansen classification system^[18] (Figure 1) and to produce fracture maps through 3D CT mapping. We postulated that the 3D maps of posterior

malleolar fractures would demonstrate the fracture lines, fracture characteristics and recurrent patterns of PMF, which would have the potential to enhance surgeons' understanding and recognition of PMF during diagnostic intervention, preoperative planning, surgery and proper internal fixation. In addition, the 3D maps of medial malleolus and fibula were also obtained from the two groups.

MATERIALS AND METHODS

Patient cohort

A retrospective analysis was undertaken for the CT imaging data of patients diagnosed with PMF in our institution from January 2010 to December 2017. This data was obtained by searching the picture archiving and communication system database. All fractures were classified based on the Lauge-Hansen system^[18], where the first term represents the position of the foot at the time of injury and the second term indicates the external force applied to the foot, in order to create specific fracture patterns. Inclusion criteria were as follows: (1) Participants must have either SER4 injuries or PER4 injuries; (2) Participants without pathological and osteoporotic posterior malleolar fractures; and (3) Good-quality CT images must be available. Participants were excluded if they: (1) Had fracture lines or anatomical landmarks obscured by foreign bodies; and (2) Had severe comminuted fractures in which the conditions of fracture lines were difficult to be determined. The data of participants were evaluated by a highly experienced orthopedic surgeon and senior investigator through the 3D CT rendering in the picture archiving and communication system database.

Fracture mapping

With increasing concern over the big data analytics, the distribution map of fracture lines (named fracture mapping) based on 3D CT has also been widely used in orthopedic fields to characterize fractures^[16]. The raw data in digital imaging and communications in medicine format were recorded by a 64-channel CT scanner (Siemens Somatom Sensation, Siemens, Erlangen, Germany) with the following parameters: 0.5 mm interlayer spacing, 1 mm slice thickness, 200 mA tube current and 120 kV tube voltage. Subsequently, the digital imaging and communications in medicine data for all participants were inputted to Mimics 20.0 software (Materialise, Leuven, Belgium). Through threshold segmentation, the fragments of ankle joint were separated and reconstructed. Following this, the 3D reconstruction model of each fragment was generated using the STL file. The reconstructed model was then inputted to 3-matic 12.0 software (Materialise, Leuven, Belgium) in order to reposition the fragments. This was followed by overlapping and matching with the model of typical ankle through slight adjustment and standardization. Fracture lines were drawn on the typical ankle model in compliance with the existing fracture model, while the 3D maps were obtained by superimposing the fracture lines of all participants (Figure 2).

Statistical analysis

The fracture characteristics of patients were analyzed using the frequencies and percentages for categorical variables as well as arithmetic means for continuous variables. To compare whether gender is correlated with posterior malleolus fracture among SER and PER groups, a Pearson χ^2 hypothesis test was conducted with the level of $\alpha = 0.05$ (V20.0, SPSS, Chicago, IL, United States). Descriptive analyses were carried out for each group using a combination of 3D mapping generation.

RESULTS

The present study enrolled 112 patients, of which 80 were in the SER4 group and 32 in the PER4 group. Participants had an average age of 49 (SD = 15.09 years; Figure 3). Patient demographics are summarized in Table 1. The results of Pearson χ^2 hypothesis test demonstrated that the value of χ^2 was 1.600 and P value was 0.206 ($P > 0.05$). This indicated that there was no statistically significant difference between gender in the two groups.

Comparison of the 3D maps of the two groups (SER group, Figure 4; PER group, Figure 5) revealed that the features shared by both groups was the presence of medial malleolus fractures and lateral malleolus fractures among all cases with posterior malleolus fracture. However, when compared to the PER4 ankle fracture, which demonstrated larger fragments following posterior ankle fracture, the posterior ankle

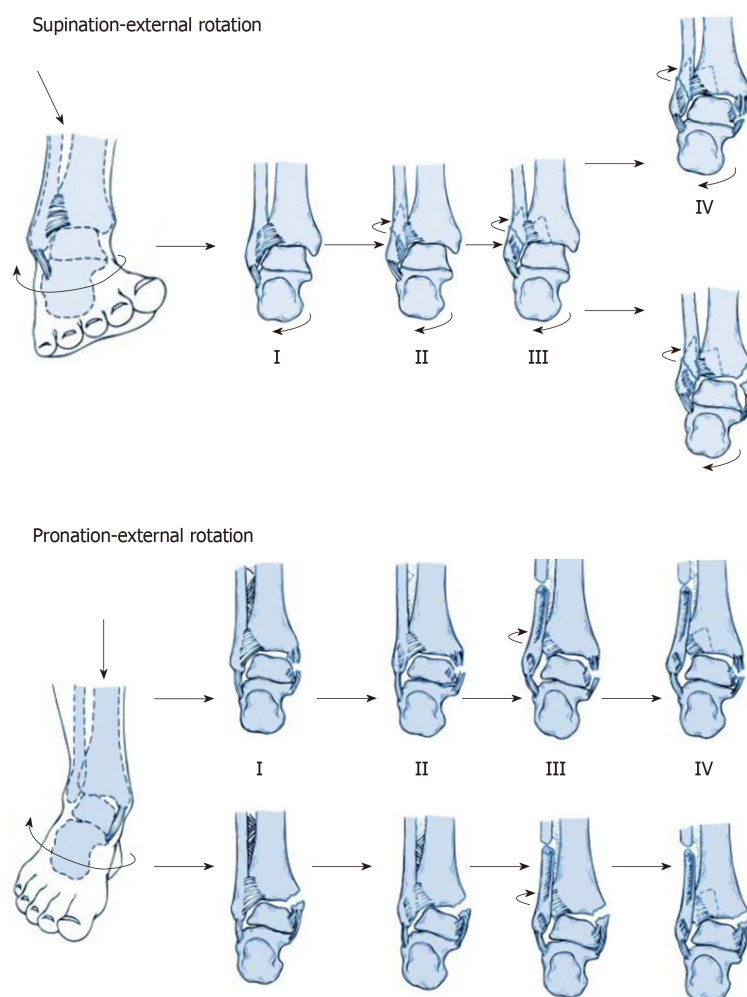


Figure 1 The injury mechanisms of supination-external rotation grade IV and pronation-external rotation grade IV groups.

fracture fragments resulting from SER4 ankle fractures exhibited relatively smaller fragments. In addition, distribution analyses on posterior malleolus fracture lines indicated that the SER group tended to have higher linear density but more concentrated and orderly distribution fracture lines compared to the PER group. This was supported by a number of posterior malleolus fracture lines extending to the medial malleolus. However, no significant difference in the distribution of medial malleolus fracture lines was found between the two groups.

In addition, an apparent difference was found in the distribution of lateral malleolus fracture lines between the two groups. Notably, the majority of lateral malleolus fracture lines in the SER group originated from the lower end of the fibula before extending upwards along the anterior-to-posterior portion at an oblique angle. Comparatively, the lateral malleolus fracture lines originated from a higher localization in the PER group, followed by generating a non-uniform random distribution. Most of them extended upwards along the anterior-to-posterior portion at an oblique angle with a spiral pattern, indicating that they tended to have a greater length.

DISCUSSION

Fractures of the posterior malleolar commonly occur and may result from a rotational injury. Although treatment for associated lateral and medial structures has been well founded, controversy exists regarding their management.

Typically, the fixation approach for posterior malleolus fracture is a precise reduction of bone fragment through ligament reconstruction, followed by fixation with screws along an anterior-to-posterior direction. Obviously, the advantage of this technique lies in the fact that patients remain in a supine position for a minimally

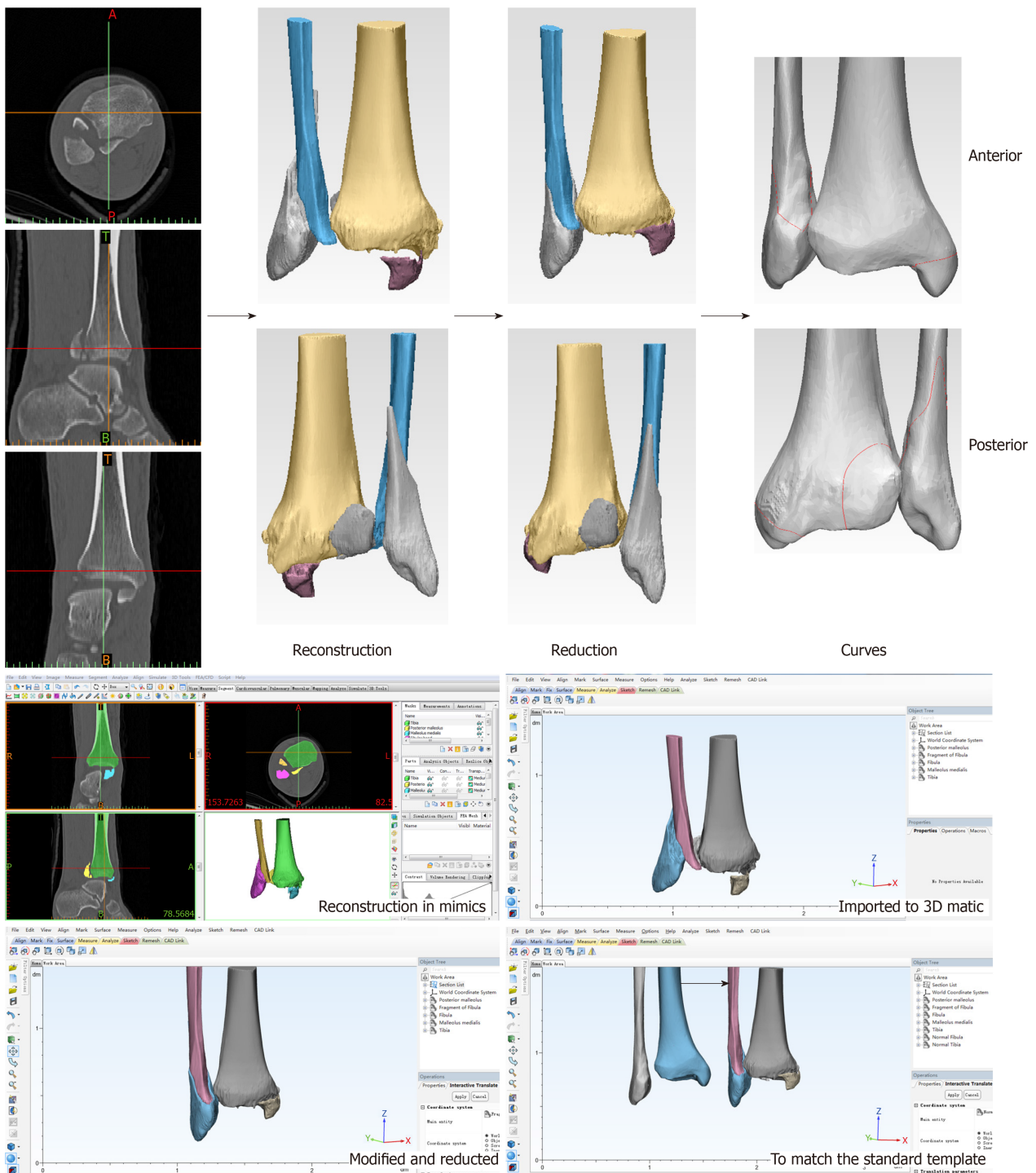


Figure 2 The process of three dimensional fracture mapping in the software programs. The ankle fracture fragments were reconstructed, reduced and normalized to optimally match the standard template. Smooth curves were constructed on the model surface and then overlapped.

invasive operation. However, its disadvantage is the high-failure rates of ligament reconstruction. In addition, it is impossible to remove the residual bone fragments in the joint. Some studies report the use of a posterolateral approach^[19-23], which has gained considerable attention and recognition. The unique leverage of this method is its direct achievement of an anatomical reduction as well as a stable fixation along the posterior-to-anterior direction with screws or plates. This approach also enabled the removal of intra-articular loose bodies that may interfere with anatomic reduction. However, the drawback of this surgery is that it requires a prone or lateral position for patients. In addition, some retrospective clinical studies have demonstrated that the open posterolateral approach for fixing a posterior malleolus fracture is much greater than percutaneous anterior-to-posterior screw fixation. Nevertheless, these findings need to be further verified by prospective comparative trials^[24].

Through the use of 3D-map analyses, our study clearly demonstrated the

Table 1 Patient demographics, *n* = 112

Variables	
Age in yr, mean \pm SD (range)	49.0 \pm 15.9 (20-89)
Supination-external rotation group	
Female	48
Male	32
Pronation-external rotation group	
Female	15
Male	17

uniformity and enrichment of posterior malleolus fracture lines in the SER group. In spite of a less extensive distribution of corresponding fracture lines, several smaller fragments protruded easily into the joints between the tibia and fibula as well as the joints between the tibia and talus. It is worth noting that these fragments generally have a sizeable impact on ankle joint prognosis, given the difficulty of achieving a complete reduction indirectly by ligament repairing as well as the challenges of achieving stable fixation *via* screws. This indicates that the functional rehabilitation of the ankle joint has been compromised to a large extent. Distribution analyses of the 3D maps revealed a scattered, non-uniform pattern of fracture lines in the PER group, many of which had extended to the medial malleolus with more severe degrees of fracture. In addition, the fracture surfaces of corresponding fragments appeared to have rough edges. It is interesting that this particular type of fracture fragment exhibits a better chance of achieving a positive effect *via* indirect ligament reconstruction. Therefore, it is reasonable to believe that in most cases of SER4 injuries, it is possible to successfully apply the posterolateral approach for fracture reduction and fixation. In contrast, for PER4 injuries, screw fixation along the anterior-to-posterior direction can generally be applied, which leads to a great effect of reduction and fixation.

Several studies have reported a high rate (33.5%) of clinical- and/or radiologic-diagnosed osteoarthritis following posterior malleolar fractures. Besides, there is no significant effect of fragment size on long-term outcomes after conservative or surgical management of posterior malleolus fractures. However, Mingo-Robinet *et al*^[25] and McDaniel *et al*^[26] have demonstrated that the outcome of posterior malleolus fractures can be improved if the fracture size is less than or equal to 25% of total distal articular surface without affecting the quality of reduction. Additionally, they recommend that the anatomic reduction of PMF may be required for greater fracture size ($\geq 25\%$) and that failure to achieve a considerable reduction and correction of PMF subluxation does not change the overall outcome. However, our results, based on morphological analysis, seem to suggest otherwise. It is noted that if screw fixation is applied along the anterior-to-posterior direction, small PMFs may exert a greater impact on the functional rehabilitation of the ankle joint, even though this method does not achieve better reduction and fixation because the fracture fragments are typically small.

Nevertheless, it is unlikely that one single factor plays a decisive role in the functional rehabilitation of the ankle joint following posterior malleolus fracture, especially as trimalleolar fractures involve both medial malleolus and lateral malleolus. Instead, it is necessary to comprehensively evaluate the impact of a diverse set of potential risk factors, including the size, shape and location of fragments and the smoothness of fracture surface as well as other elements of fracture fixation, surgical approach and post-surgical rehabilitation. After comprehensive assessment, we recommend that individualized treatment is the best option. Moreover, we believe that most single-factor assessments deviating from the inclusion of comprehensive factors are defective and unreliable. Overall, multi-factor analyses and assessments, larger sample size, prolonged follow-up period and multicenter prospective controlled trials are needed for future investigations.

Fracture maps revealed the fracture characteristics and recurrent patterns of the posterior malleolar fractures, which might help to improve the understanding of ankle fracture as well as increase opportunities for follow-up research and aid clinical decision-making.

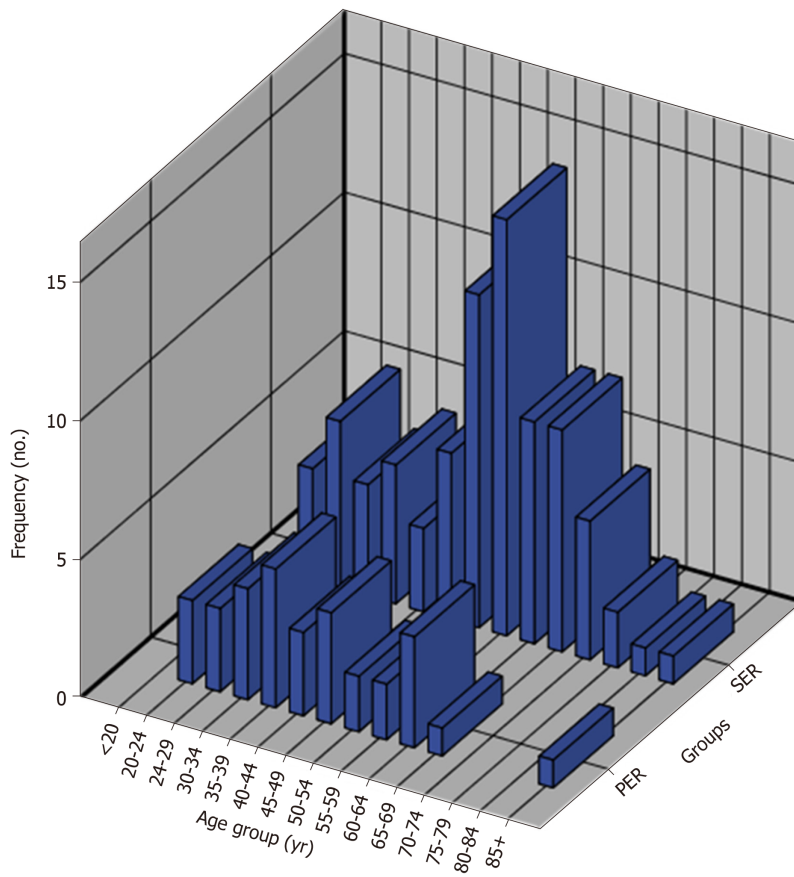


Figure 3 Histogram of the age groups of all subjects.

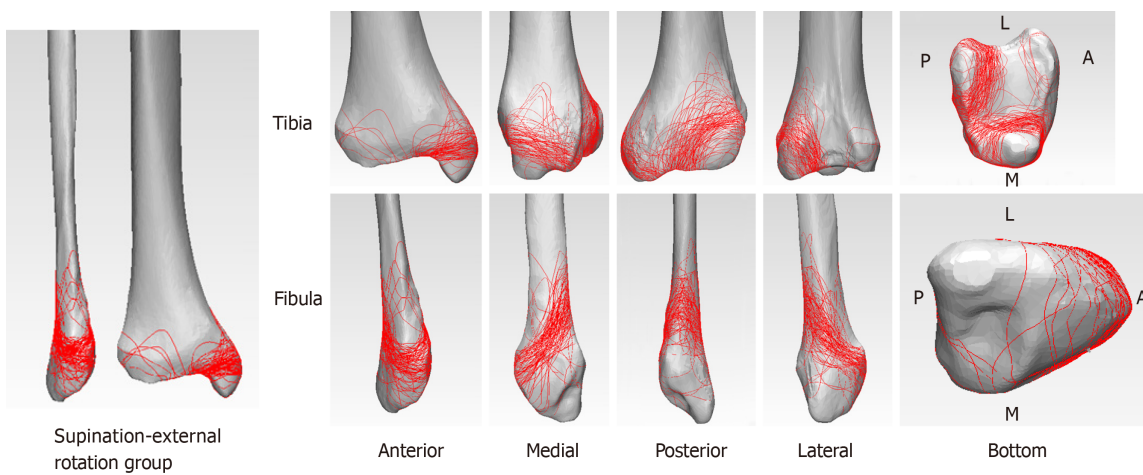


Figure 4 The three dimensional fracture maps of supination-external rotation grade IV group. Distribution analyses on posterior malleolus fracture lines indicated that the supination-external rotation grade IV group tended to have higher linear density but more concentrated and orderly distribution fracture lines compared to the pronation-external rotation grade IV groups.

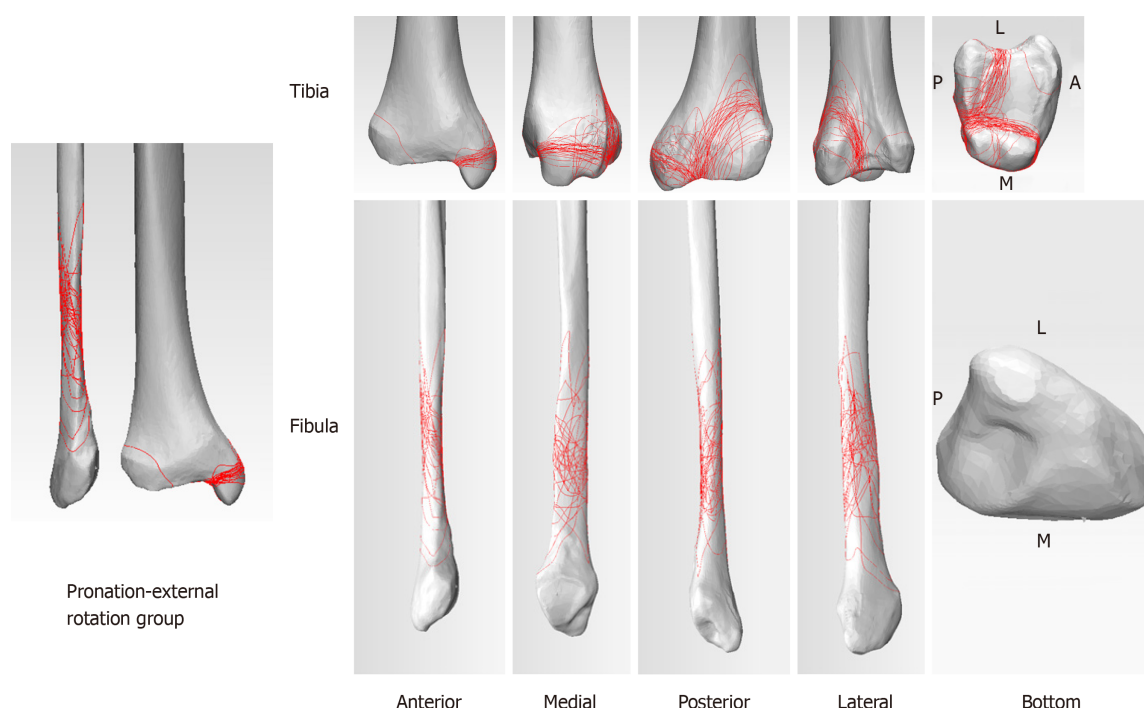


Figure 5 The three dimensional fracture maps of pronation-external rotation grade IV group. This group tended to have more extensive and unorganized distribution fracture lines compared to the supination-external rotation grade IV group.

ARTICLE HIGHLIGHTS

Research background

Posterior malleolar fractures have been reported to occur in < 40% of ankle fractures, which is widely regarded as a critical prognostic factor or outcome indicator following ankle fracture treatment. The morphology of posterior malleolar fractures can be more crucial than fragment size alone for clinical decision making.

Research motivation

The optimal treatment procedures for posterior malleolar fractures remain controversial. The fracture characteristics and recurrent patterns of the posterior malleolar fractures are unclear.

Research objectives

In this study, the authors aimed to reveal the recurrent patterns and characteristics of posterior malleolar fractures by creating fracture maps of the posterior malleolar fractures through the use of computed tomography mapping.

Research methods

A consecutive series of posterior malleolar fractures was used to create three-dimensional reconstruction images to produce the distribution map of fracture lines through three-dimensional computed tomography mapping in the Mimics and 3-matic software.

Research results

Three-dimensional maps showed that the posterior ankle fracture fragments in supination-external rotation grade IV fractures were relatively smaller than those in pronation-external rotation grade IV fractures after posterior malleolus fracture. In addition, the distribution analyses on posterior malleolus fracture lines indicated that supination-external rotation group tended to have higher linear density but more concentrated and orderly distribution fractures compared to pronation-external rotation group.

Research conclusions

Fracture maps revealed the fracture characteristics and recurrent patterns of the posterior malleolar fractures, which might help to improve the understanding of ankle fracture.

Research perspectives

Multifactor analyses and assessments, larger sample size, prolonged follow-up period and multicenter prospective controlled trials are needed for future investigations.

REFERENCES

- 1 **Court-Brown CM**, McBirnie J, Wilson G. Adult ankle fractures--an increasing problem? *Acta Orthop Scand* 1998; **69**: 43-47 [PMID: [9524517](#) DOI: [10.3109/17453679809002355](#)]
- 2 **Jaskulka RA**, Ittner G, Schedl R. Fractures of the posterior tibial margin: their role in the prognosis of malleolar fractures. *J Trauma* 1989; **29**: 1565-1570 [PMID: [2585569](#) DOI: [10.1097/00005373-198911000-00018](#)]
- 3 **Langenhuijsen JF**, Heetveld MJ, Uteet JM, Steller EP, Butzelaar RM. Results of ankle fractures with involvement of the posterior tibial margin. *J Trauma* 2002; **53**: 55-60 [PMID: [12131390](#) DOI: [10.1097/00005373-200207000-00012](#)]
- 4 **Tejwani NC**, Pahk B, Egol KA. Effect of posterior malleolus fracture on outcome after unstable ankle fracture. *J Trauma* 2010; **69**: 666-669 [PMID: [20838137](#) DOI: [10.1097/TA.0b013e3181e4f81e](#)]
- 5 **Weber M**, Ganz R. Malunion following trimalleolar fracture with posterolateral subluxation of the talus--reconstruction including the posterior malleolus. *Foot Ankle Int* 2003; **24**: 338-344 [PMID: [12735377](#) DOI: [10.1177/107110070302400406](#)]
- 6 **Regan W**, Morrey B. Fractures of the coronoid process of the ulna. *J Bone Joint Surg Am* 1989; **71**: 1348-1354 [PMID: [2793888](#)]
- 7 **Doornberg JN**, Ring D. Coronoid fracture patterns. *J Hand Surg Am* 2006; **31**: 45-52 [PMID: [16443103](#) DOI: [10.1016/j.jhsa.2005.08.014](#)]
- 8 **Doornberg JN**, Ring DC. Fracture of the anteromedial facet of the coronoid process. *J Bone Joint Surg Am* 2006; **88**: 2216-2224 [PMID: [17015599](#) DOI: [10.2106/JBJS.E.01127](#)]
- 9 **O'Driscoll SW**, Jupiter JB, Cohen MS, Ring D, McKee MD. Difficult elbow fractures: pearls and pitfalls. *Instr Course Lect* 2003; **52**: 113-134 [PMID: [12690844](#)]
- 10 **Mangnus L**, Meijer DT, Stufkens SA, Mellema JJ, Steller EP, Kerkhoffs GM, Doornberg JN. Posterior Malleolar Fracture Patterns. *J Orthop Trauma* 2015; **29**: 428-435 [PMID: [25785358](#) DOI: [10.1097/BOT.0000000000000330](#)]
- 11 **Büchler L**, Tannast M, Bonel HM, Weber M. Reliability of radiologic assessment of the fracture anatomy at the posterior tibial plafond in malleolar fractures. *J Orthop Trauma* 2009; **23**: 208-212 [PMID: [19516096](#) DOI: [10.1097/BOT.0b013e31819b0b23](#)]
- 12 **Haraguchi N**, Haruyama H, Toga H, Kato F. Pathoanatomy of posterior malleolar fractures of the ankle. *J Bone Joint Surg Am* 2006; **88**: 1085-1092 [PMID: [16651584](#) DOI: [10.2106/JBJS.E.00856](#)]
- 13 **Bartoniček J**, Rammelt S, Kostlivý K, Vaněček V, Klika D, Trešl I. Anatomy and classification of the posterior tibial fragment in ankle fractures. *Arch Orthop Trauma Surg* 2015; **135**: 505-516 [PMID: [25708027](#) DOI: [10.1007/s00402-015-2171-4](#)]
- 14 **Ferries JS**, DeCoster TA, Firoozbakhsh KK, Garcia JF, Miller RA. Plain radiographic interpretation in trimalleolar ankle fractures poorly assesses posterior fragment size. *J Orthop Trauma* 1994; **8**: 328-331 [PMID: [7965295](#) DOI: [10.1097/00005131-199408000-00009](#)]
- 15 **Armitage BM**, Wijedicks CA, Tarkin IS, Schroder LK, Marek DJ, Zlowodzki M, Cole PA. Mapping of scapular fractures with three-dimensional computed tomography. *J Bone Joint Surg Am* 2009; **91**: 2222-2228 [PMID: [19724000](#) DOI: [10.2106/JBJS.H.00881](#)]
- 16 **Su Q**, Zhang Y, Liao S, Yan M, Zhu K, Yan S, Li C, Tan J. 3D Computed Tomography Mapping of Thoracolumbar Vertebrae Fractures. *Med Sci Monit* 2019; **25**: 2802-2810 [PMID: [30990799](#) DOI: [10.12659/MSM.915916](#)]
- 17 **Cole PA**, Mehrle RK, Bhandari M, Zlowodzki M. The pilon map: fracture lines and comminution zones in OTA/AO type 43C3 pilon fractures. *J Orthop Trauma* 2013; **27**: e152-e156 [PMID: [23360909](#) DOI: [10.1097/BOT.0b013e318288a7e9](#)]
- 18 **Yin MC**, Yuan XF, Ma JM, Xia Y, Wang T, Xu XL, Yan YJ, Xu JH, Ye J, Tong ZY, Feng YQ, Wang HB, Wu XQ, Mo W. Evaluating the Reliability and Reproducibility of the AO and Lauge-Hansen Classification Systems for Ankle Injuries. *Orthopedics* 2015; **38**: e626-e630 [PMID: [26186326](#) DOI: [10.3928/01477447-20150701-62](#)]
- 19 **Talbot M**, Steenblock TR, Cole PA. Posterolateral approach for open reduction and internal fixation of trimalleolar ankle fractures. *Can J Surg* 2005; **48**: 487-490 [PMID: [16417056](#) DOI: [10.1111/j.1600-065X.2007.00529.x](#)]
- 20 **Tornetta P**, Ricci W, Nork S, Collinge C, Steen B. The posterolateral approach to the tibia for displaced posterior malleolar injuries. *J Orthop Trauma* 2011; **25**: 123-126 [PMID: [21245717](#) DOI: [10.1097/BOT.0b013e3181e47d29](#)]
- 21 **Odak S**, Ahluwalia R, Unnikrishnan P, Hennessy M, Platt S. Management of Posterior Malleolar Fractures: A Systematic Review. *J Foot Ankle Surg* 2016; **55**: 140-145 [PMID: [26100091](#) DOI: [10.1053/j.jfas.2015.04.001](#)]
- 22 **Fu S**, Zou ZY, Mei G, Jin D. Advances and disputes of posterior malleolus fracture. *Chin Med J (Engl)* 2013; **126**: 3972-3977 [PMID: [24157167](#) DOI: [10.3760/cma.j.issn.0366-6999.20131514](#)]
- 23 **Irwin TA**, Lien J, Kadakia AR. Posterior malleolus fracture. *J Am Acad Orthop Surg* 2013; **21**: 32-40 [PMID: [23281469](#) DOI: [10.5435/JAAOS-21-01-32](#)]
- 24 **Verhage SM**, Hoogendoorn JM, Krijnen P, Schipper IB. When and how to operate the posterior malleolus fragment in trimalleolar fractures: a systematic literature review. *Arch Orthop Trauma Surg* 2018; **138**: 1213-1222 [PMID: [29752537](#) DOI: [10.1007/s00402-018-2949-2](#)]
- 25 **Mingo-Robinet J**, López-Durán L, Galeote JE, Martínez-Cervell C. Ankle fractures with posterior malleolar fragment: management and results. *J Foot Ankle Surg* 2011; **50**: 141-145 [PMID: [21353996](#) DOI: [10.1053/j.jfas.2010.12.013](#)]
- 26 **McDaniel WJ**, Wilson FC. Trimalleolar fractures of the ankle. An end result study. *Clin Orthop Relat Res* 1977; **37**: 45 [PMID: [402247](#) DOI: [10.1097/00003086-197701000-00006](#)]



Published By Baishideng Publishing Group Inc
7041 Koll Center Parkway, Suite 160, Pleasanton, CA 94566, USA
Telephone: +1-925-2238242
E-mail: bpgoffice@wjgnet.com
Help Desk: <https://www.f6publishing.com/helpdesk>
<https://www.wjgnet.com>

