

# World Journal of *Clinical Cases*

*World J Clin Cases* 2020 January 6; 8(1): 1-244





### REVIEW

- 1 Role of oxysterol-binding protein-related proteins in malignant human tumours  
*Liu H, Huang S*

### ORIGINAL ARTICLE

#### Case Control Study

- 11 Oncogenic role of Tc17 cells in cervical cancer development  
*Zhang ZS, Gu Y, Liu BG, Tang H, Hua Y, Wang J*

#### Retrospective Study

- 20 Acute distal common bile duct angle is risk factor for post-endoscopic retrograde cholangiopancreatography pancreatitis in beginner endoscopist  
*Han SY, Kim DU, Lee MW, Park YJ, Baek DH, Kim GH, Song GA*
- 29 Three-dimensional computed tomography mapping of posterior malleolar fractures  
*Su QH, Liu J, Zhang Y, Tan J, Yan MJ, Zhu K, Zhang J, Li C*
- 38 Application of a modified surgical position in anterior approach for total cervical artificial disc replacement  
*Hou WX, Zhang HX, Wang X, Yang HL, Luan XR*
- 46 Potential role of the compound Eucommia bone tonic granules in patients with osteoarthritis and osteonecrosis: A retrospective study  
*Hu CX, Hu KY, Wang JF*
- 54 Prognostic factors for overall survival in prostate cancer patients with different site-specific visceral metastases: A study of 1358 patients  
*Cui PF, Cong XF, Gao F, Yin JX, Niu ZR, Zhao SC, Liu ZL*
- 68 Application of multiple Roux-en-Y hepaticojejunostomy reconstruction by formation of bile hilar duct lake in the operation of hilar cholangiocarcinoma  
*Yang XJ, Dong XH, Chen SY, Wu B, He Y, Dong BL, Ma BQ, Gao P*

#### Observational Study

- 76 Relationship between  $\beta$ -amyloid protein 1-42, thyroid hormone levels and the risk of cognitive impairment after ischemic stroke  
*Mao L, Chen XH, Zhuang JH, Li P, Xu YX, Zhao YC, Ma YJ, He B, Yin Y*

**Prospective Study**

- 88 Can the wet suction technique change the efficacy of endoscopic ultrasound-guided fine-needle aspiration for diagnosing autoimmune pancreatitis type 1? A prospective single-arm study  
*Sugimoto M, Takagi T, Suzuki R, Konno N, Asama H, Sato Y, Irie H, Watanabe K, Nakamura J, Kikuchi H, Takasumi M, Hashimoto M, Kato T, Hikichi T, Notohara K, Ohira H*

**CASE REPORT**

- 97 Pembrolizumab - emerging treatment of pulmonary sarcomatoid carcinoma: A case report  
*Cimpeanu E, Ahmed J, Zafar W, DeMarinis A, Bardarov SS, Salman S, Bloomfield D*
- 103 Sclerosing angiomatoid nodular transformation of the spleen, a rare cause for splenectomy: Two case reports  
*Chikhladze S, Lederer AK, Fichtner-Feigl S, Wittel UA, Werner M, Aumann K*
- 110 Postpartum pubic symphysis diastasis-conservative and surgical treatment methods, incidence of complications: Two case reports and a review of the literature  
*Norvilaite K, Kezeviciute M, Ramasauskaite D, Arlauskienė A, Bartkeviciene D, Uvarovas V*
- 120 Use of omental patch and endoscopic closure technique as an alternative to surgery after endoscopic full thickness resection of gastric intestinal stromal tumors: A series of cases  
*Sachdev AH, Iqbal S, Ribeiro IB, de Moura DTH*
- 126 Primary maxillary chondrosarcoma: A case report  
*Cuevas-González JC, Reyes-Escalera JO, González JL, Sánchez-Romero C, Espinosa-Cristóbal LF, Reyes-López SY, Tovar Carrillo KL, Donohue Cornejo A*
- 133 Hyalinizing clear cell carcinoma-a rare entity in the oral cavity: A case report  
*Donohue-Cornejo A, Paes de Almeida O, Sánchez-Romero C, Espinosa-Cristóbal LF, Reyes-López SY, Cuevas-González JC*
- 140 Jejunal cavernous lymphangioma manifested as gastrointestinal bleeding with hypogammaglobulinemia in adult: A case report and literature review  
*Tan B, Zhang SY, Wang YN, Li Y, Shi XH, Qian JM*
- 149 Large pelvic mass arising from the cervical stump: A case report  
*Zhang K, Jiang JH, Hu JL, Liu YL, Zhang XH, Wang YM, Xue FX*
- 157 Mechanical intestinal obstruction due to isolated diffuse venous malformations in the gastrointestinal tract: A case report and review of literature  
*Li HB, Lv JF, Lu N, Lv ZS*
- 168 Two-level percutaneous endoscopic lumbar discectomy for highly migrated upper lumbar disc herniation: A case report  
*Wu XB, Li ZH, Yang YF, Gu X*

- 175 Successful treatment of congenital palate perforation: A case report  
*Zhang JF, Zhang WB*
- 179 Calcitonin-negative neuroendocrine tumor of the thyroid with metastasis to liver-rare presentation of an unusual tumor: A case report and review of literature  
*Cai HJ, Wang H, Cao N, Huang B, Kong FL, Lu LR, Huang YY, Wang W*
- 188 Giant exophytic cystic adenomyosis with a levonorgestrel containing intrauterine device out of the uterine cavity after uterine myomectomy: A case report  
*Zhou Y, Chen ZY, Zhang XM*
- 194 Unusual presentation of bladder neuroblastoma in a child: A case report  
*Cai JB, Wang JH, He M, Wang FL, Xiong JN, Mao JQ, Li MJ, Zhu K, Liang JW*
- 200 Value of dynamic plasma cell-free DNA monitoring in septic shock syndrome: A case report  
*Liu JP, Zhang SC, Pan SY*
- 208 Sarcomatoid intrahepatic cholangiocarcinoma mimicking liver abscess: A case report  
*Wang Y, Ming JL, Ren XY, Qiu L, Zhou LJ, Yang SD, Fang XM*
- 217 Clinical characteristics on manifestation and gene mutation of a transient neonatal cyanosis: A case report  
*Yuan J, Zhu XP*
- 222 Six families with balanced chromosome translocation associated with reproductive risks in Hainan Province: Case reports and review of the literature  
*Chen YC, Huang XN, Kong CY, Hu JD*
- 234 Primary intestinal extranodal natural killer/T-cell lymphoma, nasal type: A case report  
*Dong BL, Dong XH, Zhao HQ, Gao P, Yang XJ*

**LETTER TO THE EDITOR**

- 242 Cluster headache as a manifestation of a stroke-like episode in a carrier of the MT-ND3 variant m.10158T>C  
*Finsterer J*



**ABOUT COVER**

Editorial Board Member of *World Journal of Clinical Cases*, Maddalena Zippi, MD, PhD, Doctor, Unit of Gastroenterology and Digestive Endoscopy, Sandro Pertini Hospital, Rome 00157, Italy

**AIMS AND SCOPE**

The primary aim of *World Journal of Clinical Cases* (WJCC, *World J Clin Cases*) is to provide scholars and readers from various fields of clinical medicine with a platform to publish high-quality clinical research articles and communicate their research findings online.

WJCC mainly publishes articles reporting research results and findings obtained in the field of clinical medicine and covering a wide range of topics, including case control studies, retrospective cohort studies, retrospective studies, clinical trials studies, observational studies, prospective studies, randomized controlled trials, randomized clinical trials, systematic reviews, meta-analysis, and case reports.

**INDEXING/ABSTRACTING**

The WJCC is now indexed in PubMed, PubMed Central, Science Citation Index Expanded (also known as SciSearch®), and Journal Citation Reports/Science Edition. The 2019 Edition of Journal Citation Reports cites the 2018 impact factor for WJCC as 1.153 (5-year impact factor: N/A), ranking WJCC as 99 among 160 journals in Medicine, General and Internal (quartile in category Q3).

**RESPONSIBLE EDITORS FOR THIS ISSUE**

Responsible Electronic Editor: *Yan-Xia Xing*

Proofing Production Department Director: *Yun-Xiaojuan Wu*

**NAME OF JOURNAL**

*World Journal of Clinical Cases*

**ISSN**

ISSN 2307-8960 (online)

**LAUNCH DATE**

April 16, 2013

**FREQUENCY**

Semimonthly

**EDITORS-IN-CHIEF**

Dennis A Bloomfield, Bao-Gan Peng, Sandro Vento

**EDITORIAL BOARD MEMBERS**

<https://www.wjnet.com/2307-8960/editorialboard.htm>

**EDITORIAL OFFICE**

Jin-Lei Wang, Director

**PUBLICATION DATE**

January 6, 2020

**COPYRIGHT**

© 2020 Baishideng Publishing Group Inc

**INSTRUCTIONS TO AUTHORS**

<https://www.wjnet.com/bpg/gerinfo/204>

**GUIDELINES FOR ETHICS DOCUMENTS**

<https://www.wjnet.com/bpg/GerInfo/287>

**GUIDELINES FOR NON-NATIVE SPEAKERS OF ENGLISH**

<https://www.wjnet.com/bpg/gerinfo/240>

**PUBLICATION MISCONDUCT**

<https://www.wjnet.com/bpg/gerinfo/208>

**ARTICLE PROCESSING CHARGE**

<https://www.wjnet.com/bpg/gerinfo/242>

**STEPS FOR SUBMITTING MANUSCRIPTS**

<https://www.wjnet.com/bpg/GerInfo/239>

**ONLINE SUBMISSION**

<https://www.f6publishing.com>

## Retrospective Study

# Application of multiple Roux-en-Y hepaticojejunostomy reconstruction by formation of bile hilar duct lake in the operation of hilar cholangiocarcinoma

Xiao-Jun Yang, Xiao-Hua Dong, Shi-Yong Chen, Biao Wu, Yu He, Bao-Long Dong, Bing-Qiang Ma, Peng Gao

**ORCID number:** Xiao-Jun Yang (0000-0003-3770-8451); Xiao-Hua Dong (0000-0003-2374-9826); Shi-Yong Chen (0000-0003-2678-7019); Biao Wu (0000-0003-4792-1133); Yu He (0000-0002-7127-3773); Bao-Long Dong (0000-0002-8349-1903); Bing-Qiang Ma (0000-0002-0254-6547); Peng Gao (0000-0001-7016-6485).

**Author contributions:** Yang XJ, Dong XH, and Chen SY contributed equally to this work; Yang XJ, Dong XH, Chen SY, and Gao P contributed to the conception and design; Wu B, He Y, and Dong BL acquired the data; Yang XJ, Dong XH, and Chen SY analyzed and interpreted the data; Dong XH, Chen SY, and Ma BQ drafted the article; Gao P critically reviewed the article and approved the final article; All authors reviewed and approved this article to be published.

**Supported by** National Natural Science Foundation of China, No. 81260326 and No. 81660398; and Natural Science Foundation of Gansu Province, No. 17JR5RA034.

**Institutional review board statement:** This study was reviewed and approved by the Ethics Committee of the Gansu Provincial hospital (2019-145).

**Informed consent statement:** All surgeries were performed after the patient or their relatives signed the informed consent form.

**Conflict-of-interest statement:** All authors declare no conflicts-of-interest.

**Xiao-Jun Yang, Xiao-Hua Dong, Bing-Qiang Ma, Peng Gao,** Department of General Surgery, Gansu Provincial Hospital, Lanzhou 730000, Gansu Province, China

**Shi-Yong Chen, Biao Wu,** School of Clinical Medicine, Ningxia Medical University, Yinchuan 750000, Ningxia Hui Autonomous Region, China

**Yu He, Bao-Long Dong,** School of Clinical Medicine, Gansu University of Chinese Medicine, Lanzhou 730000, Gansu Province, China

**Corresponding author:** Peng Gao, MD, Chief Physician, Doctor, Professor, Surgeon, Department of General Surgery, Gansu Provincial Hospital, No. 204 Donggang West Road, Lanzhou 730000, Gansu Province, China. [yangxjmd@aliyun.com](mailto:yangxjmd@aliyun.com)

## Abstract

### BACKGROUND

Hilar cholangiocarcinoma is the most common malignant tumor of the extrahepatic bile duct. Until now, radical resection has been the most effective method for the long-term survival of patients with the disease. However, many problems have emerged in the field of hepatobiliary surgery for a long time, including complex surgical procedures, low resection rate, and postoperative complications. We have adopted the "multiple Roux-en-Y hepaticojejunostomy reconstruction by formation of a bile duct lake" technique in the treatment of hilar cholangiocarcinoma since 2008, and obtained satisfactory short- and long-term results.

### AIM

To examine the feasibility of the application of multiple Roux-en-Y hepaticojejunostomy reconstruction by formation of a bile duct lake in the operation of hilar cholangiocarcinoma.

### METHODS

A retrospective analysis was performed for the clinical data, surgical methods, and results of 76 patients with hilar cholangiocarcinoma who were treated with hilar bile duct lake-forming multiple Roux-en-Y hepaticojejunostomy reconstruction at Gansu Provincial Hospital.

### RESULTS

In all 76 cases, the operation was successful and no operative death occurred. The mean (range) operation time was  $215.4 \pm 53.5$  min (124–678 min), and the amount

interest related to this article.

**Data sharing statement:** No additional data are available.

**Open-Access:** This article is an open-access article that was selected by an in-house editor and fully peer-reviewed by external reviewers. It is distributed in accordance with the Creative Commons Attribution Non Commercial (CC BY-NC 4.0) license, which permits others to distribute, remix, adapt, build upon this work non-commercially, and license their derivative works on different terms, provided the original work is properly cited and the use is non-commercial. See: <http://creativecommons.org/licenses/by-nc/4.0/>

**Manuscript source:** Unsolicited manuscript

**Received:** August 8, 2019

**Peer-review started:** August 8, 2019

**First decision:** October 14, 2019

**Revised:** November 10, 2019

**Accepted:** November 14, 2019

**Article in press:** November 14, 2019

**Published online:** January 6, 2020

**P-Reviewer:** Mochegiani F

**S-Editor:** Ma YJ

**L-Editor:** Filipodia

**E-Editor:** Xing YX



of bleeding during the operation was  $428.2 \pm 63.8$  mL (240–2200 mL). The overall 1-year survival rate was 78.9%, and the 3-year survival rate was 32.8%.

## CONCLUSION

The multiple Roux-en-Y hepaticojejunostomy reconstruction technique with formation of a bile duct lake is safe and effective for the surgical treatment of hilar cholangiocarcinoma.

**Key words:** Hilar cholangiocarcinoma; Bile duct lake; Hepaticojejunostomy

©The Author(s) 2020. Published by Baishideng Publishing Group Inc. All rights reserved.

**Core tip:** Hilar cholangiocarcinoma accounts for approximately 50% of all cholangiocarcinomas. Until now, radical resection has been the most effective method for the long-term survival of patients with the disease. However, many problems have emerged in the field of hepatobiliary surgery over time, including complex surgical procedures, low resection rates, and postoperative complications. We have adopted the "multiple Roux-en-Y hepaticojejunostomy reconstruction by formation of a bile duct lake" technique in the treatment of hilar cholangiocarcinoma since 2008, and obtained satisfactory short- and long-term results.

**Citation:** Yang XJ, Dong XH, Chen SY, Wu B, He Y, Dong BL, Ma BQ, Gao P. Application of multiple Roux-en-Y hepaticojejunostomy reconstruction by formation of bile hilar duct lake in the operation of hilar cholangiocarcinoma. *World J Clin Cases* 2020; 8(1): 68-75

**URL:** <https://www.wjgnet.com/2307-8960/full/v8/i1/68.htm>

**DOI:** <https://dx.doi.org/10.12998/wjcc.v8.i1.68>

## INTRODUCTION

As the most common malignant tumor of the extrahepatic bile duct, hilar cholangiocarcinoma accounts for approximately 50% of all cholangiocarcinomas<sup>[1]</sup>. Until now, radical resection has been the most effective method for the long-term survival of patients with the disease. However, many problems have emerged in the field of hepatobiliary surgery over time, including complex surgical procedures, low resection rates, and postoperative complications. Besides radiological resectability assessment and preoperative biliary drainage, the primary problem that needs to be considered before and after tumor resection is the reconstruction of biliary intestinal anastomosis, in addition to vascular resection and reconstruction<sup>[2]</sup>. For most Bismuth type I hilar cholangiocarcinomas, anastomosis is relatively simple because of only one opening in the hilum; even if two openings are sometimes present, an opening can even form as a result of simple plastic surgery. However, this is different for type II, III, and IV hilar cholangiocarcinomas, as anastomosis is extremely difficult because as many as ten bile duct openings have been found in the hilum.

In this case, many surgeons use hilar plate-jejunum anastomosis, which sutures the jejunum with the liver tissue around the opening of multiple secondary or more bile ducts; however, the incidence rates of bile leakage, infection, and anastomotic stenosis are higher after this anastomosis is applied<sup>[3-5]</sup>. Some researchers use basin-like anastomosis; that is, they suture multiple bile duct openings to each other, forming a larger basin-like opening, which is then anastomosed with the jejunum<sup>[6,7]</sup>. Although anastomosis has few complications, it can only be applied to cases where only two or three bile duct openings are present in the portahepatis. If greater than four (even up to eight or nine) bile duct openings are present, suturing them together is almost impossible. In view of this situation, we have adopted the "multiple Roux-en-Y hepaticojejunostomy reconstruction by formation of a bile duct lake" technique in the treatment of hilar cholangiocarcinoma since 2008, and obtained satisfactory short- and long-term results. Herein, we present the results of our retrospective analysis.

## MATERIALS AND METHODS

### Clinical data

The subjects included 76 patients with hilar cholangiocarcinoma, of whom 47 were men and 29 were women, who were hospitalized and underwent operation in the Department of General Surgery of Gansu Provincial Hospital between January 2008 and October 2016. The mean age was  $56.3 \pm 11.7$  years (range, 39–84 years). Gross jaundice was found in 65 patients (85.5%), and upper abdominal discomfort was found in 43 patients (56.6%). Sixteen patients (21.1%) had asthenia and weakness, and eight (10.5%) had chills and fever. The serum total bilirubin level increased in 76 patients (100%), with a mean (range) of  $238.3 \pm 76.5$  mmol/L (47–542 mmol/L). The mean preoperative jaundice time was  $22.6 \pm 5.4$  d (9–87 d). Five patients had cirrhosis, eight had intrahepatic and extrahepatic stones and cholecystolithiasis, and five had a previous history of biliary tract surgery. All 76 patients were examined for tumor markers. Seventy patients (92.1%) had an abnormal CA199 level ( $>37$  U/mL), which was  $>1000$  U/mL in 51 patients (67.1%). All patients underwent B-mode ultrasonography, computed tomography (CT), and magnetic resonance cholangiopancreatography (MRCP) examinations, showing intrahepatic bile duct dilatation in 63 patients (82.9%), and hilar and bile duct occupancy in 76 patients (100%). According to the Bismuth-Corlette classification, six cases were type I; 19, type II; 21, type IIIa; 16, type IIIB; and 14, type IV.

### Treatment

**Preoperative jaundice reduction and supportive treatment:** According to the severity of obstructive jaundice, the patients with preoperative total bilirubin levels of  $>200$  mmol/L were routinely treated with PTCD. The reduction time was 5–15 d, with a mean of  $10.2 \pm 3.1$  d. At the same time, jejunal nutrition tube bile transfusion and hepatoprotective treatment were administered, and if patients with gastrointestinal dysfunction were unable to eat, parenteral nutrition support was provided.

**Surgical methods:** Preoperative imaging data (including B-mode ultrasonography, CT, and MRCP) and intraoperative Bismuth-Corlette classification were used in combination with the patient's general condition to determine the surgical method. The standard procedure was cholecystectomy + extrahepatic bile duct excision + hepatoduodenal ligament vascularized lymph node dissection + hilar cholangioplasty + bile duct-jejunum Roux-en-Y anastomosis. On this basis, 19 Bismuth type II cases and 16 type IIIB cases were treated with left hemihepatectomy or left caudate lobectomy; 21 type IIIa cases were treated with right hemihepatectomy or right caudate lobectomy; and 14 type IV cases were treated with left/right trilobectomy plus total caudate lobectomy. Hepatic artery reconstruction was performed in 24 patients; portal vein reconstruction, in 23 cases; and portal vein reconstruction, in 13 patients. Another six patients were treated with pancreaticoduodenectomy due to invasion of the pancreatic head. Cholangioplasty and reconstruction were performed after resection of the lesion and lymph node dissection, in which 2–4 hilar bile duct openings were formed into one bile duct lake; 3–7 bile duct openings into two bile duct lakes; and 6–9 bile duct openings into three bile duct lakes. Biliary duct formation and cholangiojejunal anastomosis were sutured continuously with 5-0 Prolene. The first step was to determine the number of bile duct lakes according to the number and location of the bile duct openings found on the section of the residual liver in the hilar region after R0 radical resection and lymph node dissection. Second, the end of the bile duct was trimmed, and the adjacent two or three bile duct intervals were wedged to maximize the opening of each branch of the bile duct, and then the adjacent bile duct openings were sutured with 5-0 Prolene (Figure 1). Finally, 1–3 common bile duct openings were assembled, and multiple Roux-en-Y hepaticojejunostomy reconstructions by formation of a bile duct lake were performed (Figure 2). The numbers of bile duct lake formations and vascular reconstructions in the different Bismuth type cases are shown in Table 1. Two of the latex tube drainages were placed behind the anastomosis and liver cut surface. The drainage tube was removed 3–7 d after the operation.

All surgeries were performed after the patient or their relatives signed the informed consent form. This study was approved by the ethics committee of Gansu Provincial Hospital (2019-145).

**Postoperative adjuvant chemotherapy:** After 10–14 d of operation, 66 patients (86.8%) were treated with 4–6 cycles of the standardized therapy (oxaliplatin + gemcitabine) after the stitches were removed and gastrointestinal function had recovered.

## RESULTS

All 76 cases were confirmed as hilar cholangiocarcinoma by pathological examination,

Table 1 Bile duct lake formation and vascular reconstruction in different Bismuth-type cases

Number of bile duct lakes	Number of bile duct openings	Bismuth type				Vascular reconstruction	
		I	II	IIIa + IIIb	IV	Portal vein	Hepatic artery
1	2–4	6	9	7	0	6	8
2	3–7	0	10	21	3	8	10
3	6–9	0	0	9	11	9	6

including four cases of papillary carcinoma, 18 cases of well-differentiated adenocarcinoma, 45 cases of moderately and poorly differentiated adenocarcinoma, and nine cases of signet ring cell carcinoma. Postoperative pathological examination revealed that 53 cases (69.7%) were positive for lymph node metastasis of the hepatoduodenal ligament. The mean (range) number of lymph node metastasis was  $4.6 \pm 2.1$  (3–16), and the remaining 23 patients had no lymph node metastasis. Of the cases, 49 had nerve involvement and 23 had an intravascular tumor thrombus. The mean (range) operative time was  $215.4 \pm 53.5$  min (124–678 min). Intraoperative blood loss was  $428.2 \pm 63.8$  mL (range, 240–2200 mL). Four cases of abdominal hemorrhage occurred after operation, of which three were treated conservatively with blood transfusions and hemostasis, and one was treated with a second operation (common hepatic artery hemorrhage). Nineteen cases with transient bile leakage were cured by peritoneal drainage for  $9.4 \pm 3.7$  d (range, 7–21 d). Pleural effusion and/or ascites occurred in 35 cases (46.1%), all of which were cured after albumin infusion and diuretic treatment. No intraoperative deaths occurred, and three postoperative deaths occurred, including one patient with liver dysfunction, one patient with severe pulmonary infection, and one patient with systemic failure. Fifty-six patients had complete follow-up data. Survival curves are shown in Figure 3. The overall 1- and 3-year survival rates were 78.9% and 32.8%, respectively.

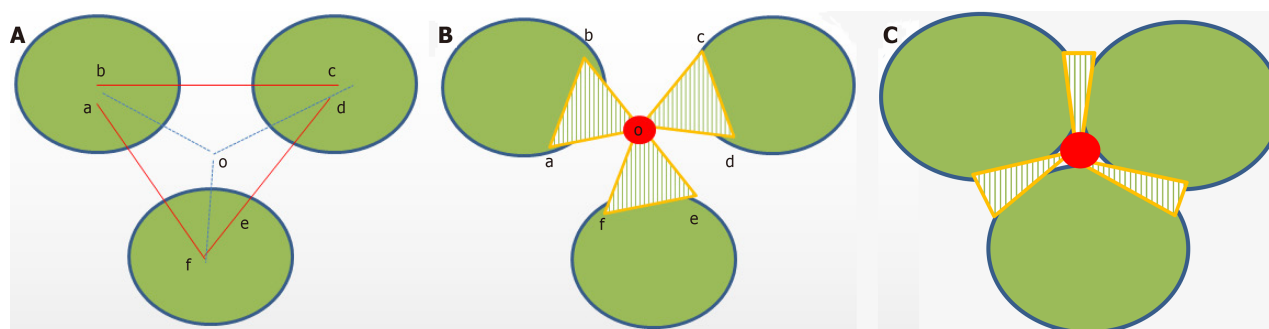
## DISCUSSION

Like Goldbach's conjecture, hilar cholangiocarcinoma is also known as the "pearl on the crown of the department of hepatobiliary surgery." Therefore, surgeons who have the courage and ability to perform hilar cholangiocarcinoma surgery are worthy of respect. At present, the surgical procedures for hilar cholangiocarcinoma are basically in accordance with the principles of the academician Huang<sup>[8]</sup>, including extrahepatic bile duct resection plus vascular skeletonization of the hepatoduodenal ligament for lymphoid tissue dissection, combined with left or right hepatic lobe (combined with caudate lobe) resection and hepatojejunostomy. If the portal vein or hepatic artery is invaded, it can be reconstructed by portal vein or hepatic artery R0 resection. The surgical procedure was based on the Bismuth classification as follows: The confluence of the left and right hepatic duct resections was performed for type I cases, combined with left and right hepatic duct formation plus Roux-en-Y hepatojejunostomy reconstruction. For type II, IIIa, or type IV, right trilectomy was necessary and combined with caudate lobectomy if the caudate lobe was invaded. For type IIIb, left hepatectomy was often required<sup>[9]</sup>.

Resection and reconstruction are two basic components of radical resection of hilar cholangiocarcinomas, and both influence and restrain each other. In addition, to complete R0 resection of hepatic bile duct lesions and vascular skeletonization of the hepatoduodenal ligament for lymphoid tissue dissection, the difficulty of radical resection of the hilar cholangiocarcinoma is related to vascular resection and reconstruction, as well as bilioenteric anastomosis reconstruction. Nearly 80% of patients with hilar cholangiocarcinomas have vascular invasion, most of which are portal vein invasion, and some are combined with hepatic artery invasion<sup>[10]</sup>. With the advancement of surgical technology, especially vascular surgery techniques, the concept of surgery has also been updated. Several studies have confirmed that portal vein/hepatic artery resection and reconstruction can improve the R0 resection rate and prognosis of patients with hilar cholangiocarcinoma<sup>[11–16]</sup>. Of the 76 patients in this study, 24 underwent hepatic artery reconstruction; 23, portal vein reconstruction; and 13, hepatic artery combined with portal vein reconstruction.

In addition, owing to the deep location of the portahepatis, narrow space, and more ends of the bile duct on the residual liver surface after the lesion was resected at a high position, hepatic-jejunal anastomosis technology has become one of the greatest technical challenges in surgery. In this case, end-to-end anastomosis of all levels (2, 3,

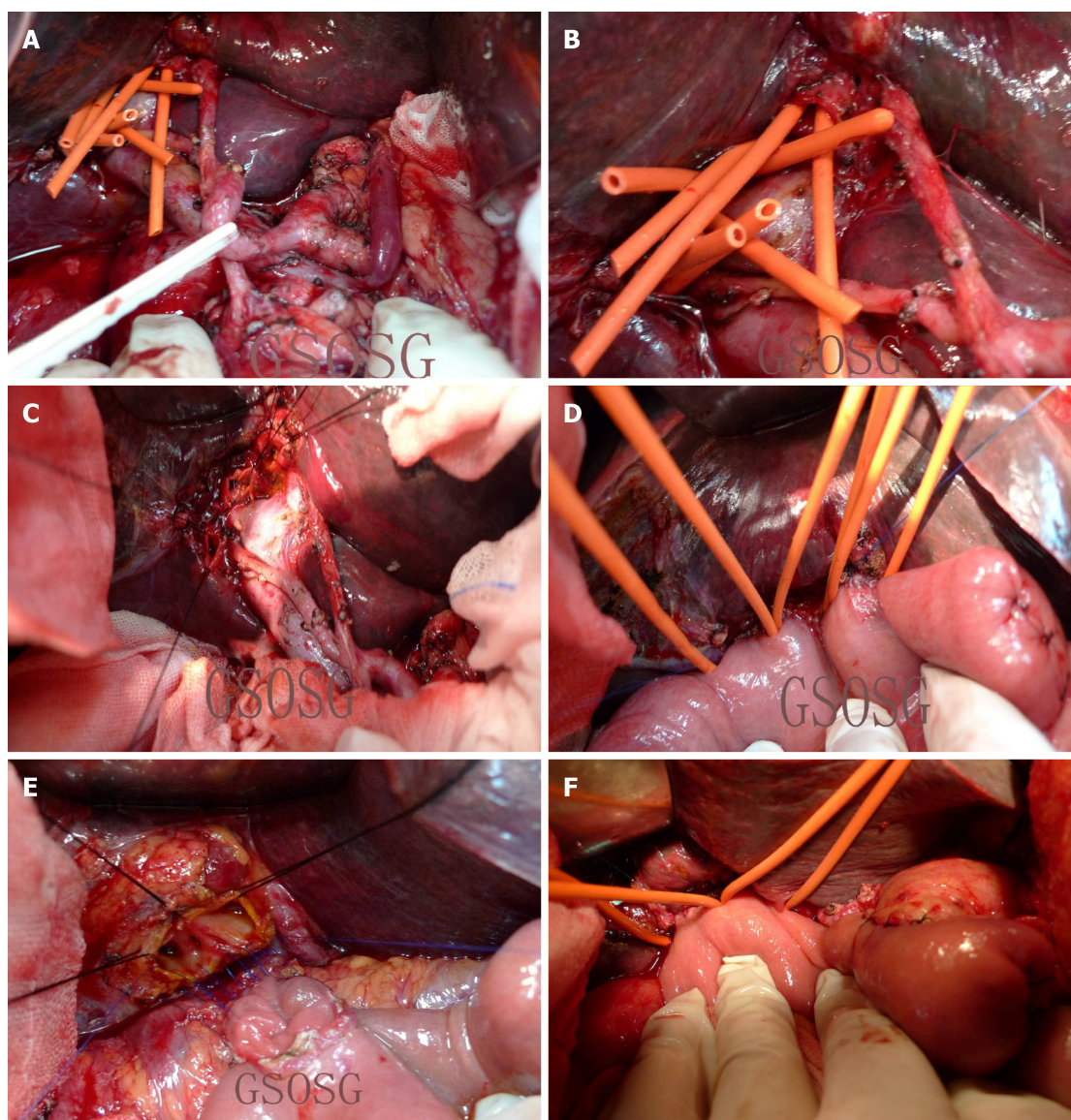




**Figure 1 Bile duct lake formation model.** A: Three of the adjacent bile ducts were formed into a bile duct lake. bc, de, and af are the adjacent bile duct septum incision lines cut to o; B: Suturing with 5-0 Prolene continuous sutures after adjacent bile duct incision. The adjacent edges, including bo and co, do and eo, and ao and fo, were continuously sutured to point o; C: Bile duct lake formation completed.

or even 4) of the bile duct and jejunal mucosa in each section was almost impossible. In view of this situation, professor Wu<sup>[6]</sup> established the basin-like Roux-en-Y cholangiojejunostomy for the radical resection of hilar cholangiocarcinoma in 1988. The grade 1-3 hepatic duct ends that had been cut were put together and reconstructed to form a wide hepatobiliary cavity, which was called "hepatobiliary duct basin," and then anastomosed with the jejunum. Academician Chen Xiaoping improved the anastomosis method in 2008<sup>[4]</sup>. First, the posterior walls of the bile duct opening and jejunal loop incision were sutured intermittently. After suturing the posterior wall, the anterior wall of the jejunal loop incision was sutured with a U-shaped suture to the liver above the bile duct opening. Some scholars further simplify the operation method and adopt the method of suturing the jejunum loop to the hepatic capsule and hepatic portal vascular sheath. This method is simple and easy to master, but has also many shortcomings such as bile leakage, infection, and anastomotic stenosis<sup>[17,18]</sup>.

Since 2008, we have made further improvements on the basis of the basin-like Roux-en-Y cholangiojejunostomy, and named it "multiple Roux-en-Y hepaticojejunostomy reconstruction by formation of a hilar bile duct lake." Thereby, a single "basin" is improved to 1-3 "lakes," making cholangioplasty and biliointestinal anastomosis relatively easy. Furthermore, the tension formed by splicing and suturing can also make the broken end of the bile duct open, conducive to the smooth drainage of the bile, thus reducing the risk of late biliary stricture. At the same time, biliary plasty and continuous suture during the formation of a bile duct lake can also play a hemostatic role, reducing the incidence of postoperative biliary bleeding. The mean operation time in 76 patients was 215.4 min. Among the patients, 22 underwent one bile duct lake formation; 34, formation of two bile duct lakes; and 20, formation of three bile duct lakes. The intraoperative blood loss was  $428.2 \pm 63.8$  mL. Postoperative complications occurred in 23 patients, including four with abdominal hemorrhage and 19 with bile leakage. No intraoperative death occurred. The overall 1- and 3-year survival rates were 78.9% and 32.8%, respectively. Therefore, the "multiple Roux-en-Y hepaticojejunostomy reconstruction by formation of a hilar bile duct lake" technique is safe and effective to use in the surgical treatment of hilar cholangiocarcinoma, which provides a reasonable choice for biliary surgeons to perform cholangiojejunostomy reconstruction in the radical operation of hilar cholangiocarcinoma.



**Figure 2 Intraoperative photographs.** A: Complete vascular skeletonization of the hepatoduodenal ligament, including groups 12a, b, c, h, p, 7, 8a, p, 9, and 11d; B: Radical resection and lymphadenectomy of hilar lesion R0 were completed; eight bile duct ends appeared on the remnant hepatic surface of the hilar region, which were hepatic segment ducts, including hepatic segments II, III, and IV; V, VII, and I; and VI and VII; C: Formation of bile duct lake was completed. Hepatic segments II, III, and IV; V, VIII, and I; and VI and VII were used to form a bile duct lake; D: Three of the end-to-side Roux-en-Y hepaticojejunostomy reconstructions by formation of bile duct lake were completed; E: Formation of a bile duct lake was completed using 5-0 Prolene continuous sutures; F: Two of the bile duct lake-forming jejunal end-to-side anastomosis were completed.



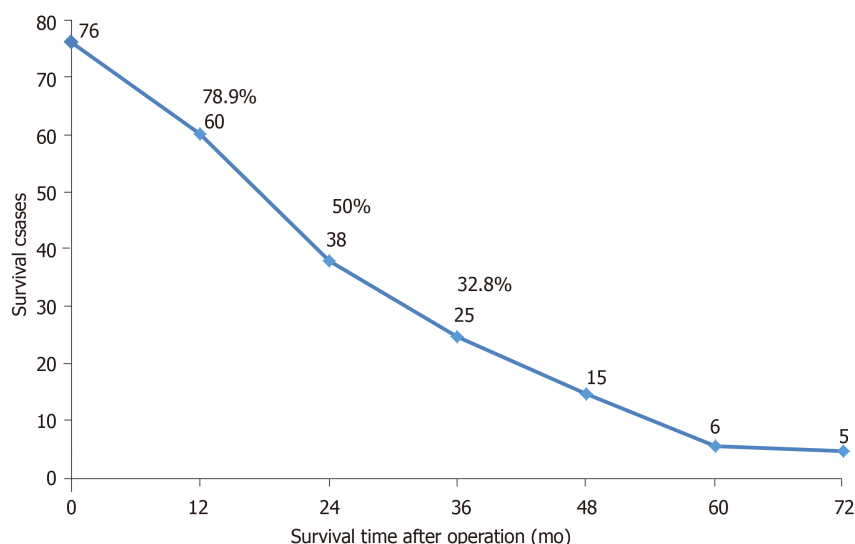


Figure 3 Survival curve.

## ARTICLE HIGHLIGHTS

### Research background

Hilar cholangiocarcinoma is the most common malignant tumor of the extrahepatic bile duct. Up to now, radical resection has been the most effective method for the long-term survival of patients with this disease. However, many problems have emerged in the field of hepatobiliary surgery over time, including complex surgical procedures, low resection rates, and postoperative complications. We have adopted the “multiple Roux-en-Y hepaticojejunostomy reconstruction by formation of bile duct lake” technique in the treatment of hilar cholangiocarcinoma since 2008, and obtained satisfactory short- and long-term results.

### Research motivation

To provide a reasonable choice for biliary surgeons to perform cholangiojejunostomy reconstruction in the radical operation of hilar cholangiocarcinoma.

### Research objectives

To examine the feasibility of the application of multiple Roux-en-Y hepaticojejunostomy reconstruction by formation of a bile duct lake in the operation of hilar cholangiocarcinoma.

### Research methods

A retrospective analysis was performed for the clinical data, surgical methods, and results of 76 patients with hilar cholangiocarcinoma who were treated with hilar bile duct lake-forming multiple Roux-en-Y hepaticojejunostomy reconstruction at Gansu Provincial Hospital.

### Research results

All 76 patients were successfully treated surgically, and no operative death occurred. The mean (range) operation time was  $215.4 \pm 53.5$  min (124–678 min), and the amount of intraoperative bleeding was  $428.2 \pm 63.8$  mL (240–2200 mL). The overall 1- and 3-year survival rates were 78.9% and 32.8%, respectively.

### Research conclusions

Multiple Roux-en-Y hepaticojejunostomy reconstruction by formation of a bile duct lake is safe and effective to use in the operation of hilar cholangiocarcinoma.

### Research perspectives

The “multiple Roux-en-Y hepaticojejunostomy reconstruction by formation of a hilar bile duct lake” technique is safe and effective to use in the surgical treatment of hilar cholangiocarcinoma, and thus provides a reasonable choice for biliary surgeons to perform cholangiojejunostomy reconstruction in the radical operation of hilar cholangiocarcinoma.

## REFERENCES

- 1 DeOliveira ML, Cunningham SC, Cameron JL, Kamangar F, Winter JM, Lillemoe KD, Choti MA, Yeo CJ, Schulick RD. Cholangiocarcinoma: thirty-one-year experience with 564 patients at a single institution. *Ann Surg* 2007; **245**: 755–762 [PMID: 17457168 DOI: 10.1097/01.sla.0000251366.62632.d3]
- 2 Yu XH, Liu C. Key Technologies of Surgical Treatment for Hilar Cholangiocarcinoma. *Gandan Waikie*

- Zazhi* 2017; **25**: 170-171
- 3 **Liu C**, Jiang XQ. Possibility of Radical Resection of Hilarcholangiocarcinoma. *Zhongguo Puwai Jichu and Linchuang Zazhi* 2016; **23**: 1299-1303 [DOI: [10.7507/1007-9424.20160334](https://doi.org/10.7507/1007-9424.20160334)]
  - 4 **Chen XP**, Zhang ZW, Huang ZY, Chen YF, Zhang WG, Qiu FZ. Improvement of Biliary Reconstruction after Resection of Hilarcholangiocarcinoma. *Zhonghua Waiké Zazhi* 2008; **46**: 634-635 [DOI: [10.3321/j.issn.0529-5815.2008.08.024](https://doi.org/10.3321/j.issn.0529-5815.2008.08.024)]
  - 5 **He XD**, Liu W, Tao LY, Zhang ZH, Cai L, Zhang SM. Clinical Value of Hilar Button Anastomosis in the Treatment of Type III and Type IV Hilarcholangiocarcinoma. *Zhonghua Zhongliu Zazhi* 2009; **31**: 626-629 [DOI: [10.3760/cma.j.issn.0253-3766.2009.08.014](https://doi.org/10.3760/cma.j.issn.0253-3766.2009.08.014)]
  - 6 **Wu JS**. Basin-like Biliary Enterostomy for Biliary. *Yixue Linchuang Yanjiu* 2002; **19**: 78-80 [DOI: [10.3969/j.issn.1671-7171.2002.06.047](https://doi.org/10.3969/j.issn.1671-7171.2002.06.047)]
  - 7 **Chen DX**, Xing GY, Liu Y. Hotspots in Surgical Treatment of Hilarcholangiocarcinoma. *Zhonghua Qiangjing Waiké Zazhi* 2017; **10**: 196-199 [DOI: [10.3877/cma.j.issn.1674-6899.2017.04.002](https://doi.org/10.3877/cma.j.issn.1674-6899.2017.04.002)]
  - 8 **Huang ZQ**. The Present situation of Surgical Treatment of Hilarcholangiocarcinoma and My Opinion. *Zhongguo Shiyong Waiké Zazhi* 2007; **27**: 341-346 [DOI: [10.3321/j.issn.1005-2208.2007.05.001](https://doi.org/10.3321/j.issn.1005-2208.2007.05.001)]
  - 9 **Zhao S**, Wang X, Liu YB. Surgical Controversy and Perihepatic Resection of Hilarcholangiocarcinoma. *Gandanyi Waiké Zazhi* 2016; **28**: 346-350 [DOI: [10.11952/j.issn.1007-1954.2016.04.026](https://doi.org/10.11952/j.issn.1007-1954.2016.04.026)]
  - 10 **Wang JM**, Jiang YQ, Zou SQ. Application of Combined Vascular Resection and Reconstruction in Resection for Advanced Hilar Cholangiocarcinoma. *Zhongguo Puwai Jichu and Linchuang Zazhi* 2011; **18**: 579-582
  - 11 **Miyazaki M**, Kato A, Ito H, Kimura F, Shimizu H, Ohtsuka M, Yoshidome H, Yoshitomi H, Furukawa K, Nozawa S. Combined vascular resection in operative resection for hilar cholangiocarcinoma: does it work or not? *Surgery* 2007; **141**: 581-588 [PMID: [17462457](https://pubmed.ncbi.nlm.nih.gov/17462457/) DOI: [10.1016/j.surg.2006.09.016](https://doi.org/10.1016/j.surg.2006.09.016)]
  - 12 **Song GW**, Lee SG, Hwang S, Kim KH, Cho YP, Ahn CS, Moon DB, Ha TY. Does portal vein resection with hepatectomy improve survival in locally advanced hilar cholangiocarcinoma? *Hepatogastroenterology* 2009; **56**: 935-942 [PMID: [19760915](https://pubmed.ncbi.nlm.nih.gov/19760915/)]
  - 13 **Igami T**, Nishio H, Ebata T, Yokoyama Y, Sugawara G, Nimura Y, Nagino M. Surgical treatment of hilar cholangiocarcinoma in the "new era": the Nagoya University experience. *J Hepatobiliary Pancreat Sci* 2010; **17**: 449-454 [PMID: [19806294](https://pubmed.ncbi.nlm.nih.gov/19806294/) DOI: [10.1007/s00534-009-0209-0](https://doi.org/10.1007/s00534-009-0209-0)]
  - 14 **Wang PF**, Zhu ZM, Cai SW. Resection and Reconstruction of Hilarcholangiocarcinoma. *Linchuang Waiké Zazhi* 2017; **25**: 177-177 [DOI: [10.3969/j.issn.1005-6483.2017.03.004](https://doi.org/10.3969/j.issn.1005-6483.2017.03.004)]
  - 15 **Chen ZY**, Beiping. Combined Vascular Resection and Reconstruction in the Surgical Treatment of Hilarcholangiocarcinoma. *Linchuang Gandanbing Zazhi* 2016; **32**: 1277-1279 [DOI: [10.3969/j.issn.1001-5256.2016.07.011](https://doi.org/10.3969/j.issn.1001-5256.2016.07.011)]
  - 16 **Bai XL**, Ma T, Yu XZ, Liang TB. Evaluation of Radical Resection of Hilarcholangiocarcinoma Combined with Vascular Resection and Reconstruction. *Zhonghua Puwaike Shoushuxue Zazhi* 2015; **9**: 12-15 [DOI: [10.3877/cma.j.issn.1674-3946.2015.05.101](https://doi.org/10.3877/cma.j.issn.1674-3946.2015.05.101)]
  - 17 **Nimura Y**. Radical surgery of left-sided klatskin tumors. *HPB (Oxford)* 2008; **10**: 168-170 [PMID: [18773047](https://pubmed.ncbi.nlm.nih.gov/18773047/) DOI: [10.1080/13651820801992674](https://doi.org/10.1080/13651820801992674)]
  - 18 **Yuan SG**, Nong KT, Liu J, Lv J, Weng J, Yang JH, Chen Q, Mei MH. Proprietary Continuous Hepaticojunostomy for Advanced Hilarcholangiocarcinoma. *Sichuan Yixue* 2011; **32**: 73-75 [DOI: [10.16252/j.cnki.issn1004-0501-2011.01.056](https://doi.org/10.16252/j.cnki.issn1004-0501-2011.01.056)]



Published By Baishideng Publishing Group Inc  
7041 Koll Center Parkway, Suite 160, Pleasanton, CA 94566, USA  
Telephone: +1-925-2238242  
E-mail: [bpgoffice@wjgnet.com](mailto:bpgoffice@wjgnet.com)  
Help Desk: <https://www.f6publishing.com/helpdesk>  
<https://www.wjgnet.com>

